

Tenascin is a stromal marker for epithelial malignancy in the mammary gland

(extracellular matrix/mammary tumor)

ELEANOR J. MACKIE*[†], RUTH CHIQUET-EHRISMANN*, CAROLYN ADAMS PEARSON*, YUTAKA INAGUMA[‡], KOJI TAYA[§], YOSHIFUMI KAWARADA[§], AND TERUYO SAKAKURA^{†¶}

*Friedrich Miescher-Institut, Postfach 2543, CH-4002 Basel, Switzerland; [‡]Laboratory of Experimental Pathology, Aichi Cancer Center Research Institute, Nagoya 464, Japan; and [§]The First Department of Surgery, Mie University School of Medicine, Tsu 514, Mie, Japan

Communicated by Diter von Wettstein, March 9, 1987 (received for review December 27, 1986)

ABSTRACT Tenascin is an extracellular matrix glycoprotein that is not present in the normal mature rat mammary gland. The distribution of tenascin was examined by immunohistochemistry in mammary tumors from carcinogen-treated and untreated rats, in virus-induced mammary tumors from mice, and in a variety of mammary gland lesions from humans. Tenascin was detectable in the stroma of the malignant but not of the benign tumors from all species. An inhibition ELISA, testing homogenates of rat tumors, confirmed that tenascin was present in malignant but not in benign tumors. Thus, tenascin was consistently found to be a stromal marker for epithelial malignancy in the mammary gland. It is concluded that tenascin may be involved in the interactions between the epithelial and mesenchyme-derived (stromal) components of the mammary gland, which are known to influence epithelial carcinogenesis in this organ.

Epithelial-mesenchymal interactions are important for the normal embryonic and postnatal development of many organs including the mammary gland (1). In addition, interactions between the epithelial and mesenchyme-derived (stromal) components are known to influence epithelial carcinogenesis in the mammary gland (2). Grobstein's studies suggested that induction of epithelial development is mediated by the extracellular matrix laid down by the organ-specific mesenchyme (3). Thus, mesenchymal extracellular matrix molecules that show variations in their tissue distributions during development and neoplasia are potential mediators of mesenchymal-epithelial interactions. The extracellular matrix glycoprotein tenascin, which was previously described as myotendinous antigen (4), and may be identical to J1 (5), cytactin (6), and glioma-associated extracellular matrix antigen (7), appears to be such a molecule. Tenascin is present in the early fetal rat mammary gland only in the dense mesenchyme closely surrounding the epithelial rudiment (8). It is not detectable in the mature rat mammary gland but is present in the stroma of rat mammary adenocarcinomas induced by the carcinogen *N*-methyl-*N*-nitrosourea (MNU; ref. 8). In the present study, the distribution of tenascin was examined in a wide variety of mammary tumors from laboratory animals to determine whether the presence of tenascin could be correlated with any particular type of neoplastic change in the mammary gland. Because of the potential clinical importance of an antigen that is not present in the normal gland but appears in mammary tumors, various human mammary lesions were also investigated.

The publication costs of this article were defrayed in part by page charge payment. This article must therefore be hereby marked "advertisement" in accordance with 18 U.S.C. §1734 solely to indicate this fact.

MATERIALS AND METHODS

Preparation of Antiserum. Antiserum was raised in rabbits to tenascin purified from conditioned medium of chicken embryo fibroblast cultures, as described (8). The antiserum was found to cross-react with rat, mouse, and human tenascin.

Tissues and Immunohistochemistry. Outbred Sprague-Dawley rats were treated with MNU for the induction of mammary tumors as described (8). Spontaneous mammary tumors were obtained from 7 of 213 untreated rats. Rat tumors and some tumors from GR mice were frozen unfixed and sectioned as described (8). Normal mammary gland from a 6-month-old rat was removed and frozen for use in the inhibition ELISA.

GR mice were obtained in 1976 from The Netherlands Cancer Institute (Amsterdam) and were maintained at the Aichi Cancer Center Research Institute as an inbred colony. Cumulative mammary cancer incidence for the last 5 years of breeders and virgins 12 months old is 93.1% and 28.0%, respectively. Hormone- (pregnancy-)dependent tumors were observed in 16.0%, 39.1%, and 79.5%, respectively, at the first, second, and third pregnancy. GR mice carrying mammary tumors were fixed by intracardiac perfusion with cold 95% ethanol containing 1% glacial acetic acid, and then tumors were removed and dehydrated. Surgically extirpated human tissues were fixed with cold 95% ethanol containing 1% glacial acetic acid. Human and mouse tumors were embedded in polyester wax and cut according to the method described (9). The sections were placed on egg albumin-coated glass slides and dried at 4°C. After the wax was removed in absolute ethanol, the sections were washed in phosphate-buffered saline.

Frozen sections and polyester wax-embedded sections were stained for the presence of tenascin by indirect immunofluorescence as described (8). Some sections of benign tumors from rats were treated with collagenase (Sigma, type I; 0.5 mg/ml, 20 min, 37°C), trypsin (GIBCO; 0.05 mg/ml, 5 min, 37°C), or hyaluronidase (Calbiochem; 0.1 mg/ml, 20 min, 22°C), and then washed in phosphate-buffered saline before application of the first antibody. Some sections from all tumors were stained with hematoxylin and eosin by standard histological methods.

Inhibition ELISA. The ELISA wells were coated with a 1:1 mixture of rat fibronectin and tenascin, and the assay was performed as described (8). Standard curves of antibody dilutions were made and the antibody concentration resulting in half-maximal absorbance was chosen for the inhibition

Abbreviation: MNU, *N*-methyl-*N*-nitrosourea.

[†]Present address: Tsukuba Life Science Center, 3-1-1 Koyadai, Yatabe, Tsukuba, Ibaraki 305, Japan.

[¶]To whom reprint requests should be addressed.

experiment. Samples of rat tissues for antibody absorption (benign and malignant tumors and normal adult mammary gland) were prepared by pulverization of the tissues under liquid nitrogen. Aliquots of 100 μ l of diluted antisera were added to 25 μ g of the frozen powdered tissues. The mixtures were incubated for 1 hr at 4°C and then assayed on the ELISA wells. An unrelated chicken-specific mouse antibody was included in this incubation mixture. The reactivity of this antibody with its antigen was not inhibited by any of the powdered tissues, demonstrating that inhibition of anti-tenascin or anti-fibronectin reactivity by a tissue sample was due to a specific antigen-antibody interaction.

RESULTS

Mammary adenocarcinomas (malignant tumors) produced in rats by the administration of MNU consist of lobules of neoplastic epithelium separated by bands of fibrous stroma (10). In immunohistochemical studies, these tumors were found to contain tenascin in the fibrous areas and the staining was most intense in the areas apposing the tumor epithelium (8). In the present study, spontaneous mammary adenocarcinomas from untreated rats were examined. They were similar histologically to the carcinogen-induced tumors, but one contained, in addition, areas composed of single tubular epithelial structures scattered amongst an extensive fibrous stroma, as illustrated in Fig. 1 *a-c*. These tumors also contained tenascin throughout the stroma. In contrast, benign mammary tumors (fibroadenomas) from MNU-treated or untreated rats contained no detectable tenascin (Fig. 1 *d-f*). Because it was considered possible that tenascin was being masked by other extracellular matrix molecules in the sections of benign tumors, sections from each of the benign rat tumors were treated with collagenase, trypsin, or hyaluronidase before staining. Tenascin was still not detectable in benign tumors after any of the treatments.

Pieces of benign and malignant rat tumors, as well as normal mammary gland, were pulverized and tested for the presence of tenascin in an inhibition ELISA (Fig. 2). The samples were also tested for the presence of fibronectin, which is known to be present in all these tissues (8). All samples tested removed the activity from anti-fibronectin antiserum, whereas only the sample of the malignant tumor was able to remove the activity from anti-tenascin antiserum. These results confirmed that fibronectin was present in all tissues analyzed, but tenascin was present only in the malignant tumors.

Mice of the GRS/A strain (GR) possess an endogenous mammary tumor virus (11). Hormone-dependent tumors appear in these mice during early pregnancies, regress after parturition, and reappear with successive pregnancies. They are classified as type P (pregnancy dependent) mammary tumors and consist mostly of small or large ductal and alveolar elements surrounded by various amounts of fibrous stroma. A single tumor can contain histologically benign and malignant areas (11). The malignant areas of the hormone-dependent GR tumors contained tenascin, whereas no tenascin was detected in the well-differentiated benign areas (Fig. 3 *d-f*). After several pregnancies, some tumors become hormone independent and are consistently malignant. Such tumors all contained tenascin in the stroma surrounding the neoplastic epithelium (Fig. 3 *a-c*).

Tenascin was present in the fibrous stroma of all of the malignant human mammary tumors examined including scirrhous adenocarcinomas and tubular adenocarcinomas (Fig. 4 *a-c*). Tenascin was only present in the fibrous stroma and not in the neoplastic epithelium. Benign human mammary neoplasms including fibroadenomas and mastopathies, which contain large amounts of fibrous tissue not present in the normal mammary gland, contained no tenascin. One case of chronic mastitis, another benign mammary lesion, was examined and tenascin was not detected (Fig. 4 *d-f*). Tenascin

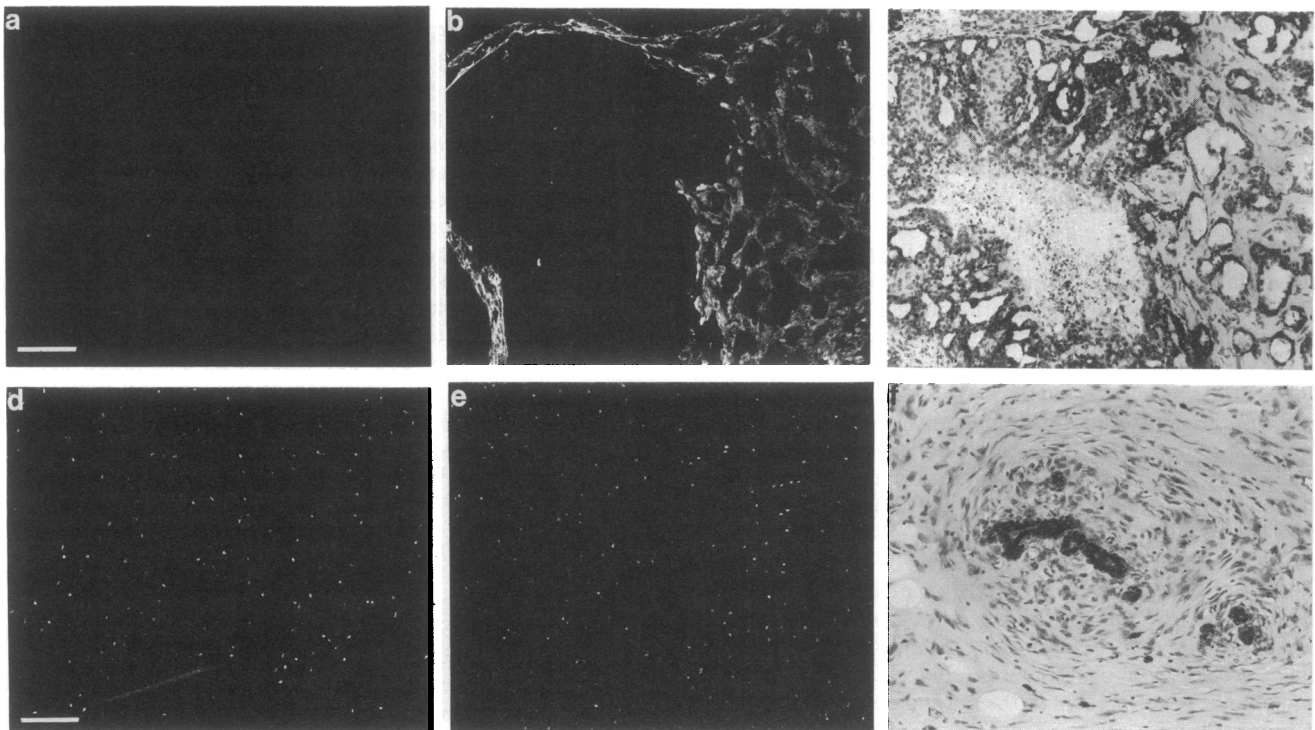


FIG. 1. Distribution of tenascin in rat mammary tumors. Serial cryosections of a mammary adenocarcinoma from an untreated rat (*a-c*) and a mammary fibroadenoma from an MNU-treated rat (*d-f*), stained with preimmune serum (*a* and *d*), antiserum to tenascin (*b* and *e*), or hematoxylin and eosin (*c* and *f*). (Bars = 50 μ m.) The spots in *d* and *e* are due to background fluorescence of unknown cause and are irrelevant. All mammary carcinomas examined from MNU-treated rats ($n = 20$) and untreated rats ($n = 4$) contained tenascin. All mammary fibroadenomas examined from MNU-treated rats ($n = 2$) and untreated rats ($n = 3$) contained no tenascin.

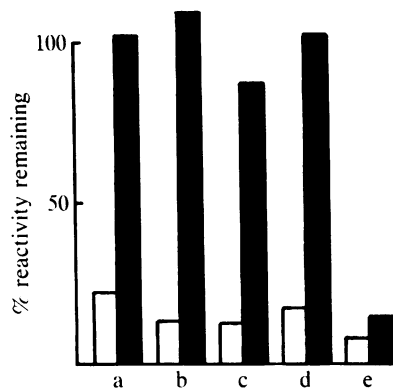


FIG. 2. Inhibition ELISA for detection of tenascin in rat mammary tissues. Percentage of control reactivity remaining after anti-fibronectin (open bars) or anti-tenascin (solid bars) antisera were preincubated with pulverized tissue samples of normal mammary gland (a), three of the benign tumors mentioned in Fig. 1 (b–d), and an MNU-induced malignant tumor (e).

was also undetectable in areas of normal mammary gland, adjacent to the lesions, in sections of human mammary tissue.

DISCUSSION

The results presented here describe the appearance in malignant mammary tumors of a stromal protein that is not detectable in normal mature mammary gland or benign mammary tumors. Variations have been reported in the distribution or amounts of extracellular matrix components produced by the stroma with neoplastic change in the

mammary gland. Type III and type V collagens are increased in human breast carcinomas (12, 13) and the relative amounts of various glycosaminoglycans in the mammary gland change with carcinogenesis (14). To our knowledge, however, the malignancy-related appearance of a stromal molecule not present in the normal mature mammary gland has not previously been reported.

The fibrous stroma of epithelial tumors is generally regarded as being recruited by the neoplastic epithelium to support tumor growth (15). Indeed, it has been demonstrated that in transplanted tumors collagen production is carried out by the host but regulated by the tumor epithelium (16). When a transplantable mouse mammary carcinoma cell line (CMT-315) was transplanted into nude mice, tenascin was detected by immunohistochemistry in the host-supplied stroma of the resulting tumor (Y.I. and T.S., unpublished results). This suggests that the neoplastic epithelium induces the production of tenascin by the tumor stroma. Tenascin is also present in the dense mesenchyme of the early fetal gland (8). It seems likely that some factor common to early fetal mammary epithelium and malignant mammary tumor epithelium may cause the production of tenascin by the mesenchyme or mesenchyme-derived stroma. Tenascin may in turn influence the mammary epithelium and contribute to the mesenchymal induction, which is known to be important during fetal development and carcinogenesis in the mammary gland (17). It has previously been demonstrated that tenascin is a poor substrate for attachment of mammary tumor epithelium compared with other extracellular matrix proteins with which the epithelium comes in contact *in vivo* (8). Perhaps, by causing detachment of tumor epithelium from the extracellular matrix, tenascin allows the cells to become invasive,

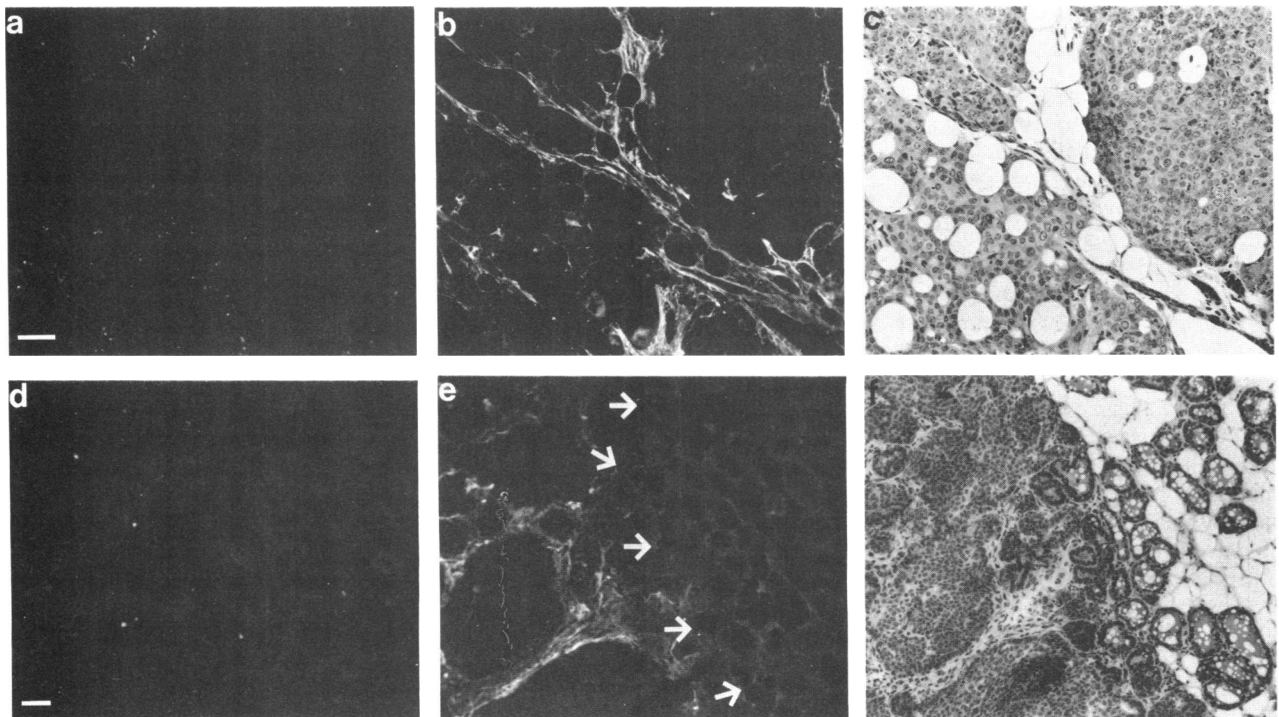


FIG. 3. Distribution of tenascin in GR mouse mammary tumors. Wax-embedded sections of a hormone-independent mammary tumor from a multiparous female (a–c) and cryosections of a hormone-dependent mammary tumor taken from a young female on the day of parturition (d–f), stained with preimmune serum (a and d), antiserum to tenascin (b and e) or hematoxylin and eosin (c and f). (c) Same section as in b, stained first for tenascin and then with hematoxylin and eosin. (d–f) Same area of three adjacent sections. Arrows outline a hyperplastic (benign) area where the epithelial cells are in an alveolar arrangement and some are secreting; no tenascin is detectable in this area. The remainder of the photographed area contains malignant epithelial cells in solid masses surrounded by fibrous stroma, which is positively stained by anti-tenascin antiserum. (Bars = 50 μ m.) In all the hormone-dependent tumors examined ($n = 18$), tenascin was associated exclusively with histologically malignant areas. All hormone-independent mammary tumors ($n = 15$) contained tenascin.

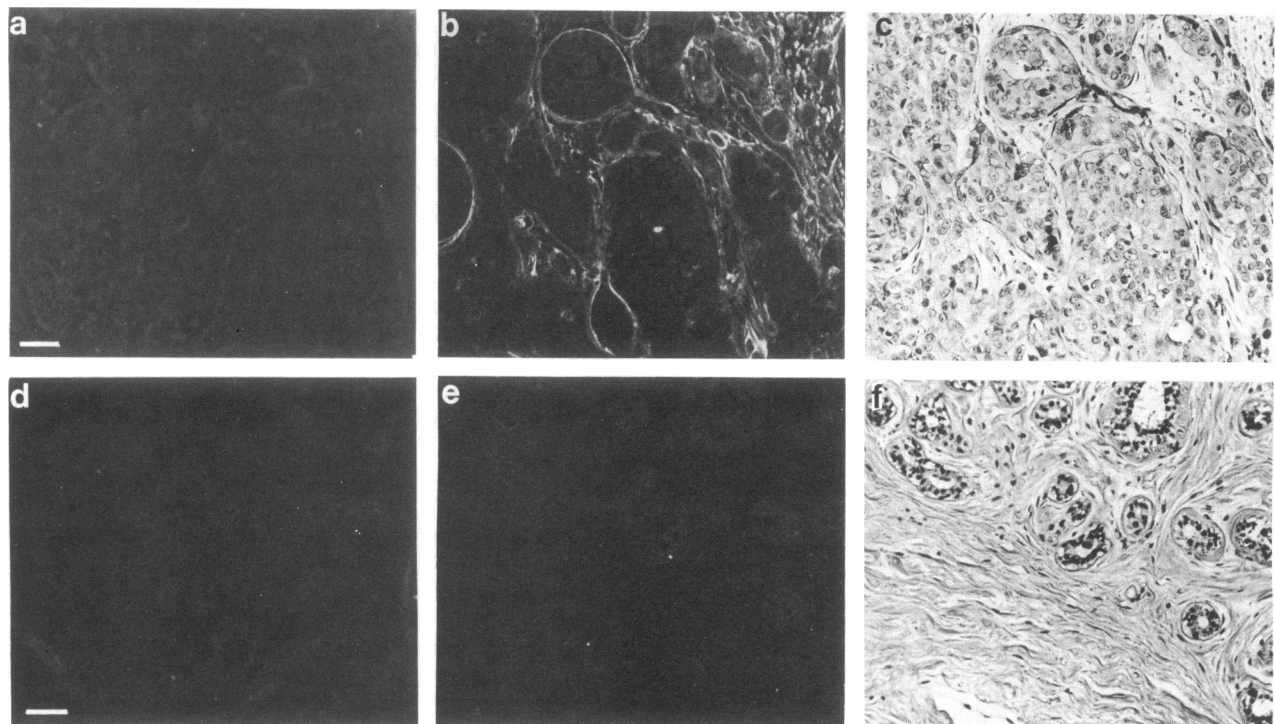


FIG. 4. Distribution of tenascin in human mammary tumors. Sections of a tubular adenocarcinoma and a fibroadenoma stained with preimmune serum (*a* and *d*), antiserum to tenascin (*b* and *e*), or hematoxylin and eosin (*c* and *f*). (*c*) Same section as in *b*; (*f*) same section as in *e*, stained first for tenascin and then with hematoxylin and eosin. (Bars = 50 μ m.) All malignant human mammary tumors examined (8 tubular adenocarcinomas including solid, medullary, papillary, and scirrhous forms) contained tenascin. All benign human mammary tumors examined (7 fibroadenomas and 15 cases of mastopathies), as well as 1 case of mastitis, contained no tenascin.

thus conferring on them the main characteristic that distinguishes malignant from benign cells.

The presence of tenascin in the adult mammary gland was found to be a consistent indicator of malignancy in mammary tumors of known and unknown etiologies for all the species examined. Consequently, antibodies to tenascin may prove to be a useful diagnostic tool in differentiating between benign and malignant mammary lesions and may be useful for cancer therapy. In recent years, many epithelial mammary tumor antigens have been studied but they are not reliable in distinguishing malignant from benign tumors or are not produced by all malignant tumors (18–22).

Possible diagnostic uses of tumor markers include detection in plasma of markers that are normally absent or present at low levels. Radioactively labeled antibodies to tenascin may be effective in the imaging of malignant mammary tumors *in situ* using methods such as those reviewed by Teh *et al.* (13). This suggestion is supported by the fact that human glioma xenografts in nude mice have been successfully localized by radioimaging using a monoclonal antibody to glioma-associated extracellular matrix antigen (23). This extracellular matrix glycoprotein has striking structural similarities to tenascin and may, therefore, be identical to tenascin (7). In addition, antibodies to tumor-associated antigens could become useful in the treatment of cancer. This approach is being used in several clinical trials (24). Tenascin, which was shown to be present in malignant mammary tumors and has a limited distribution in normal adult tissues (ref. 4; E.J.M., unpublished results), is a potentially useful target for antibody-mediated delivery of chemotherapeutic drugs or radionuclides.

Note Added in Proof. Another study of human mammary tissue has been carried out by J. H. Daams and R. A. Verstraeten (The Netherlands Cancer Institute) after this paper was accepted for publication. In their study, staining with our anti-tenascin antiserum

was seen in a line around normal mammary epithelium in some lobules and not in others.

We thank Drs. S. Stone, A. Matus, C. Moroni, and M. Chiquet for critical reading of the manuscript.

1. Kratochwil, K. (1969) *Dev. Biol.* **20**, 46–71.
2. Sakakura, T., Sakagami, Y. & Nishizuka, Y. (1981) *J. Natl. Cancer Inst.* **66**, 953–957.
3. Grobstein, C. (1954) in *Aspects of Synthesis and Order in Growth*, ed. Rudnick, D. (Princeton Univ. Press, Princeton, NJ), pp. 253–256.
4. Chiquet, M. & Fambrough, D. M. (1984) *J. Cell Biol.* **98**, 1926–1936.
5. Kruse, J., Keilhauer, G., Faissner, A., Timpl, R. & Schachner, M. (1985) *Nature (London)* **316**, 146–148.
6. Grumet, M., Hoffman, S., Crossin, K. L. & Edelman, G. M. (1985) *Proc. Natl. Acad. Sci. USA* **82**, 8075–8079.
7. Bourdon, M. A., Matthews, T. J., Pizzo, S. V. & Bigner, D. D. (1985) *J. Cell. Biochem.* **28**, 183–195.
8. Chiquet-Ehrismann, R., Mackie, E. J., Pearson, C. A. & Sakakura, T. (1986) *Cell* **47**, 131–139.
9. Kusakabe, M., Sakakura, T., Nishizuka, Y., Sano, M. & Matsukage, A. (1984) *Stain Technol.* **59**, 127–132.
10. McCormick, D. L., Adamowski, C. B., Fiks, A. & Moon, R. C. (1981) *Cancer Res.* **41**, 1690–1694.
11. van Nie, R. (1981) in *Mammary Tumors in the Mouse*, eds. Hilgers, J. & Sluysers, M. (Elsevier/North-Holland Biomed., Amsterdam), pp. 201–266.
12. Barsky, S. H., Rao, C. N., Grotendorst, G. R. & Liotta, L. A. (1982) *Am. J. Pathol.* **108**, 276–283.
13. Lagace, R., Grimaud, J.-A., Schurch, W. & Seemayer, T. A. (1985) *Virchows Arch. A* **408**, 49–59.
14. Takeuchi, J., Sobue, M., Sato, E., Shamoto, M., Miura, K. & Nakagaki, S. (1976) *Cancer Res.* **36**, 2133–2139.
15. Robbins, S. L., Cotran, R. S. & Kumar, V. (1984) *Pathologic Basis of Disease* (Saunders, Philadelphia), pp. 214–253.
16. Gullino, P. M. & Grantham, F. H. (1963) *Cancer Res.* **23**, 648–653.

17. Sakakura, T. (1983) in *Understanding Breast Cancer: Clinical and Laboratory Concepts*, eds. Rich, M. A., Hager, J. C. & Furmanski, P. (Dekker, New York), pp. 261–284.
18. Teh, J. G., Stacker, S. A., Thompson, C. H. & McKenzie, I. F. C. (1985) *Cancer Surv.* **4**, 149–184.
19. Khaw, B. A., Strauss, H. W., Cahill, S. L., Soule, H. R., Edgington, T. & Cooney, J. (1984) *J. Nucleic Med.* **25**, 592–603.
20. Berry, N., Jones, D. B., Smallwood, J., Taylor, I., Kirkham, N. & Taylor-Papadimitriou, J. (1985) *Br. J. Cancer* **51**, 179–186.
21. Johnson, C. W., Wei, W.-Z., Barth, R. F., Tuttle, S. E. & Andrews, C. A. (1985) *Cancer Res.* **45**, 3774–3781.
22. White, C. A., Dulbecco, R., Allen, R., Bowman, M. & Armstrong, B. (1985) *Cancer Res.* **45**, 1337–1343.
23. Bourdon, M. A., Coleman, R. E., Blasberg, R. G., Groothuis, D. R. & Bigner, D. D. (1984) *Anticancer Res.* **4**, 133–140.
24. Reisfeld, R. A. & Cheresch, D. A. (1985) *Cancer Surv.* **4**, 271–290.