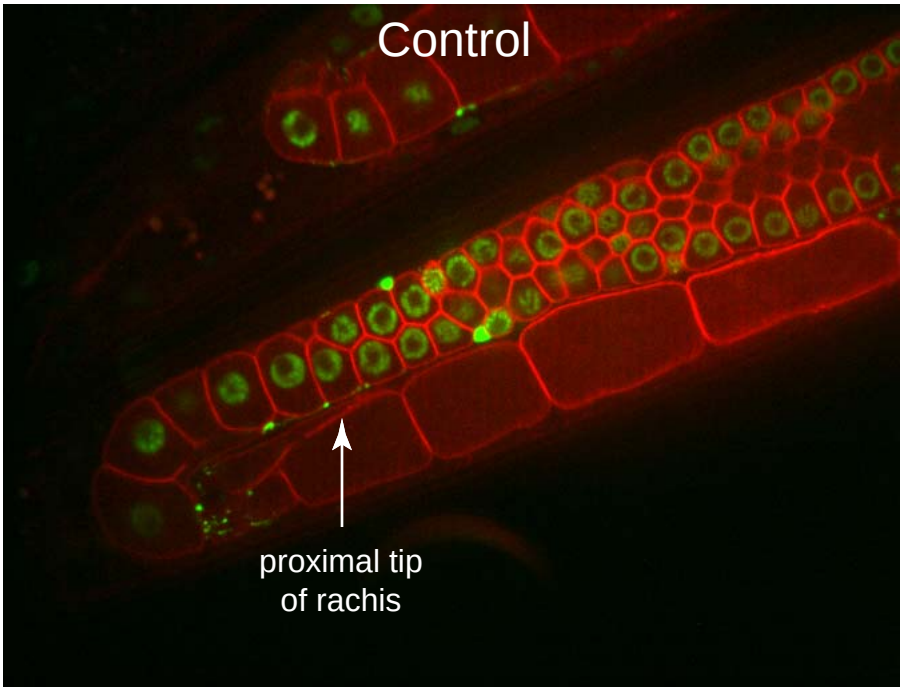
Control
proximal tip
of rachis

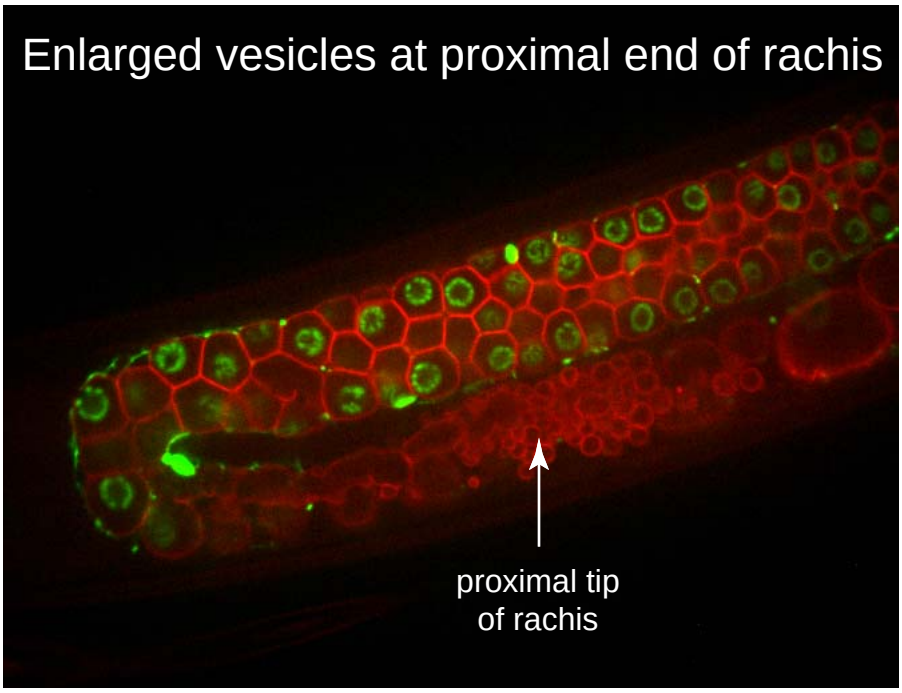
Enlarged vesicles at proximal end of rachis
proximal tip
of rachis