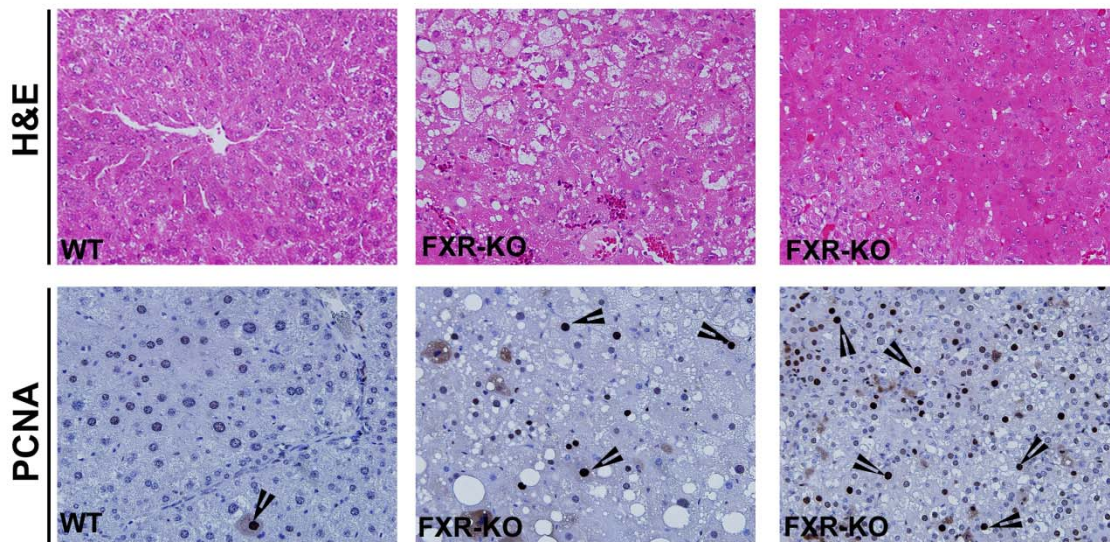


**Increased Activation of Wnt/ $\beta$ -catenin Pathway in Spontaneous Hepatocellular Carcinoma observed in Farnesoid X Receptor Knockout Mice.** Wolfe A, Thomas A, Edwards G, Jaseja R, Guo GL, and Apte U. **Journal of Pharmacology and Experimental Therapeutics**



**Supplementary Figure 1.** Pathological characteristics of spontaneous HCC in FXR-KO mice. *Upper panel,* Representative photographs of H&E stained paraffin sections of livers from WT and FXR-KO mice. *Lower panel,* Representative photographs of the PCNA immunohistochemistry on liver sections from WT and FXR-KO livers. Arrowheads point to cells in S-phase of cell cycle. Magnification 400x.

**Increased Activation of Wnt/ $\beta$ -catenin Pathway in Spontaneous Hepatocellular Carcinoma observed in Farnesoid X Receptor Knockout Mice.** Wolfe A, Thomas A, Edwards G, Jaseja R, Guo GL, and Apte U. **Journal of Pharmacology and Experimental Therapeutics**

**Supplementary Table 1.** Clinical Characteristics of normal and HCC samples used in the study.

Gender	Age	Diagnosis	Tumor Grade	Stage
Male	81	Normal	N/A	N/A
Male	73	Normal	N/A	N/A
Male	71	Normal	N/A	N/A
Male	86	Normal	N/A	N/A
Male	52	Normal	N/A	N/A
Female	33	Normal	N/A	N/A
Male	66	Normal	N/A	N/A
Male	68	Normal	N/A	N/A
Male	81	Hepatocellular Carcinoma	AJCC G1: Well differentiated	I
Male	79	Hepatocellular Carcinoma	AJCC G2: Moderately differentiated	I
Female	61	Hepatocellular Carcinoma	AJCC G1: Well differentiated	I
Female	58	Hepatocellular Carcinoma	Unknown	I
Male	66	Hepatocellular Carcinoma	AJCC G3: Poorly differentiated	I
Female	62	Cholangiocarcinoma	AJCC G2: Moderately differentiated	I
Female	78	Cholangiocarcinoma	AJCC G2: Moderately differentiated	I
Female	63	Hepatocellular Carcinoma	AJCC G2: Moderately differentiated	II

**Increased Activation of Wnt/ $\beta$ -catenin Pathway in Spontaneous Hepatocellular Carcinoma observed in Farnesoid X Receptor Knockout Mice.** Wolfe A, Thomas A, Edwards G, Jaseja R, Guo GL, and Apte U. **Journal of Pharmacology and Experimental Therapeutics**

Male	73	Hepatocellular Carcinoma	AJCC G2: Moderately differentiated	II
Male	68	Hepatocellular Carcinoma	Not Reported	II
Male	60	Hepatocellular Carcinoma	AJCC G3: Poorly differentiated	II
Female	62	Hepatocellular Carcinoma	AJCC G1: Well differentiated	II
Male	60	Hepatocellular Carcinoma	AJCC G2: Moderately differentiated	II
Male	77	Hepatocellular Carcinoma	AJCC G1: Well differentiated	II
Male	63	Hepatocellular Carcinoma	AJCC G2: Moderately differentiated	II
Female	39	Hepatocellular Carcinoma	AJCC G1: Well differentiated	IIIA
Male	43	Hepatocellular Carcinoma	AJCC G3: Poorly differentiated	IIIA
Female	79	Hepatocellular Carcinoma	AJCC G2: Moderately differentiated	IIIA
Male	56	Hepatocellular Carcinoma	AJCC G2: Moderately differentiated	IIIA
Male	71	Hepatocellular Carcinoma	AJCC G2: Moderately differentiated	IIIA
Male	86	Hepatocellular Carcinoma	AJCC G1: Well differentiated	IIIA
Male	26	Hepatocellular Carcinoma	AJCC G2: Moderately differentiated	IIIA
Male	68	Hepatocellular Carcinoma	AJCC G2: Moderately differentiated	IIIA

**Increased Activation of Wnt/ $\beta$ -catenin Pathway in Spontaneous Hepatocellular Carcinoma observed in Farnesoid X Receptor Knockout Mice.** Wolfe A, Thomas A, Edwards G, Jaseja R, Guo GL, and Apte U. **Journal of Pharmacology and Experimental Therapeutics**

Male	21	Hepatocellular Carcinoma	AJCC G2: Moderately differentiated	IV
Male	70	Hepatocellular Carcinoma, metastatic	AJCC G3: Poorly differentiated	IV
Male	66	Cholangiocarcinoma of liver, metastatic	Unknown	IV