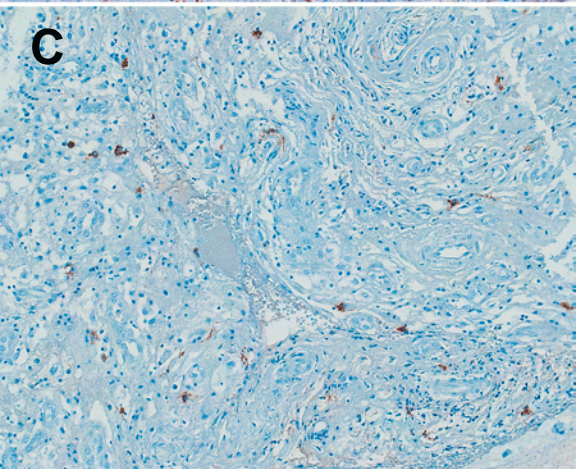
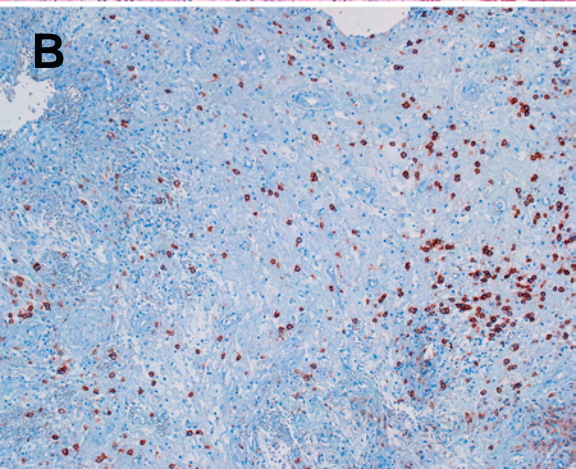
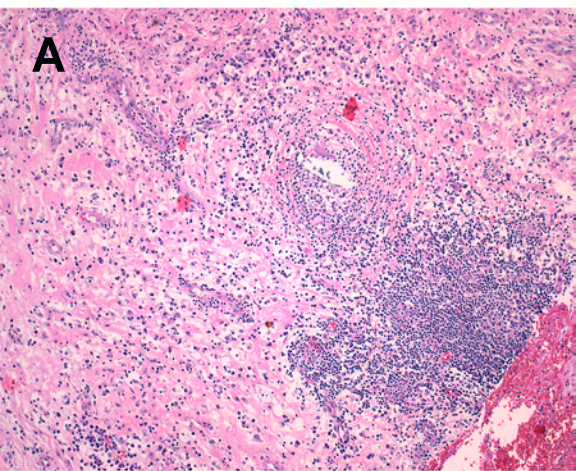


SUPPLEMENTAL DATA

Supplemental Table 1. Summary of hormonal studies and medical therapies.

Supplemental Figure 1. Histopathology of the sphenoidal sinus mass, highlighting a marked lympho-plasmacytic infiltration rich in IgG4-producing cells. A) Sphenoidal sinus H&E, 40X. B) Sphenoidal sinus CD138, 40X. C) Sphenoidal sinus IgG4, 64X.



Supplementary table 1. Summary of hormonal studies and medical therapies.

Date ID	Date	Symptoms	ACTH (9-52 pg/mL)	Cortisol (85-260 ng/mL)	TSH (0.4-3.4 mU/L)	FT4 (7-17 pg/mL)	LH (1.4-12.7 mU/mL)	Testosterone (2.7-10.9 ng/mL)	GH (0.05-5 ng/mL)	IGF-1 (71-290 ng/mL)	PRL (1-13 ng/mL)	Pit Abs	Cortisone acetate (mg/d)	Prednisone (mg/d)	Thyroxine (mcg/d)	DDAVP
1	1/14/2008	headache	7	24	0.22	4	0.3	0.1	0.4	43	2.3	-	-	-	-	-
3	10/16/2008	none										0	-	30	75	yes
4	10/20/2008	none										0	-	30	75	yes
5	11/3/2008	none	6	22	0.26	9.3			0.6	49		0	-	30	75	yes
6	11/17/2008	none										0	-	20	75	yes
7	12/1/2008	none			0.04	7.7		0.3	0.3	43	3.2	0	-	20	75	yes
8	12/15/2008	none										0	-	15	75	yes
9	1/12/2009	headache										0	-	15	75	yes
10	1/26/2009	none			0.01	7.6	0.3		0.3	66	4.8	0	-	10	75	yes
11	3/2/2009	none			0.02	7.7	0.2	0.1	0.39	48	2.3	-	-	5	75	yes
12	4/20/2009	none			0.02	8	0.1		0.5	68		-	37.5	-	75	yes
13	6/22/2009	none	5	24	0.005	7.4	0.3	0.1	0.15	56		-	37.5	-	75	yes
14	10/20/2009	none			0.039	8.4	0.3	0.1	0.27	40	7.5	-	37.5	-	75	yes
15	1/18/2010	none	5	20	0.005	7.5	0.2	0.1	0.22	67	2.1	0	37.5	-	75	no
16	8/7/2010	none	5	11	0.015	9.4	0.5	0.2	0.3	76	0.6	0	37.5	-	75	no