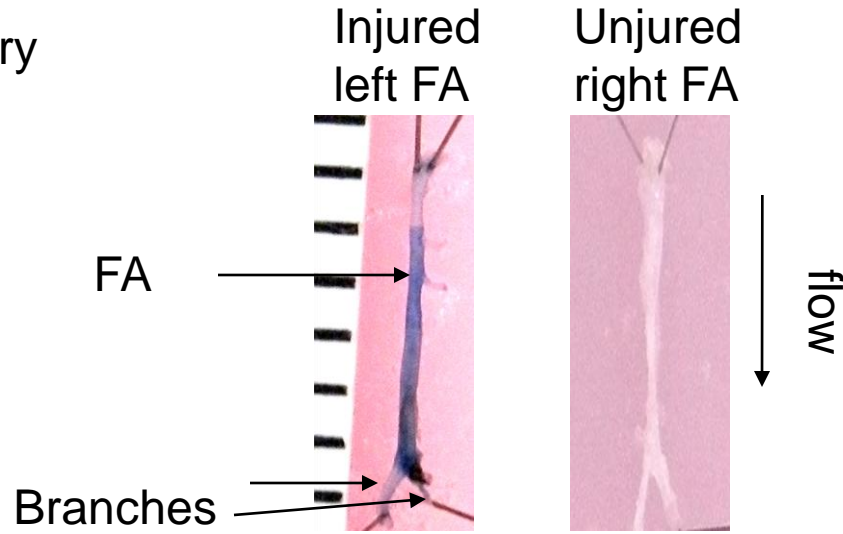



**Figure S1.** Endothelial removal was confirmed by in vivo Evans blue staining

**A. Femoral Artery**



**B. Carotid Artery**



**Fig. S1.**