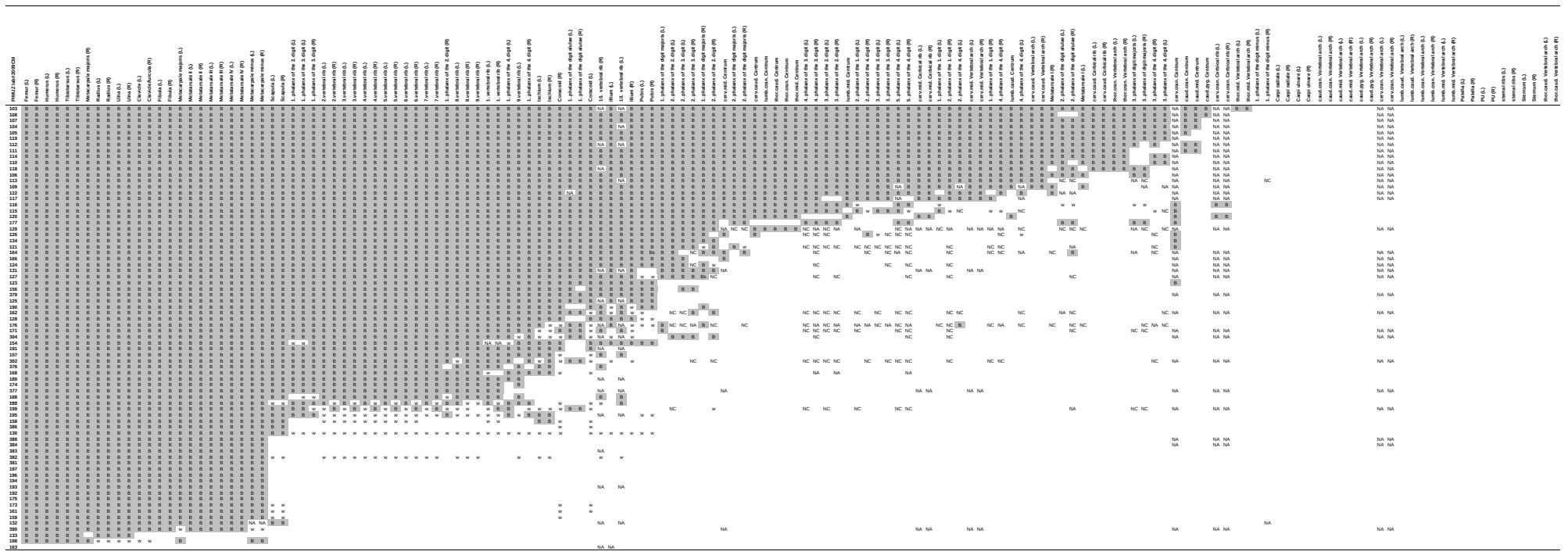
PMU17abin2030CM
Fennur (L)
Fennur (R)
Humerus (L)
Humerus (R)
Tibiotarsus (L)
Tibiotarsus (R)
Metacarpals majoris (L)
Radius (L)
Radius (R)
Ulna (L)
Ulna (R)
Clavicle (L)
Clavicle/furcula (R)
Fibula (L)
Fibula (R)
Metacarpals majoris (L)
Metacarpal II (L)
Metacarpal II (R)
Metatarsal III (L)
Metatarsal III (R)
Metatarsal IV (L)
Metatarsal IV (R)
Metacarpal minus (L)
Metacarpal minus (R)
Scapula (L)
Scapula (R)
1. phalanx of the 2. digit (L)
1. phalanx of the 3. digit (L)
1. phalanx of the 3. digit (R)
2. ventral rib (L)
3. ventral rib (L)
3. ventral rib (R)
4. ventral rib (L)
5. ventral rib (R)
6. ventral rib (R)
7. ventral rib (R)
1. phalanx of the 2. digit (R)
8. ventral rib (L)
9. ventral rib (R)
9. ventral rib (L)
1. ventral rib (L)
1. ventral rib (R)
9. ventral rib (L)
1. phalanx of the 4. digit (L)
1. phalanx of the 4. digit (R)
Ischium (L)
Ischium (R)
Coracoid (R)
1. phalanx of the digit alulae (L)
2. phalanx of the digit alulae (R)
2. phalanx of the digit alulae (L)
Ulna (L)
Ulna (R)
10. ventral rib (R)
Illium (L)
10. ventral rib (L)
Illium (R)
Pubis (L)
Pubis (R)
1. phalanx of the digit majoris (L)
2. phalanx of the 2. digit (L)
2. phalanx of the 3. digit (L)
2. phalanx of the 3. digit (R)
1. phalanx of the 2. digit (R)
2. phalanx of the digit majoris (L)
2. phalanx of the 2. digit (R)
cervical. Centrum
2. phalanx of the digit majoris (R)
cervical. Centrum
cervical. Centrum
thorac. Centrum
thorac. Centrum
thorac. Centrum
4. phalanx of the 3. digit (L)
4. phalanx of the 2. digit (L)
3. phalanx of the 2. digit (L)
3. phalanx of the 2. digit (R)
lumb.sacral. Centrum
2. phalanx of the 4. digit (R)
2. phalanx of the 1. digit (L)
3. phalanx of the 3. digit (R)
5. phalanx of the 4. digit (R)
cervical. Centrum
cervical. Centrum
1. phalanx of the 1. digit (L)
2. phalanx of the 4. digit (L)
2. phalanx of the 1. digit (R)
thorac. Centrum
3. phalanx of the 3. digit (L)
3. phalanx of the 4. digit (R)
cervical. Centrum
cervical. Vertebra/arch (R)
cervical. Vertebra/arch (R)
1. phalanx of the 1. digit (R)
4. phalanx of the 1. digit (R)
lumb.sacral. Centrum
4. phalanx of the 4. digit (L)
cervical. Vertebra/arch (L)
cervical. Vertebra/arch (R)
2. phalanx of the digit alulae (L)
Metatarsal III (R)
2. phalanx of the digit alulae (R)
Metacarpal II (L)
1. phalanx of the digit majoris (R)
cervical. Centrum
cervical. Centrum
sacral.prog. Centrum
cervical. Centrum
cervical. Centrum
cervical. Centrum
thorac. Centrum
3. phalanx of the digit majoris (L)
3. phalanx of the 4. digit (R)
3. phalanx of the 4. digit (L)
cervical. Centrum
cervical. Centrum
cervical. Centrum