

Figure S2

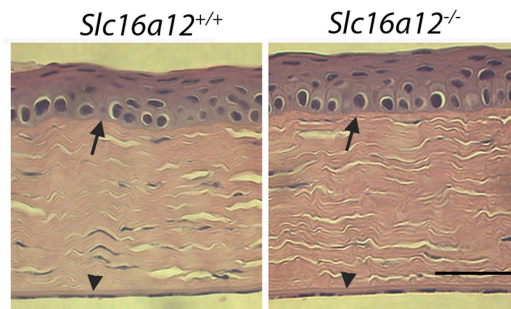


Figure S2. Corneas from *Slc16a12*^{TKO} rats are normal. Hematoxylin and eosin stained sections of the corneas of eyes from *Slc16a12*^{WT} or *Slc16a12*^{TKO} rats, arrow indicates corneal epithelium and arrow head indicates corneal endothelium. Bar = 50 μm.