

## Inhibition by Ginseng of Colon Carcinogenesis in Rats

The inhibitory effects of ginseng on the development of 1,2-dimethylhydrazine (DMH)-induced aberrant crypt foci (ACF) in the colon were investigated in rats. Male, 6-week-old rats were injected with DMH once a week for 4 weeks. Rats in Groups 1 and 2 were fed diets containing red and white ginseng, respectively, at a dose of 1% for 5 weeks, starting one week before the first treatment of DMH. Animals in Groups 3 and 4 received red or white ginseng for 8 weeks starting after DMH treatment. Group 5 served as a carcinogen control group. Numbers of ACF with at least four crypts were significantly reduced in the colon of Group 2 treated with red ginseng combined with DMH. Moreover, rats were injected with DMH 4 times at one-week intervals. They were also fed diets containing 1% red or white ginseng or the control diet throughout 30 days of the experiment. Treatment with red ginseng resulted in a significant decrease of 5-bromo-2'-deoxyuridine labeling indices in colonic crypts comprising ACF. These findings suggest that dietary administration of red ginseng in combination with DMH suppresses colon carcinogenesis in rats, and the inhibition may be associated, in part, with inhibition of cell proliferation, acting on ACF in the colonic mucosa.

Key Words : Ginseng; 1,2-Dimethylhydrazine; Rat Colon Carcinogenesis; Aberrant Crypt Foci

Shoji Fukushima\*, Hideki Wanibuchi, Wei Li

Department of Pathology, Osaka City University  
Medical School, Osaka, Japan

### Address for correspondence

Shoji Fukushima, M.D.

To whom requests for reprints should be  
addressed, at the Department of Pathology\*,  
Osaka City University Medical School, 1-4-3  
Asahi-machi, Abeno-ku, Osaka 545-8585, Japan  
Tel : +81.6-6645-3735, Fax : +81.6-6646-3093  
E-mail : fukuchan@med.osaka-cu.ac.jp

\*The contents of the study was published in *Nutrition  
and Cancer* 2000; 36: 66-73.

## INTRODUCTION

Colon cancer is one of the most common malignancies in many regions of the world (1). Also in Japan, the numbers of cases of colorectal cancer are increasing with the spread of Western dietary habits (2). The idea that this cancer might be a candidate for chemoprevention stems from epidemiological evidence that some factors in the diet may play important roles in its development, whereas others may reduce the risk (3, 4). In animal studies, repeated treatment with a carcinogen, 1,2-dimethylhydrazine (DMH), produces colon tumors in rodents (5, 6). Colon carcinogenesis models using DMH or the related azoxymethane, with putative preneoplastic aberrant crypt foci (ACF) as end-point marker lesions, have been used to assess the influence of modulatory factors (7, 8).

ACF are readily discernible morphological changes within the colonic mucosa of rodents that may contribute to the stepwise progression to colon cancer (9-11). Pretlow and co-workers (12) showed that these lesions are also present in the colonic mucosa of patients with colon cancers and suggested that they are putative precursor lesions from which adenomas and carcinomas may develop. The formation and growth of ACF are associated with induction of colon tumors in rats and are influenced by exposure to chemopreventive agents (13, 14). Natural compounds that inhibit ACF induced by

colon carcinogens have proved to be protective against colon cancer in rodents (13, 15).

Ginseng is believed to have been used in medicinal preparations for about 2000 yr in Oriental countries. Several pharmacological activities have been reported for ginseng extracts or ginseng dammarane saponins (16-19). Each type of ginseng can be ingested in various forms, for example, as fresh slices, juice, extract (tincture or boiled extract), powder, tea, tablet, or capsule (20). Preventive effects of ginseng against cancer development have been observed for many of these, including fresh ginseng extract, white ginseng extract, white ginseng powder, and red ginseng products, but not fresh ginseng slices, fresh ginseng juice, and white ginseng tea (20).

Antitumor effects of ginseng have also been supported by animal studies (21-26). For example, a medium-term (8) model system revealed anti-carcinogenic activity of ginseng regarding pulmonary adenoma induction by benzo[a]pyrene in newborn mice (27). In humans, anticancer influence of ginseng has been documented (20, 28). Although ginseng was found in one study to have a non-organ-specific preventive effect against cancer (29), there are weak negative associations between ginseng intake and cancers of the female breast, uterine cervix, urinary bladder, and thyroid gland. It is also associated with decreased odds ratios for cancers of the lip, oral cavity, pharynx, esophagus, stomach, colorec-

tum, liver, pancreas, larynx, lung, and ovary (20).

In the present study, inhibitory effects of ginseng in a DMH-induced colon carcinogenesis model in rats were assessed, with attention concentrated on quantitative values for pre-neoplastic ACF and cellular proliferative status in terms of 5-bromo-2'-deoxyuridine (BrdU) labeling (30).

## MATERIALS AND METHODS

### Animals

A total of 125 male five-week-old F-344 rats (Charles River, Hino, Shiga, Japan) were housed five per plastic cage with wood chips for bedding in an animal room under standard conditions. Body weight and food intake were measured weekly during the experiment. Diet and water were available ad libitum.

### Chemicals

DMH was purchased from Wako Pure Chemical Industries (Osaka, Japan). White ginseng and red ginseng powders were obtained from Wakunaga Pharmaceutical Co. Ltd. (Hiroshima, Japan), and each was administered at a concentration of 1% in CE-2 basal diet (Clea Japan, Osaka, Japan). Ginseng powders were from the roots of *Panax ginseng* C.A. Meyer cultivated in China.

### Experimental protocols

In Experiment 1, 65 five-week-old rats were divided into eight groups. Animals in Groups 1-5 (10 rats in each group) were given DMH (20 mg/kg body weight, subcutaneous) once a week for 4 weeks. Rats in Groups 6-8 (5 rats each group) were subcutaneously injected with 0.9% saline (vehicle) at the same time. Groups 1 and 2 also received diets containing red and white ginseng, respectively, for 5 weeks, starting one week before the first DMH or saline treatment. Groups 3 and 4 were similarly fed diets containing red and white ginseng after DMH treatment (Weeks 5-12). Group 5 served as a carcinogen-treated control. The animals of Groups 6 and 7 were fed a diet containing red and white

ginseng without DMH, and Group 8 (the vehicle control) received the basal diet alone throughout the experiment period.

In Experiment 2, 60 five-week-old rats were divided into 6 groups of 10 rats each and injected with DMH at 20 mg/kg body wt, sc (Groups 1-3) or saline alone (Groups 4-6) 4 times at one-week intervals (Weeks 1-4). The rats were fed diets containing red ginseng (Groups 1 and 4) and white ginseng (Groups 2 and 5) or the control diet (Groups 3 and 6), respectively, for 30 days, starting one week before the first DMH or saline treatment.

Animals were sacrificed under ether anesthesia at week 12 (Experiment 1) and the second day after the last injection of DMH (Experiment 2), respectively. All 60 rats in Experiment 2 received a single injection of BrdU (Sigma Chemical, St. Louis, MO; 100 mg/kg body wt, ip) one hour before sacrifice. After the colon was stained with 0.2% methylene blue as described previously (30), ACF were examined under a stereomicroscope. After they were counted, the colons were examined for BrdU immunohistochemistry, as described earlier (31).

### Statistical Analysis

Statistical analyses were completed with Stat-View software on a Macintosh computer. The significance of differences between average values for groups was analyzed using Cochran's two-tailed Student's t-test.

## RESULTS

### Experiment 1

All rats survived to the final sacrifice. The body weights of animals given DMH and red or white ginseng were smaller than those treated with DMH alone, and final average body weights of rats in Groups 1-3 were significantly lower than those in the control groups. Among the vehicle-treated animals, the relative liver weights in Group 7 were significantly lower than those in Group 8. Food consumption on a rat-per-cage basis was comparable among the groups.

Animals administered saline (vehicle) and fed the control

Table 1. Effects of Ginseng on DMH-Induced ACF Formation in the Colons of rats: Experiment 1<sup>a,b</sup>

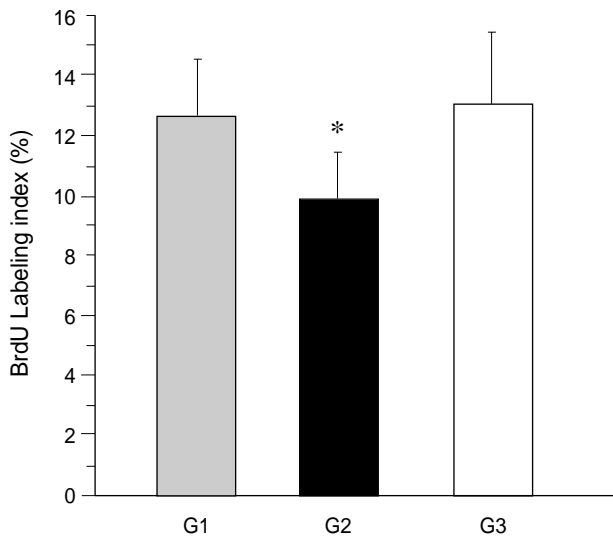
Group No.	No. of rats	Treatment	Total No. of ACF	No. of Foci Containing			
				1 crypt	2 crypts	3 crypts	≥4 crypts
1	10	DMH + WG	282.1 ± 58.5	97.7 ± 34.9	89.3 ± 21.7	55.1 ± 15.0	37.9 ± 24.8
2	10	DMH + RG	177.5 ± 92.3*	56.2 ± 28.2*	70.4 ± 36.5	32.9 ± 24.1*	18.2 ± 10.0*
3	10	DMH → WG	222.7 ± 45.4*	81.6 ± 33.5	76.7 ± 14.6	39.4 ± 8.3**	25.0 ± 11.2
4	10	DMH → RG	292.3 ± 83.6	89.8 ± 24.5	93.2 ± 27.5	64.3 ± 42.7	45.8 ± 31.3
5	10	DMH	305.5 ± 56.0	115.5 ± 42.9	91.1 ± 20.8	61.7 ± 13.2	37.2 ± 13.8

DMH, 1,2-dimethylhydrazine; WG, white ginseng; RG, red ginseng; ACF, aberrant crypt foci. <sup>a</sup>: Values are means ± SD; n: number of rats, <sup>b</sup>: Statistical significance is as follows: \*,  $p < 0.01$ ; \*\*,  $p > 0.001$  vs. Group 5.

**Table 2.** Effects of Ginseng on DMH-Induced ACF Formation in the Colons of Rats: Experiment 2<sup>a,b</sup>

Group No.	Treatment	No. of rats	Total No. of ACF	No. of Foci Containing			
				1 crypt	2 crypts	3 crypts	≥ 4 crypts
1	DMH + WG	10	111.0 ± 22.9	101.4 ± 23.1	8.2 ± 4.4	0.3 ± 0.5	0.1 ± 0.3
2	DMH + RG	10	63.2 ± 19.3*	56.7 ± 16.3*	6.0 ± 4.2*	0.6 ± 0.7	0
3	DMH	10	169.6 ± 80.2	149.5 ± 75.2	13 ± 5.5	0.5 ± 0.7	0.1 ± 0.3

DMH, 1,2-dimethylhydrazine; WG, white ginseng; RG, red ginseng; ACF, aberrant crypt foci. <sup>a</sup>: Values are means ± SD; <sup>b</sup>: Statistical significance is as follows; \*,  $p < 0.01$  vs. Group 3.



**Fig. 1.** 5-Bromo-2'-deoxyuridine labeling indices in colonic mucosal crypts within aberrant crypt foci (ACF) in rats fed ginseng or basal diet (Experiment 2) , DMH+white ginseng (Group 1); , DMH+red ginseng (Group 2); , DMH (Group 3); \*,  $p < 0.05$  vs. Group 3.

and experimental diets containing red or white ginseng lacked any ACF in the colon (data not shown). Table 1 summarizes data for DMH-induced ACF in the colons of rats fed the control and experimental diets (Groups 1-5). Administration of red or white ginseng in the diet (Groups 2 and 3) significantly suppressed the total number of ACF per colon compared with the control diet (Group 5). Particularly in animals fed red ginseng during initiation (Group 2), there was a significant reduction in the number of large ACF containing at least four crypts per focus, which have been reported to be more likely to develop into tumors (14). Numbers of foci containing three crypts were also significantly decreased by feeding white ginseng after DMH administration (Group 3). The distribution and frequency of ACF in Groups 1-5 were predominantly observed in the distal colon. Group 2 demonstrated a significantly lowered occurrence of ACF in all regions of the colon.

## Experiment 2

Exposure to red ginseng (Group 2) relative to the control (Group 3) significantly reduced the formation of ACF (Table

2). Rats administered saline (Groups 4-6) had no ACF in the colon (data not shown). Crypts containing ACF had more BrdU-labeled cells than normal-appearing crypts. Crypts containing ACF in animals fed red ginseng had fewer BrdU-labeled cells than those of animals fed the basal diet. As shown in Fig. 1, the BrdU labeling index was significantly suppressed within ACF in the animals (Group 2) fed the diet with red ginseng. The inhibition was evident along the length of the colon.

## DISCUSSION

The present study was undertaken to evaluate red or white ginseng for potential inhibition of ACF formation in the colon, putative preneoplastic lesions (10-12). The results indicate that dietary red ginseng powder exposure during the initiation phase exerts significant inhibition potential.

The colon tumor incidence in rats correlates best with numbers of large ACF ( $\geq 4$  crypts/focus), which are more likely to persist, increase in size through multiplication (9, 11), and develop into tumors (14). Large ACF are also linked with colon cancer development from the viewpoint of dysplastic change (10, 11), altered proliferative pattern (11), K-ras mutations (32), and DNA adduct formation (33). Therefore, the finding of significant reduction of large ACF ( $\leq 4$  crypts/focus) might point to an effect on tumor yield. Although this requires confirmation in a long-term experiment, the results provide support for human intervention trials of red ginseng as a cancer-chemopreventive agent.

Ginseng has potent cancer-chemopreventive effects in humans (20, 23, 24, 28). Epidemiological studies have shown that the odds ratios of ginseng consumers are decreased with all kinds of cancers in case-control studies (20, 28). Recently, a prospective study to evaluate the preventive effect of ginseng against lung cancer in humans also revealed a reduced risk with ginseng intake, adjusted for smoking, with no cancer death among 24 red ginseng consumers (29). In the present study, significant decrease of the number of large ACF was not observed in animals given white ginseng powder, although total colonic ACF were reduced (Experiment 1). Therefore, the present study indicated that white ginseng is not as effective as red ginseng at inhibiting DMH-induction of ACF development in the rat colon.

Concerning the effects of red ginseng, Yun and co-workers

(21) carried out extensive animal experiments to investigate whether ginseng inhibited carcinogenesis. They reported that oral administration of red ginseng extract inhibited the incidence and the proliferation of lung tumours induced by various chemical carcinogens in mice. It was considered that the anticarcinogenic mechanism partly involved elevation of natural killer cell activity (34, 35). Matsuda and colleagues (36, 37) reported that red ginseng inhibited formation of pulmonary metastases after infusion of tumor cells into rats and that combined with mitomycin C showed a stronger antitumor effect, with enhanced in vitro cytotoxicity, than the same combination with white ginseng. Moreover, it has been reported that the ability of red ginseng saponins to inhibit lung metastasis of tumor cells in mice is related to inhibition of adhesion and invasion of tumor cells and also to antiangiogenesis (23). In terms of the effect of ginseng on body weight of rats, Table 1 shows no toxic effect of red or white ginseng in the control Groups 6 or 7 compared with Group 8 in Experiments 1 and 2. However, a significant decrease in body weight was noted in Groups 1-3 in Experiment 1 and Group 2 in Experiment 2. The decrease in body weight was seen only in groups treated with DMH simultaneously with or before ginseng administration. A possible synergistic effect of ginseng with DMH metabolites could affect body weight; therefore, the body weight loss in the present experiment could be a DMH-specific phenomenon.

Ginseng is classified into three types depending on how it is processed: fresh ginseng, white ginseng, and red ginseng. White ginseng is four to six yr old and dried after peeling; red ginseng is harvested when it is six yr old and then steamed and dried. The major active components of ginseng are 20(s)-protopanaxadiol and 20(s)-protopanaxatriol saponins. The specific properties of saponin components of white and red ginseng preparations have been reported (23, 38, 39). Considered to be the major active components (40), saponins have been reported to have antimutagenic activity, inhibit tumor angiogenesis and metastasis (23, 41), reduce growth of several tumor cell lines (42) and human ovarian cancers in nude mice (25, 26), and exert immunomodulating potential (43, 44). The chemical properties and biological effects of triterpenoid saponin components (ginsenosides) have been widely studied (23, 39, 45, 46). Although red ginseng contains other tumor growth-inhibitory substances (47), many investigators have shown that ginsenosides suppress tumor growth and inhibit tumor metastasis (23, 24, 48). Karikura and associates (49, 50) described five and six decomposition products of ginsenoside Rb1 and ginsenoside Rb2, respectively, in the rat large intestine after oral administration. It is not known, however, which component of red ginseng has the most profound effect on cancer, and clearly studies focused on this question are of high priority.

Modulation of cell proliferation in ACF and colon epithelial cells has been proposed as a mechanism whereby agents

impact on colon cancer (51, 52). BrdU is a good parameter for evaluating cell proliferation, because only S phase cells are labeled, although care in its use is necessary, since BrdU has been classified as a potential carcinogen (53). It should be stressed that the inhibition of cell proliferation, as monitored by BrdU LIs, clearly correlates with suppression of ACF development by several chemopreventive agents (54, 55). In the present study, red ginseng reduced the BrdU labeling index of crypt cells. Whether this is the only mechanism underlying red ginseng actions in our model, however, remains to be determined.

It is noteworthy in this context that red ginseng was effective for inhibition of ACF development during the initiation, but not the promotion, phase. Reduction of ACF number and multiplicity, as well as the relation of cancer chemoprevention in general to the initiation phase of carcinogenesis, has been discussed in detail (14, 56). Belleli and others (57) showed a 50% decrease in the number of colon tumors in rats receiving 1, 25-(OH)<sub>2</sub> vitamin D<sub>3</sub> before carcinogen administration but found that the same treatment during the initiation or postinitiation phase did not change the tumor incidence. Previously, Wattenberg (58) classified carcinogenesis inhibitors according to the phase in which they show inhibitory effects in animal models of carcinogenesis: 1) inhibitors of the formation of the active carcinogen itself, 2) blocking agents, which block the carcinogen at the initiation phase, preventing it from reaching or reacting with target sites, and 3) suppressing agents, which suppress the formation of neoplasia when administered in the postinitiation phase. In our model the formation of ACF was inhibited in rats receiving red ginseng before carcinogen administration and in the initiation phase, suggesting that the agent might influence the formation of active DMH itself and act as a blocking agent. Metabolic studies are necessary to assess whether this is indeed the case.

## ACKNOWLEDGEMENTS AND NOTES

The authors thank Wakunaga Pharmaceutical Co. Ltd., Hiroshima, Japan for supply and advice concerning ginseng. This work was supported by a grant-in-aid for cancer research from the Ministry of Health and Welfare of Japan.

## REFERENCES

1. Shike M, Winawer SJ, Greenwald PH, Bloch A, Hill MJ, Swaroop SV. *Primary prevention of colorectal cancer: the WHO Collaborating Centre for Prevention of Colorectal Cancer. Bull World Hlth Org 1990; 68: 377-85.*
2. Tajima K, Hirose K, Nakagawa N, Kuroishi T, Tominaga S. *Urban-rural difference in the trend of colorectal cancer mortality with special reference to the subsites of colon cancer in Japan. Jpn J Cancer*

- Res* 1985; 76: 717-28.
3. Potter JD, McMichael AJ. *Diet and cancer of the colon and rectum: a case-control study.* *J Natl Cancer Inst* 1986; 76: 557-69.
  4. Mukhtar H, Athor M. *Dietary anticarcinogens and cancer prevention.* *Cleavel Clin J Med* 1988; 55: 507-8.
  5. Pozharisski KM, Likhachev AJ, Klimashevski VF, Shaposhnikov JD. *Experimental intestinal cancer research with special reference to human pathology.* *Adv Cancer Res* 1979; 30: 165-237.
  6. Druckrey E. *Organ-specific carcinogenesis in the digestive tract.* In: *Topics in Chemical Carcinogenesis*, Nakahara W, Takayama S, Sugimura T, Odashima S, editors, Baltimore Maryland: University Park Press, 1972; 73-101.
  7. Bird RP. *Role of ACF in understanding the pathogenesis of colon cancer.* *Cancer Lett* 1995; 93: 55-71.
  8. McLellan EA, Bird RP. *Aberrant crypts: potential preneoplastic lesions in the murine colon.* *Cancer Res* 1988; 48: 6187-92.
  9. McLellan EA, Medline A, Bird RP. *Dose response and proliferative characteristics of aberrant crypt foci: putative preneoplastic lesions in rat colon.* *Carcinogenesis* 1991; 12: 2093-8.
  10. McLellan EA, Bird RP. *Aberrant crypts: potential preneoplastic lesions in the murine colon.* *Cancer Res* 1988; 48: 6187-92.
  11. McLellan EA, Medline A, Bird RP. *Sequential analyses of the growth and morphological characteristics of aberrant crypt foci: putative preneoplastic lesions.* *Cancer Res* 1991; 51: 5270-4.
  12. Pretlow TP, O'Riordan MA, Pretlow TG, Stellato TA. *Aberrant crypts in human colonic mucosa: putative preneoplastic lesions.* *J Cell Biochem* 1992; 16G (Suppl): 55-62.
  13. Pereira MA, Barnes LH, Rassman VL, Kolloff GV, Steele VE. *Use of azoxymethane-induced foci of aberrant crypts in rat colon to identify potential cancer chemopreventive agents.* *Carcinogenesis* 1994; 15: 1049-54.
  14. Pretlow TP, O'Riordan MA, Somich GA, Amini SB, Pretlow TG. *Aberrant crypts correlate with tumor incidence in F344 rats treated with azoxymethane and phytate.* *Carcinogenesis* 1992; 13: 1509-12.
  15. Tanaka T, Mori H. *Inhibition of colon carcinogenesis by non-nutritive constituents in foods.* *J Toxicol Pathol* 1996; 9: 139-49.
  16. Tanaka O, Kasai R. *Saponins of ginseng and related plants.* In: *Progress in the Chemistry of Organic Natural Products*, Herz W, Griesebach H, Kirby GW, Tamm C, editors, New York: Springer-Verlag 46, 1984; 1-76.
  17. Shibata S, Tanaka O, Shoji J, Saito H. *Chemistry and pharmacology of panax.* In: *Economic and Medicinal Plant Research*, Wagner H, Hikino H, Farnsworth NR, editors, Tokyo: Academic Press, 1985; 218-84.
  18. Tanaka O. *Saponin composition of Panax species.* In: *Recent Advances in Ginseng Studies*, Shibata S, Ohtsuka T, Saito H, editors, Tokyo: Hirokawa Publishing Co., 1990; 43-8.
  19. Bhattacharya, SK, Mitra SK. *Anxiolytic activity of Panax ginseng roots: an experimental study.* *J Ethnopharmacol* 1991; 34: 87-92.
  20. Yun TK, Choi SY. *Preventive effect of ginseng intake against various human cancers: a case-control study on 1987 pairs.* *Cancer Epidemiol Biomarkers & Prev* 1995; 4: 401-8.
  21. Yun TK, Yun YS, Han IW. *Anticarcinogenic effect of long-term oral administration of red ginseng on newborn mice exposed to various chemical carcinogens.* *Cancer Detect Prev* 1983; 6: 515-25.
  22. Xiaoguang C, Hongyan L, Xiaohong L, Zhaodi F, Yan L, Lihua T, Rui H. *Cancer chemopreventive and therapeutic activities of red ginseng.* *J Ethnopharmacol* 1998; 60: 71-8.
  23. Mochizuki M, Yoo YC, Matsuzawa K, Sato K, Saiki I, Tono-Oka S, Samukawa K, Azuma I. *Inhibitory effects on tumor metastasis in mice by saponins, ginsenoside-Rb2, 20(R)-and 20(S)-ginsenoside-Rg3, of red ginseng.* *Biol Pharm Bull* 1995; 18: 1197-202.
  24. Sato K, Mochizuki M, Saiki I, Yoo YC, Samukawa K, Azuma I. *Inhibition of tumor angiogenesis and metastasis by a saponin of panax ginseng, ginsenoside-Rb2.* *Biol Pharm Bull* 1994; 17: 635-9.
  25. Tode T, Kikuchi Y, Kita T, Hirata J, Imaizumi E, Nagata I. *Inhibitory effects by oral administration of ginsenoside Rh2 on the growth of human ovarian cancer cells in nude mice.* *J Cancer Res Clin Oncol* 1993; 120: 24-6.
  26. Nakata H, Kikuchi Y, Tote T, Hirata J, Kita T, Ishii K, Kudoh K, Nagata I, Shinomiya N. *Inhibitory effects of ginsenoside Rh2 on tumor growth in nude mice bearing human ovarian cancer cells.* *Jpn J Cancer Res* 1998; 89: 733-40.
  27. Yun TK, Kim SH, Lee YS. *Trial of a new medium-term model using benzo(a)pyrene induced lung tumor in newborn mice.* *Anticancer Res* 1995; 15: 839-45.
  28. Yun TK, Choi SY. *A case-control study of ginseng intake and cancer.* *Int J Epidemiol* 1990; 19: 871-6.
  29. Yun TK, Choi SY. *Non-organ specific cancer prevention of ginseng: a prospective study in Korea.* *Int J Epidemiol* 1998; 27: 359-64.
  30. Li W, Wanibuchi H, Salim EI, Wei M, Yamamoto S, Nishino H, Fukushima S. *Inhibition by ginseng of 1,2-dimethylhydrazine induction of aberrant crypt foci in the rat colon.* *Nutr Cancer* 2000; 36: 66-73.
  31. Hsu SM, Raine L, Fager H. *Use of avidin-biotin-peroxidase complex (ABC) in immunoperoxidase techniques: a comparison between ABC and unlabeled antibody (PAP) procedures.* *J Histochem Cytochem* 1981; 29: 577-80.
  32. Shivapurkar N, Tang Z, Ferreira A, Nasim S, Garrett C, Alabaster O. *Sequential analysis of K-ras mutations in aberrant crypt foci and colonic tumors induced by azoxymethane in F344 rats on high-risk diet.* *Carcinogenesis* 1994; 15: 775-8.
  33. Qin X, Zarkovic M, Nakatsuru Y, Arai M, Oda H, Ishikawa T. *DNA adduct formation and assessment of aberrant crypt foci in vivo in the rat colon mucosa after treatment with N-methyl-N-nitrosourea.* *Carcinogenesis* 1994; 15: 851-5.
  34. Yun TK, Kim SH. *Inhibition of development of benzo(a)pyrene-induced mouse pulmonary adenoma by several natural products in a medium-term bioassay system.* *J Korean Cancer Assoc* 1988; 20: 133-42.
  35. Yun YS, Moon HS, Oh YR, Jo SK, Kim YG, Yun TK. *Effect of red ginseng on natural killer cell activity in mice with lung adenoma induced by urethan and benzo(a)pyrene.* *Cancer Detect Prev* 1987; 1(suppl): 301-9.
  36. Matsuda H, Tong CN, Kubo M. *Pharmacological study on Panax ginseng C.A. MEYER. XIV. Effect of 70% methanolic extract from red ginseng on the cytotoxic effect of mitomycin C against rat ascites hepatoma AH 130.* *Yakugaku Zasshi (Jap)* 1992; 112: 846-55.

37. Tong CN, Matsuda H, Kubo M. *Pharmacological study on Panax ginseng C.A. MEYER. XIV. Effect of 70% methanolic extract from red and white ginseng on the antitumor activity of mitomycin C. Yakugaku Zasshi (Jap) 1992; 112: 856-65.*
38. Kitagawa I, Yoshihara M, Yoshihara M, Hayashi T, Taniyama T. *Chemical studies of crude drugs (1). Constituents of Ginseng radix rubra. Yakugaku Zasshi (Jap) 1983; 103: 612-22.*
39. Liu CX, Xiao PG. *Recent advances on ginseng in China. J Ethnopharmacol 1992; 36: 27-38.*
40. Ota T, Maeda M, Odashima S. *Mechanism of action of ginsenoside Rh 2: uptake and metabolism of ginsenoside Rh 2 by cultured B16 melanoma cells. J Pharm Sci 1991; 80: 1141-6.*
41. Umnova NV, Michurina TL, Smirnova NI, Aleksandrova IV, Poroshenko GG. *Study of antimutagenic properties of Bio-ginseng in mammalian cells in vitro and vivo. Bull Exp Biol Med 1991; 111: 507-9.*
42. Matsunaga H, Katano M, Yamamoto H, Mori M, Takat K. *Studies on the panaxtriol of Panax ginseng C.A. Meyer. isolation, determination and antitumor activity. Chem Pharm Bull 1989; 37: 1279-81.*
43. Kenarova B, Neychev H, Hadjiivanova C, Petkov VP. *Immunomodulating activity of ginsenoside Rg1 from Panax ginseng. Jpn J Pharmacol 1990; 54: 447-54.*
44. Kim JY, Germolec DR, Luster MI. *Panax ginseng as a potential immunomodulator: studies in mice. Immunopharmacol Immunotoxicol 1990; 12: 257-76.*
45. Jeong TC, Kim HJ, Park JI, Ha CS, Park JD, Kim SI, Roh JK. *Protective effects of red ginseng saponins against carbon tetrachloride-induced hepatotoxicity in Sprague Dawley rats. Planta Med 1997; 63: 136-40.*
46. Ota T, Fujikawa-Yamamoto K, Zong ZP, Yamazaki M, Odashima S, Kitagawa I, Abe H, Arichi S. *Plant-glycoside modulation of cell surface related to control of differentiation in cultured B16 melanoma cells. Cancer Res 1987; 47: 3863-7.*
47. Matsunaga H, Katano M, Yamamoto H, Mori M, Takata K. *Determination of panaxytriol, a new type of tumour growth inhibitor from Panax ginseng, by capillary gas chromatography. J Chromatogr 1989; 481: 368-72.*
48. Kikuchi Y, Sasa H, Kita T, Hirata T, Tode T, Nagata I. *Inhibition of human ovarian cancer cell proliferation in vitro by ginsenoside Rh 2 and adjuvant effects to cisplatin in vivo. Anti-cancer Drugs 1991; 2: 63-7.*
49. Karikura M, Miyase T, Tanizawa H, Takino Y, Taniyama T, Hayashi T. *Studies on absorption, distribution, excretion and metabolism of ginseng saponins. V. The decomposition products of ginsenoside Rb 2 in the large intestine of rats. Chem Pharm Bull Tokyo 1990; 38: 2859-61.*
50. Karikura M, Miyase T, Tanizawa H, Taniyama T, Takino Y. *Studies on absorption, distribution, excretion and metabolism of ginseng saponins. VII. Comparison of the decomposition modes of ginsenoside-Rb 1 and -Rb 2 in the digestive tract of rats. Chem Pharm Bull Tokyo 1991; 39: 2357-61.*
51. Tanaka T, Kawabata K, Kakumoto M, Makita H, Hara A, Mori H, Satoh K, Hara A, Murakami A, Kuki W, Takahashi Y, Yonei H, Koshimizu K, Ohigashi H. *Citrus auraptene inhibits chemically induced colonic aberrant crypt foci in male F344 rats. Carcinogenesis 1997; 18: 2155-61.*
52. Barsoum GH, Hendrickse C, Winslet MC, Youngs D, Donovan IA, Neoptolemos JP, Keighley MR. *Reduction of mucosal crypt cell proliferation in patients with colorectal adenomatous polyps by dietary calcium supplementation. Br J Surg 1992; 79: 581-3.*
53. Coltrera MD, Gown AM. *PCNA/cyclin expression and BrdU uptake define different subpopulations in different cell lines. J Histochem Cytochem 1991; 39: 23-30.*
54. Kawamori T, Tanaka T, Ohnishi M, Hirose Y, Nakamura Y, Satoh K, Hara A, Mori H. *Chemoprevention of azoxymethane-induced colon carcinogenesis by dietary feeding of S-methyl methane thio-sulfonate in male F344 rats. Cancer Res 1995; 55: 4053-8.*
55. Tanaka T, Kawamori T, Ohnishi M, Makita H, Mori H, Satoh K, Hara A. *Suppression of azoxymethane-induced rat colon carcinogenesis by dietary administration of naturally occurring xanthophylls astaxanthin and canthaxanthin during the postinitiation phase. Carcinogenesis 1995; 16: 2957-63.*
56. Kawamori T, Tanaka T, Suzuki M, Okamoto K, Tamai Y, Torihara M, Yamahara J, Mori H. *Chemoprevention of azoxymethane-induced intestinal carcinogenesis by a novel synthesized retinoidal butenolide, 5-hydroxy-4-(2-phenyl-(E)-ethenyl)-2 (5H)-furanone, in the rat. Carcinogenesis 1995; 16: 795-800.*
57. Belleli A, Shany S, Levy J, Guberman R, Lamprecht SA. *A protective role of 1, 25-dihydroxyvitamin D3 in chemically induced rat colon carcinogenesis. Carcinogenesis 1992; 13: 2293-8.*
58. Wattenberg LW. *Chemoprevention of cancer. Cancer Res 1985; 45: 1-8.*