

F_1/I *kras*^{V12} transgenic zebrafish

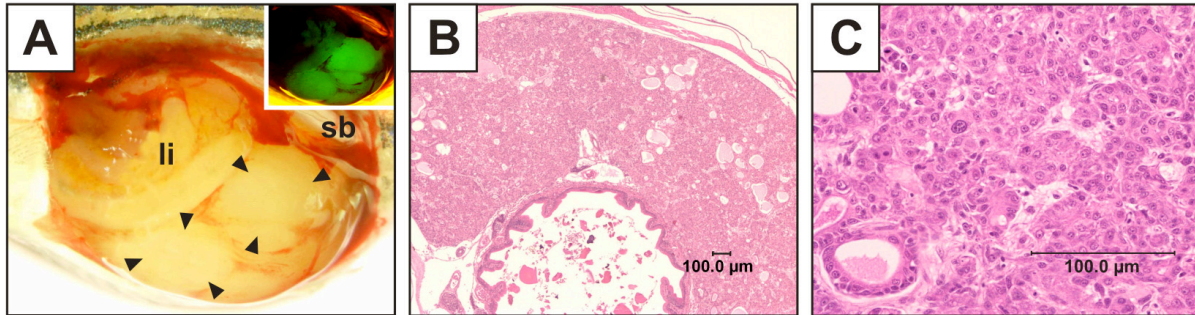


Fig. S2. Morphological and histological examination of liver tumor of F_1/I transgenic fish. (A) Liver from transgenic male fish of line F_1/I (84 dpf) displaying macroscopic tanned nodules. (B,C) Histological observations confirmed mixed carcinoma with hepatocellular component grade III.