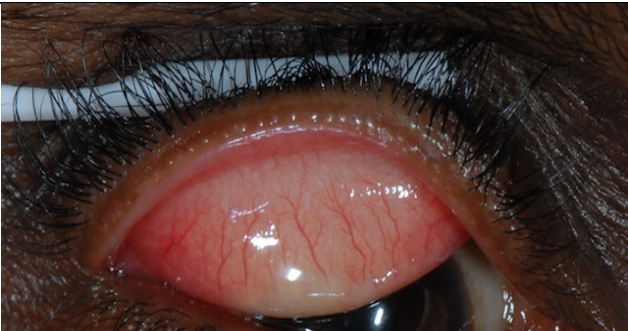




Supplemental Figure S2: Conjunctivalisation: anterioplacement of the muco-cutaneous junction of the upper eyelid

Sign	Definition	
0	None. The muco-cutaneous junction is posterior to the line of meibomian gland orifices, which clearly lie within the lid margin skin.	
1	Muco-cutaneous junction is located anterior to its normal position; the junction is very close to meibomian gland orifices, which lie just within lid margin skin.	
2	The muco-cutaneous junction is located anterior to the line of the meibomian gland orifices for <50% lid (in this picture temporal orifices are enveloped in conjunctival epithelium)	
3	The muco-cutaneous junction is located anterior to the line of the meibomian gland orifices for >50% lid (in this picture all central orifices are enveloped in conjunctival epithelium)	