

Annex
Patient 1

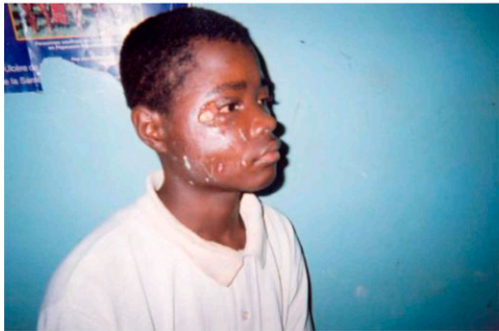

Figure 1. Mixed disseminated ulcerated form (Admission, 27/10/2003)

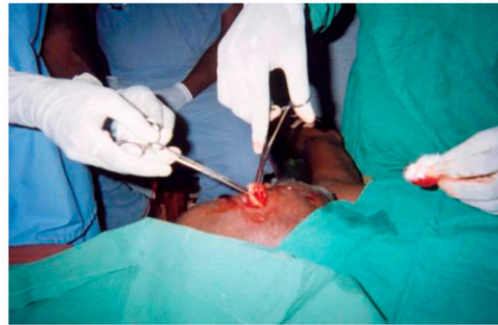

Figure 2. Sequestrectomy (week 1)

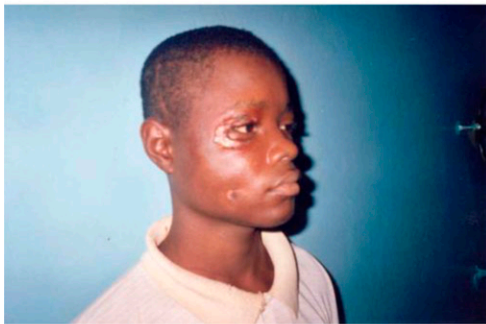


Figure 3. Healing – hospital discharge after 80 days of treatment (surgery without antibiotics)

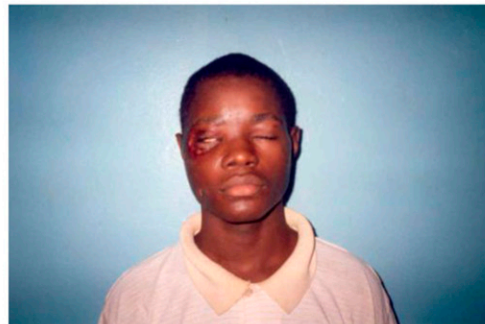

Figure 4. Lid gap on right eye after plastic surgery




Figure 5. Follow-up, 4 years after hospital discharge




Figure 6. Complete right eye closure (result of exercises, lubrication and massage at home)

Patient 2

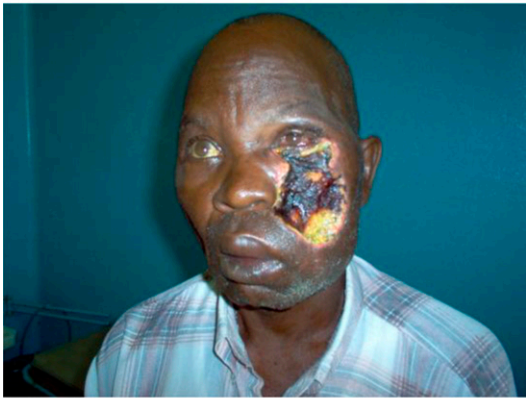

Figure 1. Large disfiguring BU (admission, 25/02/2004)

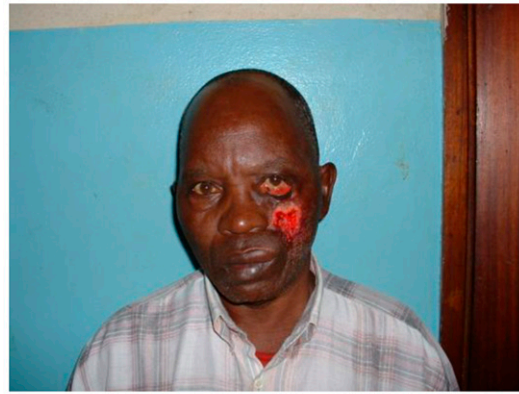

Figure 2. Healing with retractile scar causing tarsal conjunctiva exposure and mouth deviation (68 days of treatment, surgery without antibiotics)

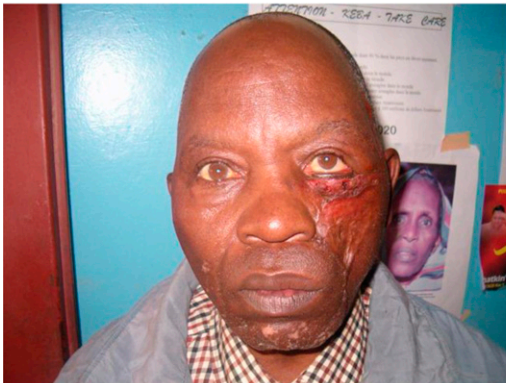

Figure 3. Plastic surgery 2 years after hospital discharge

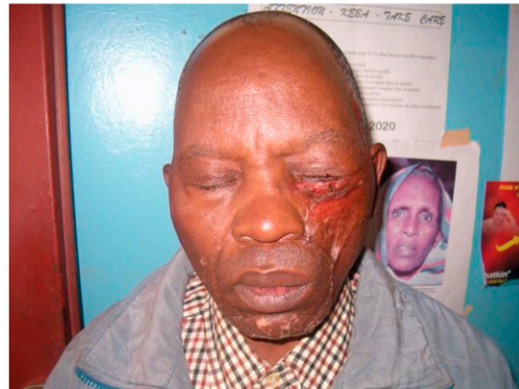

Figure 4. Complete eye closure obtained after plastic surgery

Patient 3

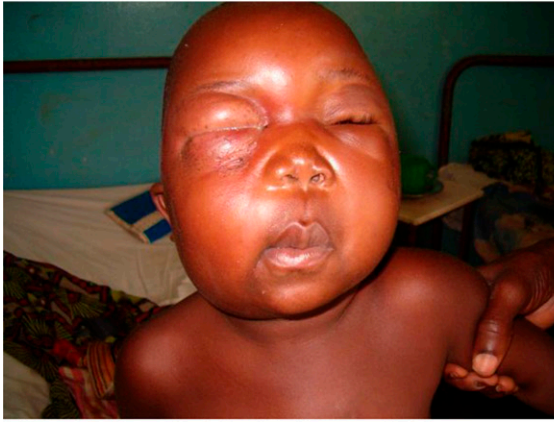

Figure 1. Periorbital advanced edematous lesion on right eye with early extension on left side (admission, 07/02/2005)

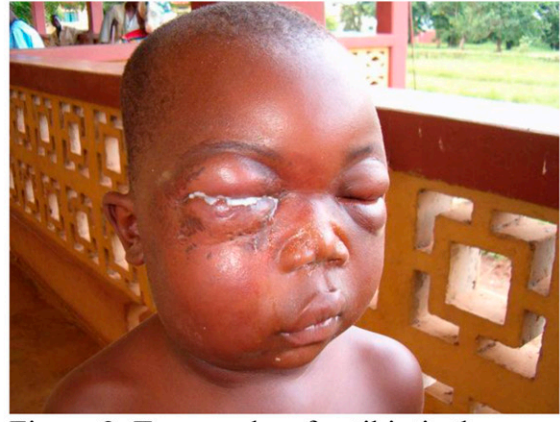

Figure 2. Two weeks of antibiotic therapy (rifampin and streptomycin)

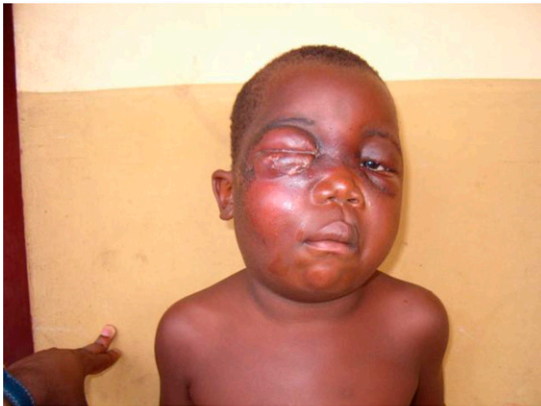

Figure 3. Reduction of left eyelids edema after one month antibiotic therapy

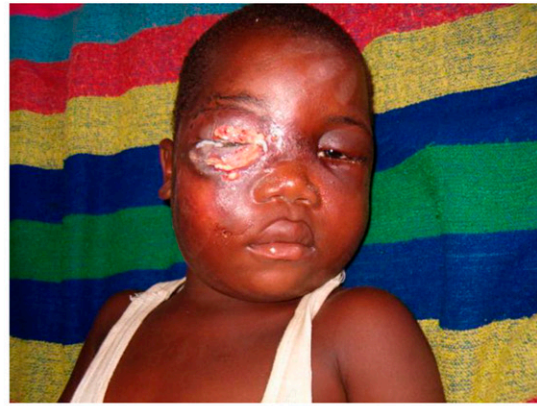

Figure 4. Ulceration of right eyelids (6 weeks of antibiotic therapy)

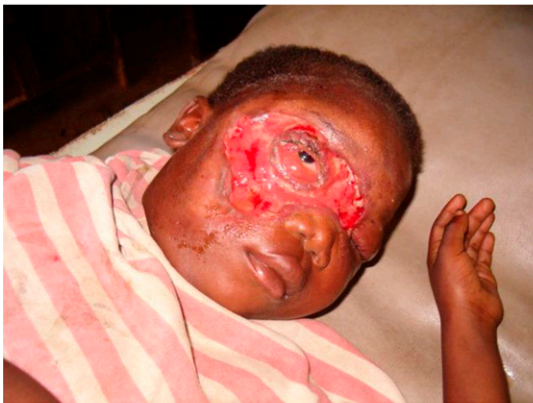

Figure 5. Cleaned wound (1 week of daily wound dressings after debridement at day 46 of antibiotics)

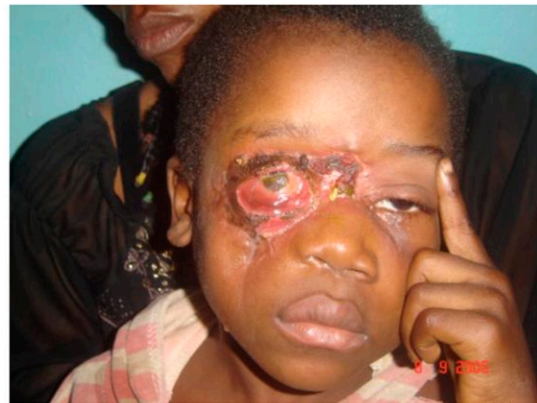

Figure 6. Healing – hospital discharge with loss of the sight in the right eye (213 days of treatment)

Patient 4

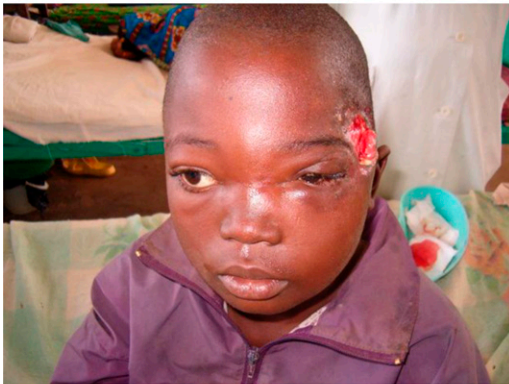

Figure 1. Extended edematous ulcerated lesion of the left side of the face (admission, 06/05/2005)

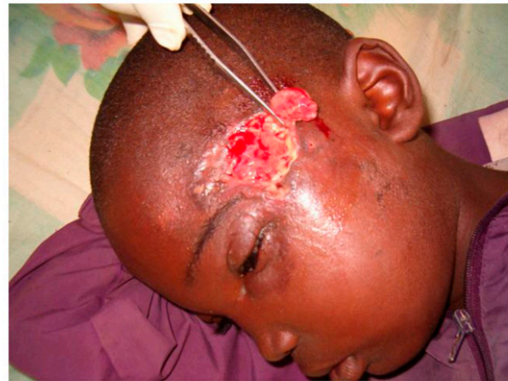

Figure 2. Mixed ulcerated lesion (admission, 06/05/2005)

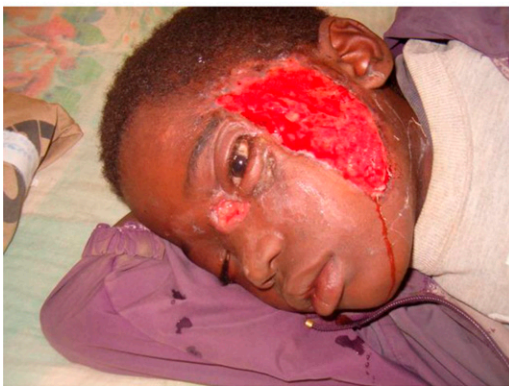

Figure 3. Cleaned wound after the end of antibiotic therapy combined with surgery (first debridement after 3 days of antibiotics) and daily wound dressings

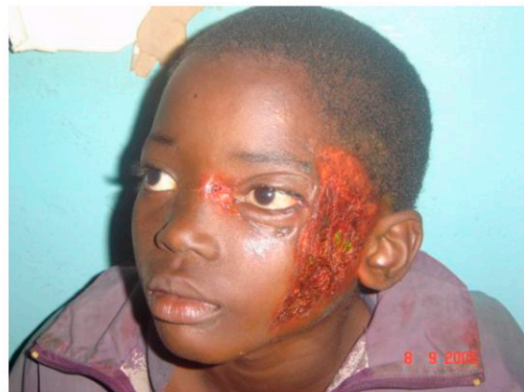

Figure 4. Healing – hospital discharge after 125 days of treatment

Patient 5

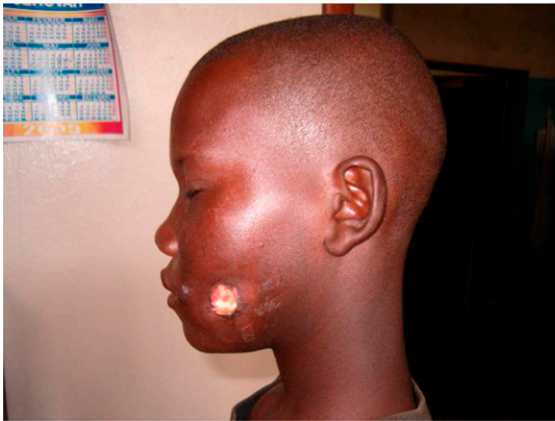


Figure 1. Typical BU on the left cheek (admission, 11/05/2005)

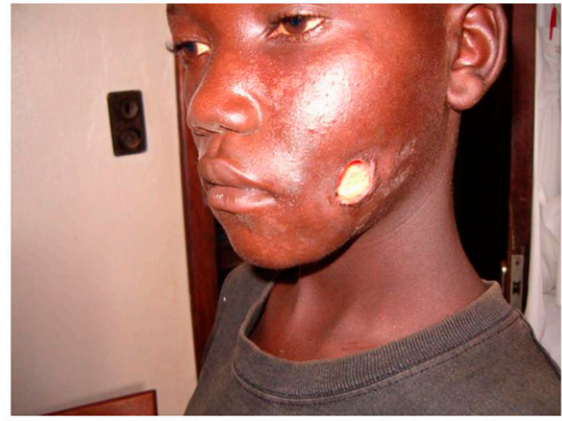

Figure 2. Typical BU on the left cheek (admission, 11/05/2005)

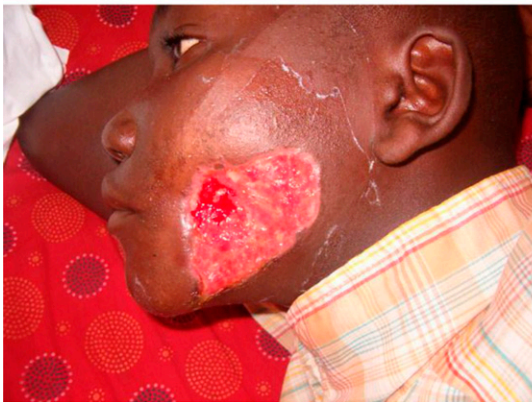

Figure 3. Cleaned wound after 2 excisions (first debridement 11 days after antibiotic therapy) combined with antibiotic therapy and daily wound dressings (106 days of treatment)

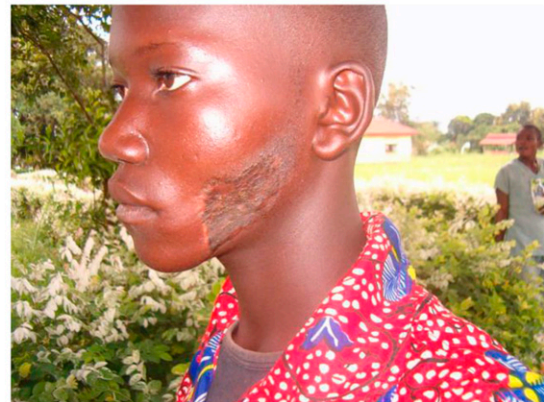


Figure 4. Follow-up 9 months after hospital discharge

Patient 6

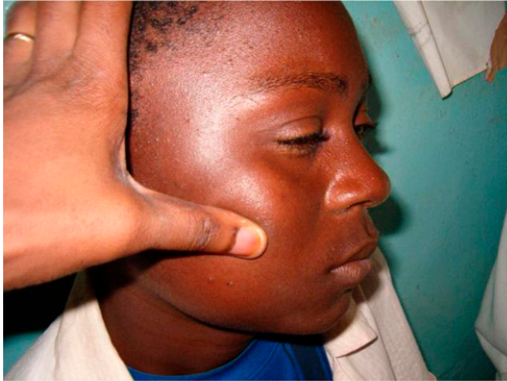


Figure 1. Nodule on the right cheek (admission, 16/06/2005)

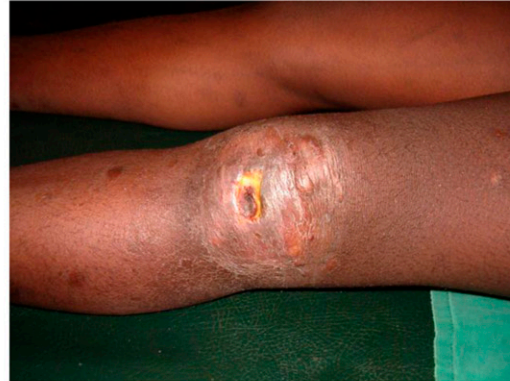

Figure 2. Plaque with early ulceration (mixed disseminated BU)

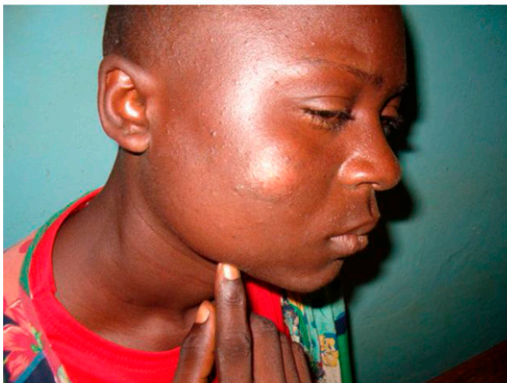


Figure 3. Week 2 of antibiotic therapy

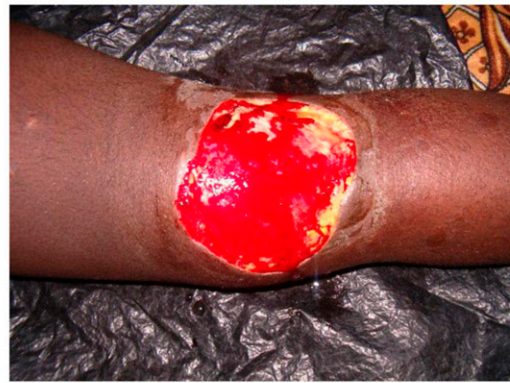

Figure 4. Wound after plaque excision performed after 25 days of antibiotics

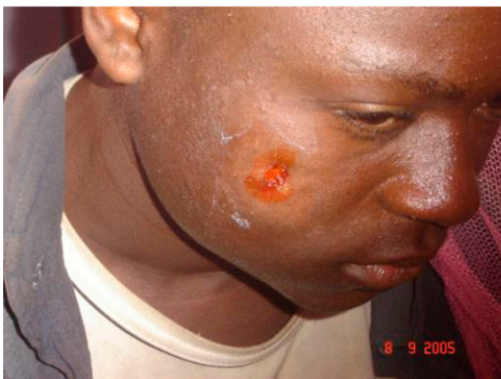

Figure 5. Healing after minimal debridement combined with antibiotic therapy

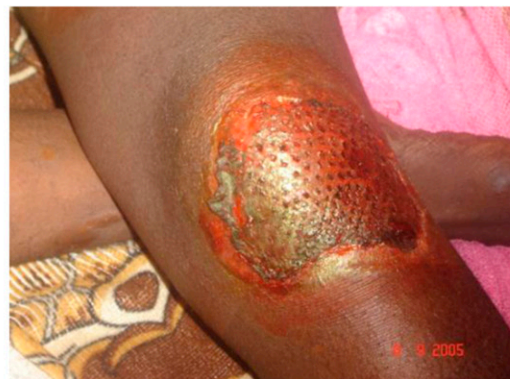

Figure 6. Healing after skin graft (84 days)

Patient 7

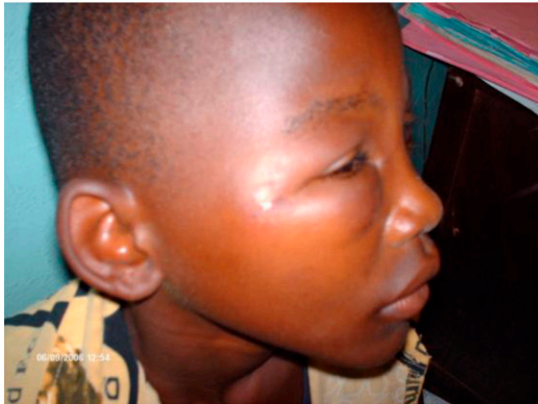

Figure 1. Periorbital edematous lesion on the right side of the face (admission 03/05/2006)

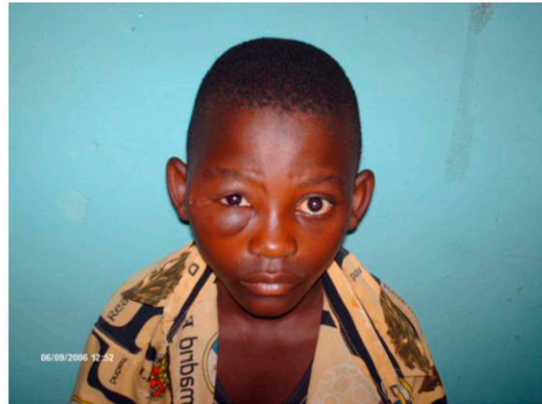


Figure 2. Frontal view of the edematous lesion

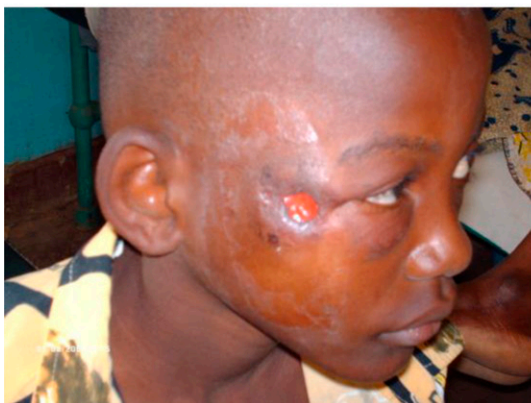

Figure 3. Ulceration on the right temple after debridement (47 days after antibiotics)

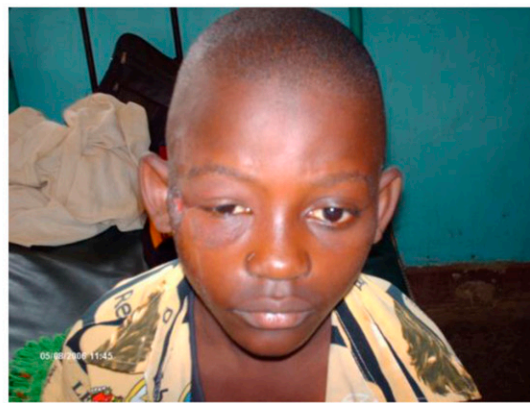


Figure 4. Reduction of the eyelids edema (week 8 of antibiotic therapy)

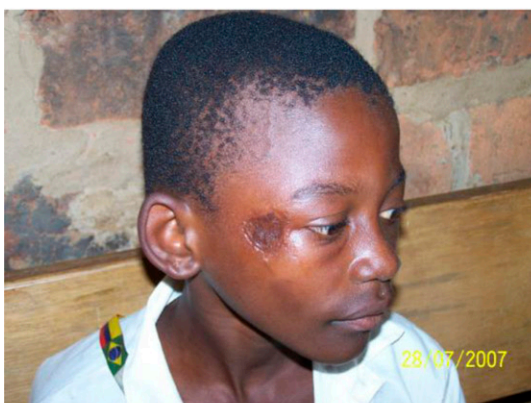

Figure 5. Scar of healed ulcer seen \pm 1 year after hospital discharge

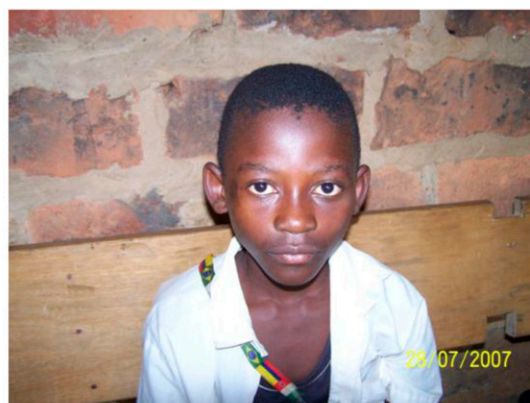


Figure 6. Patient healed without complications Follow-up 1 year after hospital discharge (127 days of treatment)

Patient 8

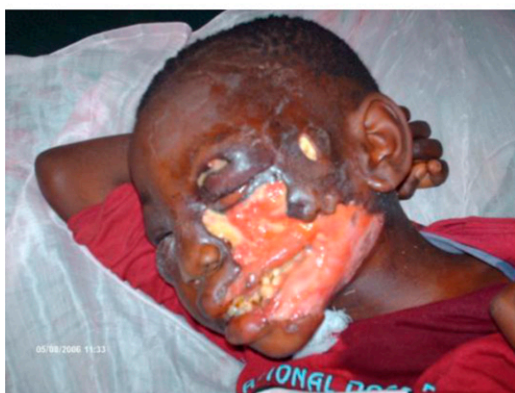

Figure 1. Large mixed disfiguring BU (admission 14/07/2006, first debridement 2 days after antibiotic therapy)

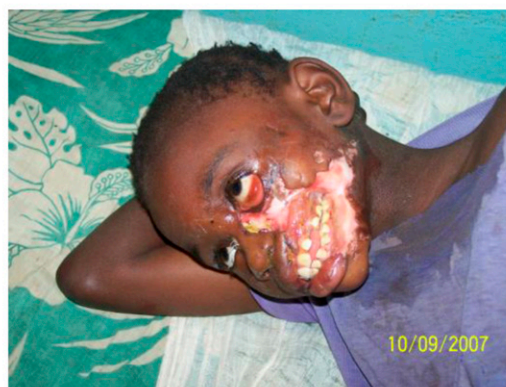

Figure 2. Healing with complications after antibiotic therapy combined with surgery (301 days of treatment)

Patient 9

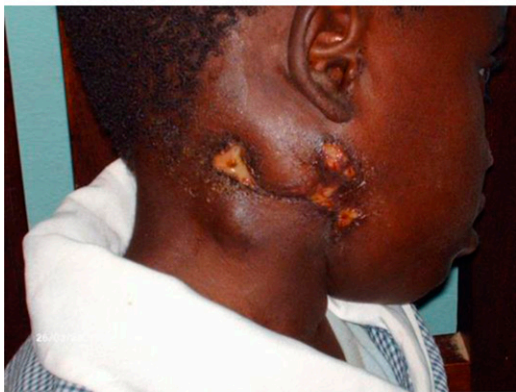

Figure 1. Mixed ulcerated lesion (BU not confirmed)(admission, 08/09/2006)

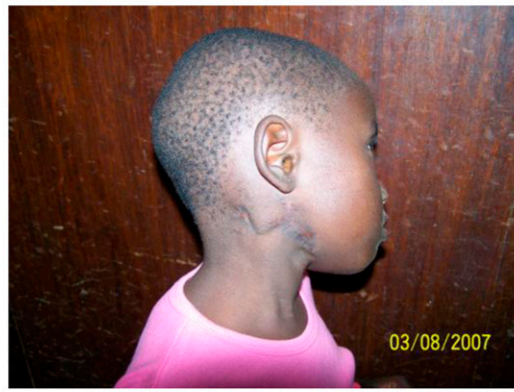

Figure 2. Follow-up 1 year after hospital discharge (32 days of treatment)

Patient 10

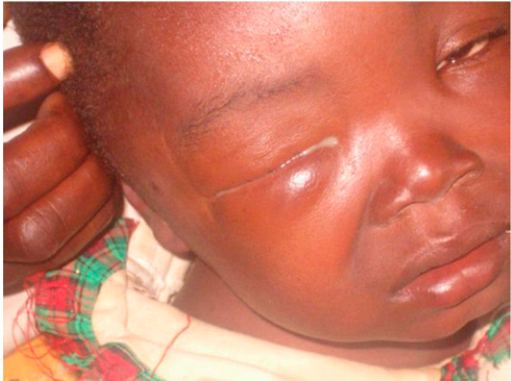

Figure 1. Painless swelling of the right eyelids (admission 16/09/2006)

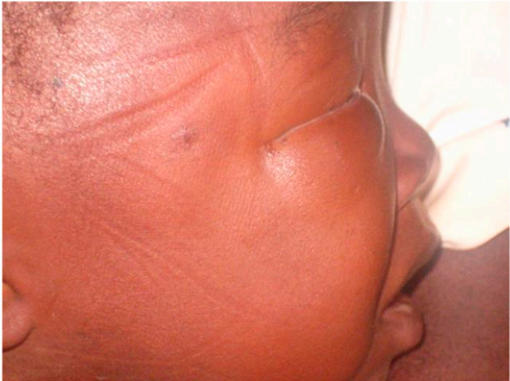

Figure 2. Papula on the right temple (admission 16/09/2006)

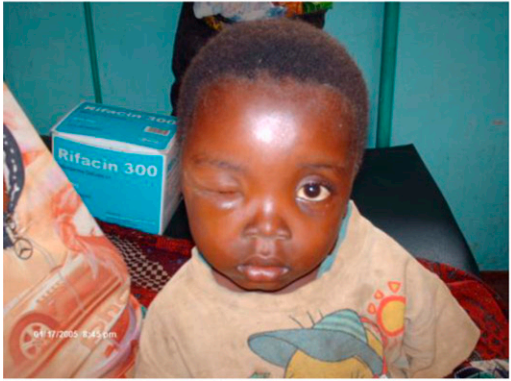

Figure 3. Week 1 of antibiotic therapy

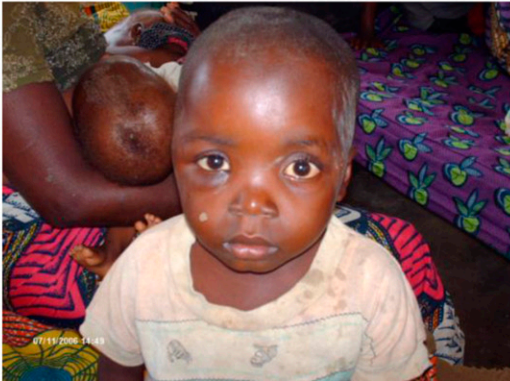

Figure 4. Week 7 of antibiotic therapy

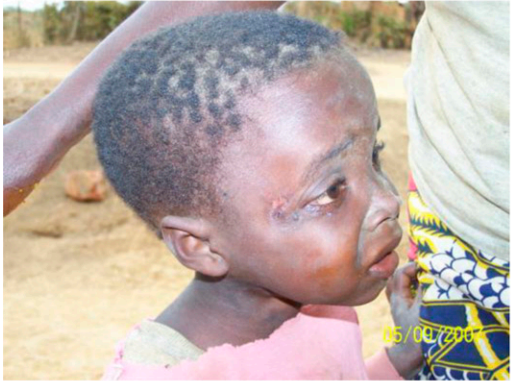

Figure 5. Small scar on the right side of the corner of the right eye



Figure 6. One year after specific antibiotic treatment without surgery (66 days of treatment)

Patient 11

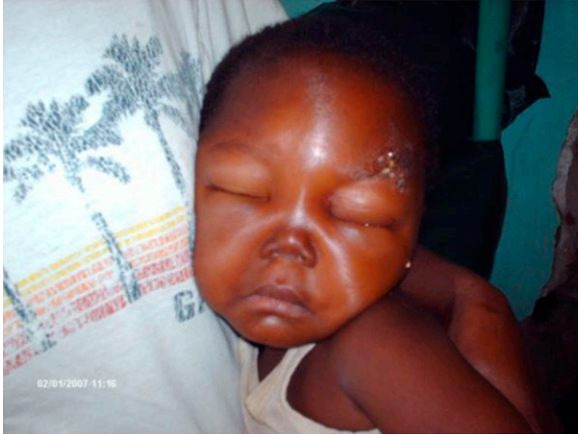

Figure 1. Extensive edematous lesion of the face (admission 02/01/2007)

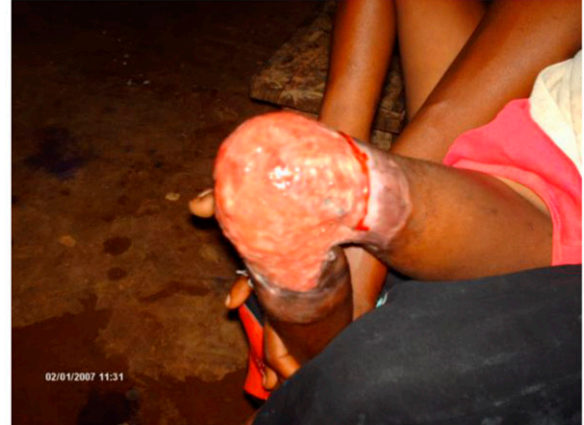

Figure 2. Ulcer on the left knee (mixed disseminated BU)(02/01/2007)

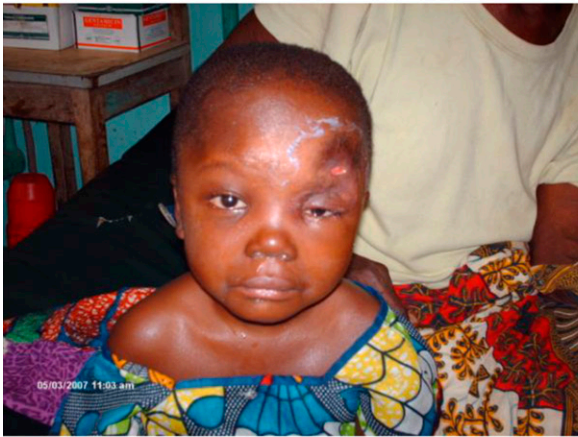

Figure 3. Remarkable edema reduction with small ulceration near the left eyebrow (8 weeks of rifampin + streptomycin)

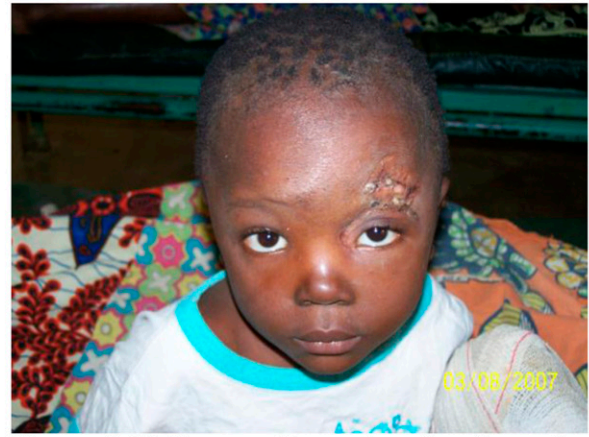

Figure 4. Follow-up 5 months after the end of antibiotic therapy (no surgery on the face)

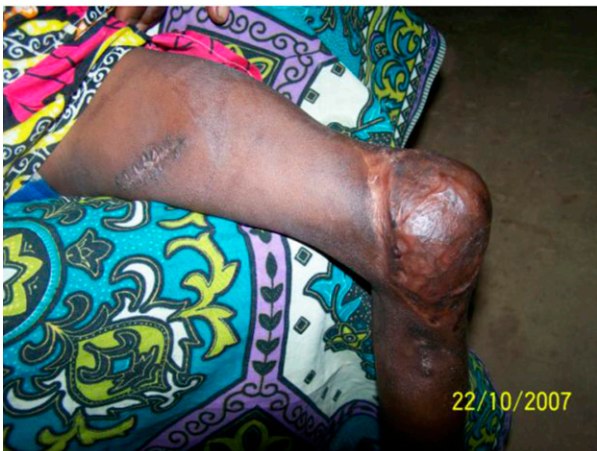

Figure 5. Scar of excised nodule on the left thigh. Skin grafted lesion of the left knee healed with functional limitation (297 days of treatment)

Patient 12

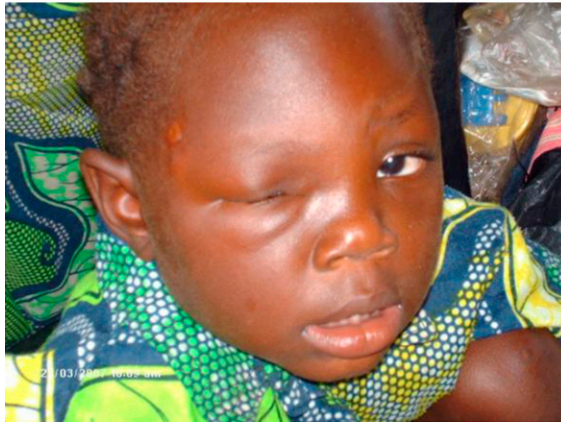

Figure 1. Periorbital edematous lesion on the right side of the face with complete eye closure (admission 26/03/2006)

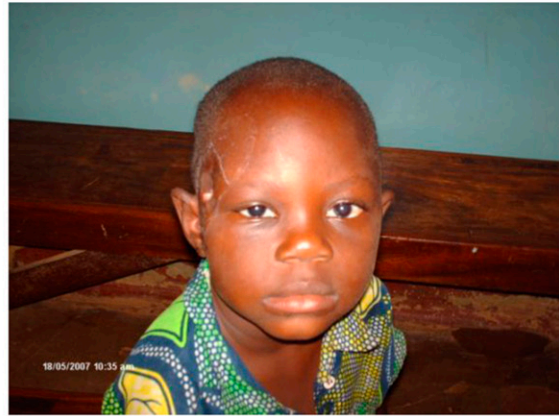

Figure 2. Noteworthy reduction of the edema (week 8 of antibiotic therapy)

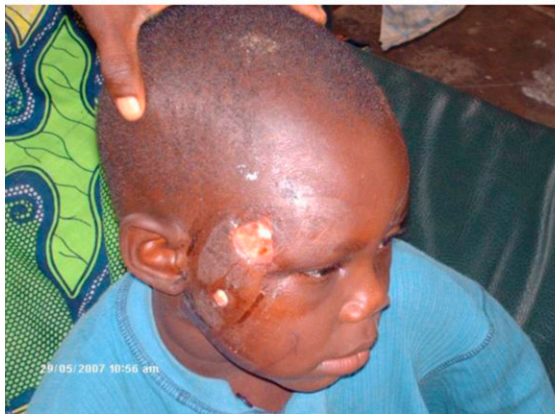

Figure 3. Ulceration on the temple (week 9 after treatment)

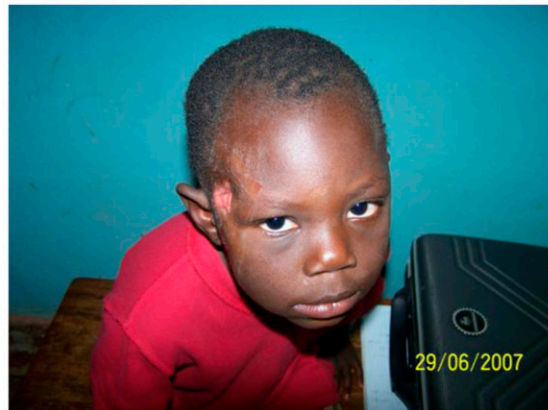


Figure 4. Follow-up in hospital 1,5 month after the end of antibiotic therapy

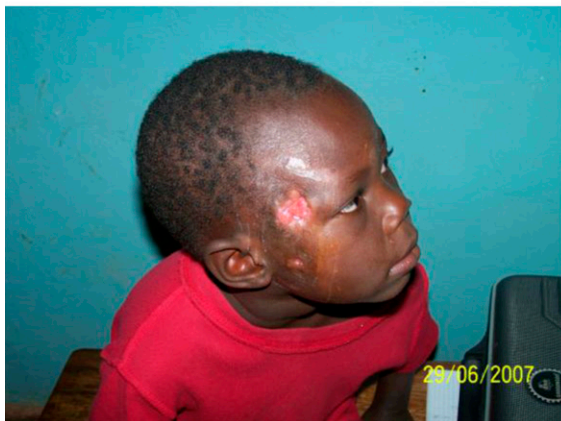

Figure 5. Cleaned wound after surgical treatment (49 days after antibiotic therapy)

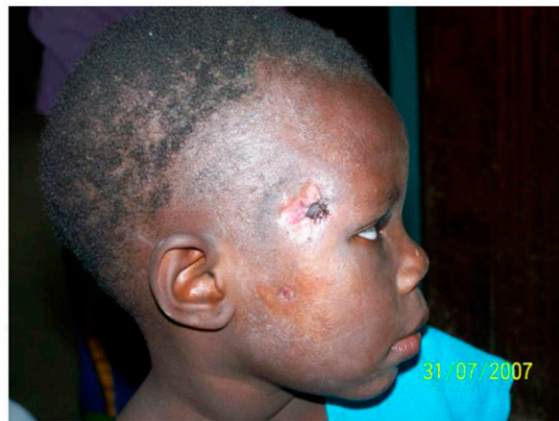

Figure 6. Healing – hospital discharge after 133 days of treatment

Patient 13

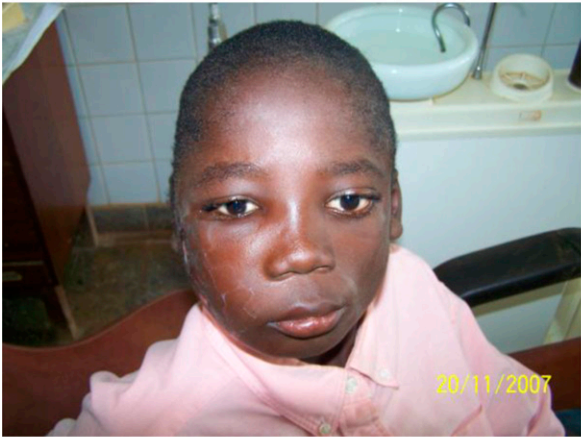

Figure 1. Edematous ulcerated lesion of the right side of the face (admission 20/11/2007)

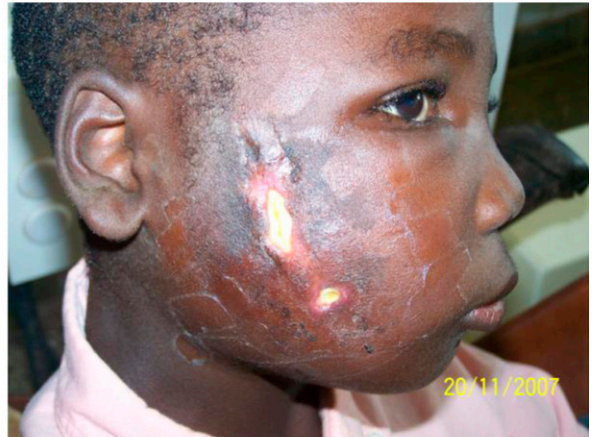

Figure 2. Mixed ulcerated lesion (admission 20/11/2007)

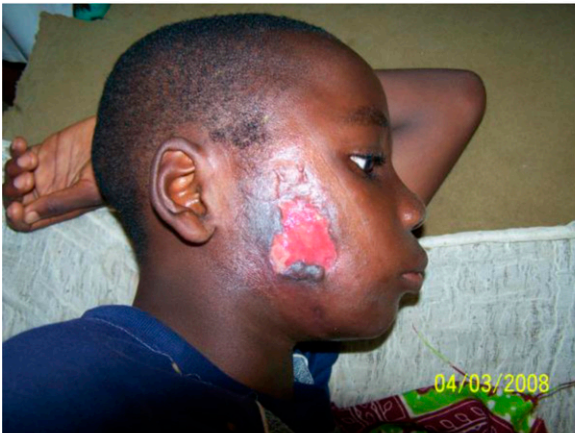

Figure 3. Cleaned wound ready for skin graft after 8 weeks of antibiotic therapy and daily wound dressings

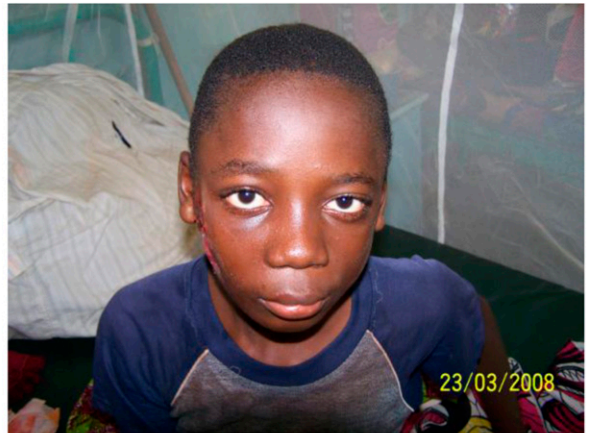

Figure 4. Complete reduction of the edema (after 151 days of treatment)