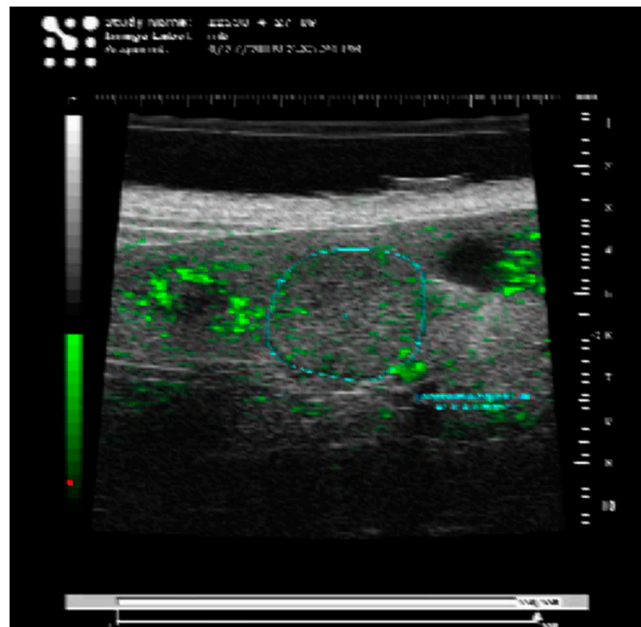


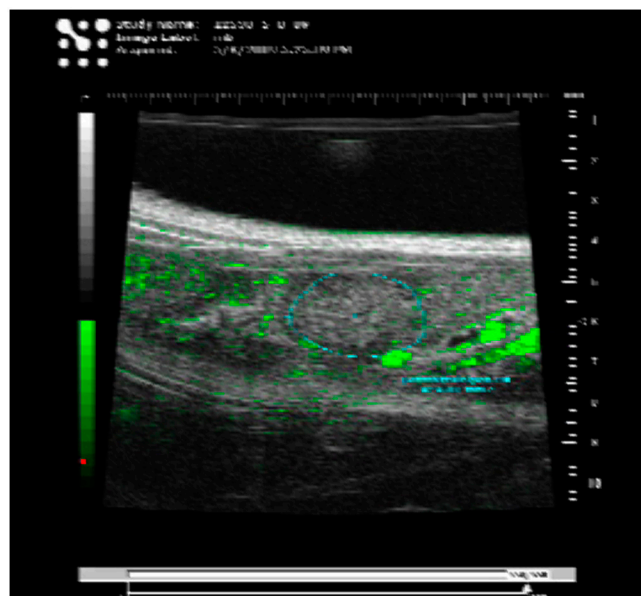
Supporting Information

Olson et al. 10.1073/pnas.1111079108



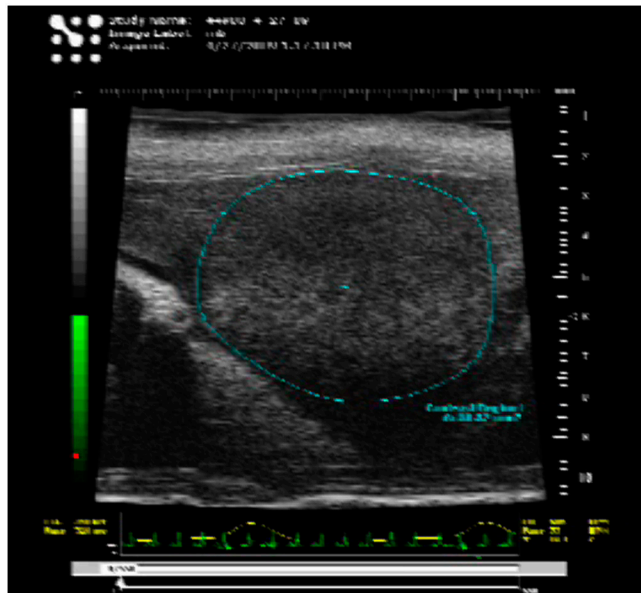
Movie S1. Microbubble contrast-enhanced ultrasound reveals reduction in blood perfusion following sunitinib treatment. Pancreatic neuroendocrine tumor before sunitinib treatment.

[Movie S1 \(MOV\)](#)



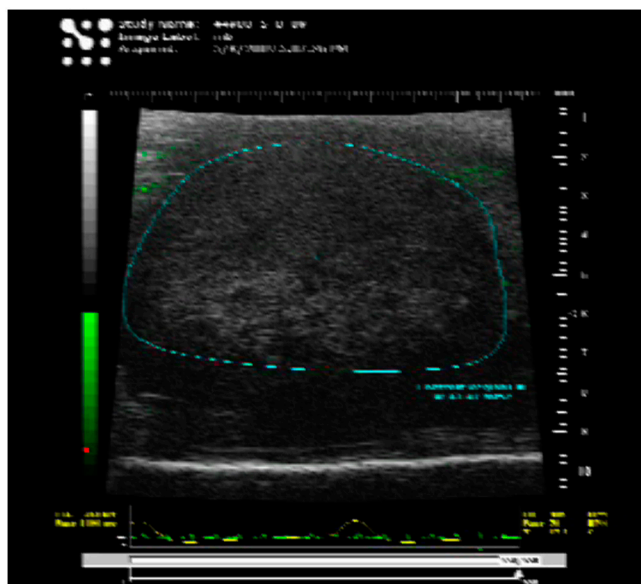
Movie S2. Microbubble contrast-enhanced ultrasound reveals reduction in blood perfusion following sunitinib treatment. Pancreatic neuroendocrine tumor after sunitinib treatment.

[Movie S2 \(MOV\)](#)



Movie S3 Pancreatic ductal adenocarcinoma tumor before sunitinib treatment.

[Movie S3 \(MOV\)](#)



Movie S4 Pancreatic ductal adenocarcinoma tumor after sunitinib treatment.

[Movie S4 \(MOV\)](#)