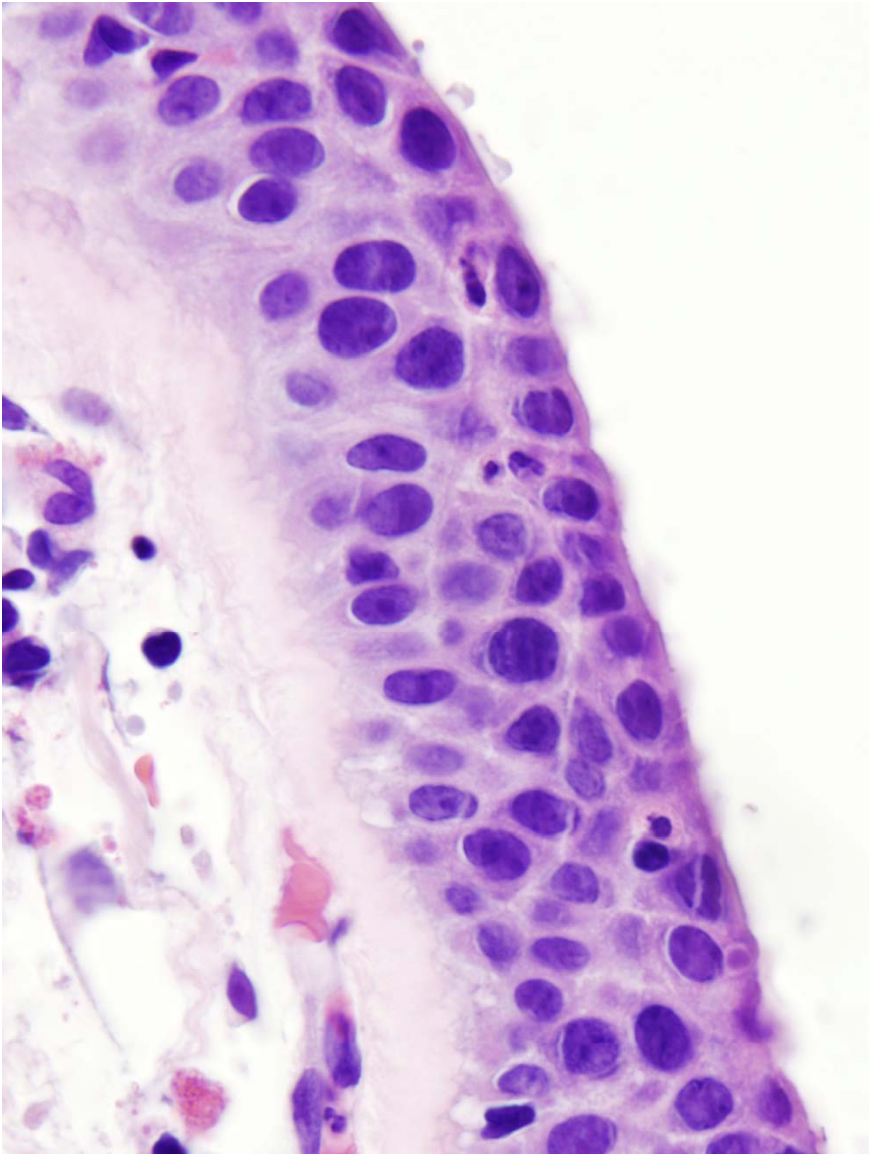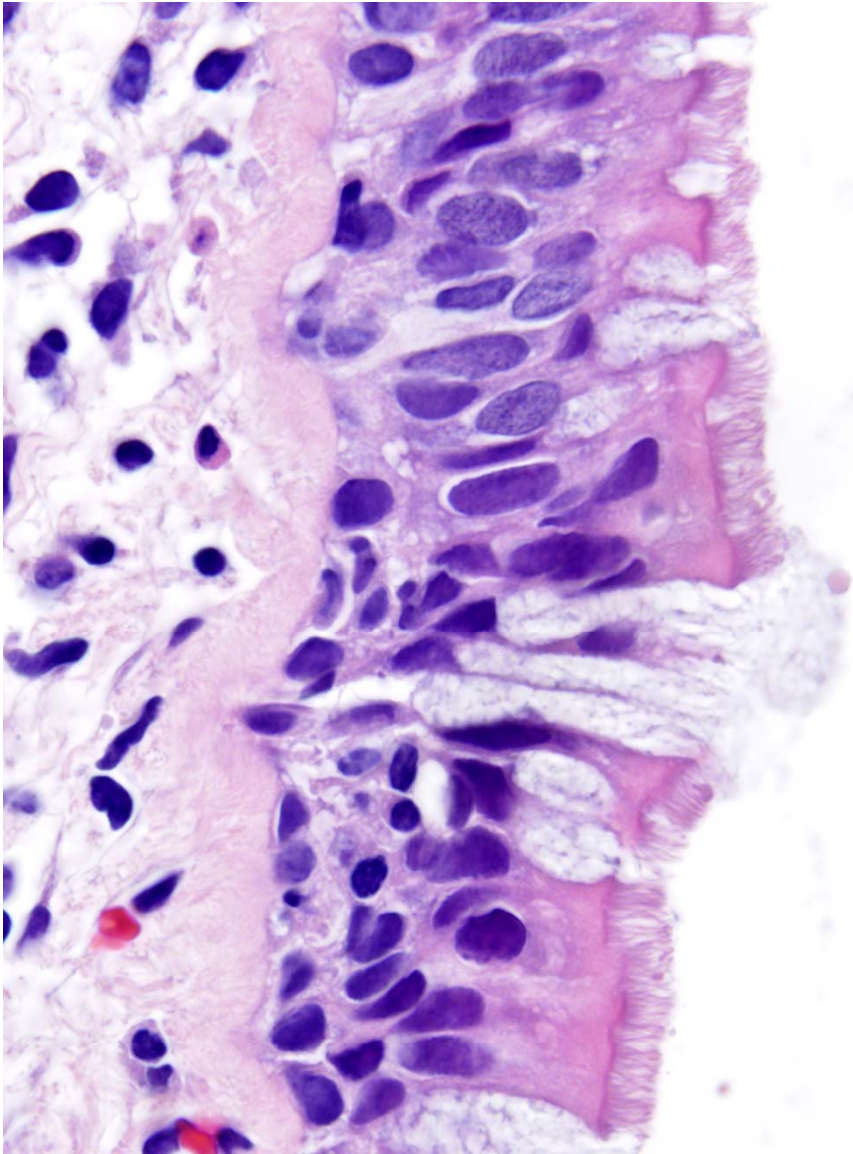


Figure 1s: Iloprost Trial Endobronchial Histology



RB1/2 baseline (severe dysplasia)



RB1/2 after iloprost (normal mucosa)