

Supporting Information

Target gene analyses of 39 amelogenesis imperfecta kindreds

CHAN H-C, ESTRELLA NM RP, MILKOVICH RN, KIM J-W, SIMMER JP, HU JC-C

University of Michigan School of Dentistry, Ann Arbor, MI, USA; and School of Dentistry,
Seoul National University, Seoul, Korea

Figure S1. Oral photographs and radiographs of the family 37 (*AMELX*, pP70T) proband at age 11.5.

Figure S2. Oral photographs of the unaffected father (II:4) of family 37 (*AMELX*, pP70T).

Figure S3. Oral photographs for family 39 (*FAM83H*, pQ452X).

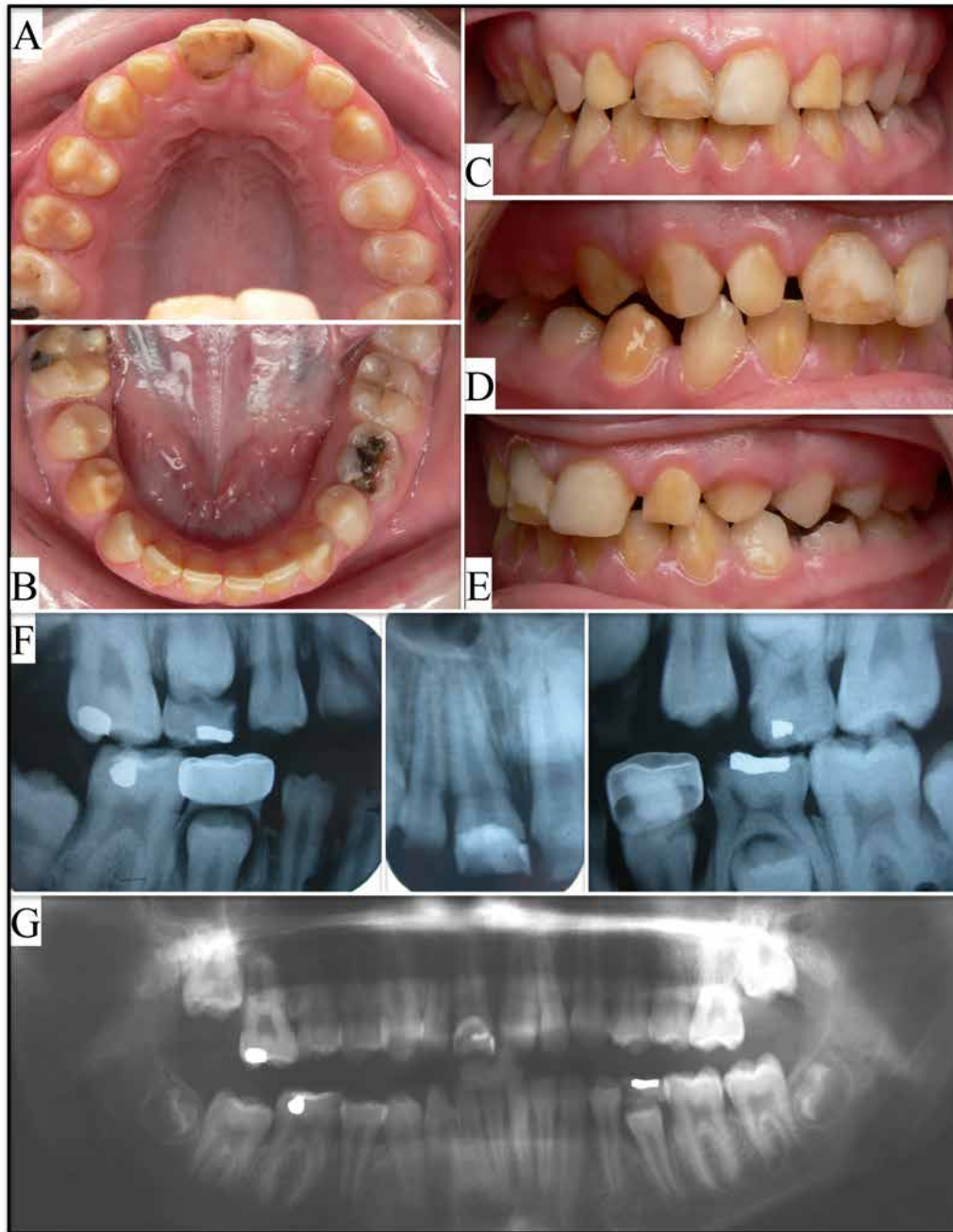


Fig. S1. Oral photographs and radiographs of the family 37 (*AMELX*, p.P70T) proband at age 11.5. **A:** maxillary occlusal; **B:** mandibular occlusal; **C:** frontal; **D:** right buccal; **E:** left buccal; **F:** intraoral radiographs; **G:** panoramic radiograph. Generalized spacing suggested a decreased enamel thickness. The striking appearance of affected and seemingly unaffected enamel located in the same tooth (e.g. tooth #6 in D) and separated in vertical pattern led us to target *AMELX* for mutational analysis. Radiographically, the enamel is thin and more radiopaque than dentin. There appears to be minor taurodontism in the molars. Repeated composite bonding and repair of restorations on the facial surfaces of the maxillary central incisors was reported.

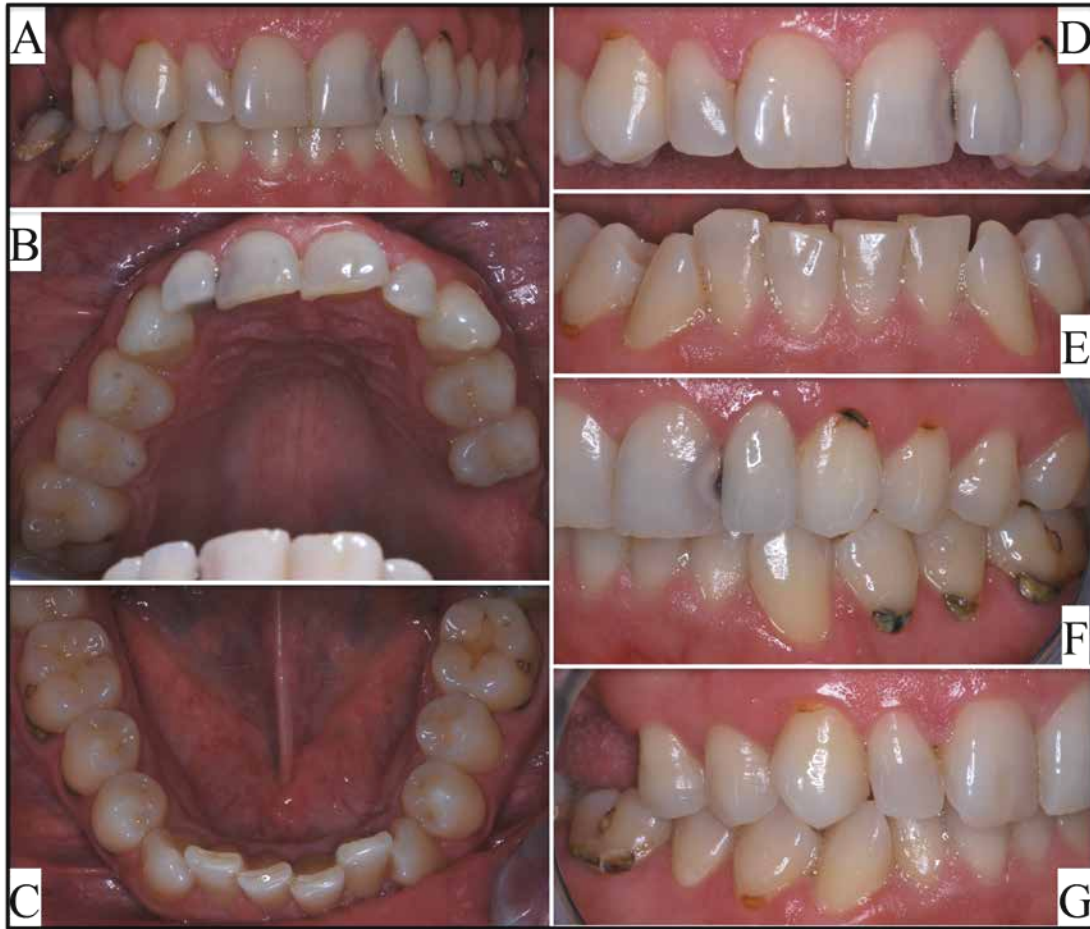

Fig. S2. Oral photographs of the unaffected father (II:4) of family 37 (*AMELX*, p.P70T). **A:** frontal; **B:** maxillary occlusal; **C:** mandibular occlusal; **D:** maxillary facial; **E:** mandibular facial; **F:** left buccal; **G:** right buccal. The enamel shows normal thickness, texture and color, although dental caries is evident.

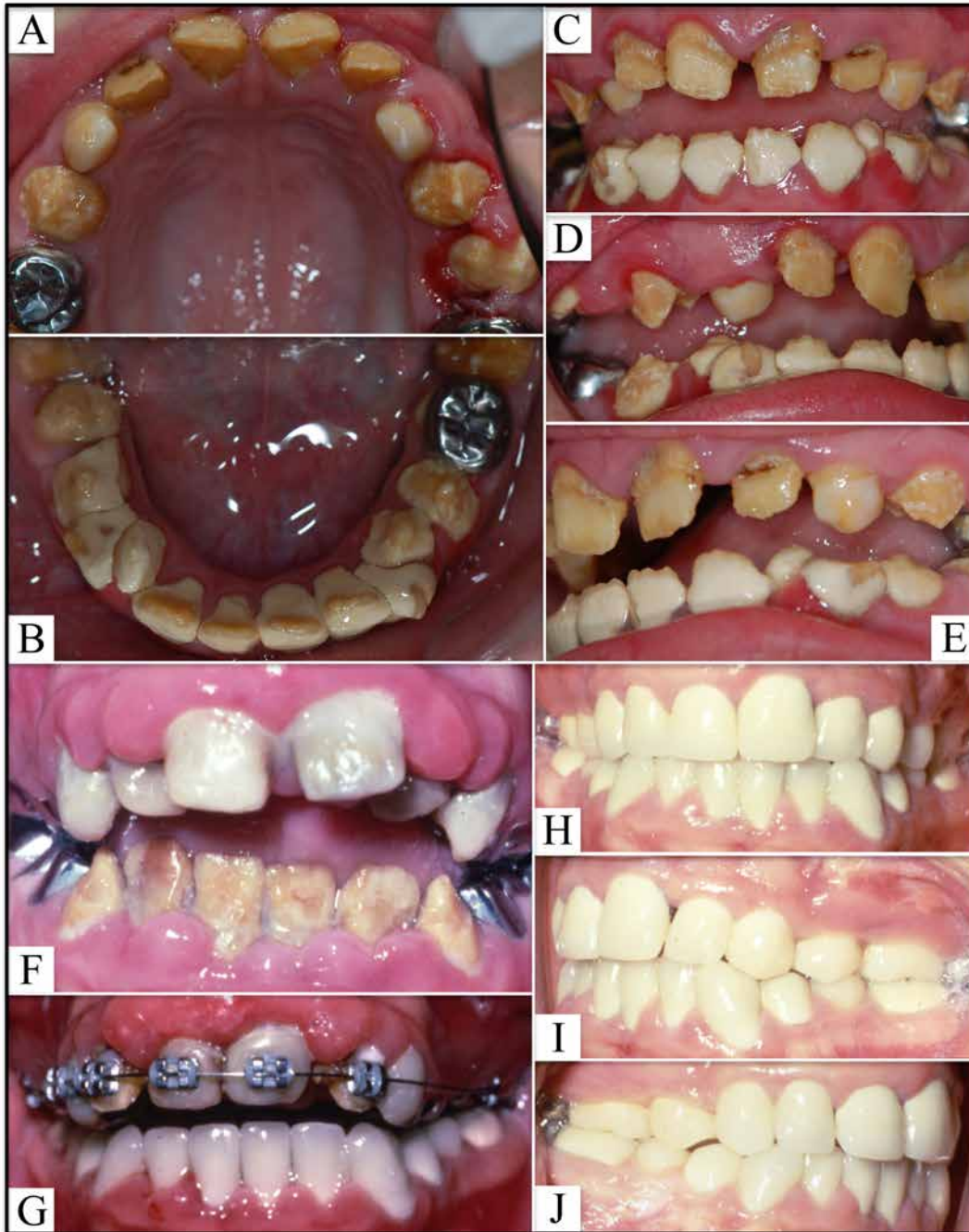


Fig. S3. Oral photographs for family 39 (*FAM83H*, pQ452X). Besides the proband, his older sister and mother both had the p.Q452X mutation in one allele of *FAM83H*. **A-E:** Oral photographs of affected sister at age 13 (III:3). The white material covering the mandibular teeth was calculus. **F-J:** Oral photographs of affected mother (II:5). These photos were brought in by the mother and were taken when she was in her early teens. **F:** anterior teeth before restoration; **G:** anterior teeth following mandibular restoration and during maxillary orthodontic treatment; **H-J:** dentition following full-mouth reconstruction.