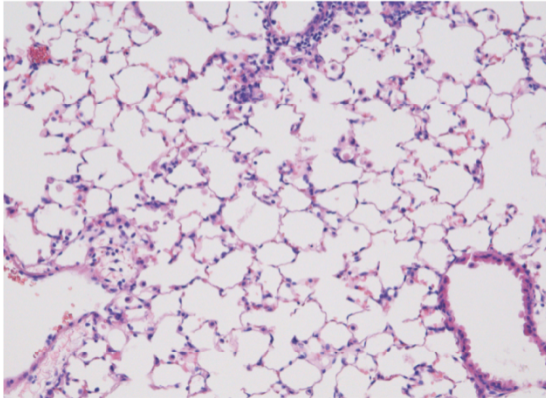
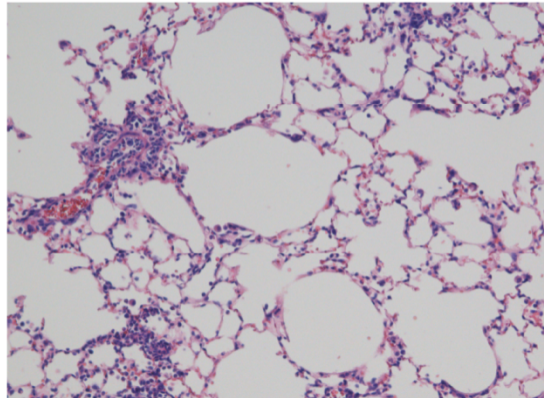


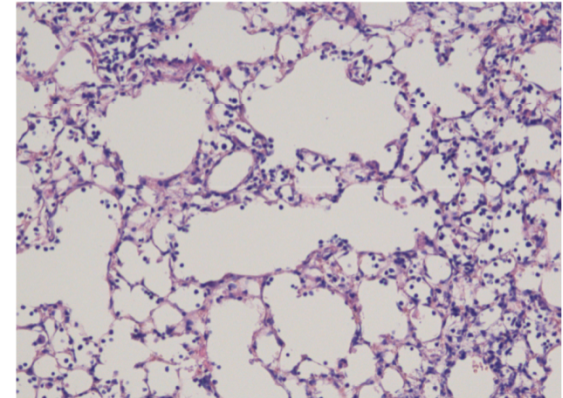
WT



IL6-KO

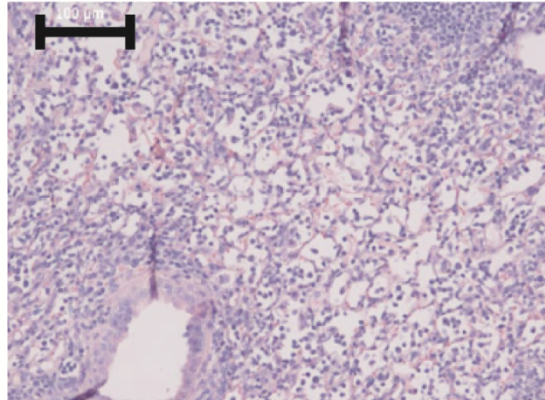


IL6R-KO

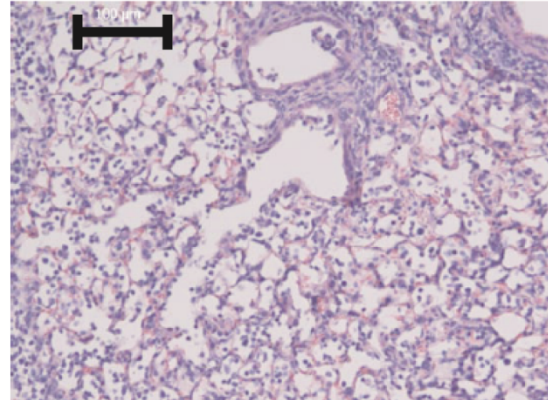


Supplementary Fig. S1. Histopathology of lungs from WT, IL-6 KO and IL-6R KO mice at day 11 p.i. with PR8 H1N1. 200x magnification of H&E stained lung sections are shown.

WT



IL6-KO



Supplementary Fig. S2. Histopathology of lungs from WT and IL-6 KO mice at day 7 p.i. with PR8 H1N1..200x magnification of H&E stained lung sections are shown. Size bars indicate 100 μm.