

**Appendix 3: Examples of different imaging modalities (Figures A and B) and treatments (Figure C) available for the management of suspected stones in the common bile duct**

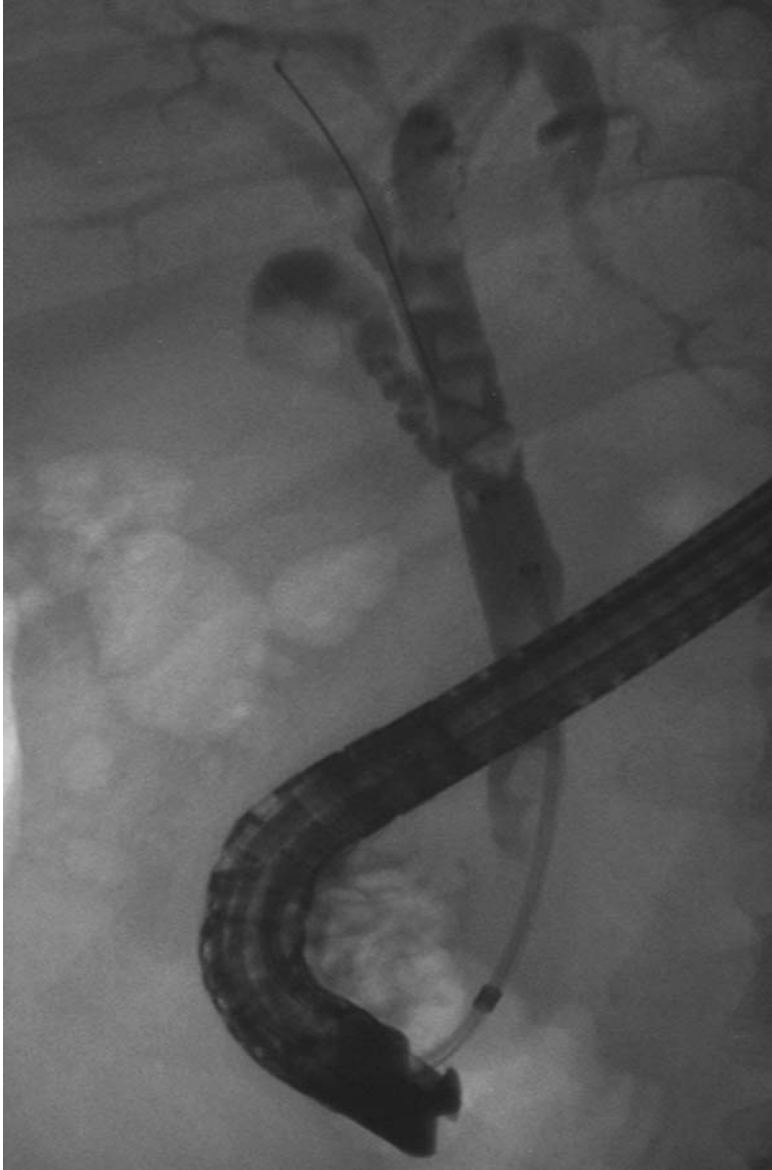


Figure A: Endoscopic retrograde cholangiopancreatography (ERCP) illustrating multiple stones in the common bile duct as filling defects.

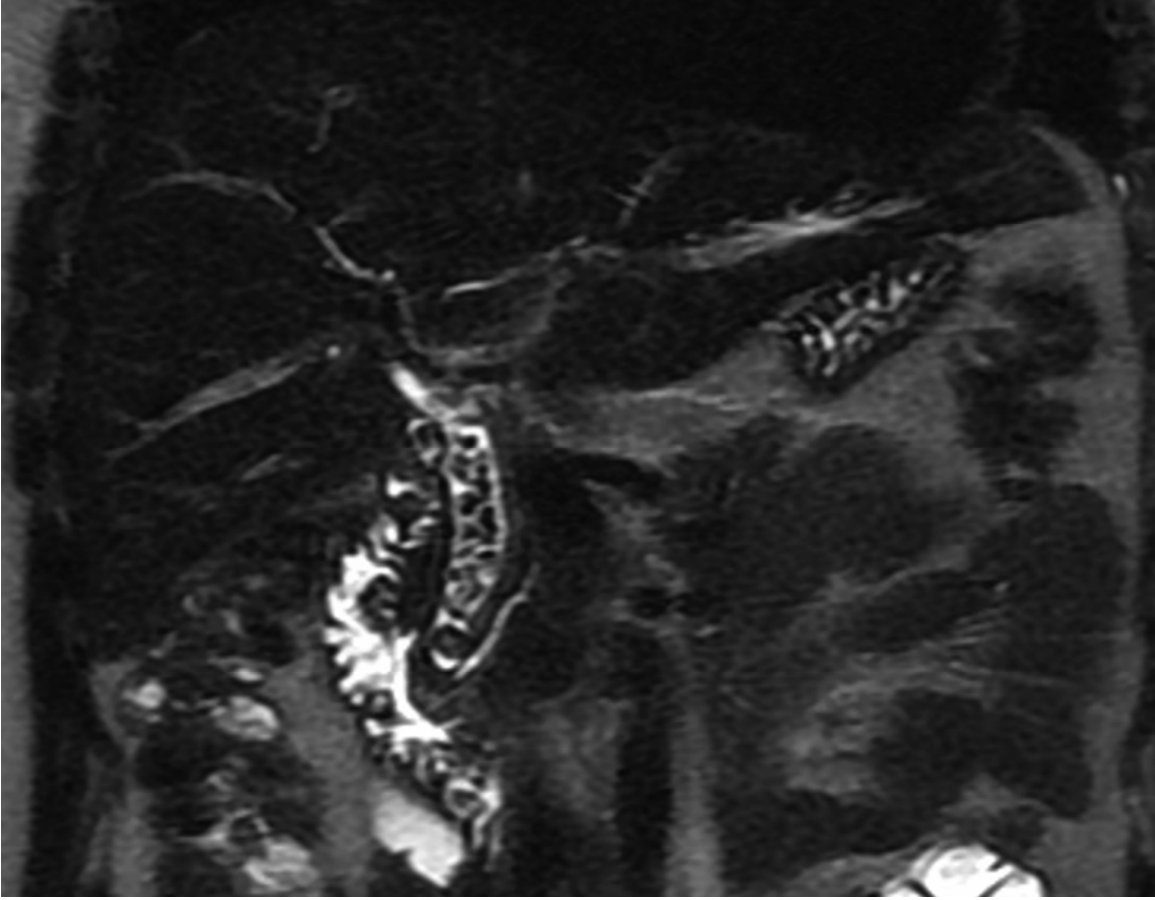


Figure B: Magnetic resonance cholangiopancreatography showing multiple stones in the common bile duct, as well as the pancreatic duct.

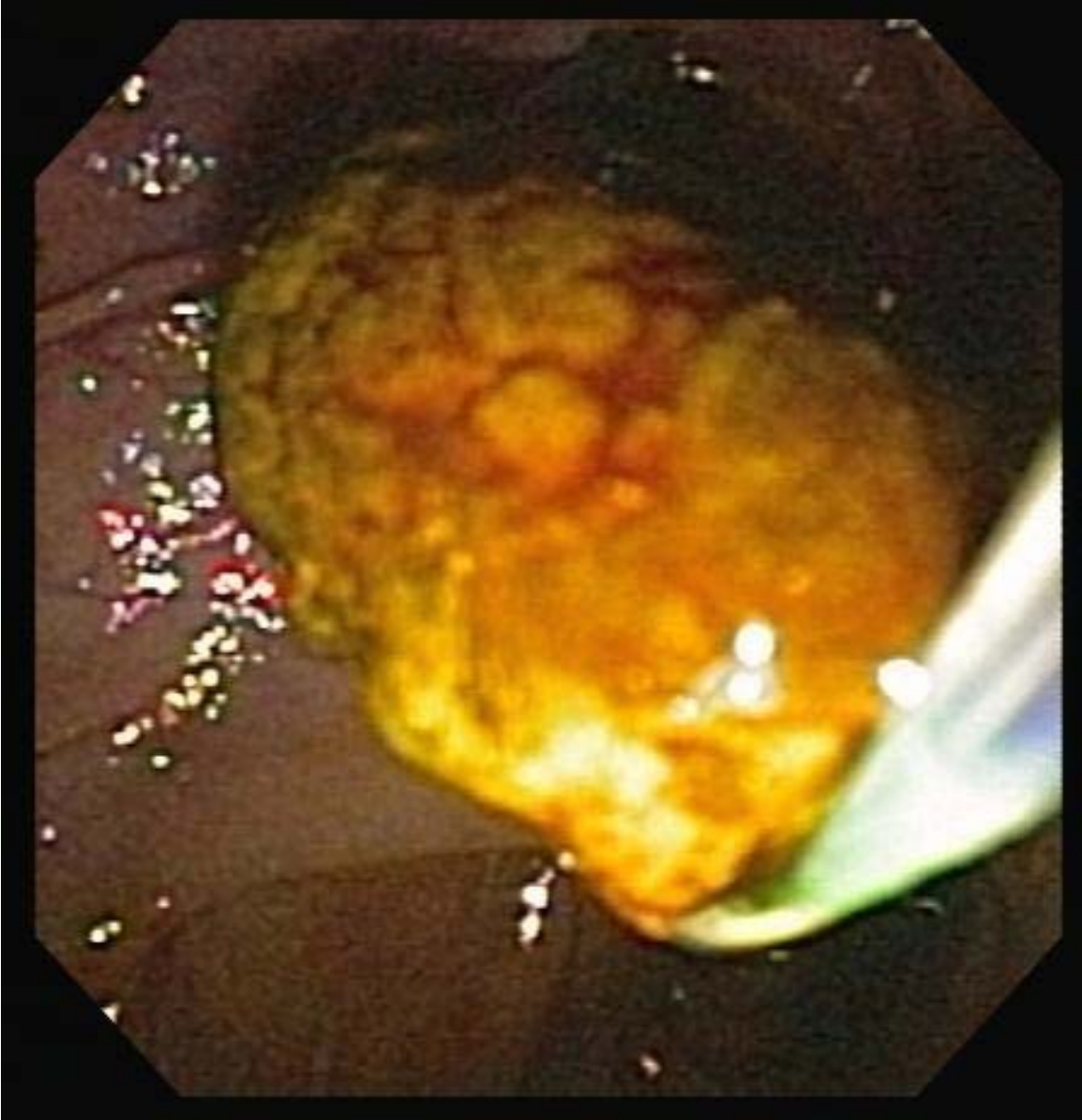


Figure C: Endoscopic view: Common bile duct stone being removed with a balloon catheter.