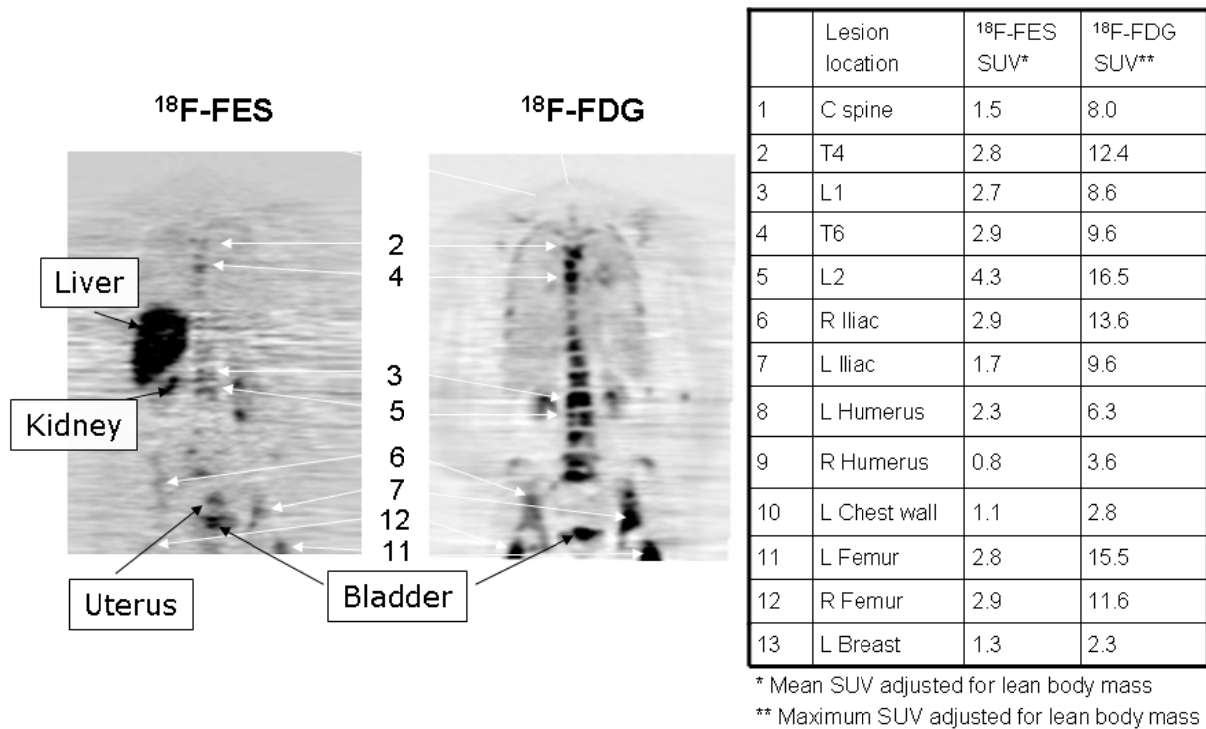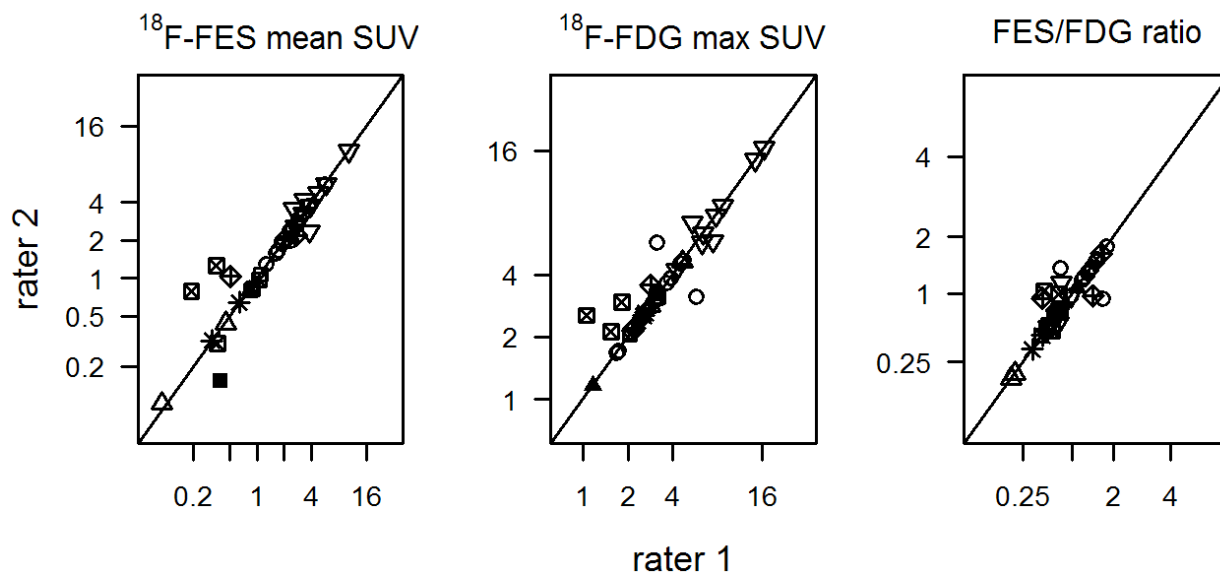


SUPPLEMENTAL FIGURE 1: Torso survey images from a 43-year-old female patient with ER+, PgR+, HER2- metastatic breast cancer. Thirteen lesions were analyzed, with FES mean  $\text{SUV}_{\text{LBM}}$  ranging from 0.8 to 4.3, and FDG max  $\text{SUV}_{\text{LBM}}$  ranging from 2.3 to 16.5. Of note, the lesions with the lowest FES  $\text{SUV}_{\text{LBM}}$  values (#9, #10, #13) also had lower FDG SUV values.



SUPPLEMENTAL FIGURE 2: Concordance of two raters in SUV measures (and FES/FDG ratio) for 38 lesions in 9 patients. Plotting symbols identify the 9 patients, and the diagonal line shows equivalence of measurements for the two raters.