

## CONCLUSIONS

It can be deemed a good practice to open the mastoid antrum and air cells if the middle ear mucosa is unhealthy (oedematous polypoidal mucosa, granulation, tympanosclerosis, etc). If the middle ear mucosa is healthy, tympanoplasty alone seems sufficient for a successful surgical outcome, irrespective of the fact whether the ear was dry or quiescent prior to surgery.

Meticulous and complete removal of disease from the middle ear cleft, with a stable assembly with ossicular chain will surely give a dry ear with good hearing (the Eustachian tube function being good). Mastoidectomy did not seem to play a significant beneficial role as regards the postoperative hearing gain.

## REFERENCES

1. Vartiainen E, Kansanen M, (1992 March) : Tympanomastoidectomy for chronic otitis media without cholesteatoma, Otolaryngology Head and Neck Surgery.

2. Vartainen E, Vartainen J, (1995 March) :Hearing results of surgery for chronic otitis media without cholesteatoma, Ear Nose Throat Journal, 74 (3) 165-166.
3. Gresdroff M, Garin P, (1995 July) :Myringoplasty long term results in adults and children, American Journal of Otology, 16(4) 532-5.
4. Podoshin L, Fradis M, Malatskey S, (1996 March) : Tympanoplasty in adults; A five year survey, Ear Nose Throat Journal 75 (3) 149-152, 155-156.
5. Paperella M.M, Froymovich O, ( May 1994) : Surgical advances in treatment of otitis media, Annals of Otology Rhinology Laryngology (suppl), 163, 49-53.

### *Address for correspondence:*

Anita Krishnan,  
402, Embassy Tranquil,  
No.22, 8th Main, 3<sup>rd</sup> Block,  
Koramangala,  
Bangalore-560034.

# SURGICAL DECOMPRESSION IN BELL'S PALSY - OUR VIEWPOINT

**D.S. Grewal<sup>1</sup>, Bachi T. Hathiram<sup>2</sup>, Rohan Walvekar<sup>3</sup>,  
Alok V. Mohorikar<sup>4</sup>, Minal Shroffs, N.K. Bahal<sup>6</sup>**

*Abstract : Bell's palsy or acute idiopathic lower motor neuron facial palsy is a common cause of facial palsy seen in clinical practice. The cause of this disease is not exactly known though there are many theories regarding its etiology. In this article, we present the theory of "Tertiary ischaemia" in cases of persistent Bell's palsy. Our concept of Tertiary ischaemia is further supported by histological findings of the nerve sheath biopsy taken during surgical decompression in cases of Bell's palsy. The procedure of performing posterior tympanotomy and improving the exposure of the middle ear structures therein is also explained.*

*Key Words : Bell's palsy; Tertiary ischaemia; Open window effect*

## HISTORICAL ASPECTS

In 1821, Sir Charles Bell, an anatomist and a surgeon first described facial palsy and named it "Bell's Palsy." He was subsequently knighted for his work. In 1919, Antoni using physical diagnostic techniques labelled the disease as "Acute infectious polyneuritis cerebral acousticofacialis," while in 1960, Dalton identified "Ramsay Hunt Syndrome" as a florid form of Bell's palsy. In 1904, Riek suggested that the cause may be a sub-clinical middle ear infection and proposed a combined medical and surgical treatment. However, Watermann in 1909 showed that the middle ear was normal in cases of Bell's palsy. There was a divergence of opinion regarding the treatment. In 1982, Peitersen published his landmark article in which 1101 patients were followed up for a period of one year. It showed that almost 80% of the

patients had some return of facial function without any kind of intervention.

The concept of spasm of middle meningeal artery or the stylomastoid artery and paralysis due to ischaemia gradually came in. In 1936, Tumarkin suggested "vascular decompression" which included cortical mastoidectomy with obliteration of the stylomastoid artery as a treatment option. The 1950s saw many treatment regimens that included low dose Histamine to massive doses of Histamine and Prednisolone (Taverner, 1955). Korkis (1961) classified patients into two groups - the "vasospastic group" who showed good results with a cervical sympathetic block and the "organic thrombosis group" who did not benefit from the same. Various adjuvants were used like galvanic stimulation, physical therapy

- facial support, massage, exercises and splints. They have been recommended and condemned.

Brackmann (1974) advocated the decompression of the facial nerve in cases of Bell's palsy as he felt that decompression done at the right time helped in reducing the incidence of persistent facial palsy. For a very long time it was believed that decompression at the stylomastoid foramen was a sufficient treatment for Bell's palsy till Fisch, in 1977, recommended middle cranial fossa approach to decompress the facial nerve. Transmastoid Extralabyrinthine Subtemporal approach was described by May (1979). Thus, at present, there are various approaches for decompression of the nerve. However, the role of decompression in cases of Bell's palsy is still debatable.

## INTRODUCTION

Acute idiopathic lower motor neuron facial palsy is also known as 'Bell's Palsy'. Bell's Palsy is described as acute idiopathic lower motor neuron palsy of the facial nerve that is usually unilateral, self-limiting, non-progressive, non-life threatening and spontaneously remitting by 4-6 months and always by 1 year. The diagnosis of Bell's palsy is that of exclusion and theoretically it is considered to be accurate only when there is no evidence of any other cause for facial palsy. Nevertheless, there is evidence that a typical idiopathic palsy is mediated by a viral inflammatory immune reaction. Clinical, epidemiological and laboratory data have shown that Bell's palsy is a form of acute benign cranial polyneuritis caused by the Herpes Simplex virus I (Murakami *et al*, 1996). An accurate diagnosis along with understanding of the disease process is required to provide an appropriate treatment and to estimate the prognosis. The facial nerve takes its origin from the lower border of the pons from the facial colliculus and passes through the temporal bone ending by dividing in the substance of the parotid gland. Its unique journey through a long and tortuous narrow fallopian canal and its intracranial and extracranial relationship determines its vulnerability to disease.

### Etiopathogenesis in Bell's Palsy

There are three accepted theories with regard to the etiopathogenesis in cases of Bell's palsy. They include Vascular ischaemia theory; Viral theory and Hereditary theory.

### Vascular ischaemia theory

This theory proposes that there is decrease in the blood supply of the facial nerve that leads to primary ischaemia and subsequently secondary ischaemia. Vasospasm of the blood vessels lead to the decrease in the blood supply to the facial

nerve. Though epineurium has a rich vascular supply, the nerve is relatively avascular due to which primary ischaemia will cause a palsy of the nerve. However the opponents of this theory cite that the nerve has an adequate blood supply with numerous anastomoses between the stylomastoid and

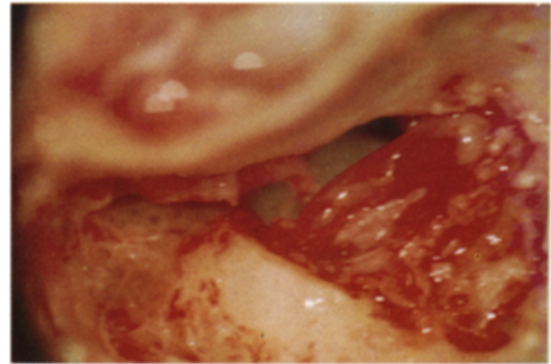


Fig. I : Intra-operative photograph of facial nerve decompression by a posterior tympanotomy. The facial nerve is seen in its mastoid portion and its sheath is slit open. Note the thickened fibrosed nerve sheath with nerve bulging out of the sheath with marked edema at the stylomastoid foramen.

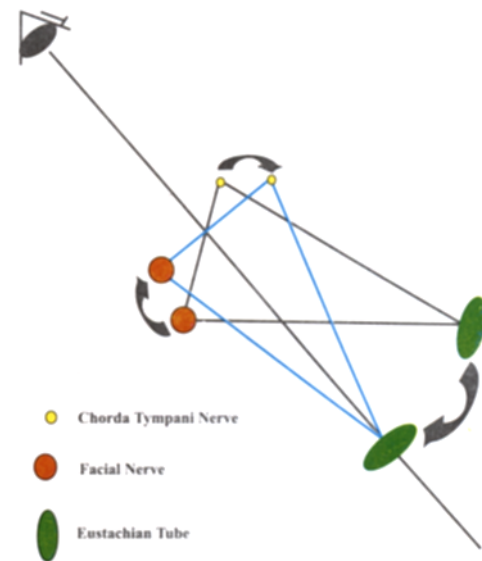


Fig II : OPEN WINDOW EFFECT: This diagrammatic representation shows the relationship of the facial nerve, chorda tympani nerve and the eustachian tube in a posterior tympanotomy and improvement of the visual field on tilting the patient's head as seen through the operating microscope.

Solid line – Exposure seen in the regular position of the patient while operating.

Dotted line – Improved exposure following tilting of the head of the patient causing an apparent increase in the distance between the chorda tympani nerve and facial nerve as they now lie in the same plane which is perpendicular to the visual axis– termed by us as the open window effect.

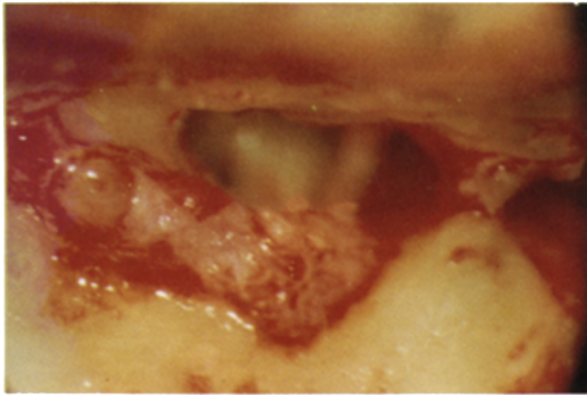


Fig. III : Intra-operative photograph shows the site of biopsy of the Facial nerve sheath with bulging of the out of the facial nerve at the biopsy site.

the petrosal blood vessels. Drachman (1969) has noted that primary ischaemic neuropathy is rare occurring only in certain conditions like the Liereche's syndrome and possibly Diabetes Mellitus. Proponents of this theory have demonstrated lack of significant anastomosis between the stylomastoid and the petrosal vessels (Donath and Lengyel, 1957); decreased vascularity of the horizontal segment of the facial nerve (Blunt, 1954) and acute onset facial paralysis following the embolisation of the middle meningeal artery (Calcaterra *et al*, 1976). Hilger in 1949 proposed that the process of primary ischaemia leads to secondary ischaemia. Primary ischaemia causes arteriolar constriction followed by capillary dilatation that causes increase in the capillary permeability and transudation of fluid. This leads to compression of the lymph capillaries subsequently causing an additional accumulation of fluid. This causes compression of the capillaries and venules. Due to a rigid bony fallopian canal, there is zonal ischaemia and a vicious cycle follows. Sunderland (1945) has pointed out that obstruction to the venous outflow leads to swelling or edema that leads to the obstruction of the arteriolar flow. McGovern *et al* (1966) propose that the triggering mechanism in Bell's palsy is an immunological process of mast cell degranulation activated by complement of specific allergens. This causes the release of Histamine in immediate hypersensitivity reactions.

### Viral Theory

This theory proposes that Bell's palsy may be a part of polyneuropathy of viral origin. Adour *et al* (1978) have found involvement of multiple cranial nerves in cases of Bell's palsy. Also, they have found a stationary titer to Herpes simplex virus or a rising titer to Herpes zoster and also an abnormality in spinal fluid in some patients. Thus, they have concluded that Bell's palsy is an acute benign cranial

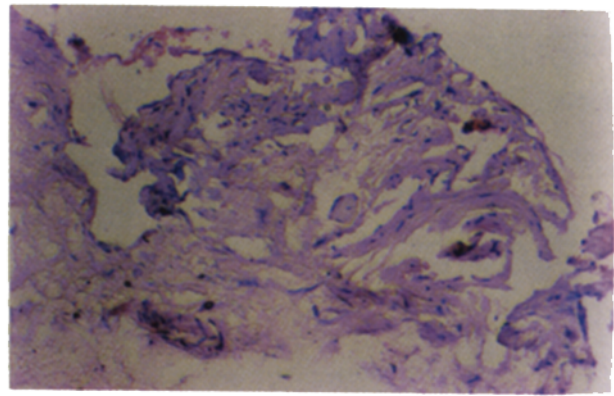


Fig. IV : Histopathology (H & E, 200X) of the facial nerve sheath showing the presence of edema and fibrosis in a case of Bell's palsy.

polyneuritis caused by reactivation of Herpes simplex virus. Djupesland *et al* (1975) have also proposed that Bell's palsy may be caused due to cranial polyneuropathy that may be viral in origin. This view is supported by May and Hardin (1977) and Tomita (1977) who have also concluded that Herpes simplex virus or Herpes zoster virus is a cause of infection. It is proposed that the virus replicates in the ganglion cells causing local damage and hypofunction of the nerves. It then passes down to the axons causing radiculitis. It infects the Schwann cells causing inflammation and auto immune response. Lymphocytic infiltration follows leading to fragmentation of myelin, demyelination and chromatolysis. When the inflammation and the autoimmune reaction resolve, remyelination follows.

### Hereditary theory

A familial anatomic variation in the facial canal may account for tendency towards the incidence of facial palsy. The bony constriction of the fallopian canal leads to acute recurrent attacks of facial palsy. This is commonly seen in osteoprosis

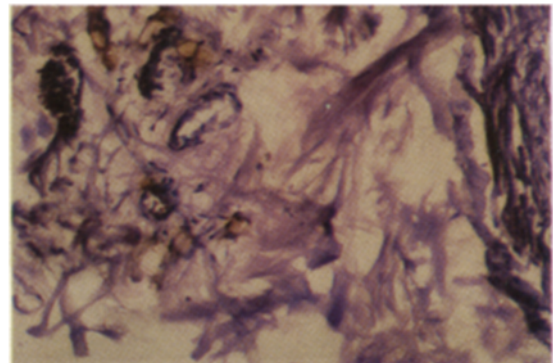


Fig. V : Histopathology (H & E, 400X) of the facial nerve sheath in a case of Bell's palsy showing the features of obliterative endarteritis along with blood vessels with markedly thickened vessel walls.

group of diseases in which the fallopian canal is of an abnormally small diameter. It also makes the nerve more prone for primary ischaemic insult or viral infections. It is proposed that this trait of development of recurrent attacks of facial palsy is a recessive trait.

#### **Our viewpoint on etiopathogenesis...**

We, while supporting all the theories for Bell's palsy, also propose an extension of the vascular ischaemia theory in cases of persistent facial paralysis occurring in Bell's palsy. This persistent facial paralysis is related to what can be called as "Tertiary Ischaemia."

To understand the concept of tertiary ischaemia it is important to understand the arterial supply of the facial nerve as well as the microscopic anatomy of the facial nerve sheath. A detailed account of the blood supply of the nerve is given by Blunt (1954). To summate, in short the facial nerve is supplied by branches of both the vertebro-basilar and the carotid systems. In the posterior cranial fossa it is supplied by the anterior inferior cerebellar artery. Within the internal auditory meatus it is supplied by the internal auditory artery while at the geniculate ganglion it is supplied by the petrosal branch of the middle meningeal artery and in the mastoid segment by the stylomastoid branch of the posterior auricular artery. Both the arterial systems have been implicated to have an extensive anastomosis. However, some researchers believe that the labyrinthine segment is an anatomical transition zone between the vertebro-basilar and the carotid systems and is hence considered to be more vulnerable for damage. Also, the meatal foramen or the entrance to the fallopian canal is considered by Fisch and Esslen to be the narrowest portion of the fallopian canal and this increases the vulnerability of the nerve to damage (Esslen, 1977).

The facial nerve is covered by a nerve sheath in the fallopian canal. The nerve sheath has three distinct layers - a tough shiny periosteal layer followed by a layer of loose connective tissue containing blood vessels and a firm layer of fibrous tissue that sends strands that connect the perineural connective tissue. The nerve itself has perineurium, epineurium and endoneurium. The epineurium has a rich vascular supply that communicates freely with the larger vessels. However, the nerve itself is relatively avascular.

With this basis of arterial supply of the nerve and the nerve sheath anatomy, the concept of tertiary ischaemia can be explained. Primary ischaemia in Bell's palsy leads to increase in the capillary permeability with accumulation of fluid within a rigid bony fallopian canal. This leads to zonal ischaemia

also known as secondary ischaemia. If the process of secondary ischaemia is prolonged it can lead to what we call as tertiary ischaemia. In secondary ischaemia, the vascular events that take place in the nerve sheath cause vasospasm of the arterioles in the layer of loose connective tissue. This is a temporary reversible event. In most of the cases, this temporary vasospasm resolves with complete return of function within 4 – 6 months. However, in certain cases, it may persist leading to the permanent event of endarteritis of the blood vessels of the nerve sheath. Due to this the nerve sheath becomes thickened, fibrous and cord-like. A thicker nerve sheath further enhances the compressive effects on the nerve and it persists even after the resolution of inciting factors. This leads to a persistent facial palsy and to prevent this early surgical intervention is required which, as per our experience, gives excellent results.

#### **Histological Aspects**

We have demonstrated the presence of endarteritis of the nerve sheath histologically by taking a biopsy of the nerve sheath in cases of Bell's palsy during its surgical decompression. The microscopic features include the presence of vessels with thickened walls along with a few vessels showing features of obliterative endarteritis. These features are typically seen in cases that have a persistent facial palsy. Also, the other features that can be appreciated are the presence of edema in early cases. In some cases with persistent palsy, marked amount of fibrosis can be seen in the nerve sheath which can be appreciated as a thickened nerve sheath under the operating microscope. These typical features can be very well demonstrated by some special stains like the Masson's trichrome.

#### **Treatment:**

The medical treatment of Bell's palsy includes oral steroids e.g. Prednisolone (1 mg/kg/day) which is given in tapering doses; Vasodilators e.g. Xanitol nicotinate; Antihistaminics; Antibiotics, Antivirals and other adjuvants like Facial exercises and physiotherapy and eye care. The medical treatment forms the mainstay of treatment in Bell's palsy and it results in improvement of most of the cases. The surgical treatment includes the decompression of the facial nerve that may be done by various approaches. They include middle cranial fossa approach; Translabyrinthine approach; Transmastoid extralabyrinthine Subtemporal approach and Total decompression that may be a combination of the approaches mentioned above.

It still remains controversial whether a case of Bell's palsy should be offered surgical treatment and at what point of

time should it be offered. There are no strict criteria as to when the facial nerve should be decompressed. Various researchers have debated on the role of surgical decompression. The Marsh and Coker criteria (1991) state the following indications:

- \* Complete denervation
- \* Paralysis for more than 4 - 6 weeks
- \* Incomplete return of function in 60 days
- \* Recurrent facial palsy
- \* Nerve excitability test shows a difference of 3.5 mA on both the sides

Schirmer's test can be used to decide the mode of surgical decompression - if the tear flow is reduced by more than 50% on the affected side, then a total decompression or middle fossa approach is indicated.

## DISCUSSION

We studied 30 cases of Bell's palsy. The cases were studied for a variable period with a mean follow-up of 1-year. All the cases were investigated and appropriate treatment was administered to them. The investigations included the Schirmer's test, Tympanometry and tests for taste sensations along with CT scans in selected cases among the topodiagnostic tests. The prognostic tests included the EMG and NET.

Of the 30 cases, 12 cases were offered surgical decompression by a transmastoid approach and the rest of the cases were treated medically. We selected a transmastoid approach because the entire facial nerve can be decompressed till the labyrinthine segment without causing dizziness, loss of hearing and an exteriorized mastoid cavity. The Marsh and Coker criteria were applied to select the cases appropriate for surgical decompression.

In all the cases, a standard postauricular incision was taken with an anteriorly based pedicle flap. A complete cortical mastoidectomy was done and a posterior tympanotomy was performed. The mastoid segment of the facial nerve was then decompressed. The incus was disarticulated, if necessary and temporarily translocated in the middle ear. The middle fossa dura was then skeletonised and the decompression proceeded proximal to the second genu till the entire nerve was decompressed and its sheath was slit. (Fig.-1)

During the decompression, we have observed that after posterior tympanotomy, the standard surgical position of the patient provides a limited view of the structures seen in the middle ear including the tympanic portion of the facial nerve through the tympanotomy window. However by tilting the

head of the patient downwards, the distance between the chorda and facial nerve apparently increases bringing both in the same plane which lies perpendicular to the visual axis. This improves the view of the middle ear structures through which horizontal facial and the tympanic end of the Eustachian tube can be clearly visualized. We have termed this effect as "the Open Window" effect. (Fig.- 2).

Of the 12 cases we decompressed, biopsy of the nerve sheath was taken in 7 cases. (Fig.- 3) The biopsy was taken on random basis and the gross and microscopic features of the nerve sheath were studied. On gross examination the sheath was thick and cord-like. Microscopically it showed gross fibrosis of the connective tissues along with thickened vessel walls and features of obliterative endarteritis. (Fig.- 4 & 5) This was seen in all the cases where the biopsy was taken. The above findings are in conjunction with our theory of Tertiary ischaemia and the histological changes seen during the same. These findings further support our viewpoint of the need to slit the sheath of the nerve in all the cases in order to relieve the nerve of the strangulating effects of the thickened rigid nerve sheath. These histological changes along with the results seen after surgical decompression forms the basis of our viewpoint for the need of surgical decompression of the facial nerve along with slitting of the nerve sheath in selected cases of Bell's palsy.

## CONCLUSION

With regard to the etiopathogenesis in cases of Bell's palsy, there are three accepted theories. They include the Vascular ischaemia theory; Viral theory and Hereditary theory. We propose an extension of the vascular ischaemia theory by postulating "Tertiary ischaemia" in cases of Bell's palsy with persistent facial paralysis based on our surgical experience and histological findings of the biopsies of the nerve sheath. The thickened vessel walls with endarteritis and fibrosis of the nerve sheath can be clearly demonstrated in the biopsies of the nerve sheath taken from the decompressed facial nerve in the cases of persistent facial paralysis in Bell's palsy, thus proving our theory of "Tertiary ischaemia." To prevent the sequelae of persistent facial palsy, surgical decompression is the solution. Surgical decompression by a transmastoid approach as described above is an adequate procedure and provides excellent results. However, this should always be accompanied by the slitting open of the nerve sheath, consequently decompressing the nerve not only from its rigid bony canal but also from a thickened nerve sheath.

## ACKNOWLEDGEMENT

We are grateful to Dr. (Mrs.) Sharadini Dahanukar, Dean,



T.N. Medical College and B.Y.L. Nair Charitable Hospital for allowing us to publish this paper.

## REFERENCES

1. Adour, K.K., Byl, F.M., Hilsinger, R.L., Kahn, Z.M., Sheldon, M.I. (1978): The true nature of Bell's palsy: Analysis of 1000 Consecutive Patients. *Laryngoscope* 88: 787.
2. Antoni, N. (1919): Herpes Zoster. *Med. Forlaning Hygiea* 81:340.
3. Blunt, M.J. (1954): The Blood supply of the Facial nerve. *J. Anat.* 888:520.
4. Brackmann, D.E. (1974): Bell's palsy: Incidence, Etiology and Results of Medical Treatment. *OCNA Vol.7 No.2*, 357.
5. Calcaterra, T. C., Rand, R.W., Bentson, J.R. (1976): Ischaemic Paralysis of Facial Nerve: A Positive Etiological factor in Bell's palsy. *Laryngoscope* 86: 92.
6. Dalton, G.A. (1960): Bell's palsy: Some Problems of Prognosis & Treatment. *Br. Med. J.*: 1: 1765.
7. Djupesland, G., Berdal, P., Johannessen, J.A., Degre, M., Stein, R., Skrede, S., (1975): The role of Viral Infection as a Cause of Acute Peripheral Facial Palsy. *Acta Otolaryngol.* 79:221.
8. Donath, T. and Lengyel, I. (1957): "The vascular structure of the intrapetrosal section of the facial nerve, with special reference to peripheral facial palsy". *Acta Med. Acad. Sci. Hung.* 10 : 249.
9. Drachman, D. (1969): "Bell's Palsy – A Neurological point of view". *Archives of Otolaryngology*, 89: 147.
10. Esslen, E. (1977): The acute facial palsies: Investigations on localization and pathogenesis of Meato-labyrinthine facial palsies. Berlin Springer Verlag.
11. Fisch, U. (1977): Total facial nerve decompression and Electroneuronogram. *In* : Neurological surgery of the Ear. pp.21 (Silverstien, H., Norrell, H., eds. Birmingham/U.S.A. Aesculapius pub. Co.)
12. Hilger, J.A. (1949): The nature of Bell's palsy. *Laryngoscope* 59:228.
13. Korkis, B. (1961): Treatment of recent Bell's palsy by cervical sympathetic block. *Lancet* 1: 255.
14. Marsh, M.J., Coker, N.J. (1991): Surgical Decompression of Idiopathic Facial Palsy. *OCNA*, Vol. 24: 675.
15. May, M., Hardin, W.B. (1977): Facial Palsy: Interpretation of Neurological Findings. (Trans.) *Am. Acad. Ophthalmol. Otol.*: 84: ORL 710.
16. May, M. (1979): Total Facial Nerve Exploration: Transmastoid, Extralabyrinthine, Subtemporal: Indication and Results. *Laryngoscope*, 89: 906.
17. McGovern, F.H., Thompson, E., Link, N. (1966): The experimental production of ischaemic facial paralysis. *Laryngoscope*, 76: 1138.
18. Murakami, S., Mizobuchi, M., Naakaashiro, Y., Takashi, D., Hato, N., Yanagihara, N. (1996): Bell's palsy and Herpes Simplex Virus: Identification of Viral DNA in Endoneural fluid and Muscle. *Ann. Intern. Med.* 124: 27.
19. Peiterson, E. (1982): The Natural History of Bell's palsy. *Am. J. Otol.* 4; 107.
20. Sunderland, P.S. (1945): Blood supply of peripheral nerves. *Arch. Neurol. Psych.* 54:280.
21. Taverner, D. (1955): Bell's palsy. *Brain* 78:209.
22. Tomita, H. (1977): "Viral etiology of Bell's palsy". *In* Facial Nerve Surgery Ed. By U. Fisch Amsterdam, Kugler Medical Publication.

### **Address of Correspondence :**

D.S. Grewal  
 Professor and Head,  
 Department of E.N.T. and Head & Neck Surgery,  
 No. 28; College Bldg. 1<sup>st</sup> Floor,  
 T.N. Medical College and  
 B.Y.L. Nair Charitable Hospital.  
 Mumbai 400008.