

Supplementary Note S1

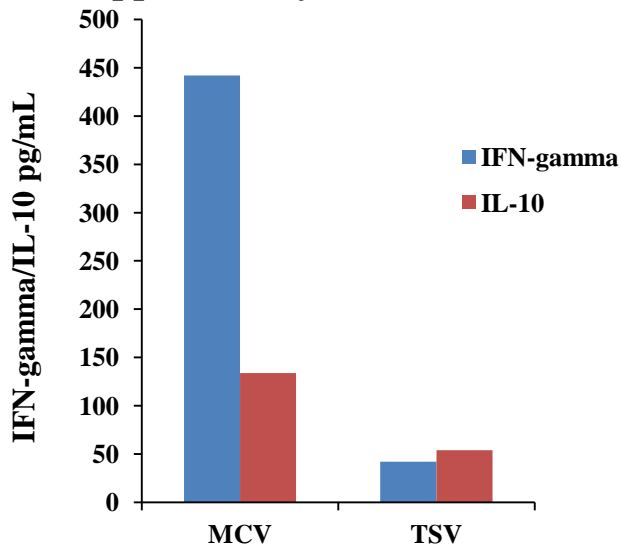


Table: Kinetics of MCV and TSV-specific IL-10 responses in the MCC patient and in healthy control subjects from 3 and 5 day supernatant

Serostatus	Subject	MCV		TSV	
		IL-10 pg/ml		IL-10 pg/ml	
		3d	5d	3d	5d
^a MCV ⁺ TSV ⁻	#T1	62	134	154	54
MCV ⁺ TSV ⁻	#T43	32	202	12	28
MCV ⁺ TSV ⁻	#T17	28	60	10	20
MCV ⁺ TSV ⁺	#T46	10	18	4	30
MCV ⁺ TSV ⁺	#T16	54	160	28	58
MCV ⁻ TSV ⁻	#T44	16	24	8	46

^a: MCC patient

Fig. MCV and TSV-specific Th-cell responses in a MCC tumor patient

Clinical information of MCC patient

Age, sex and location of tumor: 48 years, male, trunk

Stage of MCC: T3N1aM0; tumor >5cm with nodal metastasis detected in sentinel node biopsy (AJCC staging system)¹

MCV and TSV serostatus: Pos (MCV), Neg (TSV)

MCV and TSV DNA status: In Blood- MCV (Neg), TSV (Neg)
In Tumor- MCV (Pos), TSV (Neg)

Treatments : Radical surgery with 2 cm marginal, sentinel node biopsy followed by complete lymph node dissection, and post operative radiotherapy

Other information: Patient is alive, follow up time one year.

Immunostaining and histology

Histology consistent with MCC confirmed by immunohistochemistry:

Panycytokeratin +

CK20 +

BCLA2 +

SYP (synaptophysin) +

ChA (chromogranin A) neg

TTF-1 (thyroid transcriptase factor 1) neg

References

1. Allen PJ, Bowne WB, Jaques DP, Brennan MF, Busam K, et al. (2005) Merkel cell carcinoma: Prognosis and treatment of patients from a single institution. J Clin Oncol 23(10): 2300-2309. 10.1200/JCO.2005.02.329.