

S. Vergauwen  
P. M. Parizel  
L. van Breusegem  
J. W. Van Goethem  
Y. Nackaerts  
L. Van den Hauwe  
A. M. De Schepper

## Distribution and incidence of degenerative spine changes in patients with a lumbo-sacral transitional vertebra

Received: 17 June 1996  
Revised: 2 October 1996  
Accepted: 22 October 1996

S. Vergauwen · P. M. Parizel (✉)  
L. van Breusegem<sup>1</sup> · J. W. Van Goethem  
Y. Nackaerts · L. Van den Hauwe  
A. M. De Schepper  
Department of Radiology,  
Antwerp University Hospital,  
Wilrijkstraat 10, B-2650 Edegem, Belgium  
Tel. +32-3-821 3732;  
Fax +32-3-825 2026

### Present address:

<sup>1</sup>Department of Radiology,  
St. Vincent Hospital, Antwerp, Belgium

**Abstract** The purpose of this prospective study was to determine the overall incidence and distribution of lumbo-sacral degenerative changes (i.e. disc protrusion or extrusion, facet degeneration, disc degeneration, nerve root canal stenosis and spinal stenosis) in patients with and without a lumbo-sacral transitional vertebra (LSTV). The study population consisted of 350 sequential patients with low back pain and/or sciatica, referred for medical imaging. In all cases CT scans of the lumbo-sacral region were obtained. In 53 subjects (15%) an LSTV was found. There was no difference in overall incidence of degenerative spine changes between the two groups. We did find, however, a different distribution pattern of degenerative changes between patients with and those without an LSTV. Disc protrusion

and/or extrusion occurred more often at the level suprajacent to the LSTV than at the same level in patients without LSTV (45.3% vs 30.3%). This was also the case for disc degeneration (52.8% vs 28%), facet degeneration (60.4% vs 42.6%) and nerve root canal stenosis (52.8% vs 27.9%). For spinal canal stenosis there was no statistically significant difference between the two categories. In conclusion, our findings indicate that an LSTV does not in itself constitute a risk factor for degenerative spine changes, but when degeneration occurs, it is more likely to be found at the disc level above the LSTV.

**Key words** Transitional vertebrae · Suprajacent degenerations · Spine CT

## Introduction

Lumbo-sacral transitional vertebrae (LSTV) are common congenital anomalies, with a reported prevalence of 3%–21% [5]. The causal role of LSTV in low back pain syndrome is controversial. Some authors [3, 10] have suggested that there is an increase of degenerative disease more cephalad in spines with transitional lumbo-sacral segments but this has been disputed by other investigators [12].

It was our impression that in patients with low back pain, degenerative changes occurred more often at the level above such an LSTV. The aim of this study was to

determine the distribution and incidence of degenerative pathology in patients with an LSTV.

## Materials and methods

### Study type and subjects

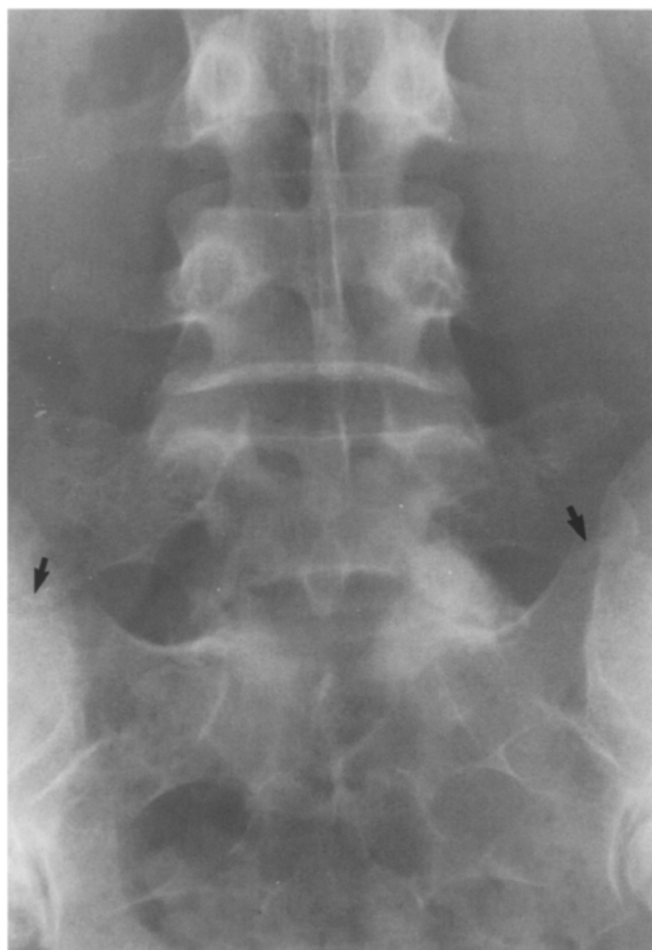We performed a prospective, sequential study of 350 adults with low back pain and/or sciatica referred for a CT examination of the lumbo-sacral spine. In selected cases, plain X-ray films and MRI examinations were used for comparison. The CT scans were analysed by three experienced radiologists. We did not assess the intra- or interobserver reproducibility, as this was beyond the scope of our study.

## Imaging

In all instances (i.e. patients and controls), high-resolution CT scans of the lumbo-sacral spine were obtained on a GE 9800 Hi-Light Advantage system or a GE 9800 Quick CT system. The standardized CT protocol involved examination of the three lowermost disc levels. Axial sections were performed parallel to the disc interspaces as determined from a lateral scout radiograph. Slice thickness was 5 mm, with an increment of 4 mm (1-mm overlap between slices). The axial CT scans were obtained with a 3-s scan time, 140 kV and 140 mA. Both bone and soft tissue window settings were obtained in all instances. When considered necessary by the referring physician, MR examinations of the lumbo-sacral spine were performed either on a superconductive 1.5-T system (Magnetom 63SP4000, Siemens, Erlangen) or on a 0.2-T resistive system (Magnetom Open, Siemens).

## Image analysis and definitions

LSTV were defined on the basis of two criteria. First, at least one transverse process had to fuse or articulate with the first contiguous sacral segment. Second, an intervertebral disc space, even a vestigial one, had to be present caudal to the LSTV. A typical transitional vertebra meeting these criteria is shown in Fig. 1.



**Fig. 1** Anteroposterior radiograph showing a typical lumbo-sacral transitional vertebra (LSTV) in a 47-year-old man. The transverse processes articulate with the first sacral segment bilaterally (arrows)

The terms lumbarization and sacralization were deliberately avoided, since the entire spine was not always visualized and consequently positive identification of the fifth lumbar vertebra was not always possible.

Further image analysis was performed to evaluate the distribution and incidence of degenerative spine changes with regard to five criteria: (1) disc protrusion/extrusion; (2) nerve root canal stenosis; (3) spinal stenosis; (4) facet degeneration; (5) disc degeneration.

To be included as a disc protrusion in this study, focal or asymmetric extension of the disc beyond the interspace, with the base against the disc of origin broader than any other dimension of the protrusion, had to be present. (For a schematic axial representation of disc protrusion, see Jensen et al. [6].) Disc extrusion was defined as a more extreme extension of the disc beyond the interspace, with the base against the disc of origin narrower than the diameter of the extruding material itself or with no connection between the disc material and the disc of origin [6].

The term "nerve root canal stenosis" included narrowing from the lateral recess to the intervertebral foramen with marked decrease or obliteration of the fat in the nerve root canal and of such magnitude that the exiting nerve root or dorsal root ganglion was likely to be compressed. The lateral recess was considered narrowed when it was less than 3 mm in maximum anteroposterior dimension, measured between the superior articular process and the posterior aspect of the vertebral body at the level of the nerve root canal [4].

Central spinal stenosis was diagnosed when the anteroposterior canal diameter was less than 12 mm or when the interpedicular distance was less than 20 mm or when the cross-sectional area of the spinal canal was less than 1.5 cm<sup>2</sup> [1, 7, 13].

Facet degeneration was diagnosed when osteophyte and cyst formation, joint space narrowing and subchondral sclerosis were observed [11].

Disc degeneration was defined as decreased distance between the vertebral end plates, spur formation and sclerosis of the end plates [14].

## Results

In the study population of 350 individuals an LSTV was found in 53 subjects (15%). This group included 21 men and 32 women ranging in age from 23 to 85 years, with a mean age of 47.3 years. In the remainder of this paper, subjects with an LSTV will be referred to as 'patients'. The remaining 297 individuals suffered low back pain and/or sciatica, but did not have an LSTV. This group included 152 men and 145 women. They ranged in age from 18 to 88 years with a mean age of 45.5 years. These subjects will be referred to as the 'control population'.

A comparison of abnormalities detected by CT in spines with and without transitional vertebrae is presented in Table 1.

Except for nerve root canal stenosis, we could identify no higher incidence of structural problems in patients with than in those without an LSTV. Intervertebral disc protrusion and/or extrusion, disc degeneration, facet degeneration and spinal stenosis were diagnosed in a remarkably similar proportion of cases. Although the absolute overall incidence of structural pathology between the two groups was comparable, the location was notably different.

**Table 1** Incidence of degenerative spine pathology in patients with and without a lumbo-sacral transitional vertebra (LSTV)

	With LSTV (n = 53)	Without LSTV (n = 297)	P-value <sup>a</sup>
Disc protrusion and/or extrusion	27 (50.9%)	160 (53.9%)	NS
Disc degeneration	27 (50.9%)	132 (44.4%)	NS
Facet degeneration	30 (56.6%)	144 (48.5%)	NS
Nerve root canal stenosis	32 (60.4%)	118 (39.7%)	P = 0.006
Spinal stenosis	9 (17.0%)	58 (19.5%)	NS
No abnormality	9 (17.0%)	35 (11.8%)	NS

<sup>a</sup> Based on two-tailed Fisher's exact test. Level of significance set at  $P = 0.05$

First we analysed the level of disc protrusion and/or extrusion (Table 2). In patients without an LSTV, disc protrusion and/or extrusion was noted at a variety of levels between L3 and S1 and especially at the levels L4-L5 (30.3%) and L5-S1 (35%). In patients with an LSTV, two trends were apparent. First, in no case was a protruded or extruded disc observed at the interspace between the LSTV and the sacrum. Second, the incidence of disc protrusion and/or extrusion was higher at the interspace immediately above the LSTV (45.3%) than at any other level (18.9% at L4-L5 and 0% at L5-S1). An example is shown in Fig. 2.

Disc and facet degeneration (Tables 3, 4) was also noted to occur with much greater frequency immediately above the transitional vertebra. Nerve root canal stenosis (Table 5) was also noted to be much more common at the interspace above the LSTV (52.8%). By contrast, in patients without LSTV, nerve root canal stenosis was observed at a variety of levels in the lower lumbar spine.

We could not find a significant difference in the distribution of spinal stenosis between the two groups (Table 6).

## Discussion

Sacralization or lumbarization of a transitional vertebra can only be ascertained by counting all the vertebral bodies, beginning at the cranio-cervical junction (C0). Since on a CT examination the entire spine is not visualized, it is not always possible to accurately identify the fifth lumbar vertebra. Standard practice has been to count cephalad, beginning with the presumed L5 vertebra at the lumbo-sacral promontory. This practice may result in in-

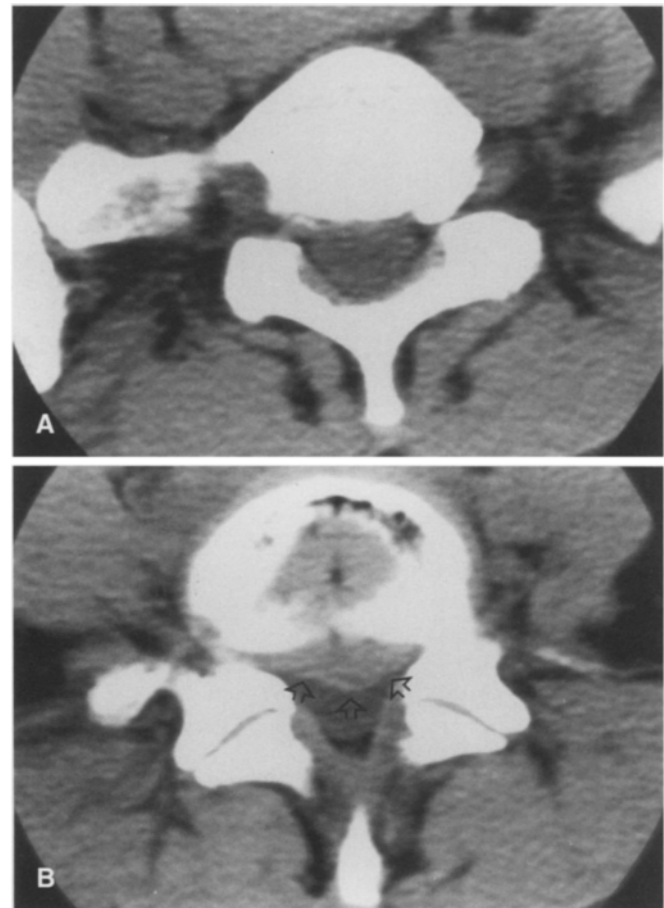
**Table 2** Location of disc protrusion and/or extrusion in patients with and without an LSTV

Level <sup>a</sup>	With LSTV (n = 53)	Without LSTV (n = 297)	P-value
L3-L4	10 (18.9%)	13 (4.4%)	$P < 0.001$
L4-L5(TV)	24 (45.3%)	90 (30.3%)	$P = 0.039$
L5(TV)-S1	0 (0%)	104 (35.0%)	$P < 0.001$

<sup>a</sup> The LSTV was considered to be in the L5 position, regardless of the absolute count in the vertebral column

accurate numbering of vertebrae, and hence erroneous localization of disc pathology [5].

Radiographic abnormalities such as transitional vertebrae have been commonly cited as significant findings in patients with low back pain. However it has been stated that this condition is of no relevance to back pain [8].



**Fig. 2** Axial CT scans in a patient with an LSTV. **A** Axial CT scan through the level of the LSTV. The right transverse process of the LSTV articulates with the sacrum. **B** Axial CT scan through the intervertebral disc above the LSTV. A large central to left paramedian disc protrusion is apparent (open arrows). The protruding disc material causes a focal impression on the anterior surface of the dural sac. Note the degeneration of the intervertebral disc as evidenced by the presence of vacuum signs

**Table 3** Location of disc degeneration in patients with and without an LSTV

Level	With LSTV (n = 53)	Without LSTV (n = 297)	P-value
L3-L4	16 (30.2%)	68 (22.9%)	NS
L4-L5(TV)	28 (52.8%)	83 (28.0%)	$P < 0.001$
L5(TV)-S1	1 (1.9%)	118 (39.7%)	$P < 0.001$

**Table 4** Location of facet degeneration in patients with and without an LSTV

Level	With LSTV (n = 53)	Without LSTV (n = 297)	P-value
L3-L4	22 (41.5%)	87 (29.3%)	NS
L4-L5(TV)	32 (60.4%)	127 (42.8%)	$P = 0.024$
L5(TV)-S1	10 (18.9%)	136 (45.8%)	$P < 0.001$

**Table 5** Location of nerve root canal stenosis in patients with and without an LSTV

Level	With LSTV (n = 53)	Without LSTV (n = 297)	P-value
L3-L4	9 (17.0%)	18 (6.1%)	$P = 0.011$
L4-L5(TV)	28 (52.8%)	83 (27.9%)	$P < 0.001$
L5(TV)-S1	7 (13.2%)	76 (25.6%)	NS

**Table 6** Location of spinal stenosis in patients with and without an LSTV

Level	With LSTV (n = 53)	Without LSTV (n = 297)	P-value
L3-L4	5 (9.4%)	24 (8.1%)	NS
L4-L5(TV)	5 (9.4%)	43 (14.5%)	NS
L5(TV)-S1	1 (1.9%)	7 (2.4%)	NS

The results of our study indicate that there is no significant difference in the overall incidence of degenerative changes of the lumbar spine between patients with and those without transitional vertebrae.

However, when degenerative changes do occur, they are found more often suprajacent to the LSTV. This implies that on CT examinations of the lumbar spine, findings such as intervertebral disc protrusion and/or extrusion, disc degeneration, facet degeneration and spinal stenosis are seen more often at the suprajacent level. These findings are in agreement with a previous study by Elster, who found that disc bulge or herniation, when it occurs, is nearly nine times more common at the interspace immediately above the transitional vertebra than at any other level [3].

From a mechanistic point of view, this greater incidence of degeneration could be attributed to the relative hypermobility of the disc above an LSTV. This is analogous to the hypermobility seen in spinal segments adjacent to block vertebra [2]. The disc space below an LSTV is often vestigial and devoid of nuclear material and is rarely the site of pathological alteration or degeneration [9]. Regarding nerve root canal stenosis, we could not find a significant difference between the two groups. The reason for this remains unclear.

## Conclusions

LSTV are predisposed to a unique pattern of problems. Despite their high prevalence little is known about their biomechanics. In our study population (patients with low back pain and/or sciatica) the overall incidence of degenerative changes did not differ very much between patients with and those without LSTV. However, when an LSTV is present, degenerative changes (including disc protrusion, disc extrusion, disc degeneration, facet degeneration and nerve root canal stenosis) are more common at the disc space suprajacent to the LSTV. So an LSTV constitutes a risk factor for degenerative changes at the suprajacent level. One can postulate that hypermobility and altered stresses become concentrated at the level immediately above an LSTV. Long term follow-up studies in adolescents and young adults would be necessary to estimate the added risk for early degenerative changes in LSTV.

## References

- Eisenstein S (1983) Lumbar vertebral canal morphometry for computerized tomography in spinal stenosis. *Spine* 8: 187-191
- Elster AD (1984) Quadriplegia after minor trauma in the Klippel-Feil syndrome. *J Bone Joint Surg [Am]* 66: 1473-1474
- Elster AD (1989) Bertolotti's Syndrome Revisited. Transitional vertebrae of the lumbar spine. *Spine* 14: 1373-1377
- Elster AD, Jensen KM (1985) Computed tomography of spondylolisthesis: patterns of associated pathology. *J Comput Assist Tomogr* 9: 867-874
- Hahn PY, Strobel JJ, Hahn FJ (1992) Verification of lumbosacral segments on MR images: identification of transitional vertebrae. *Radiology* 182: 580-581
- Jensen MC, Brant-Zawadzki MN, Obuchowski N, Modic MT, Malkasian D, Ross JS (1994) Magnetic resonance imaging of the lumbar spine in people without back pain. *N Engl J Med* 331: 69-73
- Lee BCP, Kazam E, Newman AD (1978) Computed tomography of the spine and spinal cord. *Radiology* 128: 95-102

- 
8. Nachemson AL (1970) The lumbar spine – an orthopaedic challenge. *Spine* 1: 59–71
  9. Nicholson AA, Roberts GM, Williams LA (1988) The measured height of the lumbosacral disc in patients with and without transitional vertebrae. *Br J Radiol* 61: 454–455
  10. Rosenberg NJ (1975) Degenerative Spondylolisthesis. Predisposing factors. *J Bone Joint Surg [Am]* 57: 467–473
  11. Siegle RL (1986) *Imaging in internal medicine*. Little, Brown, Boston, p 171
  12. Southwood JD, Bersack SR (1950) Anomalies of the lumbosacral junction in 550 patients without symptoms referable to the low back. *AJR* 64: 624–634
  13. Ullrich CG, Binet EF, Sanecki MG, Kieffer SA (1980) Quantitative assessment of the lumbar spinal canal by computed tomography. *Radiology* 134: 137–143
  14. Weismann BNW, Sledge CB (1986) *Orthopedic radiology*. Saunders, Philadelphia, pp 298–301