

N. Boos  
J. K. Webb

## Pedicle screw fixation in spinal disorders: a European view

Received: 6 November 1996  
Accepted: 9 December 1996

**Abstract** Continuing controversy over the use of pedicular fixation in the United States is promoted by the lack of governmental approval for the marketing of these devices due to safety and efficacy concerns. These implants have meanwhile become an invaluable part of spinal instrumentation in Europe. With regard to the North American view, there is a lack of comprehensive reviews that consider the historical evolution of pedicle screw systems, the rationales for their application, and the clinical outcome from a European perspective. This literature review suggests that pedicular fixation is a relatively safe procedure and is not associated with a significantly higher complication risk than non-pedicular instrumentation. Pedicle screw fixation provides short, rigid segmental stabilization that allows preservation of motion segments and stabilization of the spine in the absence of intact posterior elements, which is not possible with non-pedicular instrumentation. Fusion rates and clinical outcome in the treatment of thoracolumbar fractures appear to be superior to that achieved using other forms of treatment. For the correction of spinal

deformity (i.e., scoliosis, kyphosis, spondylolisthesis, tumor), pedicular fixation provides the theoretical benefit of rigid segmental fixation and of facilitated deformity correction by a posterior approach, but the clinical relevance so far remains unknown. In low-back pain disorders, a literature analysis of 5,600 cases of lumbar fusion with different techniques reveals a trend that pedicle screw fixation enhances the fusion rate but not clinical outcome. The most striking finding in the literature is the large range in the radiological and clinical results. For every single fusion technique poor and excellent results have been described. This review argues that European spine surgeons should begin to back up the evident benefits of pedicle screw systems for specific spinal disorders by controlled prospective clinical trials. This may prevent forthcoming medical licensing authorities from restricting the use of pedicle screw devices and dictating the practice of spinal surgery in Europe in the near future.

**Key words** Pedicle screw fixation · Fusion rate · Outcome · Indications · Review

N. Boos (✉)  
Orthopaedic University Hospital,  
Balgrist, Forchstrasse 340,  
CH-8008 Zürich, Switzerland  
Tel. +41-1-386 11 11;  
Fax ++41-1-386 1609;  
e-mail: 76322.3506@compuserve.com

J. K. Webb  
Centre for Spinal Studies and Surgery,  
University Hospital,  
Queens Medical Centre, Nottingham, UK

### Introduction

In the United States, debate continues over the clinical effectiveness and safety of pedicular screw fixation for spinal

disorders. However, the controversy is predominantly linked to the problem of Food and Drug Administration (FDA) approval of these implants [50]. In recent years, extensive efforts have been made to demonstrate the safety and effectiveness of pedicular screw fixation in the United

States. Based on the results of the “Historical cohort study of pedicular fixation in thoracic, lumbar and sacral spinal fusions” [191], the representatives of the major North American spine societies clearly advocate the use of pedicular fixation for specific indications (e.g., trauma, degenerative spondylolisthesis). Nevertheless, no FDA approval for pedicular bone screws has been granted because no valid scientific evidence has so far been provided for the safety and efficacy of these implants [189].

The European practice of medicine, and specifically surgery, differs from the dominant North American concept. The fallacy that only one uniform approach is possible may lead to regulations that have nothing to do with patients’ requirements [2]. In Europe, pedicular fixation systems have become the state of the art implants to instrument an unstable spine, to facilitate deformity correction, and to enhance spinal fusion. The discrepancy between the widespread acceptance of pedicular fixation in Europe and the ongoing discussion associated with their use in the United States is striking. The reason for this may be based only on legal issues, since the American spine societies are in favor of these devices for specific indications. On the other hand, one has to ask whether the missing legal constraints may not have led to a less critical application of these devices in Europe.

Recent comprehensive reviews on pedicular systems have alluded to their role in spine surgery from an American perspective [27, 37, 50, 119, 175, 191]. However, these reviews may be biased because of the requirement to achieve FDA approval [191]. It appears therefore reasonable to consider the historical evolution of pedicular fixation systems, the rationales for their application, and the clinical outcome from a European perspective.

---

## Historical evolution

Pedicle screw fixation has its origins in Europe. In the medical literature, Raymond Roy-Camille [141] is widely credited with the first application of screws through the pedicles of the vertebrae [103]. From 1963, Roy-Camille used pedicle screw plates with clinical success. The technique was first applied to the treatment of fractures, and its use was later extended to vertebral malunions, tumors, spondylolisthesis, and low-back pain disorders [142]. After initial experience, Louis and Maresca [104, 105] modified Roy-Camille’s implant and technique better to fulfill the requirement for stabilization of the lumbosacral junction. In 1986, Louis [103] summarized his experience with this technique reviewing 455 patients. The rate of solid fusion was 97.4% in single-stage posterior procedures and 100% in patients treated by a combined approach. Only six patients (1.3%) sustained neurological compromise due to a misplaced pedicular screw, which subsided after screw removal. In the United States, Harrington was the first to use pedicle screws to reduce and

stabilize high-grade spondylolisthesis [58, 59]. The pioneering work of Fritz Magerl [112, 113] introduced the concept of angle-stable pedicular fixation, which provided the basis for short-segmental stabilization of fracture/dislocation of the thoracolumbar spine. This concept led to the development of the first new generation pedicular fixation system, the AO internal fixator [33, 34, 36]. At the same time, Steffee used standard AO neutralization plates with cancellous bone screws in the pedicles for the reduction and stabilization of degenerative spondylolisthesis [164]. The fixed holes in the AO plates made multi-level insertion difficult and led to the final development of the variable screw plates (VSP), which allowed for an angle-stable screw fixation. A further milestone in the development of pedicular fixation systems was the introduction of a new screw-rod system by Yves Cotrel and Jean Dubouset [26], which has become a widely used versatile instrumentation system in spinal surgery during the last 10 years.

The work of these pioneers, the compelling concept, and its initial clinical success formed the basis for the development of a wide variety of similar spinal fixation systems.

---

## Rationales for pedicle screw fixation

The primary goal of internal fixation of the spine is to correct deformity and to stabilize the spine until solid fusion has occurred. The rationale for choosing the pedicle as the primary site for screw anchorage to achieve these goals arises from anatomic as well as from biomechanical factors.

The application of pedicle screws was based on the rationale that the pedicle is the strongest site accessible posteriorly through which a three-dimensional rigid fixation of the vertebra can be obtained [141]. The early anatomic studies by Saillant [144] first established that the diameter and structure of the pedicle is large enough in the lumbar and lower thoracic spine to allow anchorage of vertebral screws via the transpedicular route. These results were later confirmed by other researchers, and there is now convincing evidence regarding pedicle morphology to verify this view [67, 82, 88, 116, 129, 149, 176, 193].

Transpedicular screw fixation provides a firm anchorage of the screws to the vertebral body. This anchorage enables a secure three-dimensional positional control between the screw and the longitudinal elements, which can provide a restoration of normal stiffness even in short segmental (i.e., one- or two-level) instrumentation. Biomechanical testing of screw pull-out has provided further convincing evidence that this anchorage site fulfills its expectations [86, 87, 100, 128, 184]. The biomechanical aspects of this type of spinal stabilization have been comprehensively summarized in a recent book chapter [86] and do not need further supplementation here.

Depending on the indication, the rationales for the application of pedicle screw systems vary among the different spinal pathologies.

## Spinal fractures

The goals of the treatment of spinal fractures are fracture reduction, spinal canal decompression, and rigid stabilization of the spine to allow early mobilization. The improvement in positional control of the anterior column by posterior pedicular instrumentation allows reduction of displaced, fractured vertebrae even if the posterior elements are injured [3, 34, 41]. The ability to restore the normal height of the fractured vertebra by distraction can lead to spinal canal clearance by ligamento-taxis, but bone remodeling with time appears to be a more important factor [51]. In thoracolumbar burst fractures, a thoraco-abdominal approach for an anterior decompression is therefore often not required [3, 34, 41]. Experimental and clinical studies [40, 121] have indicated the requirement for an anterior buttress despite pedicle screw fixation to avoid implant failure and loss of correction. Grafting of the vertebral body by a transpedicular route in conjunction with pedicular screw fixation may provide a valid alternative to anterior surgery [29, 98]. The possibility of rigid, short segmental stabilization overcomes the disadvantage of the distraction-type implants (e.g., Harrington instrumentation), which necessitate the inclusion of two or three levels above and below the injured vertebra [4, 38, 45, 145].

## Tumors and infection

The advantages of pedicle screw fixation in tumors or infection is based on the three-dimensional positional control and the rigid fixation. These spinal disorders often require a complete vertebrectomy and reconstruction of the anterior column. If anterior instrumentation is not sufficient (e.g., in tumor cases) or not desired (e.g., in spondylitis), combining it with posterior pedicular fixation allows a very solid construct and permits limiting the instrumentation to only the involved levels [34, 117]. In palliative tumor surgery, pedicular stabilization permits posterior tumor decompression and debulking with regard to restoration or prevention of paraplegia [77, 114]. Thus, anterior surgery, which is often ill-advised in these patients, can be avoided.

## Scoliosis

In scoliosis, the classic concept of correction with Harrington instrumentation [39, 57, 125] is based on distraction of the concavity of the curve. Attempted segmental correction with the Luque sublaminar system [106, 107] only acts on the posterior elements, and the achieved derotation is only minimal [181]. Pedicular screw fixation allows for a transmission of the derotation force to the center of the vertebra and permits a true segmental scoliosis correction [1, 92]. Due to the decreasing pedicle diameter

in the upper thoracic spine [176], pedicle screws are combined with hooks or, as a further development, pedicle hooks with screw fixation [7]. A disturbing complication of Harrington instrumentation was the development of a flatback syndrome due to the reduction in thoracic kyphosis and lumbar lordosis by distraction [89, 125]. This disadvantage can be avoided with screw- or hook-rod systems, which allow for contouring in the sagittal plan. The rod derotation maneuver, which is an essential part of scoliosis correction with CD instrumentation [25, 26] has been shown to result sometimes in trunk decompensation [19, 95, 170, 187]. Theoretically, the use of pedicle screws at the lower end vertebra may limit the rotational force transmitted to the lumbar spine. A further advantage of pedicular fixation is that a violation of the spinal canal can be avoided – a potential hazard with sublaminar wiring techniques, particularly in degenerative disorders [84].

## Spondylolisthesis

Since the first description of this procedure by Harrington [59], pedicle screws have been used to reduce high-grade spondylolisthesis. Reduction of spondylolisthesis by the means of pedicular fixation has now become very popular, particularly in Europe [35, 105, 120, 142, 148, 151]. Although it was hoped that pedicle screw fixation would allow reduction and stabilization of high-grade spondylolisthesis by a single-stage posterior approach [18], it became increasingly clear that this approach is associated with high rates of implant failure, loss of reduction, and non-union [5, 14]. However, pedicular fixation of spondylolisthesis without reduction, or with reduction in conjunction with an anterior fusion, provides high success rates and limits the instrumentation and fusion to only one or two levels [5, 11, 35, 105].

## Low-back pain

In low-back pain disorders, pedicular screw fixation allows a rigid segmental stabilization of the vertebral segments even in the absence of posterior elements (e.g., after laminectomies). Therefore, these devices should be beneficial where the treatment goal is to achieve solid fusion. Pedicle screw fixation for this indication is the most widely used application, but at the same time also the most controversial. One prospective randomized study provided clear evidence of an improved fusion rate and outcome with pedicle screw fixation [192]; however, there is still not sufficient scientific evidence to demonstrate that the clinical results with pedicular stabilization are superior to the results for alternative forms of treatment in low-back pain disorders.

These theoretical advantages and technical possibilities of pedicular screw fixation have to withstand their test

in clinical practice. The current literature will be reviewed in order to answer the question of whether these advantages also lead to a better treatment outcome without increasing the risk of complications.

---

## Complications and safety

The major concern with pedicle screw fixation is related to the safety of these devices. However, it is very important to differentiate between device-related and surgical complications. Device-related complications include screw and rod breakage, screw loosening, screw pull-out, connector slippage, and loss of correction due to implant failure. The surgical complication often used as an argument against pedicle screws is neural injury due to a misplaced screw. The goal of correct positioning is to aim the screw from anatomic landmarks on the posterior elements through the pedicular tube into the vertebral body without perforating the bone. This is certainly not an easy task for the inexperienced surgeon. However, the results in the literature demonstrate that the risk is minimal in the hands of experienced spine surgeons [103, 143, 159, 192]. The potential risk of neurological damage to the spinal cord or nerve roots is also encountered with hook-rod system or Luque instrumentation. In a meta-analysis of the literature on the treatment of unstable spinal fractures [37], the rate of neurological injury (1.1% vs 2.3%, weighted proportion) and dural tears (0.16% vs 1.2%, weighted proportion) were even higher for hook-rod than for pedicle screw systems. The overall complication rate in fractures [37] was similar for hook-rod systems (25%), anterior instrumentation (20%), Luque instrumentation (25%), and pedicle screws (27%). However, half the complications with pedicular fixation were caused by screw breakage without clinical consequences.

In a comprehensive literature review, Yahiro [188] analyzed 101 articles reporting the results of 5,756 patients treated with pedicular fixation devices for a wide variety of spinal disorders. There were 65 dural tears (1.1%), 99 neural injuries or neurological deficits (1.7%), 41 patients with broken pedicle screws (7.1%), 12 patients with broken rods (0.2%), and 146 malpositioned pedicle screws (2.5%). The reported non-union rate was 5.2% (205 patients).

A selective survey of the members of the American Back Society (13 surgeons, 617 cases) investigated the rate of complications in the treatment of a large variety of spinal disorders with pedicle screw fixation. The survey found a permanent neurological nerve injury in 2.3%, transient neuropraxia in 2.4%, screw breakage in 2.9%, and deep infection rate in 4.2% of the cases [42].

A total of 314 surgeons participated in the "Historical cohort study on pedicle screw fixation" (see below), of whom 95% submitted 30 or fewer cases [191]. This study can therefore be assumed to provide a more realistic real-

life use of pedicular devices [189] than reports written by fellow specialists. The results of this study demonstrated that the risk of neurological injury is less than 0.5%, which is indeed very low considering the fact that most surgeons appeared not to have extensive experience. The infection rate was virtually the same for pedicular as for non-pedicle screw fixation of fractures (2.8% vs 2.8%) and for pedicular fixation as for uninstrumented fusion of degenerative spondylolisthesis (2.6 vs 2.4%).

Based on the literature, which provides a large number of cases for an assessment, there is sufficient evidence that the use of pedicular fixation does not result in a complication rate that is substantially different from those associated with non-pedicle devices.

---

## Current applications and clinical outcome

The current applications and the outcome of pedicle screw fixation in the treatment of spinal disorders will be reviewed to provide a basis for further discussion of the clinical efficacy of these devices.

### Thoracic and lumbar fractures

The literature on the treatment of thoracolumbar fractures with and without pedicle screw instrumentation has been recently reviewed. Dickman et al. [37] retrieved 58 articles from the literature containing demographic and outcome data on spinal fractures ( $n = 2,072$ ). Pedicle screw, hook-rod, anterior, and Luque instrumentation were compared with regard to fusion rate, complications, and functional outcome. The authors argued that a meta-analysis cannot substitute for well-designed, prospective, randomized controlled trials [37], but that some conclusions could be supported by the data. The fusion rates for pedicular fixation (99.4%) were significantly higher than those for anterior instrumentation (94.8%) and hook-rod devices (96.9%). No significant difference was found with regard to Luque instrumentation, because of the small numbers in that group. In terms of satisfactory pain and functional outcome, pedicular screw fixation (87.0%) and 85.3% was not significantly different from hook-rod systems (90.6% and 80.0%) and anterior instrumentation (85.8% and 74.8%). Further differentiation of the reported clinical data was not possible because of inherent differences in clinical and neurological severity as well as between treatment groups [37].

As a result of the shortcomings in the existing literature, the "Historical cohort study of pedicle screw fixation in thoracic, lumbar and sacral spinal fusions" [191] was launched by a scientific committee under the auspices of the FDA, consisting of representatives of the major American societies with an interest in spine surgery (North American Spine Society, Scoliosis Research Society, American

Academy of Orthopaedic Surgeons, American Association of Neurological Surgeons, Congress of Neurological Surgeons, and Spinal Implant Manufacturer's Group). An open, non-blinded, historical cohort study was designed to recruit surgeons to collect data on patients who had undergone spinal fusions using pedicular fixation for the treatment of fractures or degenerative spondylolisthesis during a 2-year period (1990–1991) with a 2-year follow-up. Results of the treatment with non-pedicle fixation fitting the inclusion criteria were collected as a concurrent control group. The pedicle screw group consisted of 814 patients with fractures and the control group (non-pedicular fixation) of 215 patients. The time-adjusted rates of fusion in the two groups were 88.4% and 86.3%, respectively. This difference was not statistically significant. The rate of intraoperative and postoperative complications was not significantly higher for pedicular than for non-pedicular fixation devices. The most frequent screw-related event was screw fracture (6.7%), a complication that cannot be encountered with non-pedicular devices. The reoperation rate was 23.4% in the pedicular and 19.4% in the non-pedicular group, the major contributor being implant removal in both groups. In terms of the functional and pain outcome, the results appeared to be slightly better in the non-pedicular group. However, it was noted that the pedicle screw group included more patients with prior back surgery and burst fractures, which may have influenced the results.

A substantial difference between the pedicular and non-pedicular fixation group, which is not reflected in the outcome variables, is the level of fixation. Yuan et al. [191] reported that more than 75% of the patients with non-pedicular fixation had more than two spinal levels instrumented and fused, compared with less than 30% of patients with pedicular stabilization. Considering the fact that in both groups, 95% of the patients had only a single-level injury, the advantage of pedicle screw devices in immobilizing and fusing fewer motion segments is evident. However, this advantage does not find a direct reflection in the outcome scales and its clinical relevance therefore remains unknown.

The current literature supports the conclusion that pedicle screw fixation of thoracic and lumbar fractures is an effective treatment compared to non-pedicular instrumentation and provides at least equal clinical results.

## Scoliosis

*Adolescent idiopathic scoliosis.* The era of the widespread use of internal fixation began with the introduction of Harrington instrumentation for adolescent idiopathic scoliosis (AIS). In 1982, Luque introduced his system of segmental spinal fixation and reported very favorable results [106, 107]. The second generation of spinal instrumentation for scoliosis began with Cotrel-Dubouset (CD) in-

strumentation [25, 26]. This system is now widely used for the treatment of AIS. The fusion rate and outcome with these techniques is in general very favorable. The faculty of the North American Spine Society and Scoliosis Research Society pedicle fixation workshop [27] therefore reached a general consensus that pedicular fixation does not provide substantial improvements in the treatment of AIS.

However, pedicular fixation in AIS has some theoretical advantages which will be discussed here. The rationale for a combination of hooks in the thoracic spine and pedicle screw fixation in the thoracolumbar and lumbar spine is to improve the rigidity of the fixation and the amount of correction. Suk et al. [166] studied 78 AIS patients treated with CD instrumentation: 31 were instrumented with hooks only; 23 with pedicle screws inserted in a hook pattern; and 24 were treated with segmental pedicle screws. After a minimum follow-up of 2 years (range 25–52 months), major curve correction was 55% with hooks, 66% with hook pattern screws, and 72% with segmental screws, with loss of correction of 6%, 2%, and 1%, respectively. Compensatory curve correction was 57% with hooks, 67% with hook pattern screws, and 70% with segmental pedicle screws. In patients with hypokyphosis, all showed significant improvement, with best restoration among those with segmental screw fixation. Rotational correction of the apical vertebra measured by the Perdriolle method was 19% with hooks, 26% with hook pattern screws, and 59% with segmental screws. Thirteen screws (3%) were malpositioned, but they did not cause neurological impairment or adversely affect the results of treatment. The authors concluded that segmental pedicle screw fixation is a safe and effective method for correcting the triplanar deformity of idiopathic thoracic scoliosis.

The third generation of instrumentation systems, e.g., the AO universal spine system (USS), provides the opportunity for direct segmental derotation [92]. Theoretically, this should lead to improved three-dimensional deformity correction and result in a better cosmetic outcome. Preliminary results from our own center demonstrate that CD and USS instrumentation with pedicle screws result in a better deformity correction (as indicated by apical rotation and surface measurements) than Harrington or Luque instrumentation (Cole, Webb, and Burwell, work in progress). There is no evidence in the literature suggesting a substantially higher complication or failure rate for pedicle screw systems than for established methods (Harrington instrumentation, Luque instrumentation, or CD instrumentation with hooks). Therefore, further investigations on pedicle screw devices are justifiable and necessary to assess their potential benefits more comprehensively in the long term.

*Neuromuscular scoliosis.* An accepted form of treatment of neuromuscular scoliosis is segmental fixation with sublaminar wiring, which allows satisfactory curve correction

with a predictable outcome and an acceptable complication rate [9, 109]. In myelo-meningocele, however, the posterior elements are absent, which causes problems with the stabilization of the distal part of the curve, and the instrumentation relies only on the sacral fixation. Single-stage anterior or posterior procedures carry a substantial risk of failure [158, 179] and a combined anterior and posterior procedure is recommended [6, 123]. However, this necessitates a more extensive surgical approach in these children and enhances the complication rate. Pedicular fixation is advantageous since it allows a secure screw anchorage in the lumbar pedicles and sacrum despite absent posterior elements. However, there are no substantial data available to allow a statement on the clinical relevance of pedicular fixation in neuromuscular scoliosis.

### Kyphosis

A similar situation is encountered in the correction of idiopathic kyphosis (i.e., Scheuermann's disease). The anchorage of the instrumentation construct with screws in the lower end vertebra is reasonable in order to achieve a more secure fixation, but the relevance remains inadequately documented in the literature. The correction of kyphosis in ankylosing spondylitis often requires osteotomies and necessitates a rigid segmental fixation to maintain the correction [152]. Compared with all other posterior instrumentation systems, pedicular fixation is best suited to provide this stability. The largest reported series of thoracolumbar osteotomies employed pedicular fixation to stabilize the spine after osteotomy [62]. Hehne et al. [62] reported on the correction of 177 cases of kyphotic deformity in ankylosing spondylitis. Instead of a dangerous short kinking osteotomy, they suggested a polysegmental lordosis osteotomy of the lumbar spine in four to six segments using pedicular fixation and threaded rods in eight to ten segments. Of 177 patients undergoing the operation, there was a 2.3% mortality rate with cardiopulmonary problems, 2.3% suffered irreversible complications, and 18.1% suffered reversible complications, mostly small root lesions, of which 7% were reoperated. The 173 surviving patients had a mean correction of 43% and improvement in body height of 9 cm. Fifty-three of the patients were followed or more than 18 months and did not have any radiological evidence of non-union. Ninety-two percent were pain free compared with 15% before the operation. The authors concluded that the surgical potential of pedicle screw systems in the correction of angular kyphosis is superior to that of any other posterior instrumentation system. However, data in the literature on the surgical treatment of kyphosis with pedicular fixation [10, 62, 66, 117, 180] are sparse. It is not yet feasible to establish whether pedicular systems are superior to other devices in terms of clinical outcome.

### Spondylolisthesis

Pedicular fixation provides a rigid segmental fixation of the spine. The greatest benefit of these systems should therefore be obtained in cases with underlying instability. Most authors agree that instability is a significant factor in symptomatic high-grade spondylolisthesis. These patients should therefore clearly benefit from fusion and the fusion rate should increase using rigid internal fixation. There is sufficient evidence in the literature that fusion in situ is a safe and relatively reliable procedure for the treatment of high-grade spondylolisthesis, providing satisfactory long-term results [48, 61, 63, 64, 73, 75, 135, 136, 150, 155]. However, several authors [16, 35, 105, 120, 124, 148, 151, 177] have suggested that reduction of severe anterior displacement and correction of lumbosacral kyphosis may prevent some of the drawbacks of fusion in situ such as high incidence of non-union [15, 91, 174], bending of the fusion mass [15, 48, 61, 150], persistent lumbosacral deformity [15, 48, 73], or development of secondary cauda equina syndrome after fusion [147]. In contrast to the older distraction implants [17, 32, 60, 108], modern pedicular fixation systems theoretically provide the opportunity to reduce and stabilize high-grade spondylolisthesis via a single-stage posterior approach [18] without the requirement for additional anterior surgery. The current literature on the treatment of high-grade spondylolisthesis with pedicular screw fixation is still sparse. A few reports on this issue [5, 14, 163] suggest that the treatment of severe spondylolisthesis with reduction and stabilization via a single-stage posterior approach is associated with a high failure rate (non-union and implant failure). When the posterior approach is not combined with an anterior mechanical buttress, i.e., an additional anterior or posterior interbody fusion, the pedicular screws are exposed to excessive flexural loading. The consequence is fatigue failure with time that may result in a loss of reduction and non-union if the implant failure occurs prior to the maturation of the fusion mass. A comparison of the different surgical treatment options in terms of clinical outcome is difficult because of differing methods of assessment, and a further detailed analysis is therefore not feasible. The rate of good and excellent results without pedicular fixation ranges from 56% [61] to 100% [135]. Despite the shortcomings of varying outcome assessments, it appears that pedicular fixation [5, 14, 105, 120, 148] provides clinical results that at least equal those of established treatment forms [16, 18, 61, 135].

One disadvantage of the previous surgical treatment options is the cumbersome aftertreatment and the often long hospitalization time [18, 61]. Pedicular fixation is favorable with regard to early mobilization without the need for disturbing external supports, which shortens the hospitalization time. In addition, inclusion of healthy segments within the instrumentation [32, 58, 108] is no longer necessary. In this context, pedicle screw fixation is a major

improvement on both fusion without instrumentation and stabilization with one of the older instrumentation systems.

### Tumors and infection

In spinal tumors or infections that require surgery, the presentation is often a compression of neural structures. The neural compromise requires extensive surgical decompression, which often jeopardizes the stability of the spine. A further presentation is in the form of a painful kyphotic deformity, which requires a reconstruction of the spinal column. The advantage of pedicular fixation in this situation is that it provides a rigid and stable fixation that requires only the inclusion of a few (often only two) segments and preserves mobility, particularly in the lumbar spine [34, 77, 117, 122].

In thoracolumbar kyphotic deformity caused by a primary spinal tumor, solitary metastasis, or spondylodiscitis, a posterior correction and stabilization with pedicular screws in combination with an anterior vertebrectomy produces favorable results [34, 117]. However, the reported results predominantly focus on the technique and include only a very small number of patients, which precludes any reasonable analysis.

Magerl and Coscia [114] described a technique for a total posterior vertebrectomy in the thoracolumbar spine for metastasis. After the vertebrectomy, the spinal column is reconstructed with a methyl-methacrylate buttress for the anterior column and an angle-stable, rigid fixation with the AO internal fixator. This single-stage operative procedure provides sufficient stability to allow immediate postoperative mobilization and avoids the necessity for an additional anterior approach, which is often not well-tolerated by seriously ill patients. A similar approach is described by Steffee et al. [165]. McLain et al. [122] stressed the importance of achieving a reconstruction of the anterior spinal column despite the use of pedicular fixation. Implant failure had been a significant complication in their series because the anterior column disease had not been adequately addressed. Jónsson et al. [77] reported favorable results after limited posterior surgery for thoracolumbar metastasis. Surgery was confined to direct or indirect decompression via a posterior approach and stabilization with pedicular fixation over as few segments as possible. Nineteen of 25 non-ambulatory patients regained their walking ability. Nearly half of the total group of 51 patients attained improvement in functional performance and the vast majority experienced long-lasting effective pain relief.

Although very intriguing, further experience with these techniques is required before the clinical effectiveness in tumors and infection can be assessed in comparison with established forms of treatment.

### Low-back pain disorders

The application of pedicular fixation to enhance fusion rate and outcome in low-back pain disorders presently remains the most controversial issue with regard to the benefit of these systems. Some concerns arose with regard to the amount of rigidity that should be provided by pedicular fixation [184]. A further concern is that the systems are generally bulky and diminish the space for the actual bone graft.

In 1992, Turner et al. [173] reviewed the literature on patient outcome after lumbar spinal fusions. A total of 47 articles were retrieved that contained data appropriate for further analysis. The most important finding was the poor scientific quality of the articles on this topic. The meta-analysis by Turner reported a 73% solid fusion rate for anterior interbody fusion, 87.8% for posterior fusion, 89.0% for posterolateral fusion, and 94.5% for posterior lumbar interbody fusion. The rate for satisfactory clinical outcome was 65.8% for posterior fusion, 67.0% for anterior interbody fusion, 67.7% for posterolateral fusion, and 74.5% for posterior lumbar interbody fusion. There was no difference in clinical outcome according to whether or not instrumentation was used, but the effect of instrumentation on the fusion rates was not further detailed. However, Turner et al. only considered articles published before April 1991, and included only three papers that reported the use of pedicular fixation. Since then, a considerable number of articles on pedicle screw fixation and spinal fusion have been published and a reassessment is appropriate. From a Medline literature search (January 1966 to August 1995), 68 of 1,180 retrieved articles on the treatment of low-back pain disorders allowed the assessment of fusion rate and/or clinical outcome in terms of satisfactory (excellent, good) or unsatisfactory (poor) results. To allow a broad overview, no further inclusion or exclusion criteria were required. The articles were categorized with regard to different fusion techniques: anterior interbody fusion, posterolateral fusion, posterior lumbar interbody fusion, posterolateral fusion with non-pedicle systems, posterolateral fusion with pedicle screw systems, and posterior lumbar interbody fusion with pedicle screw fixation. There were not sufficient data to form an additional category for combined anterior and posterior fusion [85, 99, 132]. The average rates of fusion and satisfactory or unsatisfactory clinical outcome were calculated from the sum of absolute values reported in each article for the different techniques. We also calculated the values for unsatisfactory outcome, since more authors may agree on what comprises a poor result (e.g., persistent severe pain, no improvement, dependency on strong pain killers, inability to return to work, etc.). The authors want to stress some methodological drawbacks of this analysis: the review was based solely on a Medline search (some articles may therefore have been missed), there was no minimal follow-up, no minimum study population size, only a single reviewer

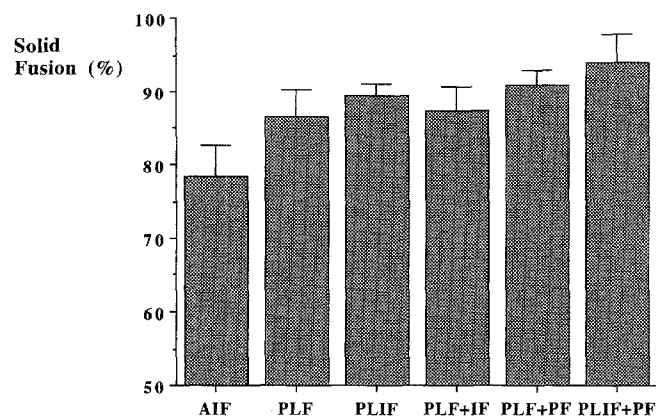
(N.B.), and no criteria for the quality of the outcome assessment for fusion and clinical results. This review should therefore not be regarded as an attempted meta-analysis, but only as an extensive literature review.

This literature analysis included 68 papers, which reported on a total of 5,601 cases. For a posterolateral fusion, pedicular screw fixation (Fig. 1, Table 1) increased the rate of solid fusion (91%) when compared with uninstrumented fusion (87%) or instrumented with non-pedicle systems (87%). The highest union rates were achieved when posterior lumbar interbody fusion was supplemented by pedicular fixation (94%). However, only two reports were retrieved that reported on this technique, which lim-

its a generalization. The lowest fusion rates were achieved using anterior interbody fusion (78%), with a range of 56% to 94%. The heterogeneity of the results is expressed in a relatively large standard error (Fig. 1). It was noted that uninstrumented posterior lumbar interbody fusion resulted in a very favorable fusion rate (89%).

In terms of satisfactory clinical outcome (Table 1, Fig. 2), there appears to be no clinically relevant difference according to whether posterolateral fusion is performed without instrumentation (70%), or instrumented with a non-pedicle system (65%) or with a pedicle screw system (68%). The worst clinical outcome was obtained when posterolateral fusion was combined with non-pedicular fixation (65%), which was surprising, but may be due to sampling errors and variations in outcome assessment. The rate of satisfactory results for anterior interbody fusion (76%) was better than that for posterior fusion regardless of whether it was instrumented or not. It was evident that posterior lumbar interbody fusion achieved a very favorable outcome in comparison with other techniques (82% and 88%). When considering unsatisfactory (poor) outcomes (Table 1, Fig. 3), the highest rate was for anterior interbody fusion (21%) and the lowest rates for posterior lumbar interbody fusion (11% and 12%) and posterolateral fusion with pedicle screw fixation (12%). A comparison of our results with those by Turner et al. [173] demonstrates similar trends and favors posterior lumbar interbody fusion in terms of radiological and clinical outcome.

The validity of the spinal literature is not increased by applying strict statistical criteria to soft clinical data. Rather than relying only on statistical analysis, we recommend a look at the graphic representation of the data, which should



**Fig. 1** Rates of solid fusion for different fusion techniques in low-back pain disorders, presented as mean and standard error of the mean (AIF anterior interbody fusion, PLF posterolateral fusion, PLIF posterior lumbar interbody fusion, IF internal fixation, PF pedicular fixation)

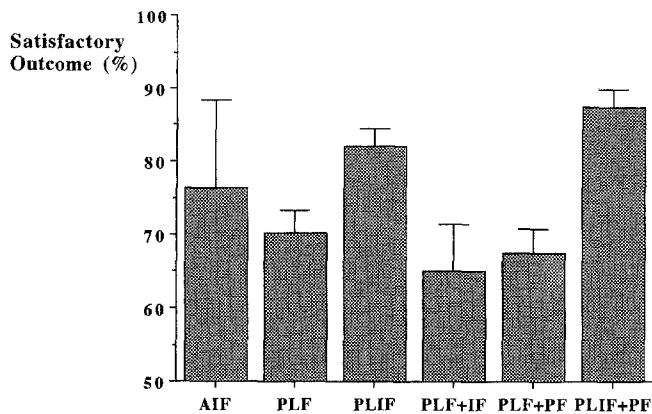
**Table 1** Literature analysis on the results of different fusion techniques in low-back pain disorders (AIF anterior interbody fusion, PLF posterolateral fusion, PLIF posterior lumbar interbody fusion, IF internal fixation, PF pedicular fixation)

Fusion technique	No. of studies	No. of cases	Solid fusion (%)		Satisfactory outcome <sup>a</sup> (%)		Unsatisfactory outcome <sup>b</sup> (%)		References
			Mean	Range	Mean	Range	Mean	Range	
AIF	10	1072	78.3	55.9–94.3	75.9	36.8–91.7	20.7	2.9–50.0	[22, 46, 47, 70, 101, 111, 138, 157, 160, 169]
PLF	16	1264	86.6	41.4–96.2	70.2	52.4–88.7	15.0	3.3–58.6	[8, 30, 31, 71, 83, 94, 102, 111, 140, 146, 161, 171, 172, 178, 192, 195]
PLIF	8	1372	89.4	81.5–94.1	82.0	77.8–98.0	10.9	2.9–13.0	[23, 24, 68, 69, 93, 97, 127, 137]
PLF + IF	10	463	87.4	63.9–98.5	65.2	55.9–95.0	15.9	0–30.0	[44, 49, 52, 72, 84, 118, 131, 167, 192, 195]
PLF + PF	22	1125	90.8	66.7–100	67.5	42.6–94.6	12.1	0–30.4	[8, 11, 13, 20, 78, 102, 110, 115, 117, 143, 156, 159, 168, 183, 185, 186, 190, 192, 194, 195]
PLIF + PF	2	305	93.8	87.0–91.7	87.6	87.0–91.7	12.4	8.3–13.0	[53, 162]

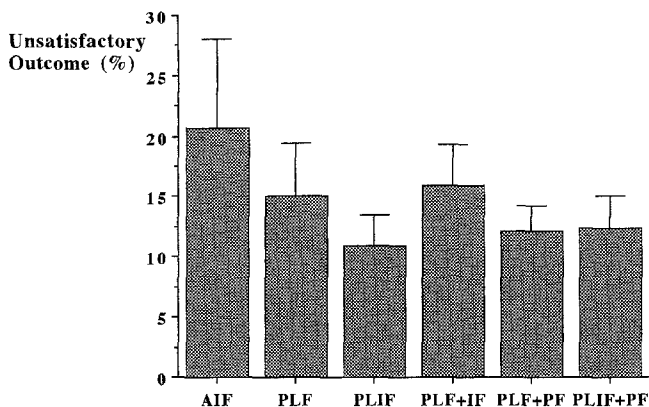
<sup>a</sup>Satisfactory outcome = good and excellent results

<sup>b</sup>Unsatisfactory outcome = poor results





**Fig. 2** Rates of satisfactory (good and excellent) outcome for different fusion techniques in low-back pain disorders, presented as mean and standard error of the mean



**Fig. 3** Rates of unsatisfactory (poor) outcome for different fusion techniques in low-back pain disorders, presented as mean and standard error of the mean

demonstrate clinically relevant differences (Figs. 1–3). It may be argued that the majority of the papers are of poor scientific quality. On the other hand, an analysis of 5,600 cases should at least reveal a trend in the results. This trend may indicate an increase in fusion rates using pedicular screw fixation. However, the improvement is only small and the clinical relevance therefore remains questionable. Based on our data, there is no evidence that pedicular fixation improves clinical outcome, despite an increased fusion rate. The best radiological and clinical results were achieved with posterior lumbar interbody fusion, which is an intriguing finding and deserves further attention.

There is a general consensus in the literature that the rate of successful uninstrumented spinal fusion significantly drops for two- or three-level fusions. Stauffer and Coventry [161] reported a 75% fusion rate for one-level and a 60% rate for two-level posterolateral fusions. Rombold [140] reported a decrease in the rate of solid posterolateral fusion from 96% (one-level) to 68% (two-level). The rates for one-level, two-level, and three-level anterior interbody fusion reported by Loguidice et al. [101] were

85%, 62%, and 50%, respectively. Chow et al. [22] reported a decrease from 85% for one-level to 48% for two-level anterior interbody fusions. The results in the literature show a trend that pedicular fixation is of particular benefit in multi-level fusions. Since instrumentation with these systems provides segmental fixation, most studies report that the high fusion rate seems similar for two- as for three-level fusions. Steffee [159] reported that the results for posterolateral fusion and instrumentation with variable screw plates are similar for one-, two- and three-level fusions (i.e., 93%, 92%, and 92%).

The success rate for lumbar spinal fusion is substantially dependent on the type of condition causing low-back pain. In most series on degenerative disorders that differentiate between diagnostic subgroups, spondylolisthesis is associated with a more favorable outcome than degenerative disc disease [71, 146, 183, 192]. The worst clinical outcome is generally obtained in cases of non-union [90, 183]. It is therefore reasonable to elucidate more closely the role of pedicular fixation in these specific diagnostic subgroups.

In symptomatic low-grade isthmic spondylolisthesis, patients do not present with severe lumbosacral malalignment and progressive slippage as in high-grade spondylolisthesis of children and adolescents, but mostly with moderate instability, nerve root entrapment, and secondary degenerative changes. The goals of treatment are here to relieve pain and reverse neurological deficit rather than to correct the deformity and to prevent progression of the slip. The literature features only a few papers that predominantly focus on the treatment of low-grade spondylolisthesis [11, 13, 21, 23, 56, 74, 79, 96, 105]. The fusion rates for posterolateral fusion without instrumentation vary between 67% [161] and 95% [96]. However, the fusion rates are less as good for two-level fusion [161]. Kaneda et al. [79, 80] and Hanley [54] reported that the fusion rate is enhanced to over 90% when the fusion is instrumented with distraction rods. However, the disturbing complication with distraction rods is decreased lumbar lordosis and inclusion of healthy motion segments. Furthermore, the stability of the fixation may be compromised if a laminectomy or a Gill's procedure is required. Therefore, pedicular fixation is advantageous, because it prevents progressive slippage following wide laminectomy as reported in the literature [65, 81, 134]. Compared to the aforementioned treatment, the high fusion rates (96%–100%) reported for pedicular fixation of low-grade spondylolisthesis are favorable [11, 13, 105]. The clinical results for all treatment forms vary widely between 60% [161] and 100% [105] satisfactory (excellent and good) results. Despite the increased fusion rate, the clinical outcome with pedicular fixation in low-grade spondylolisthesis (66% to 73% good results) appears not to have improved to the same extent [11, 13]. Pedicular fixation and posterolateral fusion for low-grade spondylolisthesis is favorable with regard to the high fusion rate and easy aftertreatment, but no bene-

fit is evident in the literature with regard to the clinical outcome.

Most patients with *degenerative spondylolisthesis* suffer back pain for a long time and cope with it fairly well. However, the predominant complaint of these patients, which often leads to surgery, relates to increasing symptoms from a central or foraminal spinal stenosis. Therefore, spinal decompression with or without fusion is the treatment of choice for this condition.

The treatment of degenerative spondylolisthesis has recently been reviewed in a meta-analysis [119] of the literature considering different treatment options (decompression without fusion, decompression with fusion, decompression with instrumented fusion, decompression with fusion with pedicular fixation, and anterior spinal fusion). A total of 25 papers reporting on 889 patients were included. There was statistical evidence that decompression with fusion provides a better clinical outcome than decompression alone (90% vs 69% good results). A further finding was that posterolateral fusion rates were enhanced by adjunctive spinal instrumentation (86% vs 96%), but no significant difference was found when comparing FDA Class II implants (i.e., Harrington rods, compression rods, Luque instrumentation) to pedicular fixation (96% vs 93%). There was no significant difference in terms of the clinical outcome (90% vs 86% satisfactory results). Device-related complications were comparable, and specific types of complications were unique to each implant [119].

Further information on the safety, efficacy, and effectiveness of pedicular bone screws in degenerative spondylolisthesis is available from the "Historical cohort study of pedicle screw fixation in thoracic, lumbar and sacral spinal fusions" [191]. A total of 2,684 cases of degenerative spondylolisthesis were contributed by 314 spine surgeons for the purpose of this study. In 2,176 cases, sufficient information on the fusion status was available. In 1,794 cases, an instrumented fusion with pedicular fixation was chosen to enhance the fusion rate. In the control group, 382 patients had decompression and uninstrumented fusion. Actuarial analysis, which generates time-adjusted rates for statistical comparison, indicated a significant ( $P < 0.01$ ) difference between the pedicle screw group (82.5%) and the uninstrumented group (74.5%). In the pedicle screw group, significantly more patients showed functional improvement (90.4% vs 86.7%) than in the uninstrumented group. Similarly, there was a significant difference with regard to improvement in back pain (91.5% vs 84%) and leg pain (91.5% vs 88.2%). From these data, it was concluded that pedicular fixation enhances the fusion rate as well as the clinical outcome in patients with degenerative spondylolisthesis.

The advancing degenerative alteration in the lumbar spine may lead to a collapsing spine (degenerative scoliosis) caused by increasing segmental instability. Patients presenting with this entity are usually in their fifth or sixth decade of life. The symptoms are caused by instability,

flat-back syndrome, foraminal nerve root impingement, and central spinal stenosis caused by facet joint and soft tissue hypertrophy. Often these symptoms are accompanied by marked osteoporosis. Surgical treatment of this entity is a challenging task. Decompression alone carries a high risk of persistent severe low-back pain due to instability and curve progression, particularly if an extensive decompression is performed at the apex of the curve. Pedicular segmental instrumentation and fusion of these degenerative disorders is an appropriate form of treatment that provides satisfactory results. The great potential of pedicular instrumentation [115, 153] lies in a better curve correction and restoration of lumbar lordosis than is possible using older implants (e.g., Harrington or Luque instrumentation). Despite promising results [116, 153] and clear conceptual advantages, no clear evidence in the literature supports the superiority of pedicle screw instrumented fusion over other forms of surgical treatment for degenerative scoliosis.

In cases where extensive posterior decompression has led to an iatrogenic instability, pedicular fixation systems have a substantial advantage. These implants provide rigid segmental fixation even if the posterior elements are partly or completely absent. None of the older implant types provides a comparable versatility for this problem. However, the literature does not reveal sufficient data to support this theoretical advantage with regard to clinical outcome. Stauffer and Coventry [161] reported on 31 patients with postlaminectomy instability, of whom 27 (87%) had a solid posterolateral fusion and 58% had a good clinical result. The same authors [160] reported on a series of 14 patients treated with anterior interbody fusion for the same condition, which resulted in a good outcome for 50% of patients and a non-union rate of 55%. The few articles [110, 154, 185] reporting on pedicular stabilization of iatrogenic instability do not subdivide the results further to allow a reasonable outcome assessment.

The benefit of pedicular fixation for the treatment of disc-related syndromes is the most controversial issue, because even fusion per se is heavily debated for this condition [55]. Our current understanding is that alterations within the intervertebral disc are responsible for the generation of pain [28, 43, 182]. If this understanding is correct, disc excision and interbody fusion should be an appropriate treatment [93]. On the other hand, posterolateral fusion with or without instrumentation may not completely eliminate sagittal motion in the anterior column and back pain may still persist despite solid fusion [76, 133, 139].

In a prospective study by Zdeblick [192], the outcome in patients with degenerative disc disease treated by fusion without instrumentation, non-pedicle screw fixation, and pedicle screw fixation, respectively, were compared. The fusion rates were 45%, 67%, and 93%, respectively. However, the clinical results, although generally better in the latter group, were not further detailed for this specific

entity. Wood et al. [186] studied 28 patients with degenerative disc disease treated by pedicular fixation and posterolateral fusion. This study group was compared to a literature control group (eight studies, 498 cases) treated by posterior or posterolateral fusion without instrumentation for the same diagnosis. The authors reported that patients treated without pedicular fixation had a non-union rate 24 times higher than that of the study group, but only 75% of the patients had an improvement in pain scores at a 2-year follow-up. The authors could therefore not demonstrate that the clinical results were substantially better than those in the literature control group. So far, there is no compelling evidence in the literature to support the use of pedicle screw fixation for this condition.

A further indication for pedicular fixation is non-union. Again, rigid segmental fixation should theoretically enhance the fusion rate. Stauffer and Coventry [160] reported on a series of 44 patients treated with anterior interbody fusion for failed previous fusion, in which solid fusion was achieved in 55% of the cases. West et al. [183] reported on 17 patients treated with variable screw plates (VSP) for symptomatic non-union. A solid fusion was only achieved in 11 of the 17 patients, despite the use of pedicular fixation. In a study by Lauermaun [90], 40 patients underwent an attempted repair for symptomatic pseudarthrosis with various techniques (Luque, Steffee, Harrington, uninstrumented posterolateral and anterior fusion). Despite the fact that the numbers were small, there was a trend for an increased fusion rate with instrumentation (50%–66%) compared to the rates achieved with uninstrumented fusion (29%–33%). However, the numbers in each group were too small to demonstrate an advantage of pedicular fixation over FDA Class II devices.

---

## Discussion

### Interpretation of the data

This review has once again demonstrated the poor quality of the scientific literature on the treatment of spinal disorders. As outlined in previous reviews [37, 119, 173, 191], there are too few prospective, randomized controlled trials including a sufficiently large number of cases to allow valid conclusions and generalization. Besides the lack of scientific rigor, the most striking finding is the heterogeneity of the results. For every single treatment option (e.g., posterior, posterolateral, anterior or posterior interbody fusion, instrumented or uninstrumented fusion, instrumentation with or without pedicular fixation) articles that report a favorable or an unfavorable outcome can be retrieved from the literature. These large variations cannot only be due to differences in study population and outcome assessment. Several bias factors also contribute to the heterogeneity in the literature.

*Performance bias.* A factor that has so far not widely been stressed as playing a decisive role is the performance and the skill of surgeons, which may vary substantially, and these have a significant impact on the obtained results.

*Comparison bias.* Surgeons may prospectively accumulate data on a new technique (e.g., pedicular fixation) about which they are enthusiastic, and then compare the results to those of an alternative method not performed with the same level of skill or interest (e.g., uninstrumented posterolateral fusion). Under these circumstances, prejudicial results are unavoidable even in prospective randomized trials.

*Selection bias.* Patient selection for the operation may substantially differ between the various studies. With increasing experience, surgeons may not perform surgery in cases where they feel that a favorable outcome is less likely (e.g., in patients with psychosocial problems). With experience, a surgeon's judgement may even be as effective as a psychological test with regard to patient selection and such a selection may therefore not be well documented.

*Assessment bias.* Assessment of the clinical results by the surgeon or an independent observer influences the outcome as well. Not every surgeon may have the same level of self-criticism or be able to assess his or her results in an unbiased manner. In most reports in the literature, the results are not assessed by an independent unbiased observer.

In Europe, there is a general notion that the risk of pedicular fixation cannot be attributed so much to the device as to the surgeon who uses it. However, it may be argued that a surgical technique has to work in the hands of the majority of the surgeons to achieve widespread acceptance. This requirement was only fulfilled in the "Historical cohort study of pedicle screw fixation," which included 312 surgeons [189], with the majority submitting only a small number of cases. The results of this study clearly suggest that with proper care the complication rates for these devices are low even in less experienced hands. On reviewing the literature, it is obvious that the surgical risks for pedicle screw fixation are no higher than those for any other spinal instrumentation.

Although there is a scarcity of valid, prospective randomized trials, a large number of cases have been reported for each fusion technique, which should allow for depiction of at least a trend in treatment outcome. This trend may exist for the treatment of thoracolumbar fractures, but the differences are small and may not be clinically relevant. In contrast to what most European spine surgeons seem to believe, there is no trend for improved treatment outcome in any other spinal disorder, which is very disappointing. The most confusing factor is that, par-

ticularly for low-back pain disorders, favorable and unfavorable results have been reported for every single fusion technique.

### The “American dilemma”

The legal background to the pedicle screw dilemma in the United States has been recently outlined in a review by Mishra et al. [126]. Although the physician is ultimately responsible for the safety and effectiveness of treatment that relies on implant devices, the United States Congress has charged the Food and Drug Administration (FDA) with the legal responsibility for ensuring that all medical devices that are brought to the market are safe and effective. The passage of the Medical Device Amendments of 1976 directed the FDA to classify all pre-amendment devices as Class I (e.g., crutches, canes, and certain cast materials), Class II (e.g., bone screws and plates, intramedullary nails, total hip arthroplasty with cement), or Class III (entirely new device, new material, or new intended uses with insufficient information on safety and effectiveness). A so-called Premarket Notification (based on section 510(k) of the Medical Device Amendment) is required whenever a medical device is being introduced into the market for the first time, whenever a device is changed or modified, or whenever there is a change in the intended use. This allows the FDA to determine whether a device is substantially equivalent, in terms of design, material, and intended use, to a legally marketed comparison product in either Class I or Class II. Substantial equivalence means that a device has the same intended use and technological characteristics as a legally marketed comparison device [126].

In the middle of the 1980s, the manufacturers of pedicle screws who intended to market these devices in the United States approached the FDA claiming these devices were pre-amendment devices. The FDA disagreed with this assessment and declared these devices to be new devices and, by the virtue of the implants, they became so-called Class III devices. However, the anomaly exists that bone screws have FDA approval (Class II devices) for application in the pedicles of the sacrum and in vertebral bodies (for anterior instrumentation), since those screws were used prior to 1976. This anomaly is based on legal aspects rather than on a medical rationale with regard to safety and effectiveness.

Despite the FDA restriction, American spine surgeons have started to use pedicular screws in the spine above the sacrum (i.e., an off-label use), which falls within their legal right to practice medicine in a manner consistent with their professional judgement and as recognized by the FDA [50]. Meanwhile, pedicular screw fixation is used by a large number of surgeons in the United States [188, 191] and is considered the state of the art in specific settings by the vast majority of surgeons. However, the marketing of

these implants is still restricted with regard to safety and effectiveness, which causes a regulatory dilemma [50]. The reason for that is the overall poor quality of the scientific literature on pedicular fixation, which lacks controlled randomized trials documenting its benefits. It appears that the reasons behind the FDA's restrictions are not predominantly dealing with implant-related problems, but with the still unproved clinical advantage of pedicle screw fixation for most current applications [130].

This confrontation in the United States is also of relevance to surgeons in the European Union, where similar controls may soon be introduced [130]. If European spine surgeons do not take on board the need to establish the value of pedicle screw fixation by more stringent scientific data, this community may soon be confronted with a similar “European dilemma.” If surgeons do not initiate and manufacturers do not fund prospective clinical trials to prove the clinical effectiveness of these devices for specific diagnostic entities, medical licensing authorities may then dictate how spine surgery is performed in the near future in Europe.

### Conclusions

From a scientific point of view, the quality of the literature on pedicle screw fixation and alternative treatment forms is in general poor. There is a lack of prospective, randomized controlled trials with a sufficiently large number of cases, which restricts valid conclusions. The data on treatment of spinal disorders is predominantly based on case series without uniform outcome assessment, which makes a comparison of results difficult.

- Despite these shortcomings, there is sufficient data to demonstrate that the use of these pedicle screw devices does not result in substantially higher complication rates than using other spinal implants. These devices may be considered to be as safe as other instrumentation devices.
- Pedicular fixation provides short, rigid segmental stabilization, which allows preservation of motion segments and stabilization of the spine in the absence of intact posterior elements, which is not possible with non-pedicular instrumentation. Although theoretically intriguing, these benefits do not find a direct reflection in the current literature in terms of clinical and radiological outcome.
- In the treatment of thoracolumbar fractures, there is a trend for pedicle screw systems to provide a higher fusion rate and better functional status and pain relief than non-pedicle systems.
- For the correction of deformity (scoliosis, kyphosis, spondylolisthesis), pedicle screws provide some theoretical advantages, but the current experience is limited and suggests that the results so far are at least equal to established treatment forms.

- There are evident theoretical advantages associated with pedicle screw fixation in the treatment of spinal tumors, but the literature is too sparse for such potential benefits to be documented.
- The most controversial issue is the application of pedicle screws in low-back pain disorders. Although a few articles have argued in favor of these devices, a critical assessment reveals that similar favorable outcomes are also reported for the majority of alternative treatment forms. There is a trend in the literature which suggests that these devices may increase the fusion rate but not necessarily clinical outcome. This is a disappointing finding and is contrary to what most spine surgeons seem to believe.
- In Europe, the use of pedicle screw systems is not yet limited by medical licensing authorities. European spine surgeons should therefore use this opportunity to back up the evident benefits of pedicle screw systems for specific spinal disorders by controlled prospective clinical trials. This may prevent forthcoming medical licensing authorities from restricting the use of pedicle screw devices and dictating the practice of spinal surgery in the near future in Europe.

## References

- Aebi M (1988) Correction of degenerative scoliosis of the lumbar spine. *Clin Orthop* 232:80–86
- Aebi M, Nazarian S (1996) Editorial. *Eur Spine J* 5:1
- Aebi M, Etter C, Kehl T, Thalgot J (1987) Stabilization of the lower thoracic and lumbar spine with the internal spinal skeletal fixation system. Indications, techniques, and first results of treatment. *Spine* 12:544–551
- Akbarnia BA, Fogarty JP, Smith KR Jr (1985) New trends in surgical stabilization of thoraco-lumbar spinal fractures with emphasis for sublaminar wiring. *Paraplegia* 23:27–33
- Ani N, Keppler L, Biscup RS, Steffee AD (1991) Reduction of high-grade slips (grades III–V) with VSP instrumentation. Report of a series of 41 cases. *Spine* 16:S302–S310
- Banta JV (1990) Combined anterior and posterior fusion for spinal deformity in myelomeningocele. *Spine* 15:946–952
- Berlemann U, Cripton PA, Rincon L, Nolte LP, Schläpfer F (1996) Pull-out strength of pedicle hooks with fixation screws. *Eur Spine J* 5:71–73
- Bernhardt M, Swartz DE, Clothiaux PL, Crowell RR, White AA (1992) Posterolateral lumbar and lumbosacral fusion with and without pedicle screw internal fixation. *Clin Orthop* 284:109–115
- Boachie-Adjei O, Lonstein JE, Winter RB, Koop S, van den Brink K, Denis F (1989) Management of neuromuscular spinal deformities with Luque segmental instrumentation. *J Bone Joint Surg [Am]* 71:548–562
- Bohm H, Harms J, Donk R, Zielke K (1990) Correction and stabilization of angular kyphosis. *Clin Orthop* 258:56–61
- Boos N, Marchesi D, Aebi M (1991) Treatment of spondylolysis and spondylolisthesis with the Cotrel-Dubousset instrumentation. A preliminary report. *J Spinal Disord* 4:472–479
- Boos N, Marchesi D, Aebi M (1992a) Survivorship analysis of pedicular fixation systems in the treatment of degenerative disorders of the lumbar spine. A comparison of Cotrel-Dubousset instrumentation and the AO-internal fixator. *J Spinal Disord* 5:403–409
- Boos N, Marchesi D, Heitz R, Aebi M (1992b) Traitement chirurgical des spondylolisthésis de l'adulte à déplacement modéré par fixation pédiculaire et fusion postéro-latérale. *Rev Chir Orthop* 78:228–235
- Boos N, Marchesi D, Zuber K, Aebi M (1993) Treatment of severe spondylolisthesis by reduction and pedicular fixation: A 4–6 year follow-up study. *Spine* 18:1655–1661
- Boxall D, Bradford DS, Winter RB, Moe JH (1979) Management of severe spondylolisthesis. *J Bone Joint Surg [Am]* 61:479–495
- Bradford DS (1979) Treatment of severe spondylolisthesis: a combined approach for reduction and stabilization. *Spine* 5:423–429
- Bradford DS (1986) Instrumentation of the lumbar spine. *Clin Orthop* 203:209–218
- Bradford DS, Boachie-Adjei O (1990) Treatment of severe spondylolisthesis by anterior and posterior reduction and stabilization. A long-term follow-up study. *J Bone Joint Surg [Am]* 72:1060–1066
- Bridwell KH, McAllister JW, Betz RR, Huss G, Clancy M, Schoenecker PL (1991) Coronal decompensation produced by Cotrel-Dubousset “derotation” maneuver for idiopathic right thoracic scoliosis. *Spine* 16:769–777
- Chang KW, McAfee PC (1989) Degenerative spondylolisthesis and degenerative scoliosis treated with a combination segmental rod-plate and transpedicular screw instrumentation system. *J Spinal Disord* 1:247–256
- Cheng CL, Fang D, Lee PC, Leong JCY (1989) Anterior spinal fusion for spondylolysis and isthmus spondylolisthesis. Long term results in adults. *J Bone Joint Surg [Br]* 71:264–267
- Chow, SP, Leong JC, Ma A, Yau AC (1980) Anterior spinal fusion or deranged lumbar intervertebral disc. *Spine* 5:452–458
- Cloward RB (1981) Spondylolisthesis: treatment by laminectomy and posterior interbody fusion. *Clin Orthop* 154:74–82
- Collis JS (1985) Total disc replacement: a modified posterior lumbar interbody fusion. Report of 750 cases. *Clin Orthop* 193:64–67
- Cotrel Y, Dubousset J (1984) Nouvelle technique d'ostéosynthèse rachidienne segmentaire par voie postérieure. *Rev Chir Orthop* 70:489–494
- Cotrel Y, Dubousset J, Guillaumat M (1988) New universal instrumentation in spinal surgery. *Clin Orthop* 227:10–23
- Crawford MJ, Esses SI (1994) Indications for pedicle fixation. Results of NASS/SRS faculty questionnaire. North American Spine Society and Scoliosis Research Society. *Spine* 19:2584–2589
- Crock H (1986) Internal disc disruption. A challenge to disc prolapse fifty years on. *Spine* 11:650–653
- Daniaux H, Seykora P, Genelin A, Lang T, Kathrein A (1991) Application of posterior plating and modifications in thoracolumbar spine injuries: indications, techniques and results. *Spine* 16:S125–S133

30. Dawson E, Lotysch III M, Urist M (1981) Intertransverse process lumbar arthrodesis with autogenous bone graft. *Clin Orthop* 154:90–96
31. DePalma AF, Prabhakar M (1966) Posterior-posterobilateral fusion of the lumbosacral spine. *Clin Orthop* 47:165–171
32. DeWald RL, Faut MM, Taddonio RF, Neuwirth MG (1981) Severe lumbosacral spondylolisthesis in adolescents and children. Reduction and staged circumferential fusion. *J Bone Joint Surg [Am]* 63:619–626
33. Dick W (1984) Innere Fixation von Brust- und Lendenwirbelbrüchen. Hans Huber, Bern
34. Dick W (1987) The “fixateur interne” as a versatile implant for spine surgery. *Spine* 12:882–900
35. Dick W, Schnebel B (1988) Severe spondylolisthesis. Reduction and internal fixation. *Clin Orthop* 232:70–79
36. Dick W, Kluger P, Magerl F, Woerdörfer O, Zäch C (1985) A new device for internal fixation of thoracolumbar and lumbar spine fractures: the “fixateur interne”. *Paraplegia* 23:225–232
37. Dickman CA, Yahiro MA, Lu HTC, Melkerson MN (1994) Surgical treatment alternatives for fixation of unstable fractures of the thoracic and lumbar spine. A meta-analysis. *Spine* 20:S2266–S2273
38. Dickson JH, Harrington PR, Erwin WD (1978) Results of reduction and stabilization of the severely fractured thoracic and lumbar spine. *J Bone Joint Surg [Am]* 60:799–805
39. Dickson JH, Erwin WD, Rossi D (1990) Harrington instrumentation and arthrodesis for idiopathic scoliosis. A twenty-one-year follow-up. *J Bone Joint Surg [Am]* 72:678–683
40. Ebelke DK, Asher MA, Neff JR, Kraker DP (1990) Survivorship analysis of VSP spine instrumentation in the treatment of thoracolumbar and lumbar burst fractures. *Spine* 16:S428–S432
41. Esses SI, Botsford DJ, Wright T, Bednar D, Bailey S (1991) Operative treatment of spinal fractures with the AO internal fixator. *Spine* 16:S146–S150
42. Esses SI, Sachs BL, Dreyzin V (1993) Complications associated with the technique of pedicle screw fixation. A selected survey of ABS members. *Spine* 18:2231–2238
43. Eyre D, Benya P, Buckwalter J, Catterson B, Heinegård D, Oegema T, Pearce R, Pope M, Urban J (1989) Intervertebral disk: basic science perspectives. In: Frymoyer JW, Gordon SL (eds) *New perspectives on low back pain*. American Academy of Orthopaedic surgeons, Park Ridge, pp 147–207
44. Flatley TJ, Derderian H (1985) Closed loop instrumentation of the lumbar spine. *Clin Orthop* 196:273–278
45. Flesch JR, Leider LL, Erickson DL, Chou SN, Bradford DS (1977) Harrington instrumentation and spine fusion for unstable fractures and fracture-dislocations of the thoracic and lumbar spine. *J Bone Joint Surg [Am]* 59:143–153
46. Flynn JC, Hoque MA (1979) Anterior fusion of the lumbar spine. End-result study with long-term follow-up. *J Bone Joint Surg [Am]* 61:1143–1150
47. Freebody D, Bendall R, Taylor RD (1971) Anterior transperitoneal lumbar fusion. *J Bone Joint Surg [Br]* 53:617–627
48. Freeman III BL, Donati NL (1989) Spinal arthrodesis for severe spondylolisthesis in children and adolescents. A long-term follow-up study. *J Bone Joint Surg [Am]* 71:594–598
49. Fujiya M, Saita M, Kaneda K, Abumi K (1990) Clinical study on stability of combined distraction and compression rod instrumentation with posterolateral fusion for unstable degenerative spondylolisthesis. *Spine* 15:1216–1222
50. Garfin SR (1994) Historical cohort study of pedicle screw fixation in thoracic, lumbar, and sacral spine fusions (editorial). *Spine* 19:S2254–S2255
51. Gertzbein SD, Crowe PJ, Fazl M, Schwartz M, Rowed D (1992) Canal clearance in burst fractures using the AO internal fixator. *Spine* 17:558–560
52. Gill K, Blumenthal SL (1993) Posterior lumbar interbody fusion. A 2-year follow-up of 238 patients. *Acta Orthop Scand [Suppl]* 251:108–110
53. Graham CE (1979) Lumbosacral fusion using internal fixation with a spinous process for the graft: a review of 50 patients with a five-year maximum follow-up. *Clin Orthop* 140:72–77
54. Hanley EN (1986) Decompression and distraction-derotation arthrodesis for degenerative spondylolisthesis. *Spine* 11:269–276
55. Hanley EN (1995) The indication for lumbar spinal fusion with and without instrumentation. *Spine* 20:S143–S153
56. Hanley EN, Levy JA (1989) Surgical treatment of isthmic lumbosacral spondylolisthesis. Analysis of variables influencing results. *Spine* 14:48–50
57. Harrington PR (1988) The history and development of Harrington instrumentation. *Clin Orthop* 227:3–5
58. Harrington PR, Dickson JH (1976) Spinal instrumentation in the treatment of severe progressive spondylolisthesis. *Clin Orthop* 117:157–163
59. Harrington PR, Tullos HS (1969) Reduction of severe spondylolisthesis in children. *South Med J* 62:1–7
60. Harrington PR, Tullos HS (1971) Spondylolisthesis in children. Observations and surgical treatment. *Clin Orthop* 79:75–84
61. Harris IE, Weinstein SL (1987) Long-term follow-up of patients with grade-III and IV spondylolisthesis. Treatment with and without posterior fusion. *J Bone Joint Surg [Am]* 69:960–969
62. Hehne HJ, Zielke K, Bohm H (1990) Polysegmental lumbar osteotomies and transpedicle fixation for correction of long-curved kyphotic deformities in ankylosing spondylitis. Report on 177 cases. *Clin Orthop* 258:49–55
63. Hensinger RN (1989) Current concepts review. Spondylolysis and spondylolisthesis in children and adolescents. *J Bone Joint Surg [Am]* 71:1098–1107
64. Hensinger RN, Lang JR, MacEwen GD (1976) Surgical management of spondylolisthesis in children and adolescents. *Spine* 1:207–216
65. Herkowitz HN, Kurz LT (1991) Degenerative lumbar spondylolisthesis with spinal stenosis. *J Bone Joint Surg [Am]* 73:802–808
66. Hirabayashi S, Kumano K, Kuroki T (1991) Cotrel-Dubousset pedicle screw system for various spinal disorders. Merits and problems. *Spine* 16:1298–1304
67. Hou S, Hu R, Shi Y (1993) Pedicle morphology of the lower thoracic and lumbar spine in a Chinese population. *Spine* 18:1850–1855
68. Hutter CG (1983) Posterior intervertebral body fusion. A 25-year study. *Clin Orthop* 179:86–96
69. Hutter CG (1985) Spinal stenosis and posterior lumbar interbody fusion. *Clin Orthop* 193:103–114
70. Inoue SI, Watanabe T, Hirose A, Tanaka T, Matsui N, Saegusa O, Sho E (1984) Anterior discectomy and interbody fusion for lumbar disc herniation. A review of 350 cases. *Clin Orthop* 183:22–31

71. Jackson RK, Boston DA, Edge AJ (1985) Lateral mass fusion. A prospective study of a consecutive series with long-term follow-up. *Spine* 10: 828–832
72. Jacobs R, Montesano P, Jackson R (1989) Enhancement of lumbar spine fusion by use of translaminar facet joint screws. *Spine* 14: 12–15
73. Johnson JR, Kirwan EO (1983) The long-term results of fusion in situ for severe spondylolisthesis. *J Bone Joint Surg [Br]* 65: 43–46
74. Johnson LP, Nasca RJ, Dunham WK (1988) Surgical management of isthmic spondylolisthesis. *Spine* 13: 93–97
75. Johnsson K, Willner S, Johnsson K (1986) Postoperative instability after decompression for lumbar spinal stenosis. *Spine* 11: 107–110
76. Johnsson R, Selvik G, Stromqvist B, Sundén G (1990) Mobility of the lower lumbar spine after posterolateral fusion determined by roentgen stereophotogrammetric analysis. *Spine* 15: 347–350
77. Jönsson B, Sjöström L, Olerud C, Andréason I, Bring J, Rauschnig W (1996) Outcome after limited posterior surgery for thoracic spine metastases. *Eur Spine J* 5: 36–44
78. Kabins MB, Weinstein JN, Spratt KF, Found EM, Chen JH, Woody J, Sayre H (1991) Isolated L4–L5 floating fusions using the variable screw placement system: unilateral vs. bilateral. Presented at the Annual meeting of the International Society for the Study of the Lumbar Spine, Heidelberg
79. Kaneda K, Satoh S, Nohara Y, Oguma T (1985) Distraction rod instrumentation with posterolateral fusion in isthmic spondylolisthesis: 53 cases followed for 18–89 months. *Spine* 10: 383–389
80. Kaneda K, Kazama H, Satoh S, Fujita M (1986) Follow-up study of medial facetectomies and posterolateral fusion with instrumentation in unstable degenerative spondylolisthesis. *Clin Orthop* 203: 159–167
81. Katz JN, Lipson SJ, Larson MG, McInnes JM, Fossel AH, Liang MH (1991) The outcome of decompressive laminectomy for degenerative lumbar stenosis. *J Bone Joint Surg [Am]* 73: 809–816
82. Kim NH, Lee HM, Chung IH, Kim HJ, Kim SJ (1994) Morphometric study of the pedicles of thoracic and lumbar vertebrae in Koreans. *Spine* 19: 1390–1394
83. Kiviluoto O, Santavirta S, Salenius P, Morri P (1985) Postero-lateral spine fusion. A 1–4 year follow-up of 80 consecutive patients. *Acta Orthop Scand* 56: 152–154
84. Kostuik JP, Errico TJ, Gleason TF (1990) Luque instrumentation in degenerative conditions of the lumbar spine. *Spine* 15: 318–321
85. Kozak JA, O'Brien JP (1990) Simultaneous combined anterior and posterior fusion. An independent analysis of a treatment for the disabled low-back pain patient. *Spine* 15: 322–328
86. Krag MH (1996) Biomechanics of transpedicle spinal fixation. In: Wiesel SW, Weinstein JN, Herkowitz H, Dvorak J, Bell G (eds) *The lumbar spine*. Saunders, Philadelphia, pp 1177–1203
87. Krag MH, Beynon BD, Pope MH, Frymoyer JW, Haugh LD, Weaver DL (1986) An internal fixator for posterior application to short segments of the thoracic, lumbar, or lumbosacral spine. Design and testing. *Clin Orthop* 203: 75–98
88. Krag MH, Weaver DL, Beynon BD, Haugh LD (1988) Morphometry of the thoracic and lumbar spine related to transpedicular screw placement for surgical spinal fixation. *Spine* 13: 27–31
89. Lagrone MO, Bradford DS, Moe JH, Lonstein JE, Winter RB, Ogilvie JW (1988) Treatment of symptomatic flatback after spinal fusion. *J Bone Joint Surg [Am]* 70: 569–580
90. Lauerman WC, Bradford DS, Ogilvie JW, Transfeldt EE (1992) Results of lumbar pseudarthrosis repair. *J Spinal Disord* 5: 149–157
91. Laurent LE, Östermann K (1976) Operative treatment of spondylolisthesis in young patients. *Clin Orthop* 117: 85–91
92. Laxer E (1994) A further development in spinal instrumentation. *Eur Spine J* 3: 347–352
93. Lee CK, Vessa P, Lee JK (1995) Chronic disabling low back pain syndrome caused by internal disc derangements. The results of disc excision and posterior lumbar interbody fusion. *Spine* 20: 356–361
94. Lehmann TR, Spratt KF, Tozzi JE, Weinstein JN, Reinartz SJ, El-Koury GY, Colby H (1987) Long-term follow-up of lower lumbar fusion patients. *Spine* 12: 97–104
95. Lenke LG, Bridwell KH, Balduz C, Blanke K (1992) Preventing decompensation in King type II curves treated with Cotrel-Dubousset instrumentation. Strict guidelines for selective thoracic fusion. *Spine* 17: S274–S281
96. Leyvraz PF, Guigoz JP (1987) Résultats du traitement chirurgical du spondylolisthésis par greffes postéro-latérales intertransversaires. A propos de 39 cas. *Rev Chir Orthop* 73: 137–141
97. Lin PM (1985) Posterior lumbar interbody fusion technique: complications and pitfalls. *Clin Orthop* 193: 90–102
98. Lindsey RW, Dick W (1991) The fixateur interne in the reduction and stabilization of thoracolumbar spine fractures with neurologic defect. *Spine* 16: S140–S145
99. Linson MA, Williams H (1991) Anterior and combined anteroposterior fusion for lumbar disc pain. A preliminary study. *Spine* 16: 143–145
100. Liu YK, Njus GO, Bahr PA, Geng P (1990) Fatigue life improvement of nitrogen-ion-implanted pedicle screws. *Spine* 15: 311–317
101. Loguidice V, Johnson R, Guyer R, Stith W, Ohnmeiss D, Hochschuler S, Rashbaum R (1988) Anterior lumbar interbody fusion. *Spine* 13: 366–369
102. Lorenz M, Zindrick M, Schwaegler P, Vrbos L, Collatz MA, Behal R, Cram R (1991) A comparison of single-level fusions with and without hardware. *Spine* 16: S455–S458
103. Louis R (1986) Fusion of the lumbar and sacral spine by internal fixation with screw plates. *Clin Orthop* 203: 18–33
104. Louis R, Maresca C (1976) Les arthrodèse stables de la lombo-sacrée (70 cas). *Rev Chir Orthop [Suppl II]* 62: 70
105. Louis R, Maresca C (1977) Stabilisation chirurgicale avec réduction des spondylolyses et des spondylolisthésis. *Int Orthop* 1: 215–225
106. Luque ER (1982a) The anatomic basis and development of segmental spinal instrumentation. *Spine* 7: 256–259
107. Luque ER (1982b) Segmental spinal instrumentation for correction of scoliosis. *Clin Orthop* 163: 192–198
108. Luque ER (1986) Segmental spinal instrumentation of the lumbar spine. *Clin Orthop* 203: 126–134
109. Luque ER (1989) Segmental spinal instrumentation in neuromuscular scolioses. *Orthopaede* 18: 128–133
110. MacMillan MM, Cooper R, Haid R (1994) Lumbar and lumbosacral fusions using Cotrel-Dubousset pedicle screws and rods. *Spine* 19: 430–434
111. Macnab I, Dall D (1971) The blood supply of the lumbar spine and its application to the technique of intertransverse lumbar fusion. *J Bone Joint Surg [Br]* 53: 628–638
112. Magerl F (1982) External skeletal fixation of the lower thoracic and the lumbar spine. In: Uhthoff H (ed) *Current concepts of external fixation of fractures*. Springer, Berlin, pp 353–366

113. Magerl F (1983) Clinical application on the thoracolumbar junction and the lumbar spine. In: Mears DC (ed) External skeletal fixation. Williams & Wilkins, Baltimore London, pp 553–575
114. Magerl F, Coscia M (1988) Total posterior vertebrectomy of the thoracic or lumbar spine. *Clin Orthop* 232: 62–69
115. Marchesi DG, Aebi M (1992) Pedicle fixation devices in the treatment of adult lumbar scoliosis. *Spine* 17: S304–S309
116. Marchesi D, Schneider E, Glauser P, Aebi M (1988) Morphometric analysis of the thoracolumbar and lumbar pedicles, anatomo-radiologic study. *Surg Radiol Anat* 10: 317–322
117. Marchesi DG, Thalgott JS, Aebi M (1991) The application and results of the AO-internal fixator in non-traumatic indications. *Spine* 16: S162–S169
118. Marchesi DG, Boos N, Zuber K, Aebi M (1992) Translaminar facet joint screws to enhance segmental fusion of the lumbar spine. *Eur Spine J* 1: 125–130
119. Mardjetko SM, Connolly PJ, Shott S (1994) Degenerative lumbar spondylolisthesis. A meta-analysis of the literature 1970–1993. *Spine* 19: S2256–S2265
120. Matthias HH, Heine J (1986) The surgical reduction of spondylolisthesis. *Clin Orthop* 203: 34–44
121. McAfee PC, Weiland DJ (1991) Survival analysis of pedicular fixation systems. *Spine* 16: S422–S427
122. McLain RF, Kabins M, Weinstein JN (1991) VSP stabilization of lumbar neoplasms: technical considerations and complications. *J Spinal Disord* 4: 359–365
123. McMaster MJ (1987) Anterior and posterior instrumentation and fusion of thoracolumbar scoliosis due to myelomeningocele. *J Bone Joint Surg [Br]* 69: 20–25
124. McPhee I, O'Brian J (1979) Reduction of severe spondylolisthesis. A preliminary report. *Spine* 4: 430–434
125. Mielke CH, Lonstein JE, Denis F, Vandenbrink K, Winter RB (1989) Surgical treatment of adolescent idiopathic scoliosis. A comparative analysis. *J Bone Joint Surg [Am]* 71: 1170–1177
126. Mishra N, Yahiro M, Morrey BF (1994) Current concepts review. The Food and Drug Administration's regulation of orthopaedic devices. *J Bone Joint Surg [Am]* 76: 919–922
127. Mitsunaga MM, Chong G, Maes KE (1991) Microscopically assisted posterior lumbar interbody fusion. *Clin Orthop* 263: 121–127
128. Moran JM, Berg WS, Berry JL, Geiger JM, Steffee AD (1989) Transpedicular screw fixation. *J Orthop Res* 7: 107–114
129. Morse BJ, Ebraheim NA, Jackson WT (1994) Preoperative CT determination of angles for sacral screw placement. *Spine* 19: 604–607
130. Mulholland RC (1994) Pedicle screw fixation in the spine. *J Bone Joint Surg [Br]* 76: 517–519
131. Nasca RJ, Littlefield PD (1990) Knodt rod distraction instrumentation in lumbosacral arthrodesis. *Spine* 15: 1356–1359
132. O'Brien JP, Dawson MH, Heard CW, Momberger G, Speck G, Weatherly CR (1986) Simultaneous combined anterior and posterior fusion. A surgical solution for failed spinal surgery with a brief review of the first 150 patients. *Clin Orthop* 203: 191–195
133. Olsson TH, Selvik G, Willner S (1977) Mobility in the lumbosacral spine after fusion studied with the aid of roentgen stereophotogrammetry. *Clin Orthop* 129: 181–190
134. Östermann K, Lindholm TS, Laurent LE (1976) Late results of removal of the loose posterior element (Gill's operation) in the treatment of lytic lumbar spondylolisthesis. *Clin Orthop* 117: 121–128
135. Peek RD, Wiltse LL, Reynolds JB, Thomas JC, Guyer DW, Widell EH (1989) In situ arthrodesis without decompression for grade-III or IV isthmic spondylolisthesis in adults who have severe sciatica. *J Bone Joint Surg [Am]* 71: 62–68
136. Pizzutillo PD, Miranda W, MacEwen GD (1986) Posterolateral fusion for spondylolisthesis in adolescence. *J Pediatr Orthop* 6: 311–316
137. Prolo DJ, Oklund SA, Butcher M (1986) Toward uniformity in evaluating results of lumbar spine operations. A paradigm applied to posterior lumbar interbody fusions. *Spine* 11: 601–606
138. Raugstad TS, Harbo K, Oogberg A, Skeie S (1982) Anterior interbody fusion of the lumbar spine. *Acta Orthop Scand* 53: 561–565
139. Rolander SD (1966) Motion of the lumbar spine with special reference to the stabilizing effect of posterior fusion. *Acta Orthop Scand [Suppl]* 37: 117–144
140. Rombold C (1966) Treatment of spondylolisthesis by posterolateral fusion, resection of the pars interarticularis, and prompt mobilization of the patient. An end-result study of seventy-three patients. *J Bone Joint Surg [Am]* 48: 1282
141. Roy-Camille R (1970) Ostéosynthèse du rachis dorsal, lombaire et lombosacré par plaque métalliques visées dans pédicules vertébraux et les apophyses articulaires. *Presse Méd* 78: 1447–1448
142. Roy-Camille R, Saillant G, Mazel C (1986) Internal fixation of the lumbar spine with pedicle screw plating. *Clin Orthop* 203: 7–17
143. Roy-Camille R, Benazet JP, Desauge JP, Kuntz F (1993) Lumbosacral fusion with pedicular screw plating instrumentation. A 10-year follow-up. *Acta Orthop Scand [Suppl]* 251: 100–104
144. Saillant G (1976) Etude anatomique des pédicules vertébraux. *Rev Chir Orthop* 62: 151–160
145. Sasso RC, Cotler HB (1993) Posterior instrumentation and fusion for unstable fractures and fracture-dislocations of the thoracic and lumbar spine. A comparative study of three fixation devices in 70 patients. *Spine* 18: 450–460
146. Savini R, Ghirardini GL, Morandi M, Pellacci F (1984) Posterolateral lumbosacral arthrodesis (PLA.). A study of 85 cases. *Ital J Orthop Traumatol* 10: 449–460
147. Schoenecker PL, Cole HO, Herring JA, Capelli AM, Bradford DS (1990) Cauda equina syndrome after in situ arthrodesis for severe spondylolisthesis at the lumbosacral junction. *J Bone Joint Surg [Am]* 72: 369–377
148. Schöllner D (1990) One stage-reduction and fusion for spondylolisthesis. *Int Orthop* 14: 145–150
149. Scoles PV, Linton AE, Latimer B, Levy ME, Digiovanni BF (1988) Vertebral body and posterior element morphology: the normal spine in middle life. *Spine* 13: 1082–1086
150. Seitsalo S, Österman K, Hyvärinen H, Schlenzka D, Poussa M (1990) Severe spondylolisthesis in children and adolescents. *J Bone Joint Surg [Br]* 72: 259–265
151. Sijbrandij S (1981) A new technique for the reduction and stabilisation of severe spondylolisthesis. A report of two cases. *J Bone Joint Surg [Br]* 63: 266–271
152. Simmons E (1995) Arthritic spinal deformity – ankylosing spondylitis. In: White AH, Schofferman JA (eds) Spine care. Diagnosis and conservative treatment. Mosby-Year Book, St Louis, pp 1652–1719
153. Simmons ED Jr, Simmons EH (1992) Spinal stenosis with scoliosis. *Spine* 17: S117–S120
154. Simpson JM, Ebraheim NA, Jackson WT, Chung S (1993) Internal fixation of the thoracic and lumbar spine using Roy-Camille plates. *Orthopedics* 16: 663–672



155. Smith MD, Bohlman HH (1990) Spondylolisthesis treated by a single-stage operation combining decompression with in situ posterolateral and anterior fusion. *J Bone Joint Surg [Am]* 72:415-421
156. Soini J, Laine T, Pohjolainen T, Hurri H, Alaranta H (1993) Spondylolisthesis augmented by transpedicular fixation in the treatment of olisthetic and degenerative conditions of the lumbar spine. *Clin Orthop* 297:111-116
157. Sorensen KH (1978) Anterior interbody lumbar spine fusion for incapacitating disc degeneration and spondylolisthesis. *Acta Orthop Scand* 49:269-277
158. Stark A, Saraste H (1993) Anterior fusion insufficient for scoliosis in myelomeningocele. 8 children 2-6 years after the Zielke operation. *Acta Orthop Scand* 64:22-24
159. Steffee AD, Brantigan JW (1993) The variable screw placement spinal fixation system. Report of a prospective study of 250 patients enrolled in Food and Drug Administration clinical trials. *Spine* 18:1160-1172
160. Stauffer R, Coventry M (1972a) Anterior interbody lumbar spine fusion. *J Bone Joint Surg Am* 54:756-768
161. Stauffer RN, Coventry MB (1972b) Posterolateral lumbar-spine fusion. *J Bone Joint Surg [Am]* 54:1195-1204
162. Steffee A, Sitkowski D (1988a) Posterior lumbar interbody fusion and plates. *Clin Orthop* 227:99-102
163. Steffee AD, Sitkowski DJ (1988b) Reduction and stabilization of grade IV spondylolisthesis. *Clin Orthop* 227:82-89
164. Steffee AD, Biscup RS, Sitkowski DJ (1986a) Segmental spine plates with pedicle screw fixation. A new internal fixation device for disorders of the lumbar and thoracolumbar spine. *Clin Orthop* 203:45-53
165. Steffee AD, Sitkowski DJ, Toham LS (1986b) Total vertebral body and pedicle arthroplasty. *Clin Orthop* 203:203-208
166. Suk SI, Lee CK, Kim WJ, Chung YJ, Park YB (1995) Segmental pedicle screw fixation in the treatment of thoracic idiopathic scoliosis. *Spine* 20:1399-1405
167. Taylor LJ, Gardner AD (1984) Knott rod fusion of the lumbar spine. *Acta Orthop Scand* 55:542-544
168. Temple HT, Kruse RW, van Dam BE (1994) Lumbar and lumbosacral fusion using Steffee instrumentation. *Spine* 19:537-541
169. Thomasen E (1985) Intercorporal lumbar spondylodesis. 312 patients followed for 2-20 years. *Acta Orthop Scand* 56:287-293
170. Thompson JP, Transfeldt EE, Bradford DS, Ogilvie JW, Boachie-Adjei O (1990) Decompensation after Cotrel-Dubousset instrumentation of idiopathic scoliosis. *Spine* 15:927-931
171. Thompson WA, Gristina AG, Healy WA Jr (1974) Lumbosacral spine fusion. A method of bilateral posterolateral fusion combined with a Hibbs fusion. *J Bone Joint Surg [Am]* 56:1643-1647
172. Truchly G, Thompson W (1962) Posterolateral fusion of lumbosacral spine. *J Bone Joint Surg [Am]* 44:505-512
173. Turner JA, Ersek M, Herron L, Haselkorn J, Kent D, Ciol MA, Deyo R (1992) Patient outcomes after lumbar spinal fusions. *JAMA* 268:907-911
174. Turner R, Bianco A (1971) Spondylolysis and spondylolisthesis in children and teenagers. *J Bone Joint Surg [Am]* 53:1298-1306
175. Vaccaro AR, Garfin SR (1995) Internal fixation (pedicle screw fixation) for fusions of the lumbar spine. *Spine* 20:S157-S165
176. Vaccaro AR, Rizzolo SJ, Allardyce TJ, Ramsey M, Salvo J, Balderston RA, Cotler JM (1995) Placement of pedicle screws in the thoracic spine. Morphometric analysis of the thoracic vertebrae. *J Bone Joint Surg [Am]* 77:1193-1199
177. Verbiest H (1979) The treatment of spondyloptosis or impending lumbar spondyloptosis accompanied by neurologic deficit and/or neurogenic intermittent claudication. *Spine* 4:68-77
178. Vincent A, Tshiakatumba ML, De Nayer P, Lokietek W, Maldague B, Malghem J, Rombouts JJ (1981) Arthrodesis postéro-latérale du rachis lombaire. Résultats à long terme. *Acta Orthop Belg* 47:619-635
179. Ward WT, Wenger DR, Roach JW (1989) Surgical correction of myelomeningocele scoliosis: a critical appraisal of various spinal instrumentation systems. *J Pediatr Orthop* 9:262-268
180. Wawro W, Boos N, Aebi M (1992) Technik der operativen Korrektur posttraumatischer Kyphosen. *Unfallchirurgie* 95:41-46
181. Webb JK, Burwell RG, Cole AA, Lieberman I (1995) Posterior instrumentation in scoliosis. *Eur Spine J* 4:2-5
182. Weinstein JN, Rydevik BL (1989) The pain of spondylolisthesis. *Semin Spine Surg* 1:100-105
183. West JL, Bradford DS, Ogilvie JW (1991) Results of spinal arthrodesis with pedicle screw-plate fixation. *J Bone Joint Surg [Am]* 73:1179-1184
184. White AA, Panjabi MM (1990) *Clinical biomechanics of the spine*, 2nd edn. Lippincott, Philadelphia, pp 590-608
185. Whitecloud III TS, Butler JC, Cohen JL, Candelora PD (1989) Complications with the variable spinal plating system. *Spine* 14:472-476
186. Wood GW, Boyd RJ, Carothers TA, Mansfield FL, Rehtine GR, Rozen MJ, Sutterlin CE (1995) The effect of pedicle screw/plate fixation on lumbar/lumbosacral autogenous bone graft fusions in patients with degenerative disc disease. *Spine* 20:819-830
187. Wood KB, Transfeldt EE, Ogilvie JW, Schendel MJ, Bradford DS (1991) Rotational changes of the vertebral-pelvic axis following Cotrel-Dubousset instrumentation. *Spine* 16:S404-S408
188. Yahiro MA (1994a) Comprehensive literature review. Pedicle screw fixation devices. *Spine* 19:S2274-S2278
189. Yahiro MA (1994b) Review of the "Historical study of pedicle screw fixation in thoracic, lumbar and sacral spinal fusions" report. *Spine* 19:S2297-S2299
190. Yashiro K, Homma T, Hokari Y, Katsumi Y, Okumura H, Hirano A (1991) The Steffee variable screw placement system using different methods of bone grafting. *Spine* 16:1329-1334
191. Yuan HA, Garfin SR, Dickman CA, Mardjetko SM (1994) A historical cohort study of pedicle screw fixation in thoracic, lumbar, and sacral spinal fusions. *Spine* 19:S2279-S2296
192. Zdeblick TA (1993) A prospective, randomized study of lumbar fusion. Preliminary results. *Spine* 18:983-991
193. Zindrick MR, Wiltse LL, Doornik A, Widell EH, Knight GW, Patwardhan AG, Thomas JC, Rothman SL, Fields BT (1987) Analysis of the morphometric characteristics of the thoracic and lumbar pedicles. *Spine* 12:160-166
194. Zuchermann J, Hsu K, White A, Wynne G (1988) Early results of spinal fusion using variable spine plating system. *Spine* 13:570-579
195. Zucherman J, Hsu K, Picetti GD, White A, Wynne G, Taylor L (1992) Clinical efficacy of spinal instrumentation in lumbar degenerative disc disease. *Spine* 17:834-837