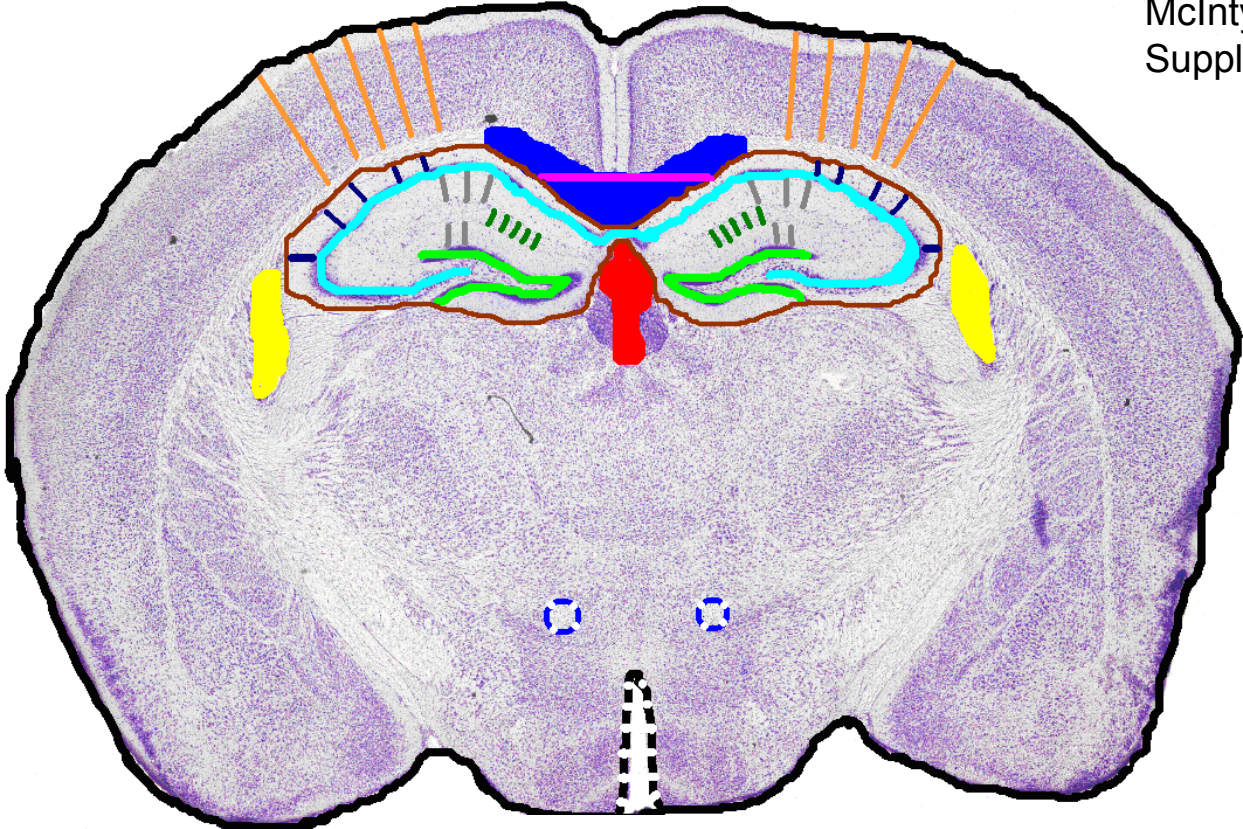

 Dorsal 3rd ventricle area


 Total lateral ventricle area


 Corpus callosum area


 Corpus callosum max span


 Average cortical thickness

 Thalamus

 Total internal length of pyramidal cell layer of hippocampus


 Average thickness of molecular layer of hippocampus


 Average thickness of stratum radiatum of hippocampus

 Average thickness of oriens layer of hippocampus

 Total brain section area

 Mammillothalamic tract

 Caudate

 Total internal length dentate gyrus