

CXR FINDING

Date of CXR: | | / | / | | | |
 Day Month Year

Quality of radiograph			
Good quality (No faults)		Not good but usable, reasons	
Not good but usable (some faults)	- Too dark	Cannot see peripheral vessels	
Bad quality – not usable*	- Too light	Cannot see vertebral ends behind the heart	
	- Rotated	Medial clavicles different distances from spinous process	
	- Under-inspired	Less than 6 anterior ribs at diaphragm mid clavicular line	
	- Parts cut off	e.g. costophrenic angles	
	- Artefacts seen	Dots, lines, metal, clothing that is not anatomy or disease	
	- Movement blur	Like a moving photo – lose sharp edges of heart	

*Fill in a new CXR form

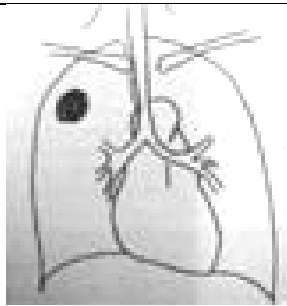
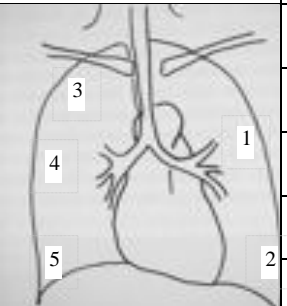
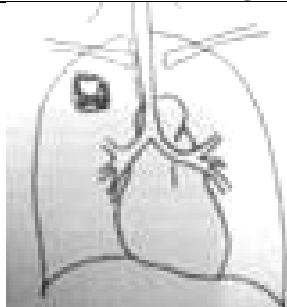
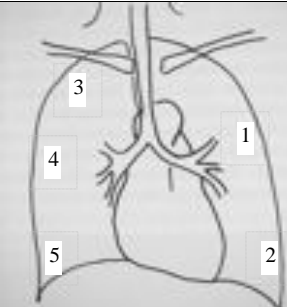
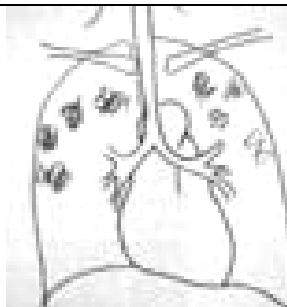
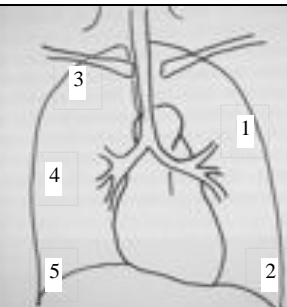
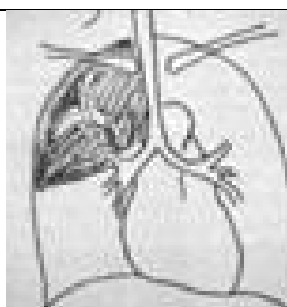
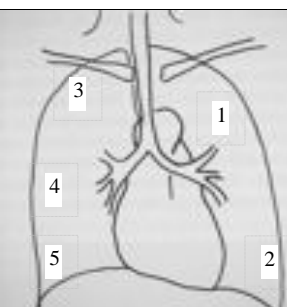
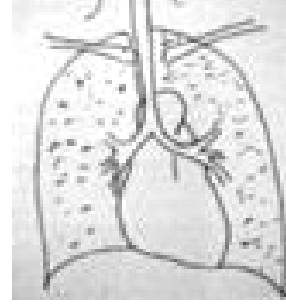
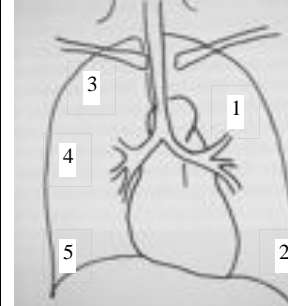
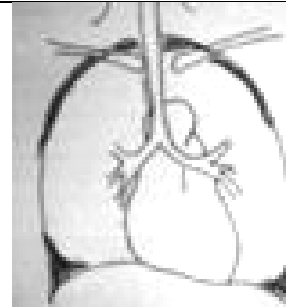
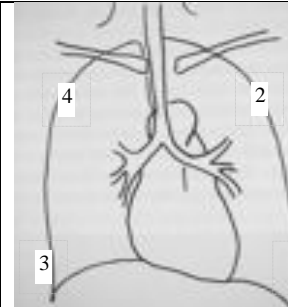
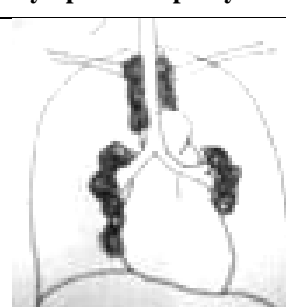
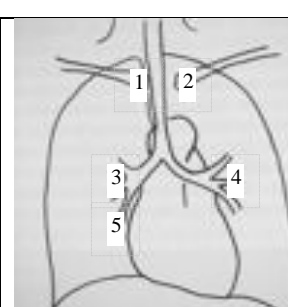
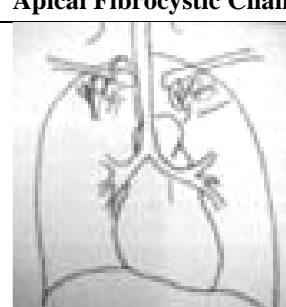
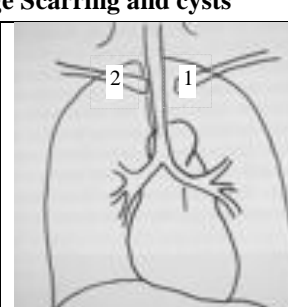
Diagram example	Record Distribution Zones
Granuloma Oval lesion	
	
	1
	2
	3
	4
	5
Cavitation (within a granuloma, consolidation or infiltrate)	
	
	1
	2
	3
	4
	5
Bronchopneumonic pattern, infiltration	
	
	1
	2
	3
	4
	5
Consolidation	
	
	1
	2
	3
	4
	5

Diagram example	Record Distribution Zones
Milliary Nodular pattern	
	
	1
	2
	3
	4
	5
Pleural effusion	
	
	1
	2
	3
	4
	5
Lymph-adenopathy	
	
	1
	2
	3
	4
	5
Apical Fibrocystic Change Scarring and cysts	
	
	1
	2

Definitely TB		Maybe TB		Not TB	
Other diagnosis					