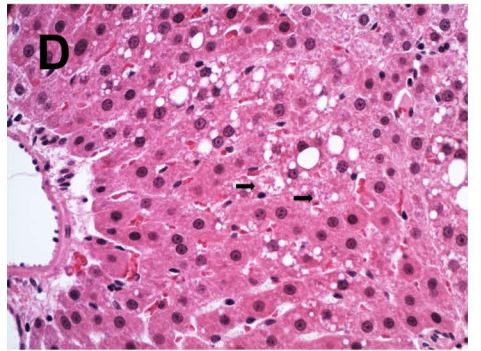
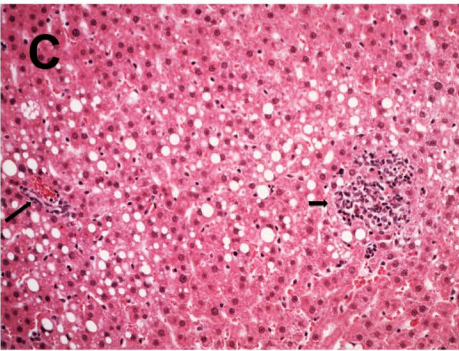
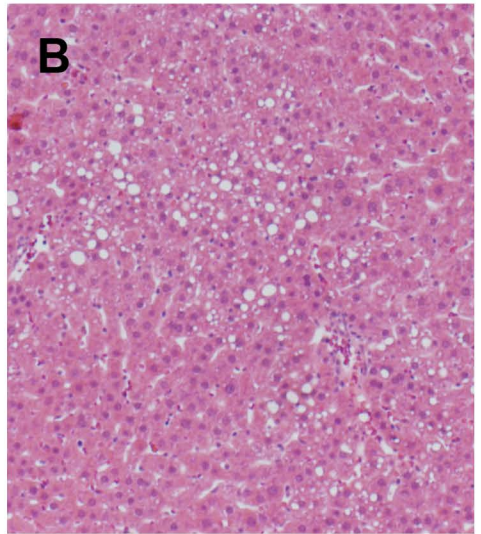
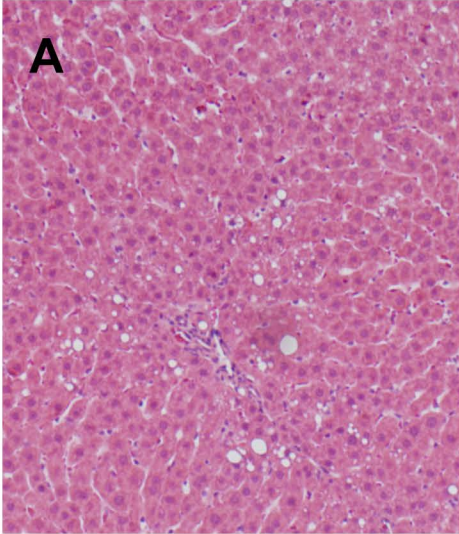


Supplemental Table

	Treatment Group	
	Control ASO (n=6)	ChREBP ASO (n=6)
Steatosis		
0	3	2
1	2	4
2	1	0
2	0	0
Portal Inflammation		
0	1	2
1	5	4
Lobular Inflammation		
0	4	5
1	2	1
Lipogranuloma		
0	5	4
1	1	2
Microgranuloma		
0	5	5
1	1	1
Ballooning		
0	4	4
1	2	2
2	0	0
NAS Score		
0	2	1
1	1	3
2	2	2
3	1	0
Fibrosis		
0	6	5
1	0	1
2	0	0

Control ASO

ChRBEP ASO



Representative photomicrographs of H&E sections of liver from fructose-fed rats treated with a Control ASO (right) or ChREBP ASO (left). Periportal steatosis was evident in both groups, as shown in Panels A&B. Panel C shows an area of periportal steatosis (long arrow indicated portal track) and microgranuloma (short arrow). Panel D demonstrates the presence of ballooning degeneration (short arrows).