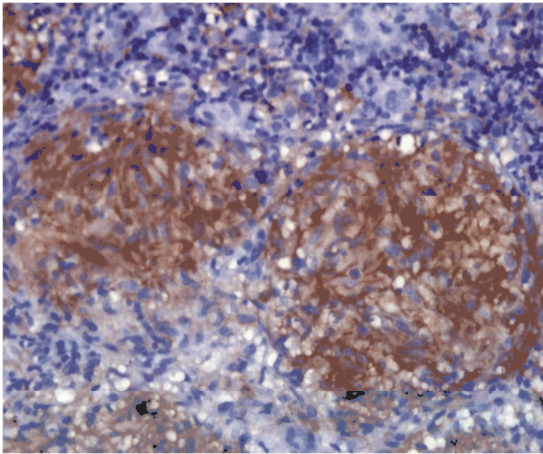
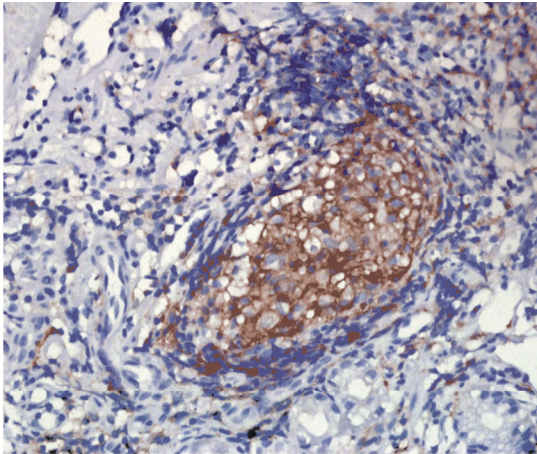


Supplementary Figure 1. Representative immunohistochemical staining for CD11c expression in granulomas from various diseases and tissues (magnification 400×).

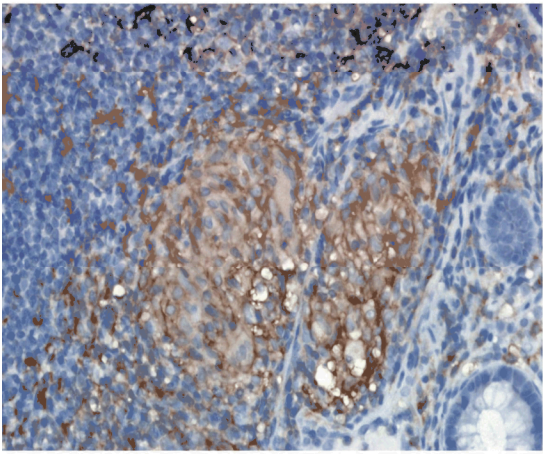
Supplemental Figure 1.



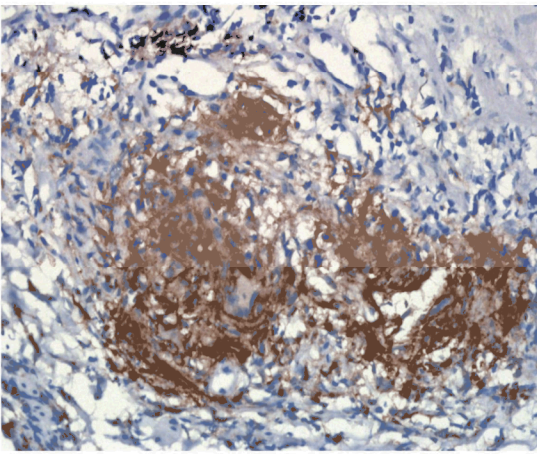
Esophageal tuberculosis



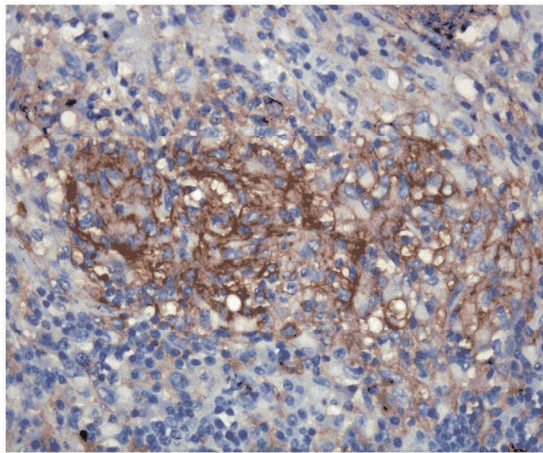
Stomach sarcoidosis



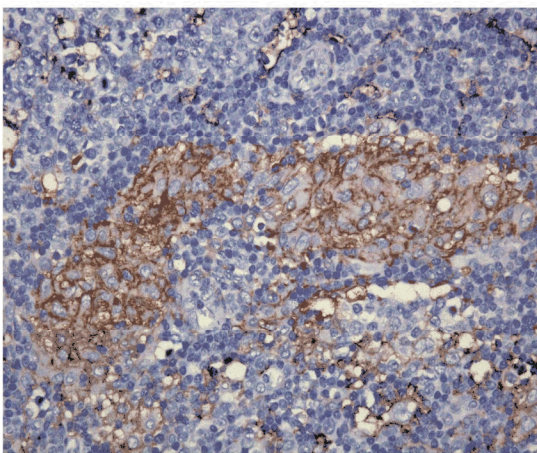
Crohn disease



Granulomatous gastritis



Groin granuloma



Epidermal cyst