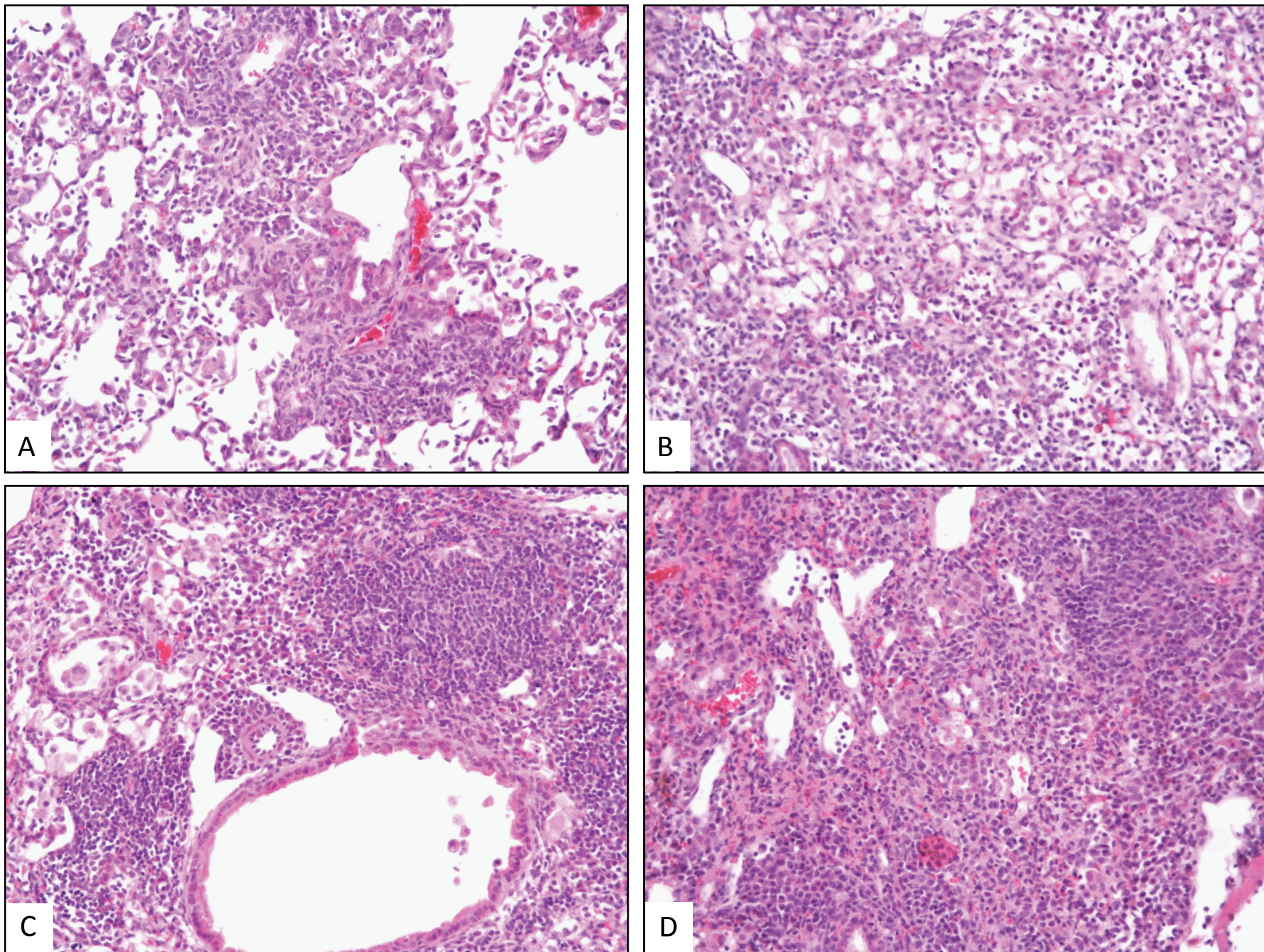


Supplemental Figure 3A. 20X Inflammation Scoring: A. Grade 1; B. Grade 2; C. Grade 3; D. Grade 4



Supplemental Figure 3A: Grading of inflammation lesions 20X.

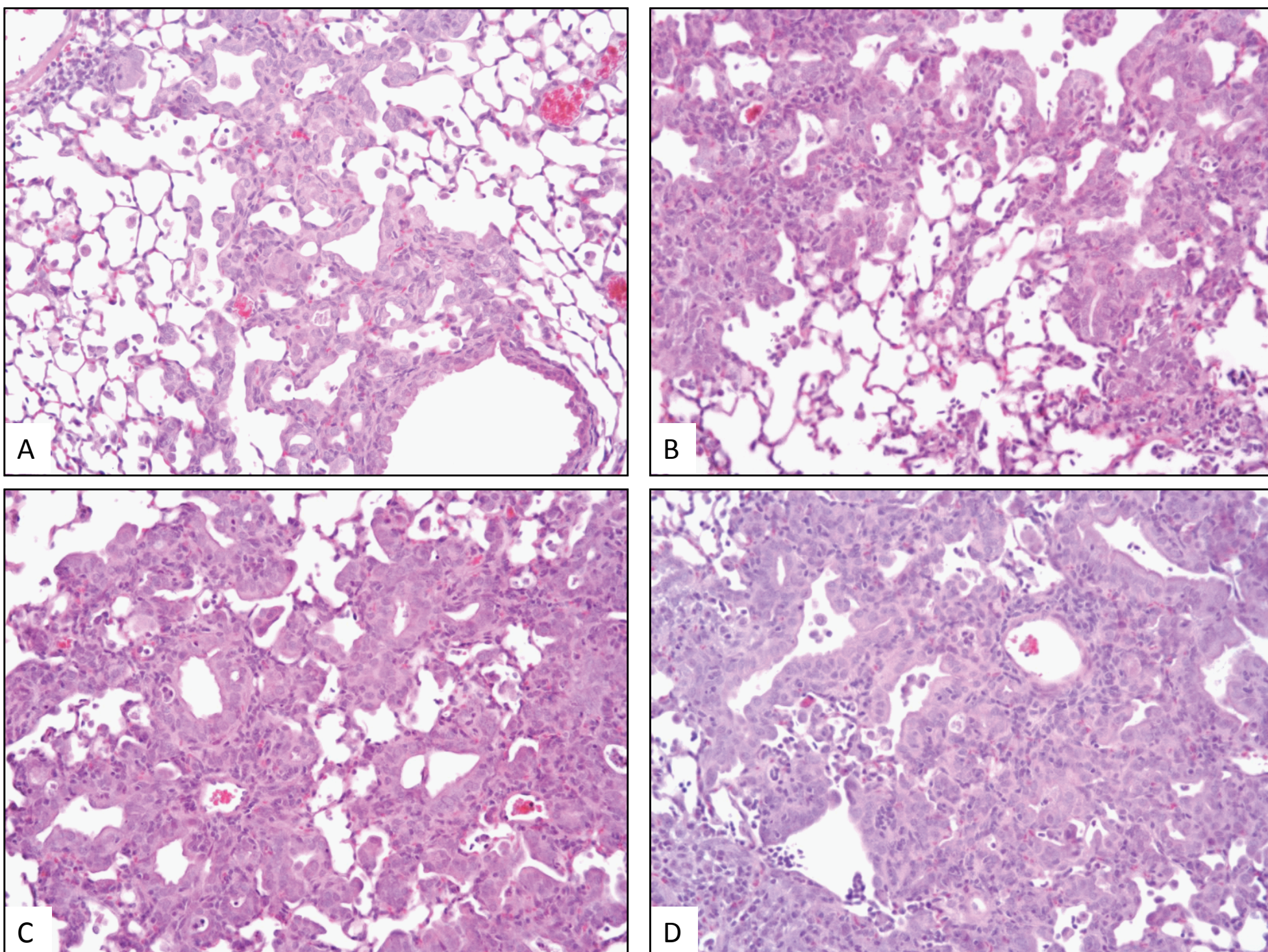
A. Grade 1: Mixed mononuclear cell infiltrate next to bronchus.

B. Grade 2: Diffuse monocyte Infiltration in alveolar spaces.

C. Grade 3: Mixed diffuse infiltrate and small focus of BALT .

D. Grade 4. Extensive dense collection of mixed mononuclear cells (BALT) as well as diffuse infiltrate.

Supplemental Figure 3B. 20X Proliferation scoring: A. Grade 1; B. Grade 2; C. Grade 3; D. Grade 4



Supplemental Figure 3B. Grading of epithelial cell proliferation 20X.

A. Grade 1: Extension of epithelial cells into alveoli next to bronchiole.

B and C. Grades 2 and 3: increasing area of epithelial cell proliferation into alveoli.

D. Grade 4: Large areas of section contain epithelial cells showing glandular formation without metaplasia.