

Marcus Richter
Louis-Philippe Amiot
Sylvia Neller
Patrick Kluger
Wolfhart Puhl

Computer-assisted surgery in posterior instrumentation of the cervical spine: an in-vitro feasibility study

Received: 12 November 1999
Accepted: 16 November 1999

M. Richter (✉) · P. Kluger · W. Puhl
Department of Orthopaedics
and Spinal Cord Injury,
University of Ulm, Ulm, Germany

L.-P. Amiot
Department of Orthopaedics,
Hôpital Sacré-Coeur, Montreal University,
Montreal, Canada

S. Neller
Department of Orthopaedic Research
and Biomechanics, University of Ulm,
Ulm, Germany

Present address:
M. Richter, RKU, Orthopädische Klinik
mit Querschnittgelähmtenzentrum
der Universität Ulm,
Oberer Eselsberg 45,
89081 Ulm, Germany
e-mail: marcus.richter@medizin.uni-ulm.de,
Tel.: +49-731-5112,
Fax: +49-731-1103

Abstract Transarticular C1/2 screws are widely used in posterior cervical spine instrumentation. The use of pedicle screws in the cervical spine remains uncommon. Due to superior biomechanical stability compared to lateral mass screws, pedicle screws can be used, especially for patients with poor bone quality or defects in the anterior column. Nevertheless there are potential risks of iatrogenic damage to the spinal cord, nerve roots or the vertebral artery associated with both posterior cervical spine instrumentation techniques. Therefore, the aim of this study was to evaluate whether C1/2 transarticular screws as well as transpedicular screws in C3 and C4 can be applied safely and with high accuracy using a computer-assisted surgery (CAS) system. We used 13 human cadaver C0-C5 spine segments. We installed 1.4-mm Kirschner wires transarticular in C1/2, using a specially designed guide, and drilled 2.5-mm pedicle holes in C3 and C4 with the assistance of the CAS system. Hole positions were evaluated by palpa-

tion, CT and dissection. Forty-eight (92%) of the 52 drilled pedicles were correctly positioned after palpation, imaging and dissection. The vertebral artery was not injured in any specimen. All of the 26 C1/2 Kirschner wires were placed properly after imaging and dissection evaluations. No injury to vascular or bony structures was observed. C1/2 transarticular screws as well as transpedicular screws in the cervical spine can be applied safely and with high accuracy using a CAS system in vitro. Therefore, this technique may be used in a clinical setting, as it offers improved accuracy and reduced radiation dose for the patient and the medical staff. Nevertheless, users should take note of known sources of possible faults causing inaccuracies in order to prevent iatrogenic damage. Small pedicles, with a diameter of less than 4.0 mm, may not be suitable for pedicle screws.

Key words Computer-assisted surgery · Cervical spine · Posterior instrumentation · In vitro

Introduction

Transarticular C1/2 screws are widely used in cervical spine instrumentation [17]. The biomechanical stability of C1/2 instrumentation with transarticular C1/2 screw fixation is superior to wiring techniques [15, 16, 47], resulting in lower non-union rates [11]. Nevertheless, there are potential risks of iatrogenic damage to the vertebral artery or

the spinal cord [1, 29, 37, 42]. Furthermore, the C1/2 joint needs to be passed in order for the C1 lateral mass to be fixed properly. This can be difficult to control with the image intensifier [48]. Other authors have already suggested that the use of a computer-assisted surgery (CAS) system in the cervical spine may be beneficial [30, 41, 46].

The use of pedicle-screw-based spinal instrumentation systems in the lumbar and thoracic spine has increased tremendously in the last decade, due to the superior bio-

mechanical properties and reposition possibilities [30]. In the lumbar and thoracic spine, conventional screw insertion techniques have been associated with lower screw misplacement rates in cadaver studies as well as clinical practice [8, 12, 18, 26, 27, 31, 32, 34, 36, 38].

The use of pedicle screws in the cervical spine remains uncommon, although promising clinical results have been published [2–4, 30]. Due to superior biomechanical stability of pedicle screws compared to lateral mass screws [21, 25], pedicle screws may be used instead, especially in patients with poor bone quality or multilevel instabilities. Nevertheless, depending on the size of the cervical pedicles and the proximity of the vertebral artery as well as the dural sac and the nerve roots, there are potential risks of iatrogenic damage to neural or vascular structures [9, 10, 21, 33].

The purpose of this study, therefore, is to evaluate the feasibility of installing transarticular C1-C2 screws as well as pedicle screws in the cervical spine using a CAS system.

Materials and methods

Thirteen human cadaveric cervical spine specimens (C0-C5) with a mean age of 76.2 ± 12.8 years were wrapped in triple-sealed plastic bags and kept frozen at -28°C prior to preparation and testing. The specimens were then thawed at room temperature and all musculature was removed while carefully preserving ligaments and bony structures.

Radiographs were taken of the intact specimen to detect serious neoplastic or degenerative disease. We used the Navitrack CAS system (Sulzer Orthopedics Ltd., Switzerland), which has been validated for the thoracic and lumbar spine [5, 7]. The optical tracking version of the CAS system was modified to fit our surgical instrumentation. Imaging of the specimens was performed using a helical CT scanner (Somatom Plus 4, Siemens, Germany), with a 1-mm non-overlapping slice thickness. Three-dimensional models of each vertebra from C1 to C4 were then produced with the CAS system. For each of those vertebrae, we defined registration surfaces that were easily identifiable in an operative context.

In the first part of the manipulation, pedicle holes were drilled at the C3 and C4 levels. We used a drill to prepare the pedicle screw holes according to our technique in the lumbar and thoracic spine. In our opinion, the advantage of the drill compared to a pedicle awl is the greater sensitivity to bony resistance due to reduced friction of the rotating drill. After registration of the proper vertebral level, pedicle screws were prepared with a 2.5-mm drill in all specimens. In order to avoid bending problems caused by the low stiffness of the 2.5-mm drill bit, we tracked a specially designed drill guide (Fig. 1), rather than the drill itself. The orientation of the pedicle holes was not chosen in the exact axis of the pedicle due to the ascending pedicle axis. The entrance point was chosen at the upper margin of the pedicle with a descending direction so that the drill would not perforate the upper endplate of the vertebra. The pedicle holes were drilled with the help of the CAS system (Figs. 2, 3), and the screw length was chosen as long as possible. Pedicle perforations were then manually controlled using a palpation probe in all four quadrants. Any loss of cortex sensation was then noted.

In the second part of the manipulation using the same specimens, C1-C2 transarticular instrumentation was performed with the CAS system. The C1-C2 transarticular instrumentation was done with a 1.4-mm Kirschner wire and a specially designed Kirsch-

ner wire guide (Fig. 4), which was tracked by the CAS system. The 1.4-mm Kirschner wire is suitable for use with newly developed cannulated 4.0-mm self-drilling and self-tapping screws. This type of instrumentation has the advantage over other methods that no dislocation between C1 and C2 can occur during insertion of the screw, as may happen after removal of a drill when using a non-cannulated system. The special Kirschner wire guide was calibrated and then tracked by the CAS system. In order to reproduce the in vivo conditions as far as possible, C1 and C2 were manipulated and displayed simultaneously by the CAS system. Registration was performed by installing the dynamic reference on the spinous process of C2. Under CAS guidance, a 1.4-mm Kirschner wire was positioned and installed with our special guide (Fig. 4). In a clinical context, cannulated 4.0-mm screws would have been installed over the Kirschner screws. However, since we were interested in validating the position of the Kirschner wires before screw installation, manipulations were then completed.

Both manipulations having been completed, the specimens were sent for CT image evaluation of the installed Kirschner wires in the C1-C2 transarticular space as well as evaluation of the drilled pedicle holes in C3 and C4. All images were acquired using 1-mm slice thickness. Positions were then assessed on a conventional CT display, with cursor facilities for error measurements.

Results

All 13 cadaveric specimens were recovered, and found free of neoplastic or serious degenerative disease. A total of 52 pedicle holes had been drilled and 26 C1/2 Kirschner wires had been placed.

Fifty holes (96%) drilled in C3 and C4 pedicles had a normal cortical palpation. Two holes (4%) had the feeling of a lateral cortical effraction (in specimens 1 and 3), both at the C3 level. In both cases, it was found that the dynamic reference had loosened. The dynamic reference base was then fixed again and the vertebra was registered again. After the new registration, drilling of the pedicle hole was repeated. CT evaluation of the specimens confirmed the lateral perforations at C3 on specimens 1 and 3. The perforations were evaluated at less than 1 mm. Two other medial perforations were detected, also under 1 mm, at C3 (right pedicle) and C4 (left pedicle), where the pedicle diameter was measured at under 4.0 mm. Thus, CT evaluation showed that 48 pedicle holes (92%) were in the correct position without perforation (Fig. 5). Interestingly, we obtained an exact correspondence between clinical palpation and CT scan in 50/52 cases (96%). Dissection did not reveal extracortical perforations. Vertebral arteries were found intact in 100% of specimens.

Twenty-six Kirschner wires (100%) were found correctly positioned, with no cortical effraction measured on the C1-C2 CT scans. The scans also showed correct positioning of the Kirschner wires when crossing the C1/2 joint and penetrating the lateral mass of C1 in all specimens. On visual inspection after complete dissection, no perforation of the groove of the vertebral artery in C2 was detected and no penetration of the Kirschner wires into the spinal canal was detected.

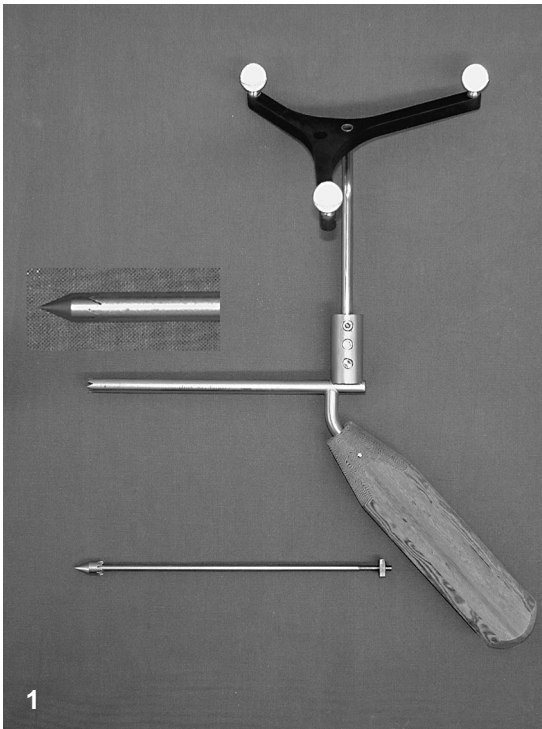


Fig. 1 Specially designed drill guide with adapter for the tracking system marker star. The drill guide is also used as pointer for the registration of the vertebra

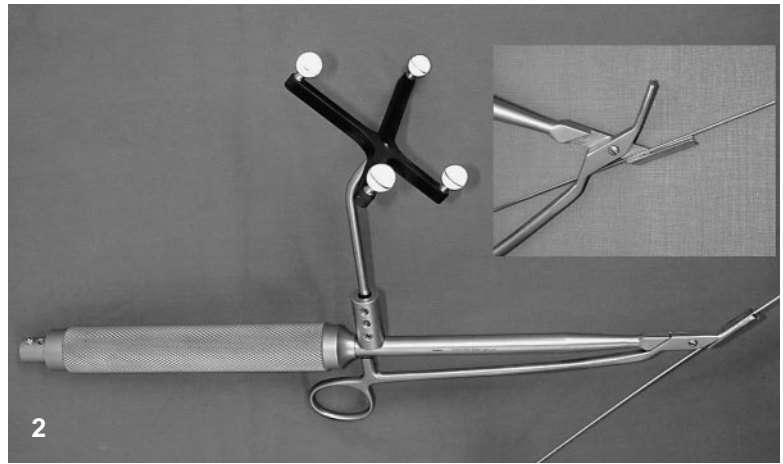


Fig. 2 Specimen with dynamic reference base fixed at the spinous process of C4, while drilling the left pedicle in C4

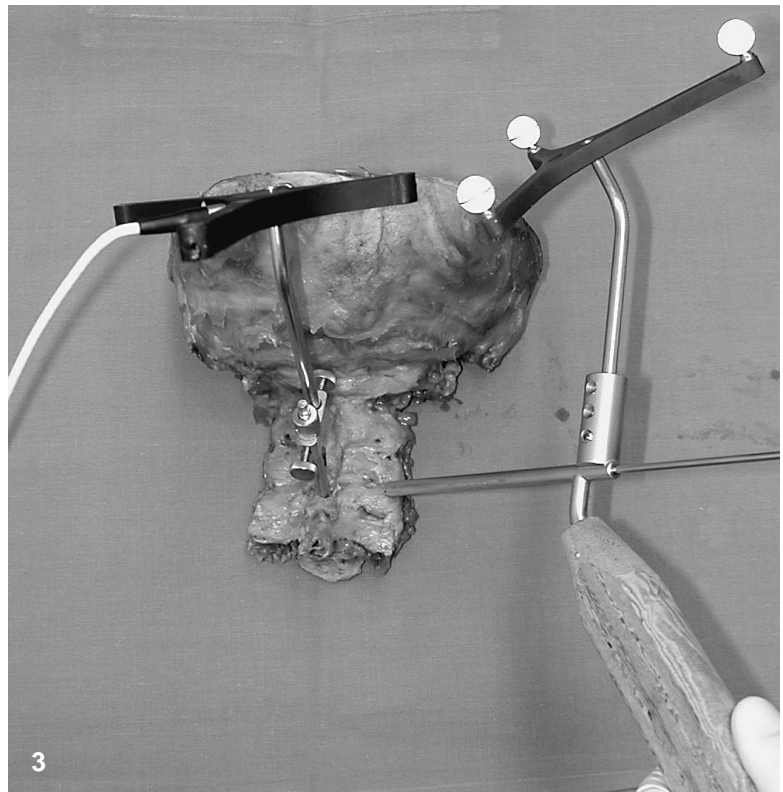


Fig. 3 Specially designed Kirschner wire guide with adapter for the tracking system marker star. The Kirschner wire guide can be opened and removed from the Kirschner wire even when used percutaneously

Discussion

Although pedicle instrumentation is very common in the lumbar and thoracic spine, it is uncommon in the cervical spine. This may be explained by the dimensions of the cervical pedicle and the proximity of vascular and neural structures. The most commonly used posterior instrumentation technique in the cervical spine, i.e., lateral mass screw fixation, results in a biomechanical stability clearly below the level of stability achieved with pedicle screws [21, 25]. This technique also carries a potential risk of iatrogenic damage to neural or vascular structures.

In 1993, CAS systems were developed for the installation of pedicle screws in the lumbar spine [6, 28, 34] based on reports of misplacement rates of between 5% and 40% using conventional techniques [13, 14, 19, 20, 39, 43–45]. In vitro studies showed that malplacement rates of pedicle screws would be significantly reduced using a CAS system [8, 24, 35, 36]. In vivo studies have confirmed those results [23, 27, 31, 32, 38].

To our knowledge, this is the first study to document the performance of a conventional spinal CAS system in the cervical spine. We extrapolated that the accuracy of these systems would also be sufficient for cervical spine surgery. The results are not statistically different from

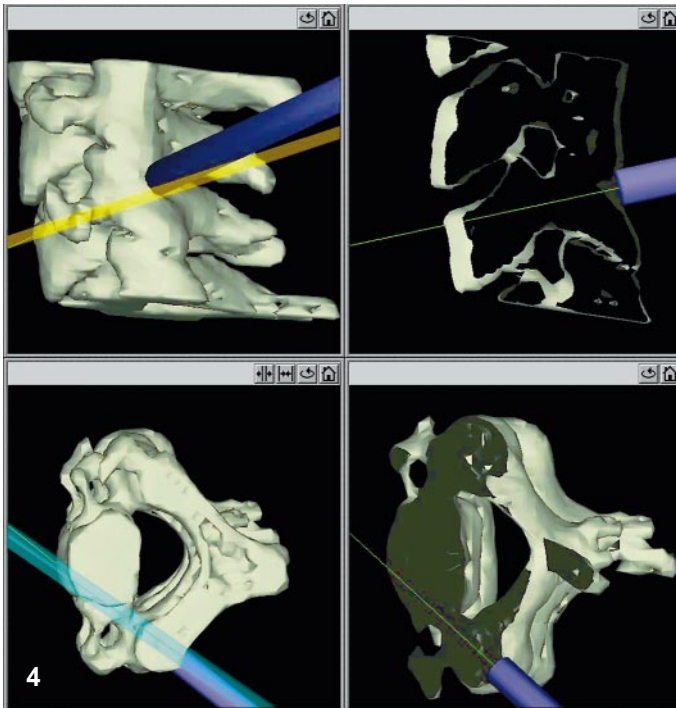
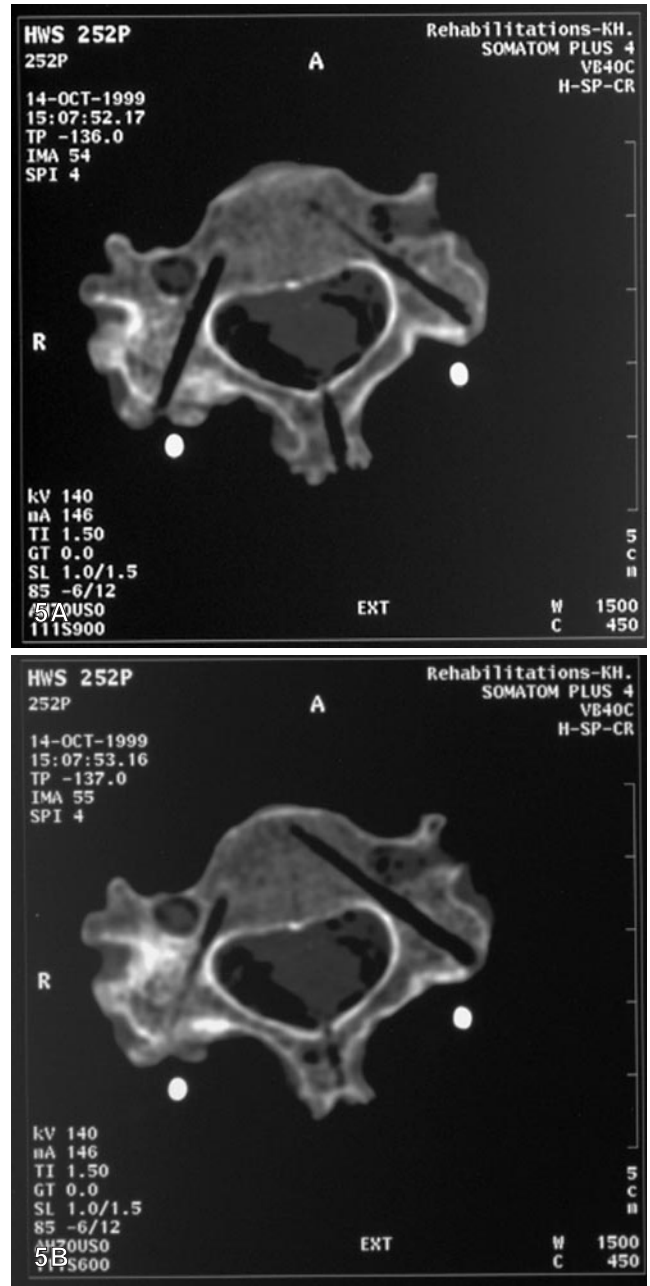


Fig. 4 Screen shot showing the CAS system screen during drilling of the left-pedicle hole in C4

Fig. 5 Example of a CT control scan after drilling of pedicle holes in C3; the bone screw hole in the spinous process can also be seen



other published CAS series relating to surgery in the thoracic or lumbar spine ($P > 0.10$) [5, 7].

We decided to use a drill to prepare the pedicles due to the reduced friction of a rotating drill compared to a pedicle awl. The reduced friction leads to greater sensitivity in feeling the bony structures passed while drilling the pedicle as well as in feeling the anterior wall of the vertebral body. As 2.5-mm drill bits bend a lot during drilling, which results in reduced accuracy, we designed a drill guide suitable for the CAS system. This drill guide can also be used as a pointer, and has a pointer insert, which means it can also be used for registration of the vertebra.

Our results show that this technique is suitable for pedicle instrumentation. We had a perforation rate of 8% without harm to vascular or neural structures. The two pedicle perforations due to loosening of the dynamic reference base (DRB) show that the fixation of the DRB at the vertebra should be carefully controlled before every surgical action. After the third specimen, we controlled the rigid fixation of the DRB and performed a validation of the drill guide before each pedicle drilling. In two cases we observed an inaccurate validation due to displacement of the DRB. After proper fixation of the DRB and a new registration of the vertebra, the pedicle holes were drilled

without perforation. Fixation of a reference on the small cervical spinous process is a major challenge. As conventional lumbar vertebral clamps are big, they will loosen more easily. Such fixations will have to be tailored to the size of cervical vertebrae. As a consequence of this study, the fixation of the DRB will be optimized in future.

The two minor perforations in pedicles with a width of less than 4.0 mm point to possible anatomic restrictions. In our opinion, pedicles with a width of less than 4.0 mm should not be instrumented with pedicle screws. The pedicle width of C3 averages 4.9 mm in males and 4.5 mm in females; the minimum width reported is 3.0 mm. The width of C4 averages 4.7 mm in males and 4.6 mm in females; the minimum width reported is 3.1 mm [10]. The pedicle width in C5 and C6 is slightly higher. These anatomic data show that some pedicles may not be suitable for pedicle screws. Therefore, pedicle width should be measured preoperatively using CT to prevent iatrogenic damage, and should be taken into consideration in the preoperative planning concerning the type of instrumentation.

In contrast to pedicle instrumentation, transarticular screw fixation in C1/2 is very common in cervical spine surgery [17]. The biomechanical stability of C1/2 instrumentation with transarticular C1/2 screw fixation is superior to wiring techniques [15, 16, 47], resulting in lower non-union rates [11]. Nevertheless, there are potential risks of iatrogenic damage to the vertebral artery, the spinal cord or the nerve roots [1, 29, 37, 42]. Furthermore, the C1/2 joint should be passed, in order that the C1 lateral mass is fixed properly [22]. This is not always easy to control with the image intensifier [48]. Therefore, the use of a CAS system may be beneficial. Besides, it may be difficult to prepare the C1/2 drill hole with a straight drill in the reduced position of the C1/2 segment due to anatomical reasons. For these reasons, we have opted for Kirschner wires to prepare the screw hole. To apply the Kirschner wires properly, a special Kirschner wire guide was designed, suitable for the CAS system. The Kirschner wires placed with the Kirschner wire guide were all posi-

tioned correctly, with perforation of bony structures. As the full length of the Kirschner wire can not be visualized with the CAS system, an additional image intensifier should be used to control the position of the Kirschner wire at the anterior aspect of C1. As the reposition maneuver is also performed using an image intensifier, this is no problem. Our data showed that the C1/2 instrumentation using a CAS system is suitable for the clinical setup. Compared to the normal technique of placing C1/2 screws with image intensifiers in two planes, radiation exposure will be reduced for the patient and the medical staff [40]. Therefore, we recommend the CAS procedure for C1/2 instrumentation. If cannulated screws should not be used, a 2.5-mm Kirschner wire or a 2.5-mm drill can be used with a modified Kirschner wire guide or a drill guide in the same way as with the pedicle screws.

Conclusions

This study evaluated two types of posterior instrumentation techniques of the cervical spine in combination with a CAS system in vitro. The study showed that pedicle instrumentations in the cervical spine and transarticular C1/2 instrumentations can be performed without risk of iatrogenic damage when using a CAS system and taking into account potential sources of inaccuracies as well as anatomic limitations. Our results did not differ significantly from other results published for CAS systems used in the thoracic and lumbar spine. Users should take note of known sources of possible faults causing inaccuracies, e.g., loosening or displacement of the dynamic reference, to prevent iatrogenic damage. Small pedicles with a width of less than 4.0 mm may not be suitable for pedicle screws.

Acknowledgement The authors would like to thank Mr. A. Okapuu-von Veh and Mr. D. Picard, Orthosoft Inc., Canada, for their technical support.

References

1. Abou Madawi A, Solanki G, Casey AT, Crockard HA (1997) Variation of the groove in the axis vertebra for the vertebral artery. Implications for instrumentation. *J Bone Joint Surg Br* 79: 820–823
2. Abumi K, Itoh H, Taneichi H, Kaneda K (1994) Transpedicular screw fixation for traumatic lesions of the middle and lower cervical spine: description of the techniques and preliminary report. *J Spinal Disord* 7: 19–28
3. Abumi K, Kaneda K, Shono Y, Fujiya M (1999) One-stage posterior decompression and reconstruction of the cervical spine by using pedicle screw fixation systems. *J Neurosurg* 90: 19–26
4. Abumi K, Takada T, Shono Y, Kaneda K, Fujiya M (1999) Posterior occipitocervical reconstruction using cervical pedicle screws and plate-rod systems. *Spine* 24: 1425–1434
5. Amiot LP, Bellefleur C, Labelle H (1997) In vitro evaluation of computer-assisted pedicle screw system. *Ann Chir* 51: 854–860
6. Amiot LP, Labelle H, DeGuise JA, Sati M, Brodeur P, Rivard CH (1995) Computer-assisted pedicle screw fixation. A feasibility study. *Spine* 20: 1208–1212
7. Amiot LP, Lang K, Putzier M, De Guise J, Zippel H, Labelle H. (1998) Comparative accuracy between conventional and computer assisted pedicle screw installation. *Scoliosis Research Society 33rd Annual Meeting*, New York, September 1998
8. Berlemann U, Monin D, Arm E, Nolte LP, Ozdoba C (1997) Planning and insertion of pedicle screws with computer assistance. *J Spinal Disord* 10: 117–124
9. Ebraheim N, Rollins JR Jr, Xu R, Jackson WT (1996) Anatomic consideration of C2 pedicle screw placement. *Spine* 21: 691–695

10. Ebraheim NA, Xu R, Knight T, Yeasting RA (1997) Morphometric evaluation of lower cervical pedicle and its projection. *Spine* 22: 1–6
11. Farey ID, Nadkarni S, Smith N (1999) Modified Gallie technique versus transarticular screw fixation in C1-C2 fusion. *Clin Orthop* 126–135
12. George DC, Krag MH, Johnson CC, Van H, ME, Haugh LD, Grobler LJ (1991) Hole preparation techniques for transpedicle screws: effect on pull-out strength from human cadaveric vertebrae. *Spine* 16: 181–184
13. Gertzbein SD, Robbins SE (1990) Accuracy of pedicular screw placement in vivo. *Spine* 15: 11–14
14. Glossop ND, Hu RW, Randle JA (1996) Computer-aided pedicle screw placement using frameless stereotaxis. *Spine* 21: 2026–2034
15. Grob D, Crisco JJ, Panjabi MM, Wang P, Dvorak J (1992) Biomechanical evaluation of four different posterior atlantoaxial fixation techniques. *Spine* 17: 480–490
16. Grob D, Dvorak J, Panjabi MM, Hayek J (1991) Die dorsale atlantoaxiale Verschraubung. Ein Stabilitätstest in vitro und in vivo. *Orthopäde* 20: 154–162
17. Grob D, Jeanneret B, Aebi M, Markwalder TM (1991) Atlanto-axial fusion with transarticular screw fixation. *J Bone Joint Surg Br* 73: 972–976
18. Jeanneret B, Magerl F (1990) Congenital fusion C0-C2 associated with spondylolysis of C2. *J Spinal Disord* 3: 413–417
19. Jerosch J, Malms J, Castro WH, Wagner R, Wiesner L (1992) Lagekontrolle von Pedikelschrauben nach instrumentierter dorsaler Fusion der Lendenwirbelsäule. *Z Orthop* 130: 479–483
20. Jia LS (1989) Dynamic change in the ligamenta flava of the cervical spine in motion (English abstract). *Chung Hua Wai Ko Tsa Chih* 27: 561–565
21. Jones EL, Heller JG, Silcox DH, Hutton WC (1997) Cervical pedicle screws versus lateral mass screws. Anatomic feasibility and biomechanical comparison. *Spine* 22: 977–982
22. Jun BY (1998) Anatomic study for ideal and safe posterior C1-C2 transarticular screw fixation. *Spine* 23: 1703–1707
23. Kalfas IH, Kormos DW, Murphy MA, McKenzie RL, Barnett GH, Bell GR, Steiner CP, Trimble MB, Weisenberger JP (1995) Application of frameless stereotaxy to pedicle screw fixation of the spine. *J Neurosurg* 83: 641–647
24. Kamimura M, Ebara S, Itoh H, Tateiwa Y, Kinoshita T, Takaoka K (1999) Accurate pedicle screw insertion under the control of a computer-assisted image guiding system: laboratory test and clinical study. *J Orthop Sci* 4: 197–206
25. Kotani Y, Cunningham BW, Abumi K, McAfee PC (1994) Biomechanical analysis of cervical stabilization systems. An assessment of transpedicular screw fixation in the cervical spine. *Spine* 19: 2529–2539
26. Laine T, Makitalo K, Schlenzka D, Tallroth K, Poussa M, Alho A (1997) Accuracy of pedicle screw insertion: a prospective CT study in 30 low back patients. *Eur Spine J* 6: 402–405
27. Laine T, Schlenzka D, Makitalo K, Tallroth K, Nolte LP, Visarius H (1997) Improved accuracy of pedicle screw insertion with computer-assisted surgery. A prospective clinical trial of 30 patients. *Spine* 22: 1254–1258
28. Lavallee S, Sautot P, Troccaz J, Cinquin P, Merloz P (1995) Computer-assisted spine surgery: a technique for accurate transpedicular screw fixation using CT data and a 3-D optical localizer. *J Image Guid Surg* 1: 65–73
29. Lu J, Ebraheim NA, Yang H, Heck BE, Yeasting RA (1998) Anatomic considerations of anterior transarticular screw fixation for atlantoaxial instability. *Spine* 23: 1229–1235; discussion 1236
30. Ludwig SC, Kramer DL, Vaccaro AR, Albert TJ (1999) Transpedicle screw fixation of the cervical spine. *Clin Orthop* 358: 77–88
31. Merloz P, Tonetti J, Pittet L, Coulomb M, Lavallee S, Sautot P (1998) Pedicle screw placement using image guided techniques. *Clin Orthop* 354: 39–48
32. Merloz P, Tonetti J, Pittet L, Coulomb M, Lavallee S, Troccaz J, Cinquin P, Sautot P (1998) Computer-assisted spine surgery. *Comput Aided Surg* 3: 297–305
33. Miller RM, Ebraheim NA, Xu R, Yeasting RA (1996) Anatomic consideration of transpedicular screw placement in the cervical spine. An analysis of two approaches. *Spine* 21: 2317–2322
34. Nolte L, Zamorano L, Arm E, Visarius H, Jiang Z, Berlerman U, Schwarzenbach O (1996) Image-guided computer-assisted spine surgery: a pilot study on pedicle screw fixation. *Stereotact Funct Neurosurg* 66: 108–117
35. Nolte L-P, Zamorano LJ, Jiang Z, Wang Q, Langlitz F, Berlemann U (1995) Image-guided insertion of transpedicular screws a laboratory setup. *Spine* 20: 497–500
36. Nolte LP, Zamorano L, Visarius H, Berlemann U, Langlotz F, Arm E, Schwarzenbach O (1995) Clinical evaluation of a system for precision enhancement in spine surgery. *Clin Biomech* 10: 193–203
37. Paramore CG, Dickman CA, Sonntag VK (1996) The anatomical suitability of the C1-2 complex for transarticular screw fixation. *J Neurosurg* 85: 221–224
38. Schwarzenbach O, Berlemann U, Jost B, Visarius H, Arm E, Langlotz F, Nolte LP, Ozdoba C (1997) Accuracy of computer-assisted pedicle screw placement. An in vivo computed tomography analysis. *Spine* 22: 452–458
39. Sim E (1993) Location of transpedicular screws for fixation of the lower thoracic and lumbar spine. Computed tomography of 45 fracture cases. *Acta Orthop Scand* 64: 28–32
40. Slomczykowski M, Roberto M, Schneeberger P, Ozdoba C, Vock P (1999) Radiation dose for pedicle screw insertion. Fluoroscopic method versus computer-assisted surgery. *Spine* 24: 975–982; discussion 983
41. Solanski GA, Crockard HA (1999) Perioperative determination of safe superior transarticular screw trajectory through the lateral mass. *Spine* 14: 1477–1482
42. Vaccaro AR, Ring D, Scuderi G, Garfin SR (1994) Vertebral artery location in relation to the vertebral body as determined by two-dimensional computed tomography evaluation. *Spine* 19: 2637–2641
43. Vaccaro AR, Rizzolo SJ, Balderston RA, Allardyce TJ, Garfin SR, Dolinskas C, An HS (1995) Placement of pedicle screws in the thoracic spine. II: An anatomical and radiographic assessment. *J Bone Joint Surg Am* 77: 1200–1206
44. Weightman B, Simon S, Rose R, Paul I, Radin E (1972) Environmental fatigue testing of silastic finger joint prostheses. *J Biomed Mater Res Symposium* 3: 15–24
45. Weinstein JN, Spratt KF, Spengler D, Brick C, Reid S (1988) Spinal pedicle fixation: reliability and validity of roentgenogram-based assessment and surgical factors on successful screw placement. *Spine* 13: 1012–1018
46. Welch WC, Subach BR, Pollack IF, Jacobs GB (1997) Frameless stereotactic guidance for surgery of the upper cervical spine. *Neurosurgery* 40: 958–963; discussion 963, 964
47. Wilke H-J, Fischer K, Kugler A, Magerl F, Claes L, Wörsdorfer O (1992) In vitro investigations of internal fixation systems of the upper cervical spine. II. Stability of posterior atlanto-axial fixation techniques. *Eur Spine J* 1: 191–199
48. Xu R, Ebraheim NA, Misson JR, Yeasting RA (1998) The reliability of the lateral radiograph in determination of the optimal transarticular C1-C2 screw length. *Spine* 23: 2190–2194