

Treatment of chronic osteomyelitis using calcium hydroxyapatite ceramic implants impregnated with antibiotic

Y. Yamashita, A. Uchida, T. Yamakawa, Y. Shinto, N. Araki, K. Kato

Department of Orthopaedic Surgery, Mie University and Osaka University, Japan

Accepted: 15 October 1997

Summary. *We treated eighteen patients with chronic osteomyelitis by implanting pieces of antibiotic-impregnated calcium hydroxyapatite ceramic into a cavity produced after thorough surgical excision of necrotic tissue. Within three months the infected sites had all healed. During follow-up ranging from 24 to 75 months there was no recurrence of infection. Two of the patients had infected prosthetic joints which were successfully revised. Infection was controlled and incorporation of the ceramic material into host bone was demonstrated radiographically. We recommend the use of porous pieces of calcium hydroxyapatite impregnated with antibiotic as a new system for drug delivery in the treatment of chronic osteomyelitis.*

Résumé. *Les auteurs rapportent le traitement de 18 patients atteints d'ostéomyélite chronique par excision chirurgicale suivie d'implantation de fragments d'hydroxyapatite de calcium imprégnés d'antibiotique. Tous les sites d'infection ont cicatrisé dans un délai de 3 mois. Pendant la période de suivi, allant de 24 à 75 mois, il n'y a pas eu de récurrence de l'infection. 2 des patients avaient une infection sur prothèse articulaire qui ont été révisés avec succès. En plus du contrôle de l'infection, il a été constaté radiologiquement une incorporation de l'hydroxyapatite. Les auteurs recommandent donc l'utilisation de ces fragments poreux d'hydroxyapatite de calcium imprégnés d'antibiotique pour le traitement de l'ostéomyélite chronique.*

Introduction

Chronic osteomyelitis remains a common problem, particularly in the developing world, despite advances in surgery and more than fifty years of experience with antibiotic therapy. Two principles of treatment are paramount; tissue which is necrotic or has a blood supply which is insufficient to promote the normal healing process must be removed, and then appropriate antibiotic therapy must be administered [10].

Antibiotic drugs, by themselves, do not provide reliable long-term arrest of chronic osteomyelitis. A high concentration of antibiotics can be obtained at the site of the infection, at least for short periods, by incorporating the drug into a delivery vehicle which is implanted locally [7]. Several methods have been used, including regional perfusion [11], external closed suction-irrigation [5], implantable pump irrigation [12] and antibiotic-impregnated implants. The materials used for impregnation with antibiotic include the patient's own blood [16], plaster of Paris pellets [6], fibrin [16], acrylic resin [8], collagen [1] and acrylic bone cement [4, 13]. Ceramic materials are well known for their applications in orthopaedic surgery, particularly as a coating for joint prostheses, and for articulating surfaces such as femoral heads and acetabulae. Porous calcium hydroxyapatite (CHA) has excellent biocompatibility, can resist mechanical forces, and is effective in filling cavities and defects in bone [15]. We have previously reported the use of porous CHA as a slow release system for antibiotics after using it to fill the space left after erosion by disease or excision of dead bone [9, 14] and emphasised its effectiveness in managing osteomyelitis.

Table 1. Details of the patients

Cases	Age/sex	Location	Organism	Antibiotics	Treatment	Follow-up (months)
1	77.M	L-tibia	<i>Pseudomonas aeruginosa</i>	IPM/CS 0.5 g	Curettage+CHA	72
2	57.F	R-tibia	<i>Staphylococcus aureus</i>	FMOX 0.5 g	Curettage+CHA	72
3	55.F	L-1st toe prox.phalanx	<i>Streptococcus pyogenes</i>	CZON 0.5 g PIPC 0.5 g	Curettage+CHA	60
4	22.M	L-tibia	<i>MRSA</i>	VCM 2.0 g	Curettage+CHA	48
5	14.F	L-femur	<i>MRSA</i>	IPM/CS 0.5 g CMZ 0.5 g	Curettage+CHA	24
6	35.M	R-prox.humerus	<i>Staphylococcus aureus</i>	FMOX 0.5 g CMZ 0.5 g	Curettage+CHA	65
7	27.F	L-prox.tibia	<i>Staphylococcus aureus</i>	FMOX 0.5 g PIPC 0.5 g	Curettage+CHA	75
8	17.F	L-dist.tibia-Ankle	<i>Staphylococcus aureus</i>	FMOX 0.5 g PIPC 0.5 g	Curettage+CHA	70
9	32.F	L-prox.tibia	<i>Staphylococcus epidermidis</i>	FMOX 0.5 g	Curettage+CHA	62
10	22.M	R-prox.tibia	<i>Staphylococcus aureus</i>	GM 0.5 g CMZ 0.5 g	Curettage+CHA	35
11	15.F	L-dist.femur	<i>Staphylococcus epidermidis</i>	FMOX 0.5 g	Curettage+CHA	39
12	45.M	L-prox.tibia	<i>MRSA</i>	IPM/CS 0.5 g VCM 1.0 g	Curettage+CHA	45
13	38.M	R-prox.tibia	<i>Streptococcus pneumoniae</i>	CMZ 1.0 g	Curettage+CHA	53
14	70.M	Lumbar spine (II)	<i>Klebsiella pneumoniae</i>	FMOX 0.5 g CMZ 0.5 g	Curettage+CHA	38
15	41.M	R-femur	<i>Pseudomonas aeruginosa</i>	IPM/CS 0.5 g GM 0.5 g	Infection of artificial body CHA.Prosthesis Revision 3 months later	42
16	37.F	L-femur	Unknown	FMOX 0.5 g GM 0.5 g	CHA. infection of tumour prosthesis Revision 6 months later	34
17	40.M	L-dist.tibia	Unknown	FMOX 0.5 g	Curettage+CHA	68
18	52.M	R-prox.humerus	Unknown	FMOX 0.5 g GM 0.5 g	Curettage+CHA	46

MRSA (methicillin resistant staphylococcus aureus); IPM/CS (imipenem/cilastatin sodium); FMOX (flomoxef sodium); CZON (cefzonam sodium); PIPC (piperacillin sodium); VCM

(vancomycin hydrochloride); GM (gentamicin sulfate); CMZ (cefmetazol sodium)

Materials and methods

We have treated ten men and eight women with chronic osteomyelitis using the principles of surgical debridement, systemic administration of antibiotics, and local implantation of CHA impregnated with an antibiotic. The mean age of the patients at the time of treatment was 38.7 years (range: 14 to 77). The duration of chronicity was judged to be from 12 to 132 months (mean: 35 months). At the time of initial presentation all patients had clinical and/or radiological evidence of chronic osteomyelitis. The chronic infection had occurred after acute haematogenous osteomyelitis in 12 patients, following open fracture in three, after closed fracture in one, and after joint replacement in two. Nine patients had one or more draining sinuses. Eleven had undergone surgery for the condition prior to our new form of treatment.

Each site of infection was initially aspirated in order to detect a causative organism. Organisms could be cultured from 15 patients; eight grew *Staphylococcus aureus*, two *Staphylococcus epidermidis*, one *Streptococcus pyogenes*, one *Streptococcus pneumoniae*, one *Klebsiella pneumoniae*, and two *Pseudomonas aeruginosa*. The choice of antibiotic for impregnation into the CHA ceramic was determined by the sensitivity of the cultured organism. In the three patients in whom no organisms were grown a broad spectrum antibiotic was selected (Table 1). We assessed healing in terms of the clinical picture, laboratory findings and radiological evidence of incorporation of the CHA implant with remodelling of surrounding bone. The duration of follow-up was from 24 to 75 months (average: 52.7 months).

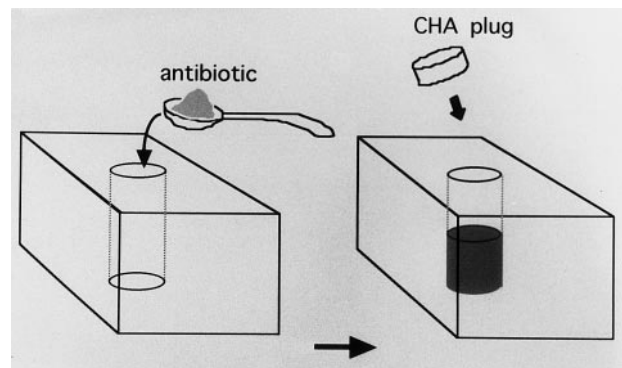


Fig. 1. Diagram of an antibiotic-CHA ceramic block. The small cylindrical hole made by ultrasound is packed with powdered antibiotics and sealed with a CHA plug

Preparation of antibiotic impregnated CHA ceramic

Various sizes of CHA ceramic blocks were sintered at 1,200°C for 2 h. They had a porosity of 30% to 40%, the diameter of the micropores was between 40 and 150 µm and there was an interconnecting pore structure open to the external surface of the blocks. At operation the chosen antibiotic was packed into a central cylindrical cavity in each porous block and sealed with a CHA plug (Sumitomo Osaka Cement Co., Ltd., Japan) (Fig. 1). The volume of antibiotics packed into the cavity depended upon the size of the blocks used. The usual dose ranged from 100 to 400 mg. The antibiotics used, either alone, or in combination, and the total doses which were employed, are shown in Table 1.

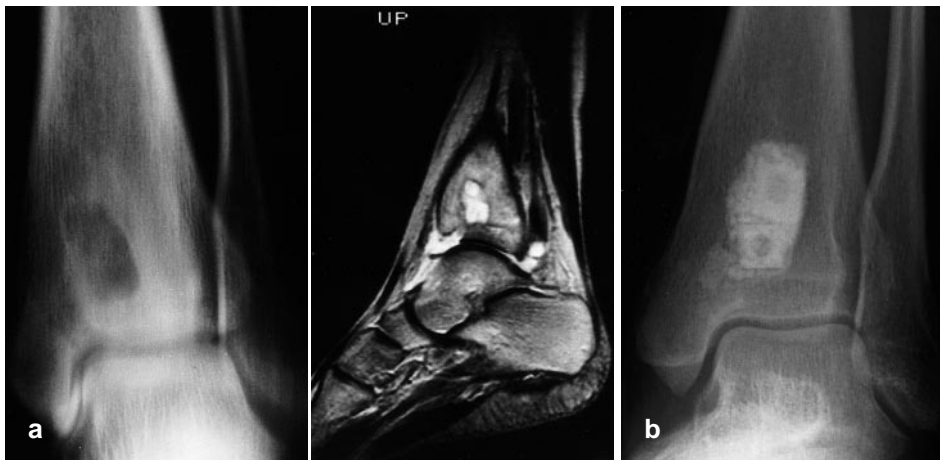


Fig. 2. **a** Anterior-posterior tomoradiograph and MRI image of the distal tibia and right ankle of a 17-year-old woman with septic arthritis. **b** The joint and the abscess of the distal tibia were treated surgically by excision of necrotic tissue followed by insertion of CHA ceramic blocks which had been impregnated with Flomoxef sodium and Piperacillin sodium (Case 8, Table 1). Inflammatory signs around the ankle and distal tibia settled and laboratory findings were normal within eight weeks. Six years later there had been no recurrence

Operative technique. The bone cortex was fenestrated to a size which permitted removal of all necrotic bone, sequestrum, and pathological granulation tissue. The excavated defect in the bone was then packed with the CHA ceramic block which had been impregnated with the chosen antibiotic until it had been completely filled. After operation a superficial suction drain was sometimes employed for up to 24 h.

Results

At the latest follow-up all foci in each of the eighteen patients were completely healed. Twelve had pain relief and evidence of improvement on laboratory tests within four weeks of operation. In the remainder there was resolution of infection within 12 weeks. There was no recurrence of infection in any of the patients.

One patient had septic arthritis of the ankle in association with a Brodie's abscess in the tibial epimetaphysis. Function was restored to the joint after eradication of the bone infection (Fig. 2). Another patient had infection around a megaprosthesis which had been inserted after resection of a tumour at the knee. The prosthesis was removed and an external fixator applied to support the bones while the antibiotic-impregnated CHA ceramic was in place. Three months later another megaprosthesis was inserted, after the laboratory tests had become normal. Five years after the revision there had been no recurrence of the tumour or of the infection (Fig. 3).

Sequential radiographs showed that there was progressive incorporation of the CHA ceramic in all patients (Fig. 4). Radiolucent zones around the implant

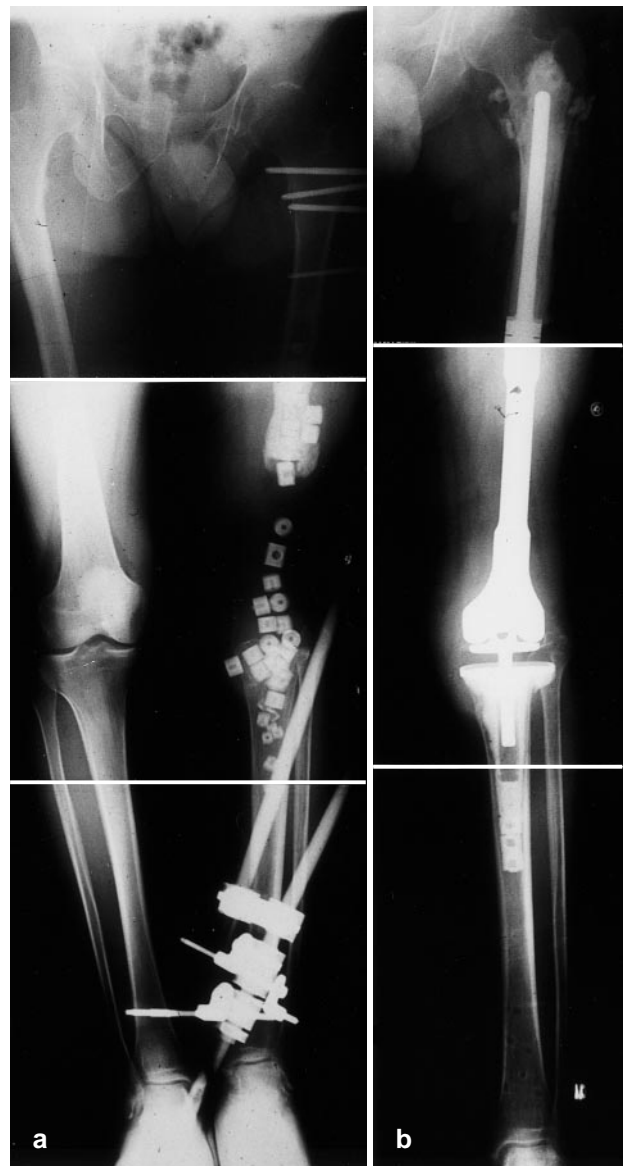


Fig. 3a, b. Radiographs after the first (a) and second (b) stages of treatment for chronic osteomyelitis around a megaprosthesis inserted after resection of the distal femur for osteosarcoma in a male aged 40 years. The infection was apparent two years after initial treatment, and did not respond to systemic antibiotic administration. The first stage was to remove the prosthesis and surrounding infected tissues, insert CHA ceramic impregnated with Flomoxef sodium and Gentamicin sulfate (as no causative organism was cultured), and to support the limb

with an external fixator. Three months later the second stage was carried out, with removal of some of the ceramic blocks and reinsertion of a megaprosthesis. Five years later there had not been a recurrence. (Case 16, Table 1)

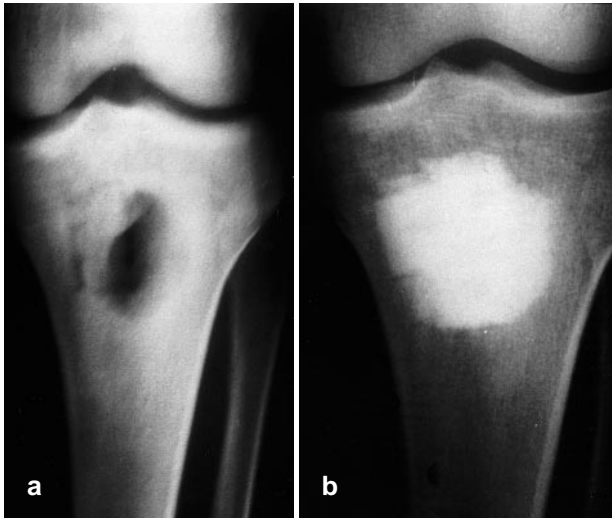


Fig. 4. **a** Radiograph showing a chronic osteomyelitic cavity in the proximal end of a tibia before treatment, and **(b)** five years after management by the method described in this article. The ceramic blocks appear to be incorporated into bone which has formed and remodelled around them. There is no evidence of translucency which might be suggestive of either infection or the presence of a fibrous membrane

gradually disappeared over six months, and in some instances sclerotic areas developed around the CHA blocks. There was no radiological evidence of breakdown of the ceramic, but in those patients in whom we performed 'second look' surgery after healing there was some histological evidence of degradation of the

implanted ceramic material. These changes were most evident around the multinucleated cells which were lodged in close contact to the ceramic (Fig. 5).

Discussion

Although there appears to have been a reduction in the incidence of recurrent acute episodes in chronic osteomyelitis since the systemic use of antibiotic drugs, this is suppression rather than cure. Not all exacerbations can be suppressed by antibiotics. The increase in joint replacement surgery has emphasised the importance of preventing and treating infection around the prostheses. Because of the altered structure of the tissues surrounding an infected site, the diffusion of antibiotics into the central part of the infected region may require high serum concentrations of the therapeutic agents.

This therapy may cause side effects such as myelosuppression, renal failure, and hepatitis. It is possible to increase the local concentration of antibiotics by impregnating them into carrier vehicles. Polymethylmetacrylate (PMMA) used as a bone cement has been the most widely evaluated [2, 3, 4]. The disadvantages include reduced biocompatibility with bone, the short duration of antibiotic release, a very low release rate, thermal damage to the antibiotic, and the need to remove the PMMA at the end of treatment. Nevertheless, this method has been widely used in the staged surgical treatment of chronic osteomyelitis.

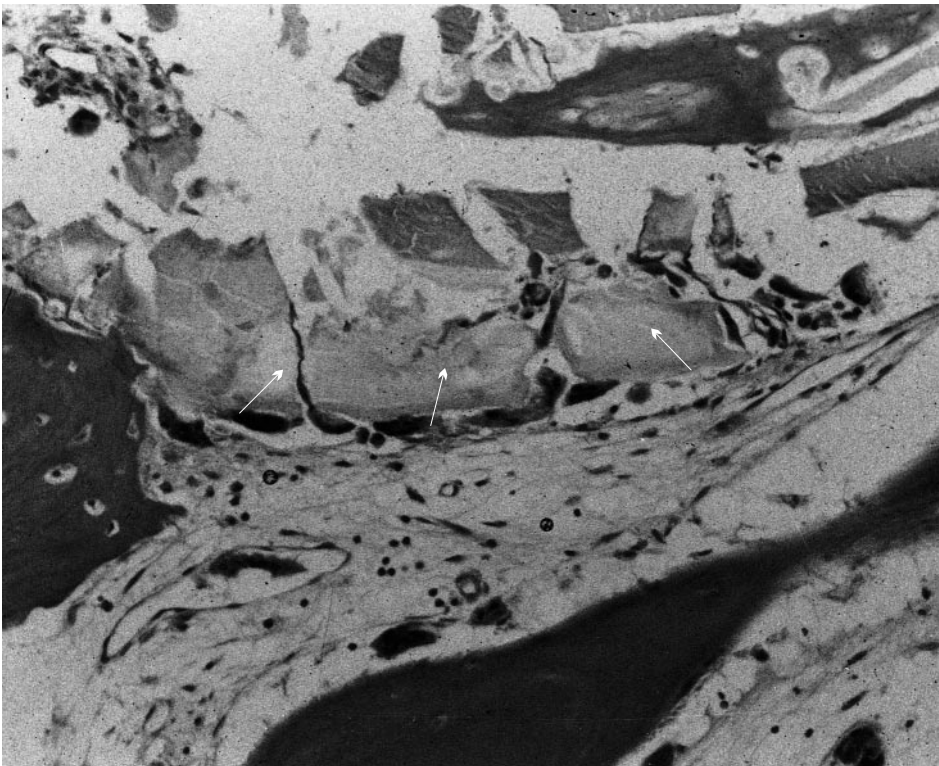


Fig. 5. Histological appearance of the degradation of the ceramic blocks. CHA (arrows) was degraded around multinucleated giant cells

We consider that antibiotic-impregnated CHA ceramic is superior to acrylic bone cement systems. Any antibiotic can be placed in a CHA ceramic cylinder as there is no thermal damage to the drug. All of the impregnated antibiotic is released over a long period and none remains trapped. CHA ceramic is fully biocompatible with bone and marrow cells which grow into the pores. Mechanical stability depends on the porosity of the material. The antibiotic-CHA ceramic composites control the infection, restore mechanical strength, encourage osteoconduction into their pores, and avoid the need for further surgery. We believe that local signs of inflammation and abnormal laboratory tests resolve more quickly using this method than when antibiotic-impregnated PMMA beads are used. Neither of our patients with infected prostheses have shown recurrence in the four years following treatment.

We are encouraged by the absence of any recurrence in the eighteen patients followed for a minimum of 24 months and we recommend the use of this approach in the treatment of all forms of chronic osteomyelitis.

Acknowledgements. The authors thank Professor Sydney Nade, Westmead Hospital, New South Wales, Australia for valuable comments and suggestions. – No benefits in any form have been received or will be received from any commercial partly related directly or indirectly to the subject of this article.

References

1. Ascheril R, Stember A, Lechner F (1986) Behandlung der chronischen Osteomyelitis mit einem Kollagen-Antibiotika-Verbund. Vorläufige Mitteilung. Unfallchirurgie 12:125–127
2. Bayston R, Milner RD (1982) The sustained release of antimicrobial drugs from bone cement. J Bone Joint Surg [Br] 64:460–464
3. Boda R (1982) Septopal-chain exchange operation for the treatment of osteomyelitic cavity. Preliminary report on 10 cases. Arch Orthop Trauma Surg 101:39–45
4. Buchholz HW, Elson RA, Heinert K (1984) Antibiotic-loaded acrylic cement: current concepts. Clin Orthop 190: 96–108
5. Compere EL (1962) Treatment of osteomyelitis and infected wounds by closed irrigation with detergent antibiotic solution. Acta Orthop Scand 32:324–333
6. Dahners LE, Funderburk GH (1987) Gentamicin-loaded plaster of paris as a treatment of experimental osteomyelitis in rabbits. Clin Orthop 219:278–282
7. Finsterbush A, Weinberg H (1972) Venous perfusion of the limb with antibiotics for osteomyelitis and other chronic infections. J Bone Joint Surg [Am] 54:1227–1234
8. Hanamura T (1984) Experimental study of acrylic resin coated gentamicin tables for local antibiotic therapy. J Jpn Orthop Assoc 58:555–565
9. Korukusuz F, Uchida A, Inoue I, Shinto Y, Araki N, Ono K (1993) Experimental implant-related osteomyelitis treated by antibiotic calcium hydroxyapatite ceramic composites. J Bone Joint Surg [Br] 75:111–114
10. Norden CW, Gillespie WJ, Nade S (1994) In: Infection in bones and joints. Blackwell, Boston, pp 3–418
11. Organ CHJ (1971) The utilization of massive doses of antimicrobial agents with isolation perfusion in the treatment of chronic osteomyelitis. Intermediate term results. Clin Orthop 76:185–193
12. Perry CR, Person RL (1991) Local antibiotic delivery in the treatment of bone and joint infection. Clin Orthop 263:215–226
13. Salvati EA, Callaghan JJ, Brause BD, Klein RF, Small RD (1986) Reimplantation in infection: elution of gentamicin from cement and beads. Clin Orthop 207:83–93
14. Shinto Y, Uchida A, Korukusuz F, Araki N, Ono K (1992) Calcium hydroxyapatite ceramic used as a delivery system for antibiotics. J Bone Joint Surg [Br] 74:600–604
15. Uchida A, Araki N, Shinto Y, Yoshikawa H, Ono K, Kurisaki E (1990) The use of calcium hydroxyapatite ceramic in bone tumour surgery. J Bone Joint Surg [Br] 72: 298–302
16. Zilch H, Lambiris E (1986) The sustained release of ofloxacin from a fibrin-cefotaxim compound in treatment of osteitis. Arch Orthop Trauma Surg 106:36–41