

ORIGINAL PAPER

D. Weber · D.L. Pomeroy · R. Brown · L.A. Schaper
W.E. Badenhause, Jr. · M.W. Smith · J.I. Curry
K.E. Suthers

Proximally porous coated femoral stem in total hip replacement – 5- to 13-year follow-up report

Accepted: 2 February 2000

Abstract A series of total hip replacements was performed using a proximally porous coated, tapered femoral stem system. At a mean follow-up of 8.1 (5–13) years, 80 out of 107 hips were available for clinical and radiological examination. The mean age at the index procedure was 58.6 years. The mean Harris Hip Score at final follow-up was 91.7. Radiological ingrowth was observed in 77 femoral stems, 2 stems were fibrous stable and 1 stem was loose.

Résumé Nous avons réalisé une étude rétrospective comprenant 80/107 prothèses totale de la hanche en utilisant une tige fémorale avec fixation proximale non-cimentée. L'âge moyen des patients lors de l'intervention était de 58.6 ans. La durée moyenne d'observation post-opératoire était de 8.1 ans. Le score de Harris lors du dernier examen clinique était de 91.7. Une incorporation radiologique idéale était observée dans 77 tiges, 2 tiges étaient stables et 1 tige était descellée.

Introduction

With the increasing number of total joint replacement procedures and cost reduction programs, clinical follow-up studies revealing longevity of implants are not only important for the quality of life of the patients but may become more and more valuable for effective cost control [11,24]. The results of such studies should have direct practical application and implants with successful survival rates should be favored before new designs are chosen or developed.

D. Weber (✉)
Clinic of Orthopaedic Surgery and Traumatology,
University Hospital, Rue Micheli-du-Crest 24, 1211 Geneva,
Switzerland
e-mail: danielweber61@hotmail.com
Tel.: +41-22-372-3311, Fax: +41-22-372-7799

D.L. Pomeroy · R. Brown · L.A. Schaper · W.E. Badenhause, Jr.
M.W. Smith · J.I. Curry · K.E. Suthers
The Louisville Institute for Joint Replacement
and The Arthroplasty Foundation,
234 East Gray Street, Suite 332, Louisville 40202, Kentucky, USA

With growing interest in cementless implant fixation in the last decade, especially for younger patients, mid- to long-term follow-up data are now becoming available. Mechanical loosening rates of non-cemented femoral stems have been reported in several studies and fall between 0 and 48% for various follow-up periods ranging from 3.5 to 7 years [1,2,4,6,8,12,14–17,21,26].

The purpose of this study is to report our mid-term results of a series of total hip replacements with a cementless, proximally porous coated, tapered stem design.

Materials and methods

Between July 1987 and November 1994, 94 patients underwent 107 non-consecutive primary cementless total hip replacements (THA) with the Opti-Fix femoral stem (Smith and Nephew Richards Orthopedics, Memphis, TN, USA) (Figs. 1, 2) at the Louisville Institute for Joint Replacement and The Arthroplasty Foundation. All procedures were performed by the three senior authors (D.L.P., L.A.S., W.E.B.Jr.).

Eight patients (8 hips) died and 15 patients (19 hips) failed to be evaluated within the past 2 years and could not be contacted. These patients were considered lost to follow up and not included in the study. At the time of review, 80 hips (71 patients) had complete follow-up data with a mean follow-up of 97 (60–132) months. They were evaluated clinically using Harris Hip Score (HHS) and radiographically according to the criteria developed by Engh [7]. The mean age at the time of surgery was 58.6 (29–75) years. The preoperative diagnoses were: osteoarthritis in 52 hips, avascular necrosis in 13 hips, hip fractures in 7 hips, developmental dysplasia of the hip in 3 hips, rheumatoid arthritis in 3 hips, and post-traumatic arthritis in 2 hips. The mean weight was 79 (43–117) kg.

Patient satisfaction forms (1) have been distributed and recorded annually since 1994 along with a functional assessment form (2) that mimics the interview questions asked at each clinical visit. These results have been matched with the most recent clinical results [18,19].

1. SF36 Health Survey developed by Medical Outcomes Trust 1992 measures eight domains: physical function, role limitations due to physical health problems, bodily pain, general health, vitality (energy/fatigue), social functioning, role limitations due to emotional problems, mental health (psychological distress and psychological well-being). It also includes a self-report of change in health during the past year.

2. Functional Assessment Questionnaire developed in-house, measures walking distance, walking aids, pain (localization and

intensity), problems in daily life (stair climbing, putting on socks, sitting), contentment with surgery, medications related to the index surgery.

The Opti-Fix femoral stem is a tapered stem made of a Titanium 6 Aluminum 4 Vanadium-Alloy with a proximal coating of Titanium beads (Fig. 1). In addition to the Optifix femoral stem, 69 of the procedures incorporated an Opti-Fix porous coated acetabular cup, ten received a Dual Geometry-cup (Osteonics) and one incorporated a Reflection-cup (Richards). Two head sizes were used 28 mm (19 hips) and 32 mm (61 hips). There were 36 ceramic and 44 metallic heads. Stem diameters were determined using preoper-



Fig. 1 Opti-Fix femoral component; tapered design with proximal porous coating

Fig. 2 Seven years postoperative radiograph of a femur implanted with an Opti-Fix stem in a 59-year-old asymptomatic female patient. Spot welds in zones 1 and 7, reactive lines in zones 2, 3, 4 and 5 and reactive, decreased bone density in the calcar show stable fixation

ative templating and an intra-operative radiograph was obtained with the broach in place to achieve optimal fit and filling of the femoral canal (Fig. 2). The average stem diameter was 12.9 mm (9.9–17.8 mm).

Radiographic evaluation was performed using antero-posterior and lateral roentgenograms. The films were taken immediately post-operative, at 3 and 6 months and annually thereafter. The roentgenograms were evaluated in a serial fashion, comparing each view to the previous year's as well as the immediate postoperative. The femoral zones as described by Gruen [10] were evaluated and also assessed for subsidence or toggling and grouped into one of three fixation categories (bone ingrown, stable fibrous, and loose) as described by Engh [7]. Major signs indicating the presence of osseous integration, were the absence of reactive lines adjacent to the porous coating and presence of endosteal new bone formation in contact with the porous coating. Stems that demonstrated migration (<2 mm was considered within the limits of error), toggling, or progressively divergent reactive lines were categorized as loose. Stems that demonstrated nominal subsidence during the first 6–12 months and then remained fixed after the first year as well as those with parallel reactive lines around less than half of the porous coating that did not widen with time were listed as stable. Cumulative survivorship according to Dobbs [5] using mechanical failure as end-point was calculated.

Results

Preoperatively, the mean HHS score for all 80 hips was 44.3 (range 7–71). At the most recent follow up evaluation the mean HHS reported was 91.7 (range 64–100). The scores of 6 cases with well-fixed stems (mean HHS 49.3, range 38–76) were eliminated due to debilitating factors other than the joint. No postoperative infections, deep vein thromboses or peri-prosthetic fractures were observed. When comparing clinical scores, no significant differences were found with respect to age, gender, or disease process.

All patients completed patient satisfaction and functional assessment forms within the last one and a half years. This information was coupled with their clinical evaluation. The results indicate 96% of the patients were well satisfied with their results (mean HHS 90.8); 4% were not satisfied (mean HHS 82.6) and would not be willing to go through the procedure again. Radiological examination revealed 77 (96.2%) of the femoral components to be considered optimally bone ingrown. Two stems (2.5%) were classified as stable fibrous and one as unstable.

Seventy-four of the hips displayed some reactive line formation between 1 and 3 years postoperatively

Table 1 Incidence of reactive lines

AP (%)	1A 49.4	1B 10.8	2 21.7	3 19.3	4 73.5	5 20.5	6 32.5	7A 7.2	7B 7.2
Lateral (%)	8A 22.8	8B 2.4	9 6.0	10 24.1	11 78.3	12 21.7	13 10.8	14A 9.6	14B 2.4

Table 2 Incidence of spot welds (osseointegration) within the first 36 months

AP (%)	1A 40.9	1B 6.0	2	3	4	5	6	7A 59.1	7B 73.5
Lateral (%)	8A 30.1	8B 33.7	9	10	11	12	13	14A 46.9	14B 28.9

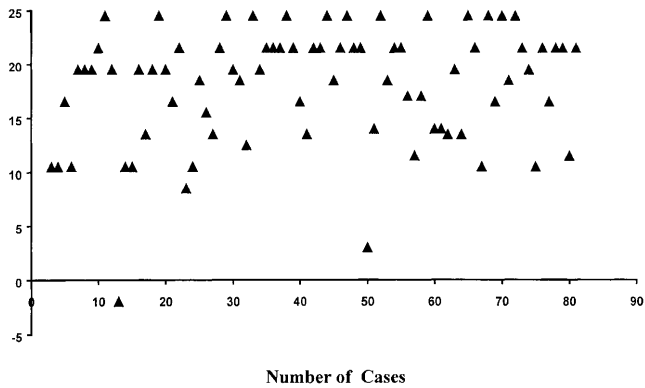


Fig. 3 Radiographic scores according to Engh et al.

(Table 1). Six hips had no reactive line formation before 3 years. Of the 77 hips classified as bone ingrown 73 demonstrated spot welds by the 36-month postoperative follow-up (Table 2). The Engh scores for all hips were calculated determining bone ingrowth (average 18.1; range $-2-24.5$) (Fig. 3).

Discussion

Non-cemented THA has been introduced with the hope of reducing the aseptic loosening rates of first generation cemented implants. But, as stated by Mulroy et al. [20], cementless femoral components must match the results of improved cementing techniques. Several studies reported excellent long-term results regarding stem fixation in total hip replacement with the use of so-called second generation cementing techniques. Loosening rates of 1–1.5% at 10–14 years follow-up were cited [20,27].

Clinical follow-up studies of non-cemented implants failed to prove superiority over cement-fixation until the late-nineties. The reported mechanical loosening-rates (revised and non-revised) for short- and mid-term follow-up are between 6 and 52% for the majority of studies [1,3,6,7,14–17,21,25,26]. Successful short-term results have been reported for a few stem designs, i.e. Zweymuller (AlloPro) [4], CLS (Sulzer) [21], Mallory Head (Biomet) [2] with a mean follow-up of 6–6.5 years. Only a few recent studies report long-term (11 years and longer) results. Kim et al. [13] reported an 11% revision rate and 59% osteolysis in the femur with the PCA stem.

Concurrently, Engh et al. [9] report favorable results with the use of the porous-coated AML stem with 5 mechanical failures in 223 THA (follow-up 12 years). Engh stresses that all mechanical unstable stems were undersized with size and fit of the stem being of crucial importance for the mechanical stability of the implant and long-term survival. Equally good results have more recently been reported by Rothman et al. [23] in their series of 121 THR utilizing a tapered, plasma sprayed femoral design (Taperloc, Biomet) with a mean follow-up of 11 years.

We present a series of 80 THR using the Opti-Fix proximally porous-coated femoral stem with an excellent intermediate result at mean follow-up of 8.1 years. The Harris Hip-Score correlated with patient satisfaction forms and functional assessment questionnaires. Radiological result show 2 fibrous stable and 77 ingrown stems; one stem was mechanically unstable but for medical reasons not revised. The unstable stem was diagnosed loose between the second and third postoperative year. After the third postoperative year, no changes in osseointegration have been observed. The characteristic of a high 2-year score correlating with durable implant stability through 5 years has been described by Engh et al. [7] and is confirmed by our radiological examinations. We consider therefore our results as promising for long-term outcomes.

Undoubtedly improving the quality of the patients life is the goal of any joint replacement. But there is also increasing pressure from cost reducing programs. The joint replacement surgeons therefore must be able to rely on the well-documented success of implants to justify their choice of prosthesis [11]. The current literature reports promising results with low revision rates for several non-cemented femoral stem designs. We can expect more crucial information concerning long-term stability and revision rates of different designs as well as studies comparing cemented with cementless THR [22] in clinical trials in the next decade.

Acknowledgements This work was supported by a grant from the Swiss Society of Orthopaedic Surgery.

References

1. Barrack RL, Folgueras A, Munn B, Tvetden D (1997) Pelvic lysis and polyethylene wear at 5–8 years in an uncemented total hip. *Clin Orthop* 335:211–217
2. Bourne RB, Rorabeck CH (1998) A critical look at cementless stems. Taper designs and when to use alternatives. *Clin Orthop* 355:212–223
3. Capello WN, Sallay PI, Feinberg JR (1994) Omniflex modular femoral component. Two to five year results. *Clin Orthop* 298:54–59
4. Delaunay CP, Kapandji AI (1996) Primary total hip arthroplasty with the Karl Zweymuller first-generation cementless prosthesis. A 5 to 9 year retrospective study. *J Arthroplasty* 11: 643–652
5. Dobbs HS (1980) Survivorship of total hip replacements. *J Bone Joint Surg [Br]* 62:169–173
6. Dorr LD, Lewonowski K, Lucero M, Harris M, Wan Y (1997) Failure mechanisms of anatomic porous replacement I cementless total hip replacement. *Clin Orthop* 334:157–167
7. Engh CA, Massin P, Suthers KE (1990) Roentgenographic assessment of the biologic fixation of porous surfaced femoral components. *Clin Orthop* 257:107–128
8. Engh CA, Hooten JP, Jr, Zettl, Schaffer KF, Ghaffarpour M, McGovern TF, Macalino GE, Zicat BA (1994) Porous-coated total hip replacement. *Clin Orthop* 298:89–96
9. Engh CA, Jr, Culpepper, II, WJ, Engh CA (1997) Long-term results of use of the anatomic medullary locking prosthesis in total hip arthroplasty. *J Bone Joint Surg [Am]* 79:177–184
10. Gruen TA, McNeice GM, Amstutz HC (1979) “Modes of Failure” of cemented stem-type femoral components. A radiographic analysis of loosening *Clin Orthop* 141:17–27

11. Herberts P, Malchau H (1997) How outcome studies have changed total hip arthroplasty practices in Sweden. *Clin Orthop* 344:44–60
12. Huo MH, Fye MA, Martin RP, Zatorski LE, Keggi KJ (1997) Unsatisfactory results of a first-generation modular femoral stem implanted without cement. *J Arthroplasty* 12:490–496
13. Kim YH, Kim J-S, Cho S-H (1999) Primary total hip arthroplasty with a cementless porous-coated anatomic total hip prosthesis. 10- to 12-year results of prospective and consecutive series. *J Arthroplasty* 14:538–548
14. Lautiainen IA, Joukainen J, Makela EA (1994) Clinical and roentgenographic results of cementless total hip arthroplasty. *J Arthroplasty* 9:653–660
15. Malchau H, Wang YX, Karrholm J, Herberts P (1997) Scandinavian multicenter porous coated anatomic total hip arthroplasty study. Clinical and radiographic results with 7- to 10-year follow-up evaluation. *J Arthroplasty* 12:133–148
16. Mallory TH, Head WC, Lombardi AV, Jr, Emerson RH, Eberle RW, Mitchell MB (1996) Clinical and radiographic outcome of a cementless, titanium, plasma spray-coated total hip arthroplasty femoral component. Justification for continuance of use. *J Arthroplasty* 11:653–660
17. Maloney WJ, Woolson ST (1996) Increasing incidence of femoral osteolysis in association with uncemented Harris-Galante total hip arthroplasty. A follow-up report. *J Arthroplasty* 11:130–134
18. McGrory BJ, Morrey BF, Rand JA, Ilstrup DM (1996) Correlation of patient questionnaire responses and physician history in grading clinical outcome following hip and knee arthroplasty. A prospective study of 201 joint arthroplasties. *J Arthroplasty* 11:47–57
19. McGuigan FX, Hozack WJ, Moriarty L, Eng K, Rothman RH (1995) Predicting quality-of-life outcomes following total joint arthroplasty. Limitations of the SF-36 health status questionnaire. *J Arthroplasty* 10:742–747
20. Mulroy, Jr, RD, Harris WH (1990) The effect of improved cementing techniques on component loosening in total hip replacement. An 11-year radiographic review. *J Bone Joint Surg [Br]* 72:757–760
21. Robinson RP, Deysine GR, Green TM (1996) Uncemented total hip arthroplasty using the CLS-stem: a titanium alloy implant with a corundum blast finish. Results at a mean 6 years in a prospective study. *J Arthroplasty* 11:286–292
22. Rorabeck CH, Bourne RB, Laupacis A, Feeny D, Wong C, Tugwell P, Leslie K, Bullas R (1993) A double-blind study of 250 cases comparing cemented with cementless total hip arthroplasty. *Clin Orthop* 298:156–164
23. Rothman RH, Hozack WJ, Sharkey PF, Orozco F (1999) Ten year minimum follow-up with a tapered titanium cementless femoral component in primary hip arthroplasty. Ninth Annual Meeting of the AAHKS, November 12–14, 1999, Dallas, Texas, USA
24. Saleh KJ, Gafni A, Saleh L, Gross AE, Schatzker J, Tile M (1999) Economic evaluations in the hip arthroplasty literature. Lessons to be learned. *J Arthroplasty* 14:527–532
25. Savilahti S, Myllyneva I, Lindholm TS, Pajamaki KJ, Nevalainen J, Laippala P (1995) Clinical outcome and survival of Link RS total hip prosthesis. *J Bone Joint Surg [Br]* 77:369–373
26. Smith E, Harris WH (1995) Increasing prevalence of femoral lysis in cementless total hip arthroplasty. *J Arthroplasty* 10:407–412
27. Wroblewski BM, Siney PD (1993) Charnley low-friction arthroplasty of the hip. Long-term results. *Clin Orthop* 292:191–201