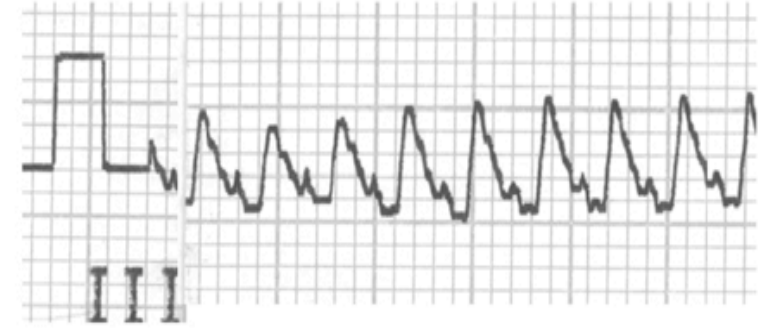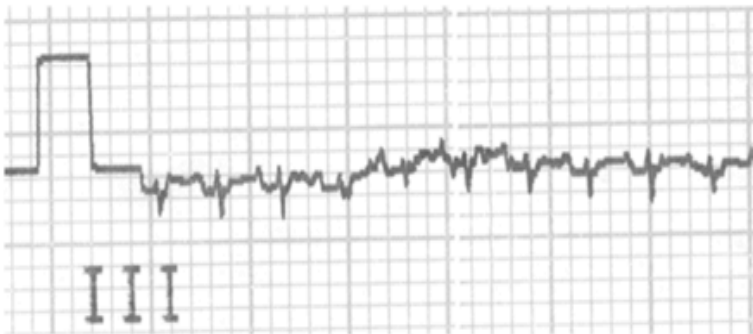
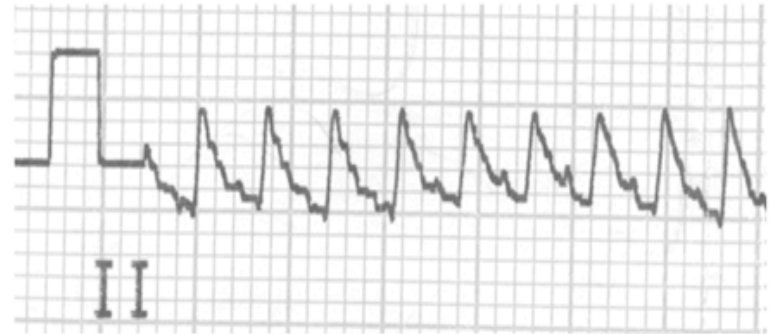
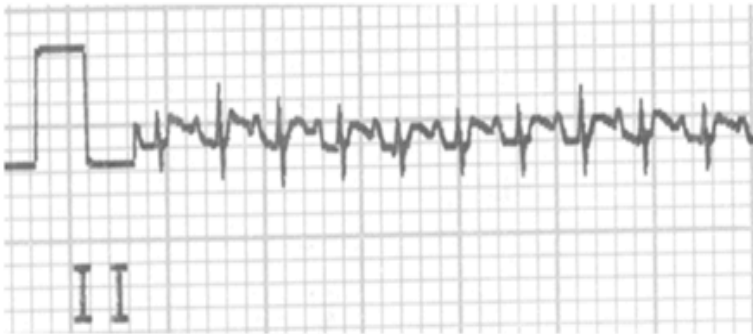
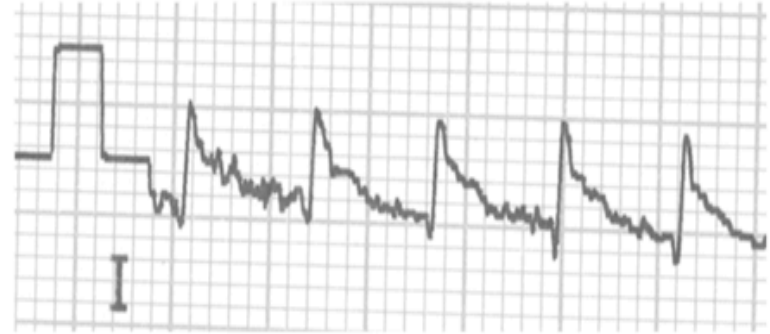
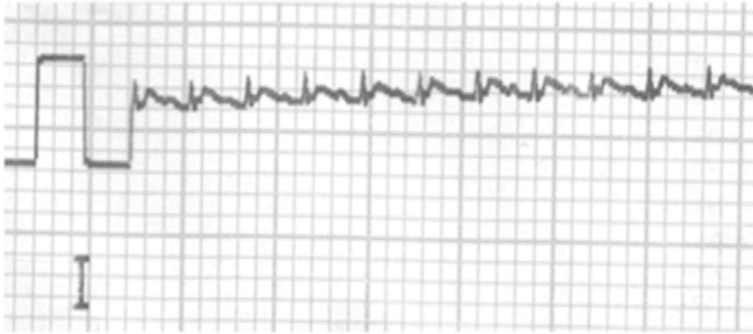


ECG of pre-operation

ECG of post-operation



Online Figure 1. ECG prior to and after ligation of the left anterior descending coronary artery, the latter showing ST elevation as evidence of myocardial injury