

Peritoneal Tuberculosis in a Pregnant Woman from Haiti, United States

Technical Appendix

Technical Appendix Table. Cases of peritoneal tuberculosis in pregnancy from published reports and the authors' clinical experience*

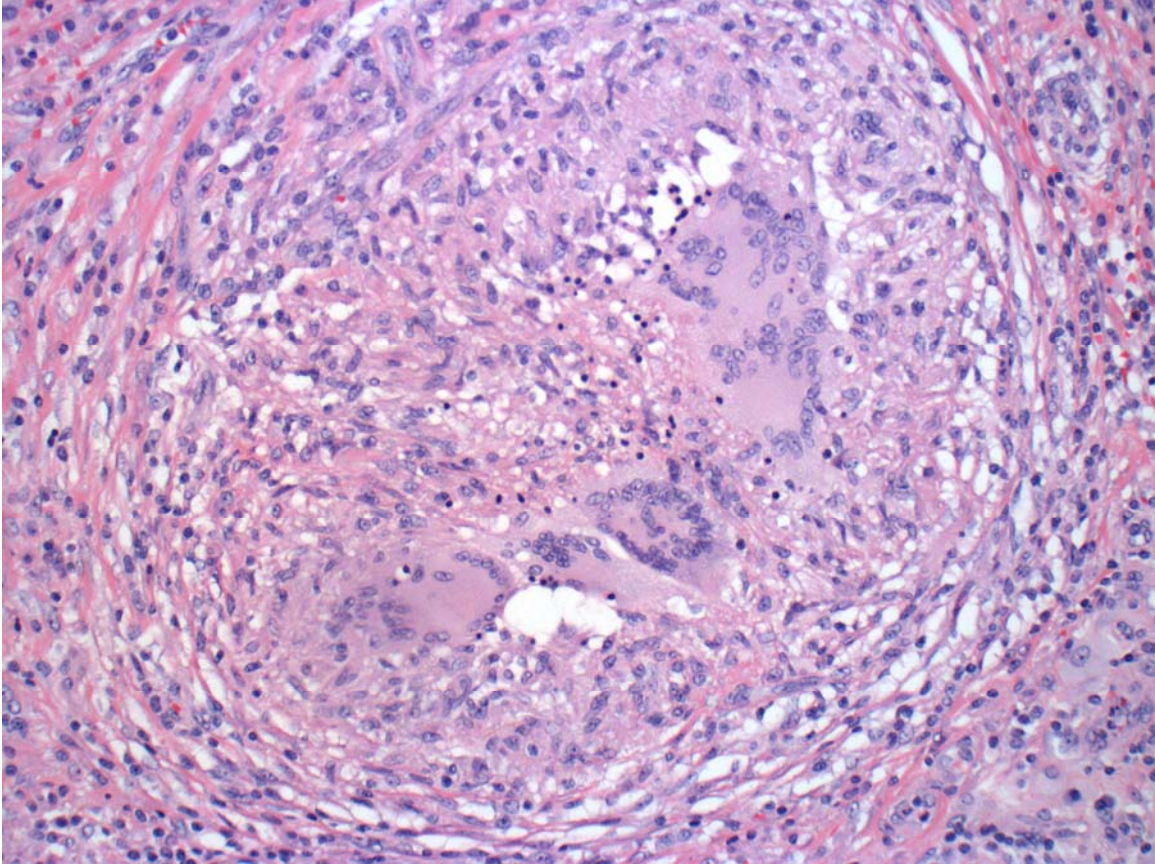
Reference or source	Patient age at presentation, y	Country or region of origin	Symptoms	Duration of illness prior to diagnosis	Diagnostic tests and findings	Pregnancy outcome
Present case	29	Haiti	Vaginal bleeding, abdominal pain, fever	3 wk	MRI of omental mass, granulomata and AFB on omental pathology, positive nucleic acid amplification and omental cultures	Birth at 26 weeks gestation; male infant survived
Case-patient from Haiti #1	20	Haiti	Foul vaginal discharge, abdominal pain, fever	Unknown	Granulomata on placental, uterine, and omental pathology; negative tissue AFB stain	Stillborn child; gestational age unknown; patient had hysterectomy
Case-patient from Haiti #2	26	Haiti	Cough, weight loss, abdominal swelling, fever	Unknown	Clinical diagnosis after response to a therapeutic trial of antitubercular drugs	Birth at 29 weeks gestation; male infant survived
Case-patient from Haiti #3	28	Haiti	Vaginal discharge, abdominal pain, fever	Unknown	Granulomata on placental, uterine, and omental pathology; negative tissue AFB stain	Birth at 28 weeks gestation; female infant died
Coden, 1972 (1)	26	Unknown	Abdominal pain, vomiting, anorexia, fever	6 mo	Positive ascites fluid culture for <i>M. tuberculosis</i> ; therapeutic trial of antitubercular drugs	Term birth; male infant survived
Brooks and Stirrat, 1986 (2)	25	Caribbean	Weight loss, nausea, vomiting, fever	Wk, unknown, <1 mo	Ascites fluid AFB stain and culture negative, omental pathology with AFB	Birth at 33 weeks gestation; male infant survived
Lee, 2005 (3)	23	South Korea	Ascites, fever	Unknown	Ascites fluid adenosine deaminase 70 U/L, serum CA-125 372 IU/mL, negative ascites fluid AFB stain and culture, MRI with omental cake, granulomata and AFB on omental pathology	Birth at 37 weeks gestation; male infant survived

Reference or source	Patient age at presentation, y	Country or region of origin	Symptoms	Duration of illness prior to diagnosis	Diagnostic tests and findings	Pregnancy outcome
Sakorafas, 2009 (4)	28	Ethiopia	Abdominal pain, nausea, vomiting, fever	Mo, unknown	Serum CA-125 163 IU/mL, ascites fluid AFB stain and culture negative, granulomata on peritoneal pathology, peritoneal biopsy cultures positive for <i>M. tuberculosis</i>	Pregnancy without other complications; otherwise, details unknown

* Published reports are limited to those in English. MRI, magnetic resonance imaging; AFB, acid-fast bacilli.

References

1. Coden J. Tuberculous peritonitis in pregnancy. *BMJ*. 1972;3:153. [PubMed](https://pubmed.ncbi.nlm.nih.gov/12345678/)
<http://dx.doi.org/10.1136/bmj.3.5819.153>
2. Brooks JH, Stirrat GM. Tuberculous peritonitis in pregnancy. Case report. *Br J Obstet Gynaecol*. 1986;93:1009–10. [PubMed](https://pubmed.ncbi.nlm.nih.gov/12345678/) <http://dx.doi.org/10.1111/j.1471-0528.1986.tb08027.x>
3. Lee GS, Kim SJ, Park IY, Shin JC, Kim SP. Tuberculous peritonitis in pregnancy. *J Obstet Gynaecol Res*. 2005;31:436–8. [PubMed](https://pubmed.ncbi.nlm.nih.gov/12345678/) <http://dx.doi.org/10.1111/j.1447-0756.2005.00316.x>
4. Sakorafas GH, Ntavatzikos A, Konstantiadou I, Karamitopoulou E, Kavatha D, Peros G. Peritoneal tuberculosis in pregnancy mimicking advanced ovarian cancer: a plea to avoid hasty, radical and irreversible surgical decisions. *Int J Infect Dis*. 2009;13:e270–2. [PubMed](https://pubmed.ncbi.nlm.nih.gov/12345678/) <http://dx.doi.org/10.1016/j.ijid.2008.11.003>



Technical Appendix Figure. Hematoxylin and eosin–stained tissue from the patient’s omental biopsy, demonstrating necrotizing granulomata. Acid-fast stains of the specimen showed rare acid-fast bacilli. Original magnification $\times 400$.