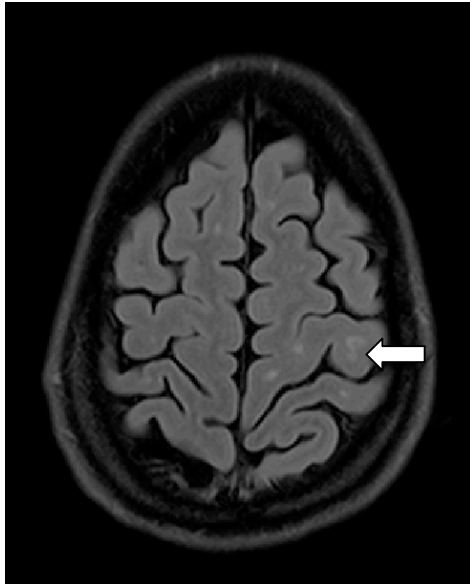


**Figure e-2:**

A. Axial T2 FLAIR U-fibre hyperintensity in RRMS patient



B. Sagittal T2 FLAIR showing ovoid lesions perpendicular to lateral ventricle (Dawson's Fingers) in a RRMS patient

