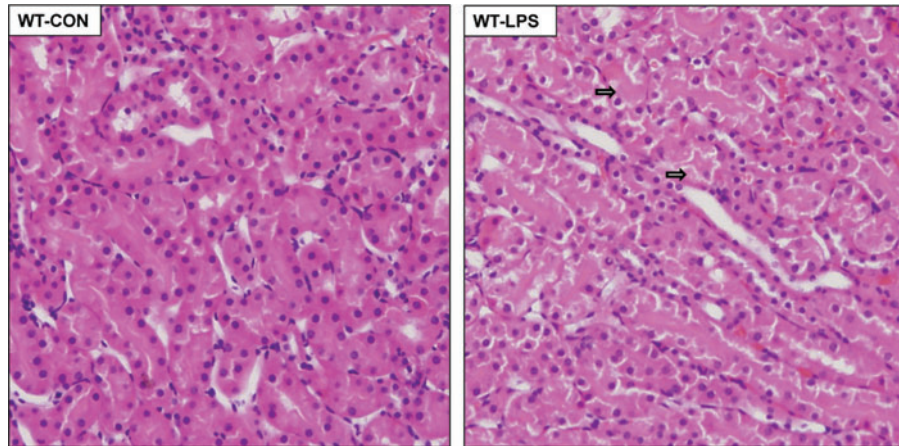


Supplementary Data



SUPPLEMENTARY FIG. S1. Representative hematoxylin and eosin–stained kidney sections demonstrating damage in corticomedullary areas of the LPS-treated wild-type mice (WT-LPS), showing swelling (arrows) of epithelial cells with focal desquamation of the brush borders.