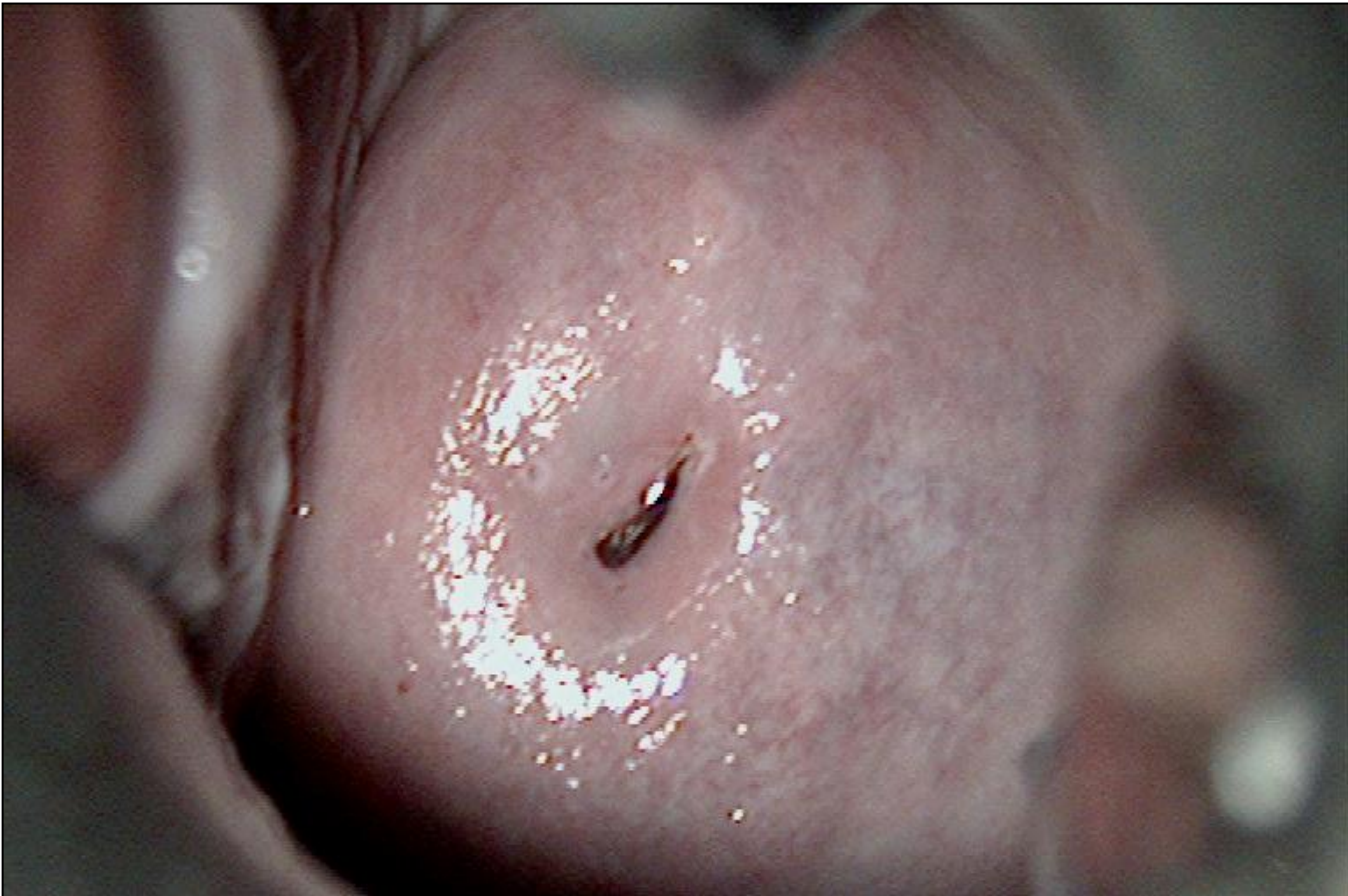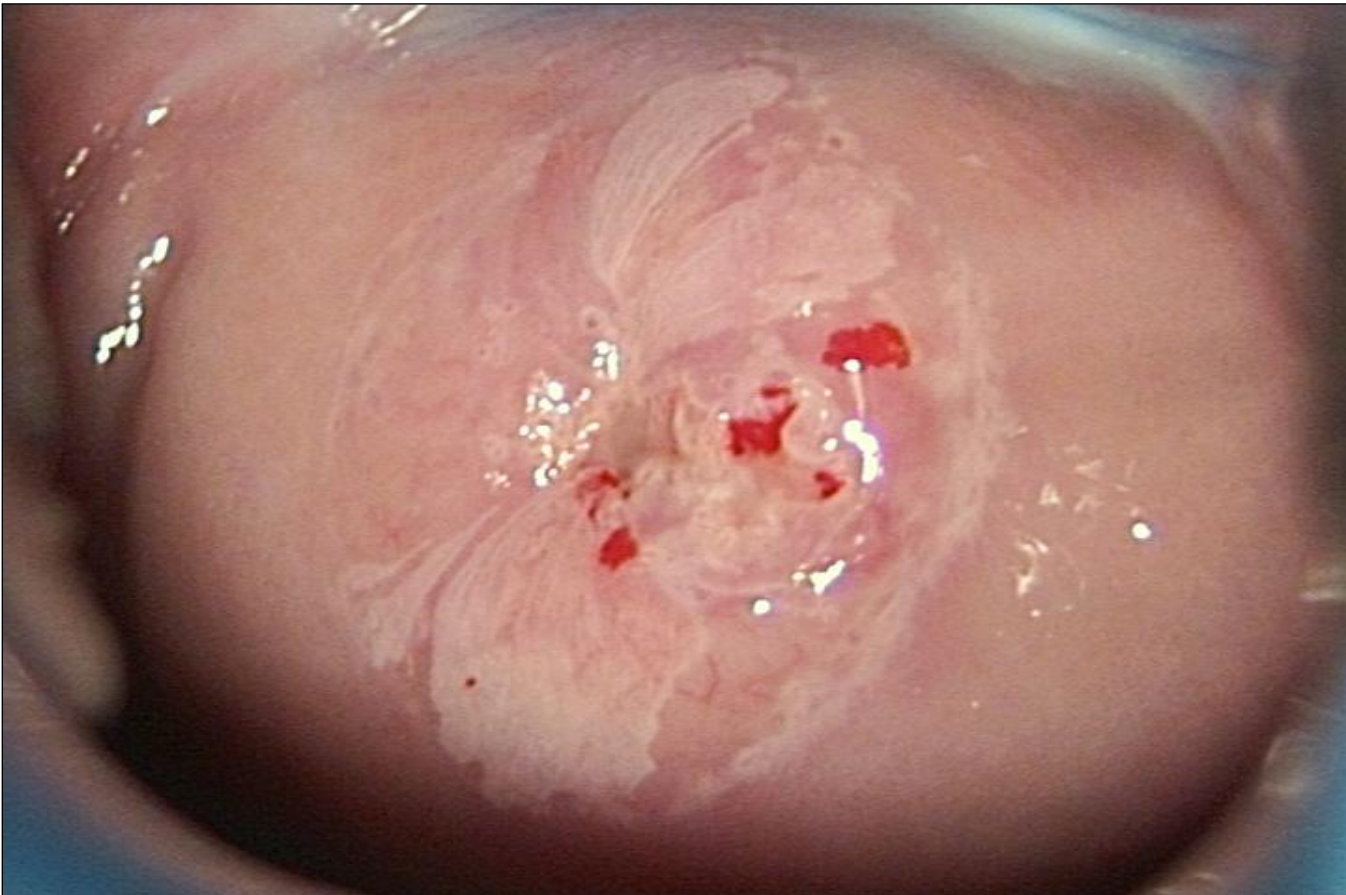




Digital colposcopic photographs representing the four categories of the International Federation for Cervical Pathology and Colposcopy classification of 2002

Figure 1.

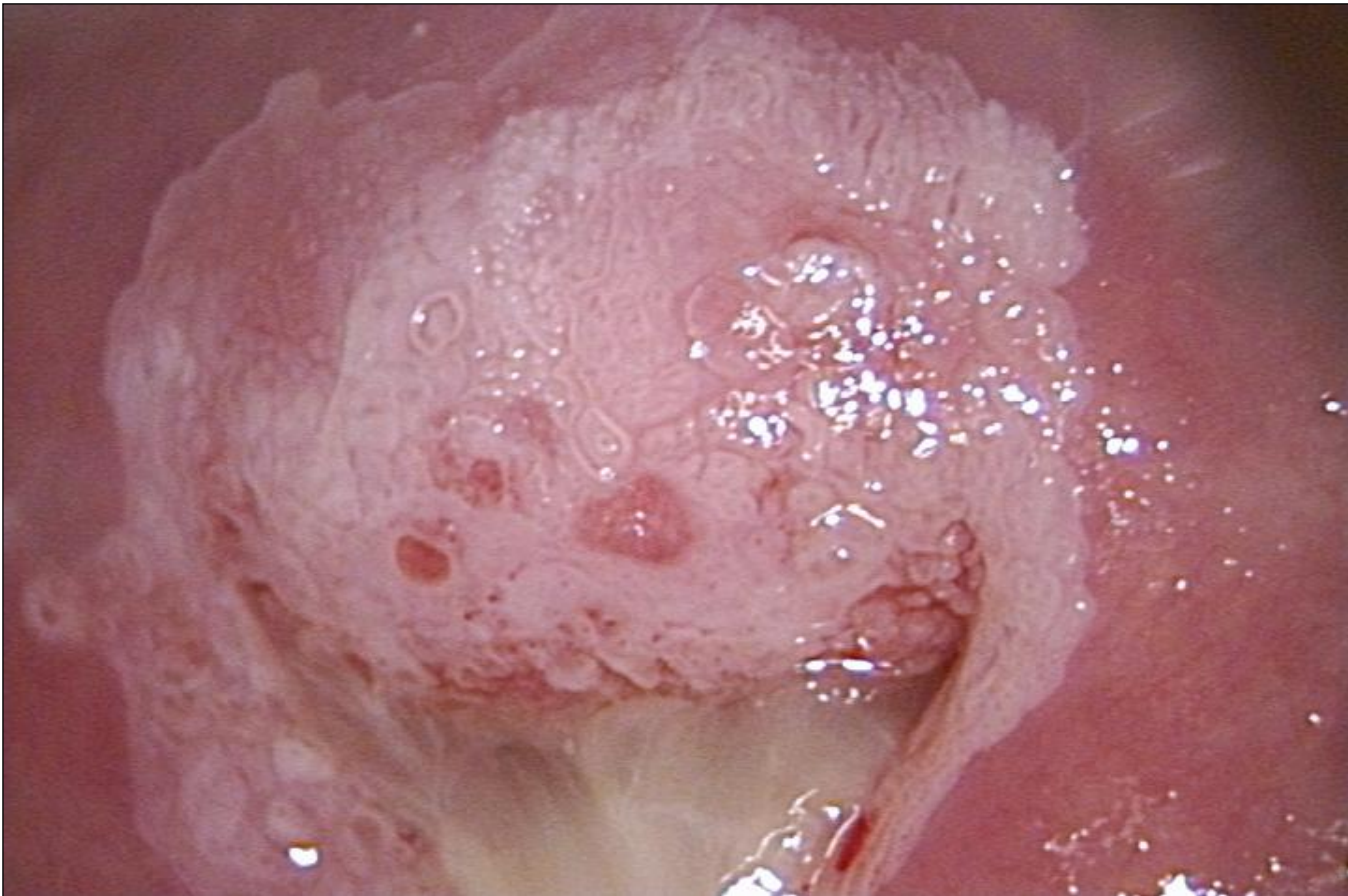
Normal colposcopic findings (Negative)



Digital colpophotographs representing the four categories of the International Federation for Cervical Pathology and Colposcopy classification of 2002

Figure 2.

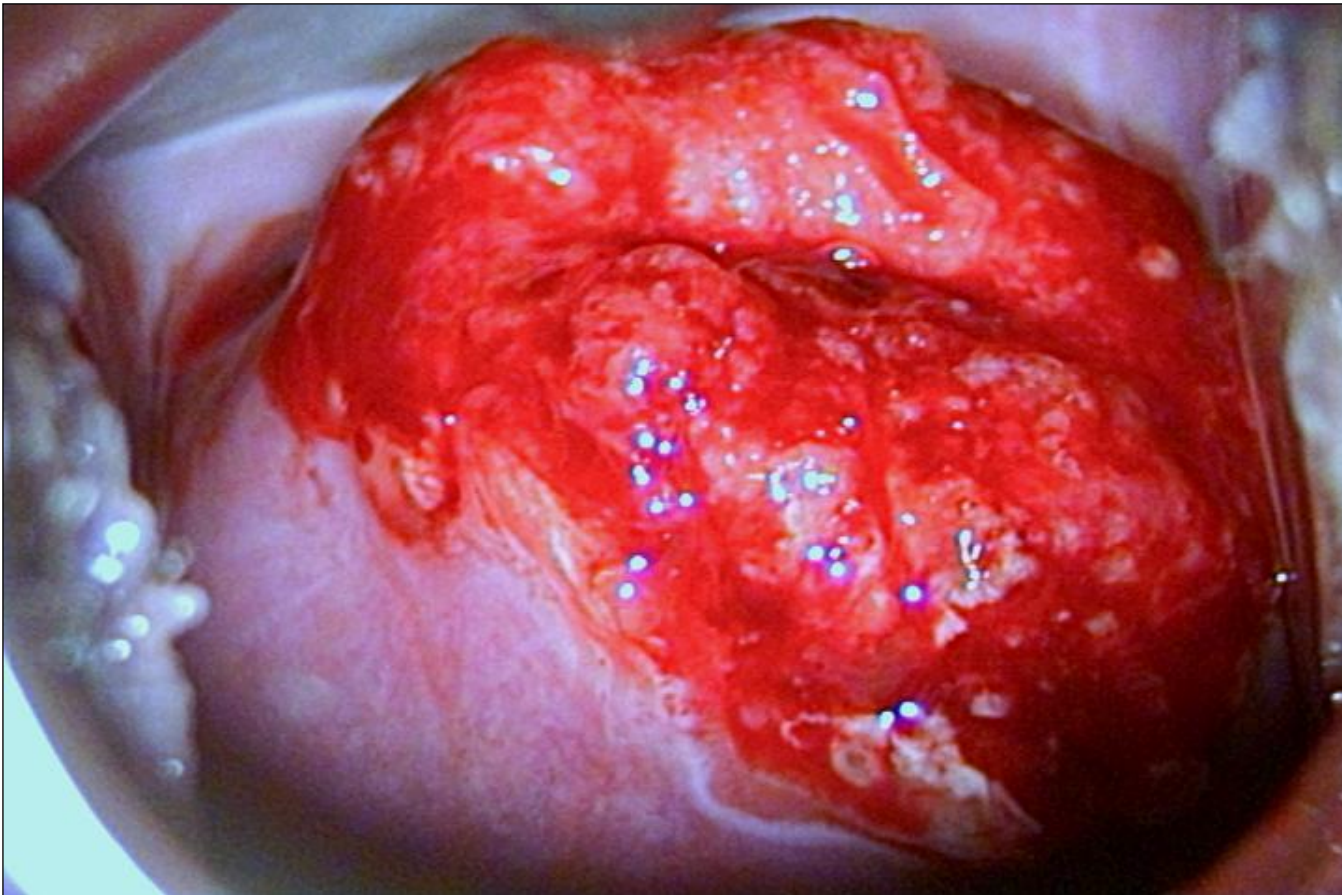
Abnormal colposcopic findings-minor changes (Abnormal, grade 1)



Digital colposcopic photographs representing the four categories of the International Federation for Cervical Pathology and Colposcopy classification of 2002

Figure 3.

Abnormal colposcopic findings-major changes (Abnormal, grade 2)



Digital colpophotographs representing the four categories of the International Federation for Cervical Pathology and Colposcopy classification of 2002

Figure 4.

Colposcopic features suggestive of invasive cancer (Suspected invasive cancer)