

Healing of Rickets with Phosphate Supplementation in the Hypophosphatemic Male Mouse

PIERRE J. MARIE, ROSE TRAVERS, and FRANCIS H. GLORIEUX, *Genetics Unit, Montreal Shriners Hospital; Departments of Surgery and Pediatrics, McGill University, Montréal, Québec, Canada H3G 1A6*

ABSTRACT The hypophosphatemic male mouse, an animal model for human vitamin D-resistant rickets, is characterized by low serum phosphorus concentration due to increased urinary phosphate excretion, rickets, osteomalacia, and dwarfism. Because phosphate administration can heal rickets but not osteomalacia in the human disease, we have compared the effect of phosphate supplementation on the epiphyseal and endosteal bone mineralization in the mutant animal. Phosphate was given in drinking water for 137 d and the biochemical and bone responses were assessed by analytical and histomorphometric methods. Treatment with phosphate normalized the endochondral calcification (vertebral growthplate thickness: 83 ± 5 SD vs. controls $[+Y] 73 \pm 8 \mu\text{m}$, NS), but did not correct the endosteal bone mineralization (mineralization front: 13.6 ± 2.7 vs. $+Y 67.1 \pm 6.9\%$ osteoid surface, $P < 0.001$, endosteal mean osteoid seam thickness: 46.4 ± 6.1 vs. $+Y 3.3 \pm 0.3 \mu\text{m}$, $P < 0.001$). In addition, both osteoblastic and osteoclastic recruitment and activity were stimulated, as a result of a probable increase in parathyroid hormone secretion following the phosphate induced fall in serum calcium. Our results show that in the hypophosphatemic mouse, phosphate supplementation can heal the epiphyseal, but not the endosteal defective bone mineralization. Then, the biochemical and skeletal response to phosphate therapy appear to be similar to what we have observed in the human disease, further stressing the interest of the animal model.

INTRODUCTION

The hypophosphatemic (Hyp)¹ mouse has been proposed as a valuable animal model for human vitamin

D-resistant rickets (VDRR) (1). As in the human disease, the mutation is transmitted as an X-linked dominant trait and causes hypophosphatemia due to an intrinsic renal tubular reabsorption defect for phosphate (2). Moreover, the Hyp mouse has a mild hypocalcemia (1) and reduced bone magnesium (Mg) content (3). Besides these biochemical abnormalities, the mutant animal presents with growth retardation resulting from rickets (1) and skeletal deformities associated with histologic evidence of osteomalacia (3). In children with VDRR, the radiological appearance of rickets can be healed by adequate supplementation of phosphate (Pi) (4) whereas osteomalacia remains uncured (5, 6). The present study was designed to evaluate the effect of Pi on the epiphyseal and endosteal mineralization in the affected male mouse.

METHODS

Animals. At weaning, six normal male mice (+/Y) and seven hemizygous mutants (Hyp/Y) from the C57BL/6J strain were fed a mouse Purina chow containing 0.50% calcium and 0.74% phosphorus. Pi supplementation was given to the Hyp animals as Pi salts (1.93 g elemental phosphorus/liter) ad lib. in drinking water from weaning (21 d old) to death (149 d old). Daily water intake was about 4 ml/mouse.

Analytical procedures. 1 d before sacrifice, fasted mice were housed in metabolic cages where urine was collected for 16 h overnight. At death, blood was drawn by cardiac puncture and serum and urine prepared for biochemical determinations. Calcium, phosphorus, Mg, alkaline phosphatase and creatinine concentrations were determined using modified Auto Analyzer procedures (Technicon Instruments Corp., Tarrytown, N. Y.). The fractional excretion of phosphate was calculated by the equation: $(\text{urine Pi} \times \text{plasma creatinine}) \div (\text{plasma Pi} \times \text{urine creatinine})$ (7). Urinary cyclic (c)AMP was determined by a competitive binding assay (Amersham Searle Corp., Arlington Heights, Ill.).

Skeletal analysis. At sacrifice, tibias were freed of soft tissue and bone marrow, dried to constant weight at 100°C and ashed for 8 h at 600°C. Bone ashes were dissolved in concentrated hydrochloric acid. Calcium, phosphorus, and Mg concentrations were analysed by atomic absorption spectrophotometry. Caudal vertebrae were fixed in buffered formaldehyde (pH 7.1), embedded undecalcified in methylmethacrylate and sectioned on a microtome (Autocut, Jung Inc., Heidelberg, W. Germany). 5- μm thick transverse sections

This work was presented in part in June 1979 at the First Annual Scientific Meeting of the American Society for Bone and Mineral Research, Anaheim, Calif.

Address reprint requests to Dr. Marie.

Received for publication 10 November 1980 and in revised form 17 December 1980.

¹Abbreviations used in this paper: Hyp, hypophosphatemic; Pi, phosphate; VDRR, vitamin D-resistant rickets.

TABLE I
Effect of Phosphate Supplementation on Biochemical Parameters in the Hyp Mouse

Group (n)	Serum calcium	Serum phosphorus	Serum magnesium	Serum alkaline phosphatase	Urinary phosphorus (creatinine)	Fractional excretion of Pi	Urinary Mg (creatinine)	Urinary cAMP (creatinine)
	mg/dl	mg/dl	mg/dl	IU/liter	mg/mg	%	mg/mg	mM/mg
+Y (6)	9.1±0.2	7.5±0.6	3.0±0.1	56±5	4.4±0.8	17.2±3.6	0.73±0.08	58.6±7.8
Hyp/Y (7)	8.6±0.5*	5.2±0.7*	3.2±0.2*	227±31*	5.2±1.5	44.7±9.7*	1.28±0.24*	116.4±9.3*
Hyp/Y + Pi (6)	7.8±0.4‡	5.2±0.9	2.9±0.2‡	172±37‡	9.4±2.2‡	78.1±14.1‡	0.93±0.23‡	114.2±13.6

The results shown represent the mean±SD of all the values obtained from the indicated (n) number of animals.

* $P < 0.05$ or higher level of significance by t test as compared with +Y.

‡ $P < 0.05$ or higher level of significance by t test as compared with untreated Hyp/Y.

stained with the von Kossa method (8) or toluidine blue (9), were quantitatively analyzed using a semi-automatic image analyzer (MOP 3, Carl Zeiss Inc., Ober Kochen, Wuerntenberg, W. Germany). Bone growth and epiphyseal calcification were assessed by measuring, on histologic sections of the seventh caudal vertebra, the total length and the mean thickness, respectively, of the cartilaginous part of the growthplate. The following histologic parameters (9) were measured exclusively on the endosteal surface of the vertebral diaphysis: percentage of total surface covered by an osteoid seam (osteoid surface); percentage of osteoid surface showing a well defined metachromatic staining with toluidine blue at the calcified osteoid tissue interface (mineralization front); percentage of total surface lined with plump osteoblasts (osteoblastic surface); percentage of total surface showing resorption lacunae filled with osteoclasts (osteoclastic surface); number of osteoclasts per square millimeter of bone section. The mean endosteal and periosteal osteoid seam thickness were determined by measuring the average width of 30 or more intercepts along the bone surface. Results were expressed as mean±SD and statistic analysis was made using the Student's t test.

RESULTS

As shown in Table I, untreated Hyp/Y mice displayed a slight hypocalcemia and a striking hypophosphatemia associated with increased fractional excretion of Pi, elevated serum alkaline phosphatase, and urinary cAMP. A slight increase in serum Mg concentration was associated with a higher than normal urinary Mg excretion (Table

I) and a low Mg bone content ($0.55±0.05$ vs. +Y $0.67±0.01\%$ bone ash, $P < 0.001$). Calcium and phosphorus bone ash concentrations were normal. Pi supplementation induced a significant drop in serum calcium (Table I). Although the fasting serum phosphorus concentration was unchanged, both urinary Pi concentration and the fractional excretion of Pi rose markedly, reflecting the high Pi load brought up by treatment. Serum alkaline phosphatase was decreased but not normalized while urinary cAMP was unchanged. Although bone Mg content remained lower than normal ($0.53±0.01$ vs. +Y $0.67±0.01\%$, $P < 0.001$), serum and urinary Mg concentrations were normalized after Pi therapy (Table I).

Bone growth failure and defective epiphyseal calcification were demonstrated in untreated Hyp/Y mice by a shorter than normal vertebral length associated with a wide epiphyseal growthplate (Table II, Fig. 1A and B). Impaired endosteal bone mineralization was evidenced by excessive osteoid surface ($87.0±3.1$ vs. +Y $3.8±1.5\%$, $P < 0.001$) and thickness, and decreased extent of the mineralization front (Table II). After treatment with Pi, the vertebral length was increased but remained shorter than normal, while the growthplate thickness was reduced within the normal range and metaphyseal calcification of the primary spongiosa was induced (Table

TABLE II
Effect of Pi Supplementation on Bone Growth and Histomorphometric Bone Parameters in the Hyp Mouse

Group (n)	Vertebral length	Growthplate thickness	Mineralization front (osteoid surface)	Mean osteoid seam thickness		Osteoblastic surface	Osteoclastic surface	Number of osteoclasts
				periosteal	endosteal			
				mm	μm			
+Y (6)	3.83±0.01	73±8	67.1±6.9	4.6±0.8	3.3±0.3	1.9±0.4	0.6±0.2	0.21±0.07
Hyp/Y (7)	2.51±0.08*	135±12*	6.9±4.1*	67.7±3.4*	44.9±4.9*	1.5±0.8	0.6±0.1	0.20±0.08
Hyp/Y + Pi (6)	2.76±0.06‡	83±5‡	13.6±2.7‡	51.9±7.0‡	46.4±6.1	10.3±2.0‡	2.4±1.2‡	0.43±0.19‡

The results shown represent the mean±SD of all the values obtained from the indicated (n) number of animals.

* $P < 0.05$ or higher level of significance by t test as compared with +Y.

‡ $P < 0.05$ or higher level of significance by t test as compared with untreated Hyp/Y.

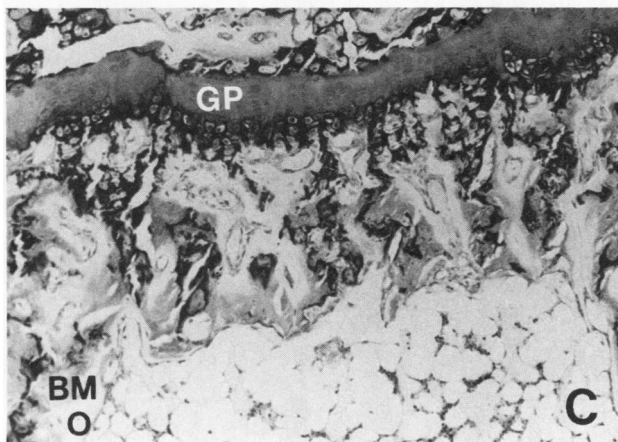
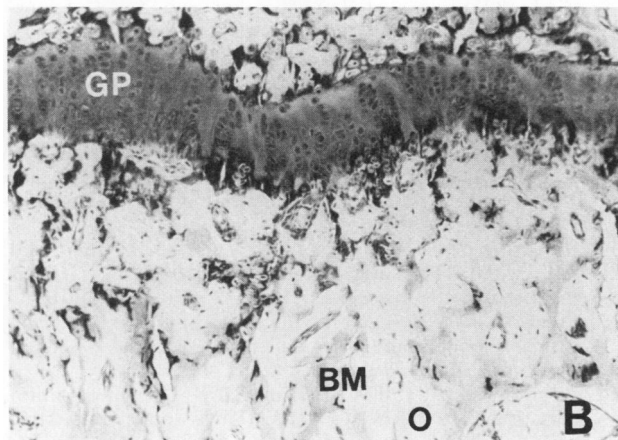
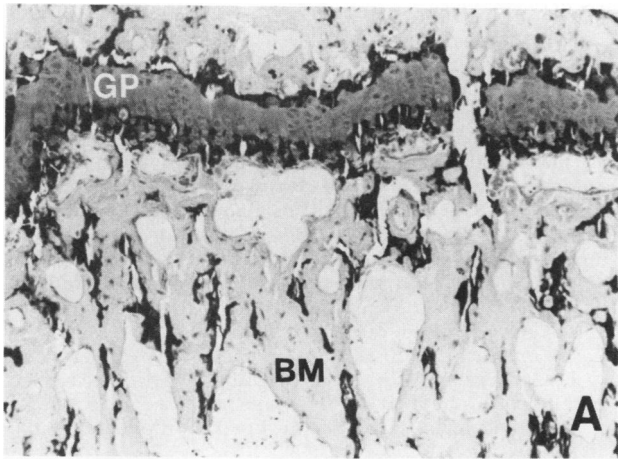


FIGURE 1 Morphologic aspect of the epiphyseal growthplate (GP) of a caudal vertebra in the normal (A) and in the Hyp/Y mouse untreated (B) or treated with Pi supplementation (C). Note that growthplate width was reduced within normal thickness in the Pi-treated mouse whereas the osteoid borders (O) remain excessively large along the calcified bone matrix (BM). Undecalcified, toluidine blue stained section, $\times 100$.

II, Fig. 1B and C). At the diaphyseal level, the osteoid surface was unchanged ($82.0 \pm 2.9\%$), the mineralization front was poorly improved while the periosteal but not the endosteal osteoid thickness was slightly reduced but not normalized. On the other hand, the extent of active osteoblasts and both the osteoclastic surface and the number of osteoclasts were markedly increased along the endosteal bone surface (Table II).

DISCUSSION

The present study demonstrates that, as in human VDRR (4, 6, 10), the rachitic lesion can be healed by Pi in the hypophosphatemic mouse. Although serum phosphorus measured in the fasting state was unchanged during Pi therapy, the marked elevation of Pi excretion shows that treated mice had a higher Pi absorption. The increased Mg excretion associated in untreated Hyp/Y with a slight hypermagnesemia appears to result from the deranged Pi homeostasis since correction of serum and urinary Mg concentrations could be achieved by Pi supplementation. In the rat, Pi depletion increases the Mg intestinal absorption and decreases the net renal tubular reabsorption of Mg with the main source of urinary loss being bone (11). In Hyp/Y mice, it is possible that correction of bone Mg content will require the normalization of endosteal bone mineralization.

As evidenced by correction of the growthplate thickness by Pi, normalization of the epiphyseal and metaphyseal calcification was achieved despite a Pi-induced drop in serum calcium. Although both calcium and Pi are essential for optimal epiphyseal mineralization, Pi seems to be the critical mineral required in the process (10, 12–14). As in VDRR (5), correction of epiphyseal calcification by Pi was associated with increased overall body length (1). The mutant animals, however, did not catch up within the normal range. This may be due to the severity of the bone disease already present at the onset of treatment.

As in the human disease, improvement of bone growth was associated with reduction of serum alkaline phosphatase concentration (5, 6). However, serum alkaline phosphatase was not corrected, which probably reflects the persistent abnormality of the endosteal bone mineralization. This discrete response of the epiphyseal and endosteal bone to Pi is fully in accordance with our findings in the human disease (5, 6). This may be due to the different ways minerals are supplied to the two regions and/or to a greater sensitivity of the epiphyseal cells to extracellular Pi concentration as compared with the endosteal cells (6).

In line with the human disease (5, 6) and with experimental studies in the rat (15), Pi supplementation lowered serum calcium, which probably induced a state of secondary hyperparathyroidism. Indeed, in-

creased serum parathyroid hormone levels have been found in Pi-treated Hyp mice (7). In the present study, urinary cAMP remained unchanged, suggesting that the phosphaturic effect of parathyroid hormone was already maximal before treatment. On the other hand, the marked increment of bone cells recruitment and activity observed in Pi treated mutants demonstrates that, as in VDRR (5, 6), bone turnover was greatly stimulated as a result of the probable increase in PTH secretion (15).

Our results show that the effects of Pi supplementation on the epiphyseal and endosteal bone mineralization and turnover are similar in Hyp/Y mice and VDRR children. In the latter, recent data showed that improvement of endosteal bone mineralization and prevention of Pi-induced secondary hyperparathyroidism require the pharmacologic use of 1,25-dihydroxyvitamin D₃ combined with Pi supplementation (6). A similar therapeutic approach, in the mutant animal, is currently under way in our laboratory.

ACKNOWLEDGMENTS

The authors are grateful to Ms. E. Rodriguez for invaluable technical assistance and to Ms. D. Bissonnette for expert secretarial work.

This work was supported by the Shriners of North America and the Conseil de la Recherche en Santé du Québec.

REFERENCES

1. Eicher, E. M., J. L. Southard, C. R. Scriver, and F. H. Glorieux. 1976. Hypophosphatemia: mouse model for human familial hypophosphatemic (vitamin D-resistant) rickets. *Proc. Natl. Acad. Sci. U. S. A.* **73**: 4667-4671.
2. Cowgill, L. D., S. Goldfarb, K. Lau, E. Slatopolsky, and Z. S. Agus. 1979. Evidence for an intrinsic renal tubular defect in mice with genetic hypophosphatemic rickets. *J. Clin. Invest.* **63**: 1203-1210.
3. Meyer, R. A. Jr., J. Jowsey, and M. H. Meyer. 1979. Osteomalacia and altered magnesium metabolism in the X-linked hypophosphatemic mouse. *Calcif. Tissue. Int.* **27**: 19-26.
4. Glorieux, F. H., C. R. Scriver, R. M. Reade, H. Goldman, and A. Roseborough. 1972. Use of phosphate and vitamin D to prevent dwarfism and rickets in X-linked hypophosphatemia. *N. Engl. J. Med.* **287**: 481-487.
5. Glorieux, F. H., P. J. Bordier, P. J. Marie, E. E. Delvin, and R. Travers. 1978. Inadequate bone response to phosphate and vitamin D in familial hypophosphatemic rickets. *In Homeostasis of Phosphate and Other Minerals.* S. G. Massry, E. Ritz, and A. Rapado, editors. Plenum Press, New York.
6. Glorieux, F. H., P. J. Marie, J. M. Pettifor, and E. E. Delvin. 1980. Bone response to phosphate salts, ergocalciferol and calcitriol in hypophosphatemic vitamin-D resistant rickets. *N. Engl. J. Med.* **303**: 1023-1031.
7. Tenenhouse, H. S., C. R. Scriver, R. R. McInness, and F. H. Glorieux. 1978. Renal handling of phosphate in vivo and in vitro by X-linked hypophosphatemic male mouse: Evidence for a defect in the brush border membrane. *Kidney Int.* **14**: 236-244.
8. Villanueva, A. R. 1973. Methods of preparing and interpreting mineralized sections of bone. *In Proceedings of the First Workshop on Bone Morphometry.* Z. F. G. Jaworski, editor. University of Ottawa press, Ottawa. 341-353.
9. Bordier, P. J., and S. Tun Chot. 1972. Quantitative histology of metabolic bone disease. *J. Clin. Endocrinol. Metab.* **1**: 197-215.
10. Fraser, D., N. T. Jaco, E. R. Yendt, J. D. Munn, and E. Liu. 1957. The induction of in vitro and in vivo calcification in bones of children suffering from vitamin D-resistant rickets without recourse to large doses of vitamin D. *Am. J. Dis. Child.* **93**: 84-85.
11. Kreusser, W. J., D. Kurokawa, E. Aznar, E. Sachtjen, and S. G. Massry. 1978. Effect of phosphate depletion on magnesium homeostasis in rats. *J. Clin. Invest.* **61**: 573-581.
12. Stendijk, R. 1961. The effect of a continuous intravenous infusion of inorganic phosphate on the rachitic lesions in cystinosis. *Arch. Dis. Child.* **36**: 321-324.
13. Brighton, C. T., and R. M. Hunt. 1978. The role of mitochondria in growth plate calcification as demonstrated in a rachitic model. *J. Bone Jt. Surg. (Am. Vol.)* **60-A**: 630-639.
14. Simmons, D. J., and A. S. Kunin. 1970. Development and healing of rickets in rats. I. Studies with tritiated thymidine and nutritional considerations. *Clin. Orthop. Relat. Res.* **68**: 252-260.
15. Harris, W. H., R. P. Heaney, L. A. Davis, E. H. Weinberg, R. D. Coutts, and A. L. Schiller. 1976. Stimulation of bone formation in vivo by phosphate supplementation. *Calcif. Tissue Res.* **22**: 85-98.