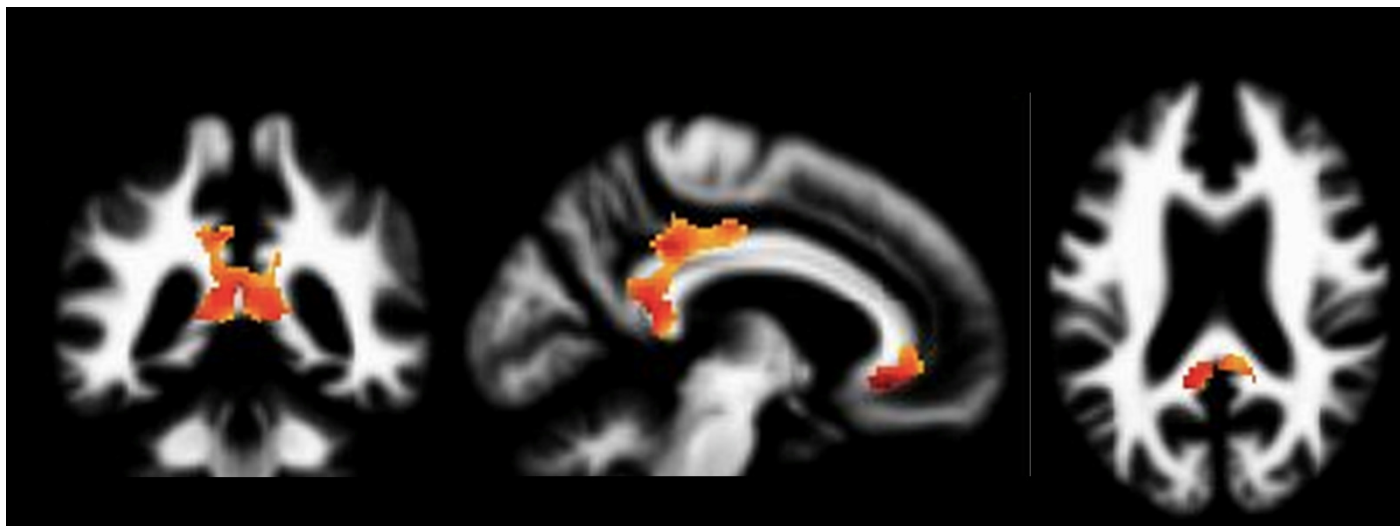


## LO-AD WM cingulum atrophy



## Grey matter atrophy in LO-AD

