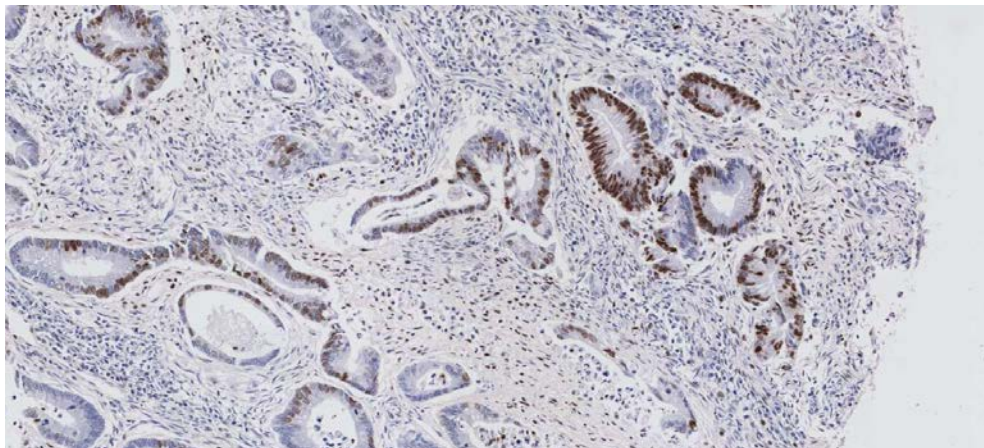


Loss of expression of ATM is associated with worse prognosis in colorectal cancer and loss of Ku70 expression is associated with CIN – Beggs et al

Figure S1: H2AX representative sections for IHC scoring

Positive:



Negative:

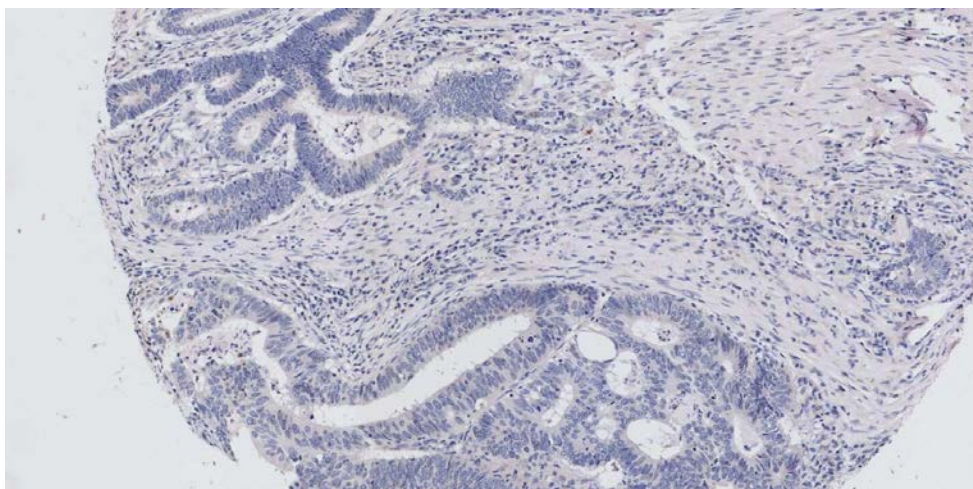
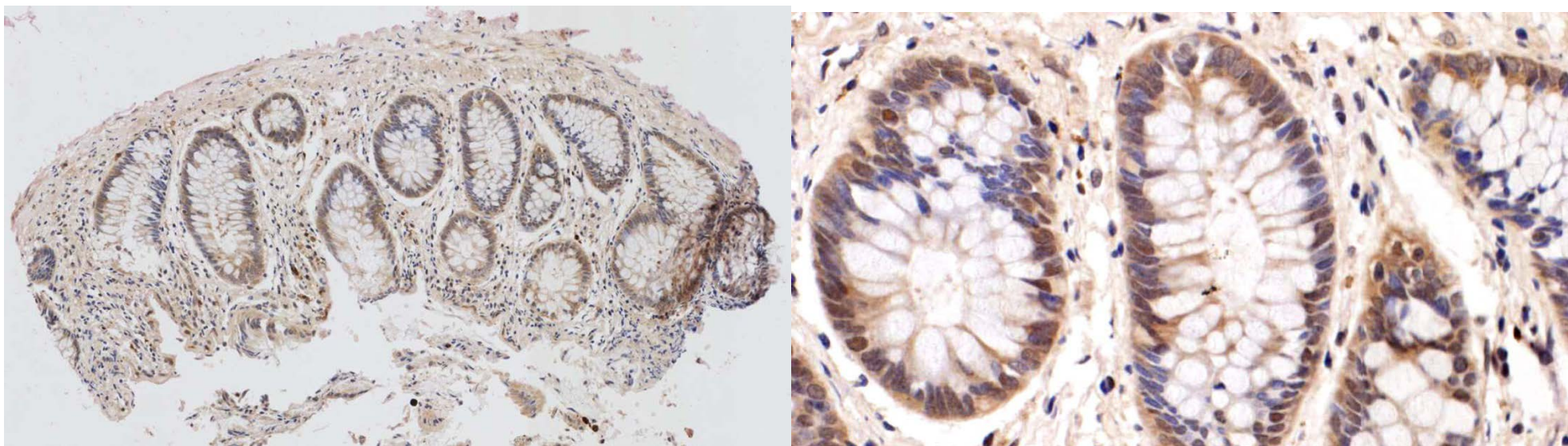


Figure S2: ATM representative sections for IHC scoring

Positive (left image = low power, right image = high power):



Negative (left image = low power, right image = high power)

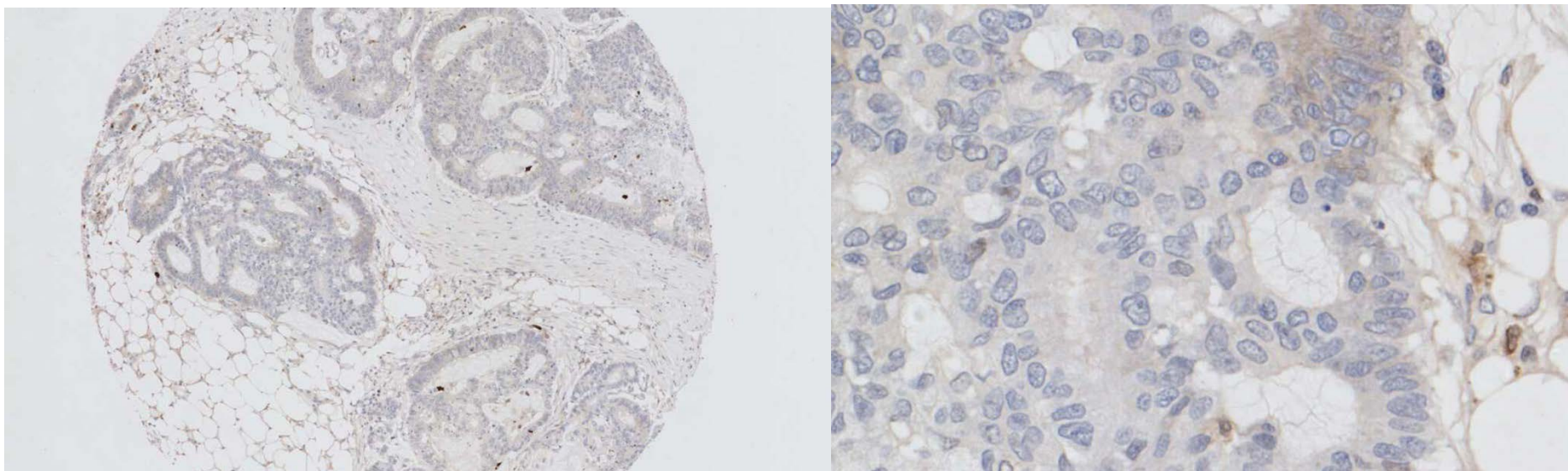
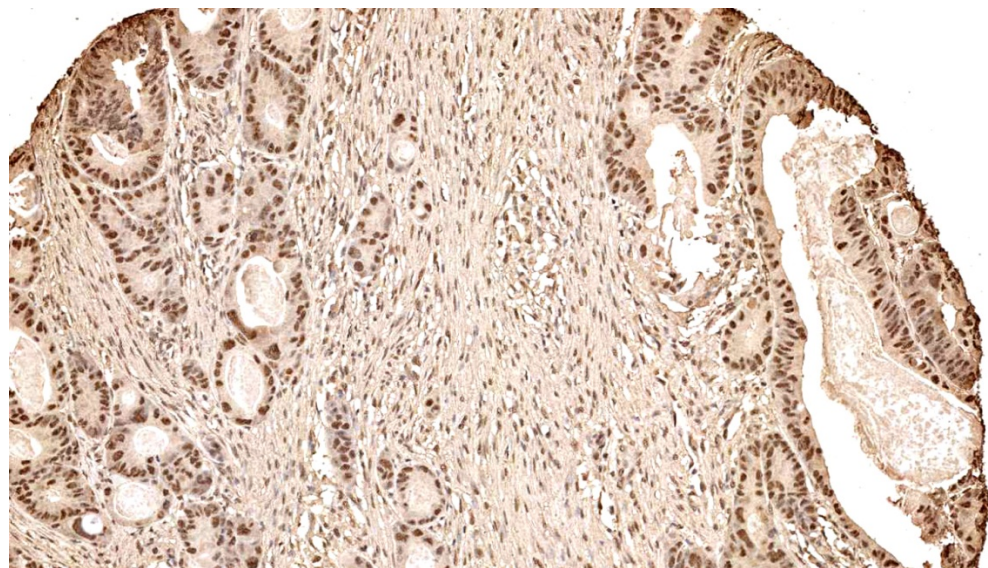


Figure 3: Ku70 representation sections for IHC scoring

Positive:



Negative:

