

# Osteomalacia Due to $1\alpha,25$ -Dihydroxycholecalciferol Deficiency

## ASSOCIATION WITH A GIANT CELL TUMOR OF BONE

MARC K. DREZNER and MARK N. FEINGLOS, *Department of Medicine, Division of Endocrinology, Veterans Administration Hospital and Duke University Medical Center, Durham, North Carolina 27710*

**ABSTRACT** Oncogenic osteomalacia is a syndrome in which unexplained osteomalacia remits after resection of a coexisting mesenchymal tumor. We have investigated the mechanism by which a giant cell tumor of bone caused biopsy-proved osteomalacia in a 42-yr-old woman. The biochemical abnormalities were: hypophosphatemia; decreased renal tubular maximum for the reabsorption of phosphate per liter of glomerular filtrate; negative calcium and phosphorus balance; hyperaminoaciduria; and subnormal calcemic response to exogenously administered parathyroid hormone. Malabsorption, hypophosphatasia, fluorosis, and acidosis were excluded as causes of the osteomalacia. Serum 25-hydroxycholecalciferol was normal ( $27 \pm 1$  ng/ml). However, the serum concentration of  $1\alpha,25$ -dihydroxycholecalciferol was low ( $1.6 \pm 0.1$  ng/100 ml). Oral administration of physiological amounts of  $1\alpha,25$ -dihydroxycholecalciferol resulted in resolution of the biochemical abnormalities of the syndrome and healing of the bone pathology. We suggest that tumor-induced inhibition of  $1\alpha,25$ -dihydroxycholecalciferol synthesis caused the osteomalacia. The causal role of the tumor was proved by demonstrating that resection was accompanied by roentgenographic evidence of bone healing and maintenance of normal serum phosphorus; renal tubular maximum for the reabsorption of phosphate; calcium and phosphorus balance; aminoaciduria; and calcemic response to exogenous parathyroid hormone.

Part of this work has been published in abstract form: 1977. *Clin. Res.* 25: 31A and 1977. Proceedings of the Third Workshop on Vitamin D, 9–13 January 1977. Walter De Gruyter & Co., Berlin. 863.

Dr. Drezner is a recipient of a Research and Education Award from the Veterans Administration.

Received for publication 6 April 1977 and in revised form 14 July 1977.

## INTRODUCTION

Osteomalacia that remits after resection of a coexisting mesenchymal tumor has been described in 13 patients (1–11). These patients with oncogenic osteomalacia presented with muscle weakness; bone roentgenograms showed changes of osteomalacia and/or rickets; and hypophosphatemia was present. Nine of these patients were adults and four, children, and the duration of symptoms ranged from 5 mo to 4 yr.

How tumors cause osteomalacia remains obscure. Neither ectopic secretion of a factor with calcitropic or phosphaturic effects, nor abnormalities in vitamin D action or metabolism have been demonstrated. The present investigation was designed to establish the diagnosis of oncogenic osteomalacia in a patient with giant cell tumor of bone and determine how the tumor caused this disorder. The data indicate that the osteomalacia was secondary to a deficiency of  $1\alpha,25$ -dihydroxycholecalciferol ( $1\alpha,25(\text{OH})_2\text{D}_3$ )<sup>1</sup> due to tumor-induced inhibition of vitamin  $\text{D}_3$  metabolism.

*Case description.* A 42-yr-old woman presented with generalized bone pain. At age 34 she developed easy fatiguability, muscle weakness, and the sudden onset of back pain. She was a normal-appearing woman without physical evidence of bone disease. Serum calcium was 9.3 mg/100 ml (normal 8.5–10.5), serum phosphorus 1.3 mg/100 ml (normal 2.5–4.5), and serum alkaline phosphatase 135 U (normal 30–85). Bone roentgenograms showed decreased bone density, multiple cortical defects, and a lytic lesion ( $2 \times 2$  cm) with sclerotic margins in the right iliac wing. Bone

<sup>1</sup> Abbreviations used in this paper:  $1\alpha,25(\text{OH})_2\text{D}_3$ ,  $1\alpha,25$ -dihydroxycholecalciferol;  $25(\text{OH})\text{D}_3$ , 25-hydroxycholecalciferol; TmP/GFR, tubular maximum of phosphate normalized to glomerular filtration rate.

biopsy from the left anterior iliac crest revealed osteomalacia and that from the lytic lesion, in the right iliac crest, showed fibroblastic proliferation and multinucleated giant cells consistent with an osteoclastoma. Family history was negative for bone disease, and serum calcium and phosphorus were normal in both parents, all siblings, and children. Chemical studies in the patient revealed normal urinary acidification, a decreased tubular maximum for the reabsorption of phosphate ( $TmP/GFR = 1.41 \text{ mg}/100 \text{ ml}$  [normal 2.5–4.55]), increased glycinuria, and normal fecal fat excretion. The diagnosis of acquired hypophosphatemic rickets with secondary hyperparathyroidism was made and therapy instituted (see below).

Over the next 7 yr bone pain became progressively worse, involving the back, pelvis, and long bones, and physical activity was markedly limited. Bone roentgenograms showed the development of non-traumatic pathologic fractures of the pelvis and expansion of the lytic lesion in the right iliac crest. During this period the patient received ergocalciferol (50,000–200,000 U/day), calcium (1–2 g/day), and phosphorus (2–4 g/day), alone and in combination. In spite of therapy, the serum concentration of calcium and phosphorus remained unchanged. Lack of therapeutic success prompted reevaluation in 1975 and repeat biopsy of the expanding lytic lesion showed a neoplasm containing many giant cells with 10–15 nuclei/cell, consistent with giant cell tumor of bone. The coexistence of giant cell tumor of bone and osteomalacia suggested the diagnosis of oncogenic osteomalacia and the patient was referred for evaluation. In preparation for study all medicines were discontinued for 10 mo.

Physical examination revealed a normal-appearing woman. There was pain on percussion over the lumbosacral spine and pain on internal and external rotation or flexion of the right hip. Muscular strength appeared intact but was difficult to assess in the right leg secondary to pain on movement. Chvostek and Trousseau signs were absent.

## METHODS

The patient was hospitalized in the Duke University Medical Center Clinical Research Unit and informed consent obtained for all studies. Dietary phosphorus was maintained at 1,200 mg/day and dietary calcium at 800 mg/day.

Bovine parathyroid extract for parenteral use of proved activity was obtained from Eli Lilly and Company (Indianapolis, Ind.).  $1\alpha,25(\text{OH})_2\text{D}_3$  for oral administration was supplied by the Chemical Research Department, Hoffmann-La Roche, Inc. (Nutley, N. J.).

**Biochemical studies.** Serum calcium (normal 8.5–10.5 mg/100 ml), creatinine (normal 0.7–1.2 mg/100 ml), and alkaline phosphatase (normal 30–100 U) were measured on the multichannel Technicon Autoanalyser (Technicon Instruments Corp., Tarrytown, N. Y.). Serum phosphorus (normal

2.5–4.5 mg/100 ml) was determined by the colorimetric method of Dryer et al. (12). Urine specimens were stored at  $-20^\circ\text{C}$  before analysis of calcium (by atomic absorption spectrophotometry), phosphorus (13), creatinine (14), and amino acids (15). Fecal fat excretion was measured by the method of Van de Kamer et al. (16) on 72-h fecal collections marked by carmine red dye and collected during ingestion of 70 g fat/day. Urinary D-xylose was measured (17) in 5-h urine specimens after the ingestion of 25 g of D-xylose.

**Balance studies and assessment of renal phosphate handling.** Calcium and phosphorus balance were determined by measuring dietary phosphorus and calcium in weighed duplicate portions of the ingested diet and subtracting urinary and fecal calcium or phosphorus excretion over 5-day periods. Studies were performed after at least 2 wk of equilibration on diet alone or diet and medication. Fecal collections were marked by carmine red dye. Aliquots of homogenized diet and feces were ashed at  $700^\circ\text{C}$  for 2–3 h, and the samples were solubilized in 6 N hydrochloric acid. Calcium was measured in these specimens by atomic absorption spectrophotometry. Phosphorus concentration was determined by a modification of the method of Dryer et al. (12), wherein samples and standards were in 0.6 N hydrochloric acid.

The tubular maximum for the reabsorption of phosphate normalized to glomerular filtration rate ( $TmP/GFR$ ) was calculated by the method of Bijvoet (18). Estimation of the normalized tubular maximum of phosphate is possible from the published nomogram (18) and unpublished observations in our laboratory have confirmed that the estimated value does, in fact, accurately approximate the value of  $TmP/GFR$  determined during phosphate infusion. For these studies serial 1-h urine collections on selected mornings were preceded by a water load of 20 ml/kg body wt. The urine phosphate (13) and creatinine (14) were determined in each specimen, serum determinations of phosphorus (12) and creatinine obtained at the midpoint of each collection, and the  $TmP/GFR$  estimated by appropriate calculations and use of the nomogram. The values reported are the mean  $\pm$  SEM of 20 determinations.

**Radioimmunoassays and competitive binding protein assays.** Serum parathyroid hormone was measured by three separate radioimmunoassays. A carboxy-terminal-specific assay (normal  $<40 \mu\text{l eq/ml}$ ) employing  $\text{GP}_1\text{M}$  antibody was purchased from the Mayo Medical Laboratory Rochester, Minn. (19). An amino-terminal-specific assay (normal  $<0.125 \text{ ng/ml}$ ) employing a guinea pig antibody raised against the synthetic (1–34) amino-terminal peptide of human parathyroid hormone was performed by Dr. Samuel Wells, Duke University Medical Center, according to the methods of Fischer et al. (20). Dr. Joel Habener (Massachusetts General Hospital, Boston, Mass.) measured parathyroid hormone (normal  $<10 \mu\text{l eq/ml}$ ) by a primarily carboxy-terminal immunoassay employing the  $\text{GP}_1$  antibody (21).

Plasma 25-hydroxycholecalciferol ( $25[\text{OH}]\text{D}_3$ ) and  $1\alpha,25(\text{OH})_2\text{D}_3$  concentrations were measured by Dr. Mark Hausler, University of Arizona Health Sciences Center, Tucson, according to previously published methods (22, 23). The results are presented as the mean  $\pm$  SEM of triplicate determinations.

**Bone studies.** Bone biopsies were obtained from the left anterior iliac crest under local anesthesia and the specimens preserved in 70% alcohol. Bone morphology was assessed and quantitative analysis performed by Dr. Jenifer Jowsey, Mayo Clinic, Rochester, Minn., employing previously described techniques (24, 25).

## RESULTS

**Metabolic cause of the osteomalacia.** A carefully documented dietary and medication history excluded fluoride as a cause of the osteomalacia. A negative family history of bone disease, normal serum alkaline phosphatase activity ( $95 \pm 6$  U), and the absence of detectable phosphoethanolamine in the urine eliminated adult-onset hypophosphatasia. Fecal fat excretion of 2.5 g/day (normal  $< 5$  g/day) and urinary D-xylose excretion of 4.5 g/5 h (normal  $> 2.5$  g/5 h) precluded impaired vitamin D absorption, secondary to steatorrhea. A serum pH of 7.42 and generation of a urine pH of 3.50 (normal  $< 4.5$ ) in response to an ammonium chloride infusion excluded systemic acidosis and renal tubular acidosis.

A history of normal dietary intake, normal liver and renal function tests (creatinine clearance 99.5 ml/min), and lack of drug exposure (e.g., phenobarbital and dilantin) indicated no obvious cause for vitamin D<sub>3</sub> deficiency or altered vitamin D<sub>3</sub> metabolism. Nevertheless, we measured the vitamin D<sub>3</sub> metabolites. The serum 25(OH)D<sub>3</sub> concentration was  $27 \pm 1$  ng/ml (normal 15–40), confirming the impression of normal

vitamin D<sub>3</sub> stores and normal cholecalciferol 25-hydroxylase activity. In contrast, the serum  $1\alpha,25$ -(OH)<sub>2</sub>D<sub>3</sub> concentration was  $1.6 \pm 0.1$  ng/100 ml (normal 2.1–4.5), an abnormally low value, indicating that a deficiency of this active vitamin D<sub>3</sub> metabolite might be related to the pathogenesis of the osteomalacia.

**Role of  $1\alpha,25$ (OH)<sub>2</sub>D<sub>3</sub> in the pathogenesis of oncogenic osteomalacia.** Tests designed to measure calcium and phosphorus homeostasis and parathyroid function were performed in the base-line state. After completion of these measurements,  $1\alpha,25$ (OH)<sub>2</sub>D<sub>3</sub> was administered orally in an initial dose of 0.5  $\mu$ g/day, gradually increased to a maintenance dose of 3.0  $\mu$ g/day (0.06  $\mu$ g/kg per day). After 2 wk of maintenance therapy, the biochemical studies were repeated. Subsequently, after cessation of therapy and upon return of the biochemical abnormalities to values comparable to the base line (serum calcium 8.9 mg/100 ml; serum phosphorus 1.6 mg/100 ml; and TmP/GFR 0.62 mg/100 ml [see below for comparison]), the tumor was resected. After surgery the patient received no medication, and after several weeks the biochemical studies were repeated.

The mean base-line serum calcium concentration

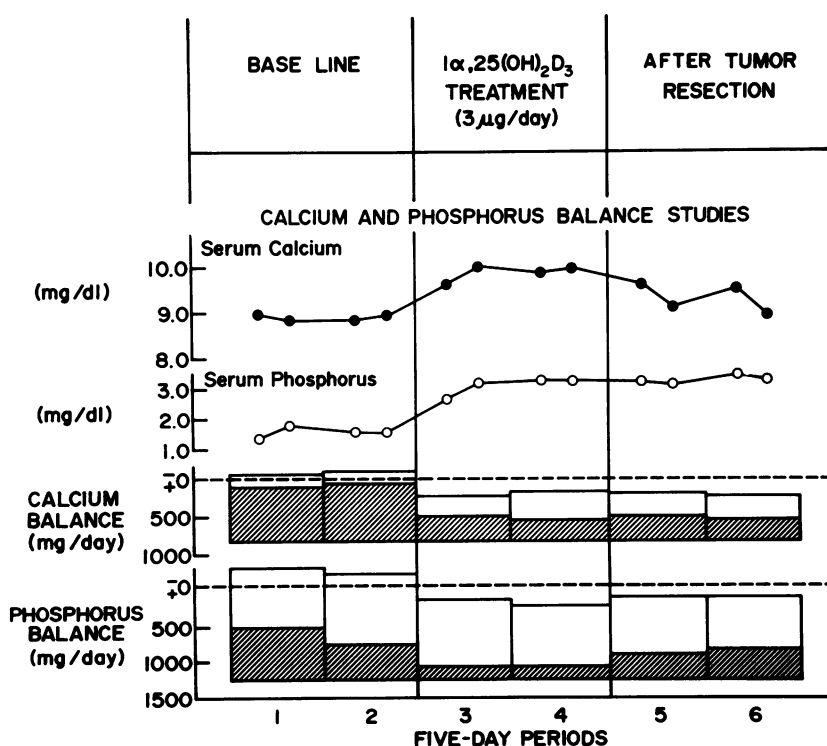


FIGURE 1 Calcium and phosphorus balance studies in the base-line state, during treatment with  $1\alpha,25$ (OH)<sub>2</sub>D<sub>3</sub> (3  $\mu$ g/day), and after tumor resection, shown according to the methods of Reifenstein et al. (26). The dietary calcium and phosphorus are plotted below the 0 line. Fecal excretion is represented by the hatched areas and urinary excretion by the open areas. Extension of the columns above 0 indicate negative balance and termination of the columns below 0 indicate positive balance.

was  $8.92 \pm 0.11$  mg/100 ml (range 8.6–9.4), a value within normal limits. In contrast, the base-line serum phosphorus concentration was below normal, mean  $1.48 \pm 0.07$  mg/100 ml (range 1.2–1.8). In response to both  $1\alpha,25(\text{OH})_2\text{D}_3$  therapy and tumor resection, the serum calcium remained normal ( $9.50 \pm 0.07$  and  $8.81 \pm 0.21$  mg/100 ml, respectively), while the serum phosphorus concentration increased to values within the normal range ( $3.19 \pm 0.03$  and  $3.22 \pm 0.03$  mg/100 ml).

TmP/GFR was quantitated in the three study periods. In the base-line state the TmP/GFR was  $0.82 \pm 0.03$  mg/100 ml, a value below normal (2.5–4.55), indicating that a renal phosphate leak was present. After treatment with  $1\alpha,25(\text{OH})_2\text{D}_3$  or tumor resection, however, the TmP/GFR rose to  $2.95 \pm 0.01$  and  $2.55 \pm 0.07$  mg/100 ml, respectively.

The calcium and phosphorus balances in the three study periods are shown in Fig. 1. In the base-line period the calcium balance averaged  $-95$  mg/day while the phosphorus balance averaged  $-210$  mg/day. The negative calcium balance was secondary to gastrointestinal malabsorption (110 mg/day absorbed; normal  $325 \pm 25$  [27]), while the negative phosphorus balance resulted from both gastrointestinal malabsorption (525 mg/day absorbed; normal 771 [28]) and renal phosphate loss (TmP/GFR, 0.82 mg/100 ml). Treatment with  $1\alpha,25(\text{OH})_2\text{D}_3$  or tumor resection resulted in a positive calcium balance (162 and 155 mg/day, respectively) and a positive phosphorus balance (205; 150 mg/day).

We also measured the calcemic response to exogenously administered parathyroid extract. Parathyroid extract (200 U) was administered intramuscularly every 6 h for 48 h or until a rise in the serum calcium to elevated values occurred. While in normal controls the serum calcium increased more than 1.0 mg/100 ml during this treatment (29–32), in our patient there was a subnormal increase in calcium in the base-line state (0.9 mg/100 ml at 50 h). In response to therapy with  $1\alpha,25(\text{OH})_2\text{D}_3$  and after tumor resection, the calcemic response returned to normal, with an increase of 2.5 and 2.4 mg/100 ml, respectively, at 14 h.

Increased urinary excretion of one or more amino acids has previously been reported in patients with oncogenic osteomalacia (2, 4, 6, 10). In the base-line state, our patient excreted markedly elevated quantities of glycine, leucine, serine and arginine, as well as increased amounts of several additional amino acids (Table I).  $1\alpha,25(\text{OH})_2\text{D}_3$  therapy and tumor resection reduced the urinary amino acid excretion to normal levels.

Many of the abnormalities noted might have been due to elevated levels of parathyroid hormone, and the response to  $1\alpha,25(\text{OH})_2\text{D}_3$  therapy or tumor resection due to alterations in parathyroid hormone con-

TABLE I  
Urinary Amino Acid Excretion in the Base-Line State, after Treatment with  $1\alpha,25(\text{OH})_2\text{D}_3$ , and after Tumor Resection

Amino acid	Urinary excretion			
	Base line	$1\alpha,25(\text{OH})_2\text{D}_3$ (3 $\mu\text{g/day}$ )	After tumor resection	Normal
	$\mu\text{mol/g creatinine}$			
Alanine	528	173	86	36–394
Valine	83	45	33	3–39
Glycine	3,798	1,890	1,829	419–2,285
Isoleucine	38	20	7	1–98
Leucine	85	21	10	10–28
Proline	277	57	36	33–216
Threonine	272	167	45	50–226
Serine	735	308	198	94–538
Cysteine	18	15	7	4–26
Methionine	27	14	9	4–22
Hydroxyproline	111	47	49	39–267
Phenylalanine	73	43	29	8–128
Aspartic acid*	350	170	139	39–193
Glutamic acid†	625	300	106	100–492
Tyrosine	115	47	32	4–166
Ornithine	290	103	148	76–212
Tryptophan	4	7	7	1–48
Arginine	906	185	200	43–223
Kynurenine	2	5	4	1–10
Cystathione	9	7	5	2–10
Cystine	118	52	60	16–66
Homocystine	7	4	1	1–10

\* Includes asparagine.

† Includes glutamine.

centration. However, at presentation the serum parathyroid hormone concentration was normal, as measured by three methods: a carboxy-terminal assay from the Mayo Medical Laboratory (25  $\mu\text{l}$  eq/ml); an amino-terminal assay with antibody directed against the 1–34 amino acid fragment (0.016 ng/ml); and a primarily carboxy-terminal assay developed against the intact molecule (4  $\mu\text{l}$  eq/ml). Furthermore, no significant change in the parathyroid hormone concentration as determined by the first two methods occurred upon treatment with  $1\alpha,25(\text{OH})_2\text{D}_3$  (22  $\mu\text{l}$  eq/ml and 0.018 ng/ml, respectively) or resection of the tumor (27  $\mu\text{l}$  eq/ml and 0.025 ng/ml, respectively).

Finally, the effects of  $1\alpha,25(\text{OH})_2\text{D}_3$  therapy on bone morphology are shown in Fig. 2. The bone biopsy obtained at presentation had large areas of unmineralized osteoid and widened osteoid seams. In contrast, the bone biopsy after treatment with  $1\alpha,25(\text{OH})_2\text{D}_3$  had considerably less unmineralized osteoid. These observations were confirmed by quantitative microradiography (Table II). A decrease in unmineralized osteoid, an increase in the mineraliza-

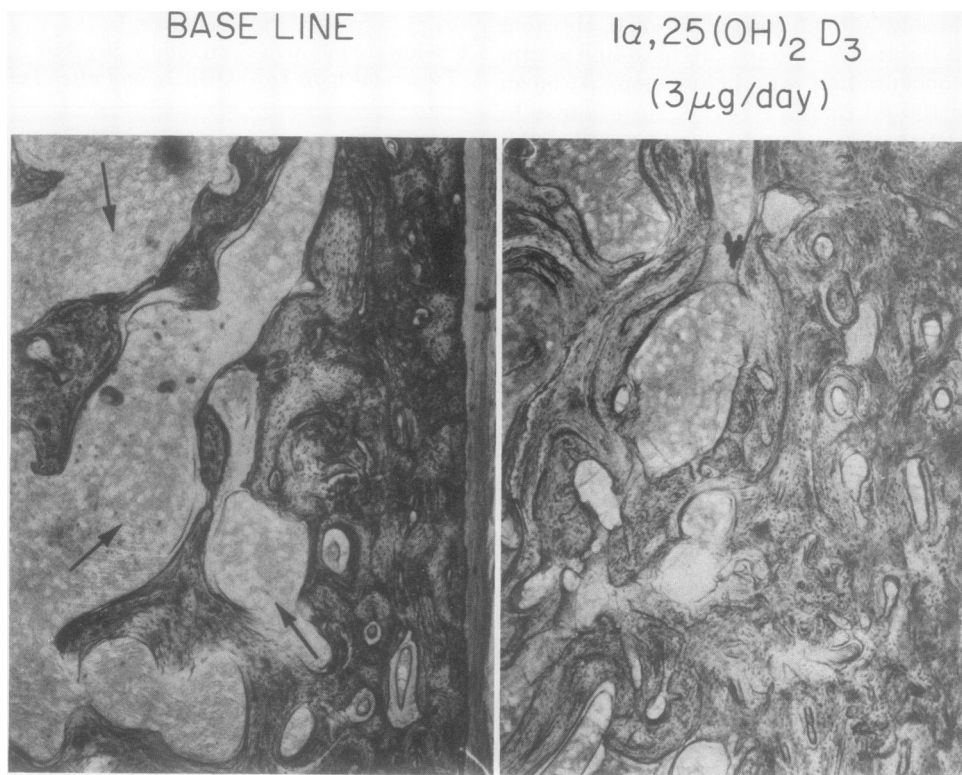


FIGURE 2 Bone biopsies from the left iliac crest. The unstained, calcified section shows large areas of unmineralized osteoid, denoted by the arrows. At the conclusion of therapy with  $1\alpha,25(\text{OH})_2\text{D}_3$  ( $3 \mu\text{g}/\text{day}$ ), a decrease in the amount of unmineralized osteoid is evident.

tion front, and a decrease in osteoid seam width indicate healing and normalization of the bone pathology upon treatment with  $1\alpha,25(\text{OH})_2\text{D}_3$ .

## DISCUSSION

Impaired conversion of vitamin  $\text{D}_3$  to  $1\alpha,25(\text{OH})_2\text{D}_3$  is responsible for several vitamin D-refractory osteo-

malacia syndromes (chronic renal insufficiency [33, 34], anticonvulsant-induced osteomalacia [35, 36], and hereditary vitamin D-dependent rickets [37]). The present study indicates that oncogenic osteomalacia is another vitamin D-refractory syndrome, caused by faulty conversion of vitamin  $\text{D}_3$  to its active metabolite,  $1\alpha,25(\text{OH})_2\text{D}_3$ .

Our patient presented with a giant cell tumor of bone and osteomalacia, suggesting the diagnosis of oncogenic osteomalacia. Resolution of the biochemical abnormalities of the syndrome after tumor resection, and roentgenographic evidence of bone healing (data not shown), established this diagnosis.

A deficiency of  $1\alpha,25(\text{OH})_2\text{D}_3$  was suggested by measurements of the serum concentration of  $25(\text{OH})\text{D}_3$  and  $1\alpha,25(\text{OH})_2\text{D}_3$ . Upon administration of  $1\alpha,25(\text{OH})_2\text{D}_3$ , the biopsy showed healing of the bone pathology (Fig. 2) and the biochemical abnormalities of the syndrome were corrected.

Two theories could explain the deficiency of  $1\alpha,25(\text{OH})_2\text{D}_3$  in our patient: defective conversion from  $25(\text{OH})\text{D}_3$ , or increased degradation of  $1\alpha,25(\text{OH})_2\text{D}_3$ . Although the physiological requirement for  $1\alpha,25(\text{OH})_2\text{D}_3$  in the human has been estimated at  $0.57 \mu\text{g}/\text{day}$  (38), the oral requirement for this compound in

TABLE II  
Quantitative Microradiography of Bone Biopsies before and after Treatment with  $1\alpha,25(\text{OH})_2\text{D}_3$

	Patient		Normal
	Base line	$1\alpha,25(\text{OH})_2\text{D}_3$ ( $3 \mu\text{g}/\text{day}$ )	
Formation, %	1.0	8.8	$2.0 \pm 0.6^*$
Resorption, %	2.4	—	$3.6 \pm 1.0$
Unmineralized osteoid, %	44.3	5.7	0
Mineralization front, %	18.7	58.8	$70 \pm 10$
Osteoid width, $\mu\text{m}$	28.8	22.5	$15.2$ ( $12.3-18.3$ ) $\dagger$

\* Mean  $\pm$  SD.

$\dagger$  Range.

a variety of disease states due to vitamin D<sub>3</sub> deficiency is 0.04–0.08 μg/kg per day (38–41). In view of this information, the dose of 1α,25(OH)<sub>2</sub>D<sub>3</sub> administered to our patient was probably in the physiological range. Resolution of the syndrome in response to this dose precludes increased degradation of this active vitamin D<sub>3</sub> metabolite as the cause of 1α,25(OH)<sub>2</sub>D<sub>3</sub> deficiency. Moreover, the inability to cure the osteomalacia with a dose of 200,000 U of ergocalciferol, 1,700 times the effective dose of 1α,25(OH)<sub>2</sub>D<sub>3</sub>, establishes that defective conversion of vitamin D<sub>3</sub> to its active metabolite underlies this disorder. Since the normal 25(OH)D<sub>3</sub> concentration indicates adequate cholecalciferol-25-hydroxylase activity, a reasonable interpretation of these findings is that a block exists in the metabolism of 25(OH)D<sub>3</sub> to 1α,25(OH)<sub>2</sub>D<sub>3</sub>.

It seems clear that the decreased production of 1α,25(OH)<sub>2</sub>D<sub>3</sub> was due to elaboration by the tumor of a factor that inhibited its synthesis. Although the precise control mechanisms operative in the kidney for the enzymatic hydroxylation of precursor vitamin D (25[OH]D<sub>3</sub>) to the active product are unknown, the interaction of parathyroid hormone, renal tubule cell cyclic AMP, and renal cell phosphate concentration has been determined (42). Our patient, however, had none of the abnormalities reported that impair vitamin D activation. Rather, sporadic onset of osteomalacia and 1α,25(OH)<sub>2</sub>D<sub>3</sub> deficiency occurred concurrently with the mesenchymal tumor, and the osteomalacia was cured after tumor resection. Thus, a role for the tumor in generating the 1α,25(OH)<sub>2</sub>D<sub>3</sub> deficiency is evident.

Although the biochemical features of this syndrome were for the most part characteristic of vitamin D deficiency (43), several measurements were at variance. First, there was a normal serum calcium concentration in our patient and in other patients with oncogenic osteomalacia. The serum calcium concentration in simple vitamin D deficiency is characteristically low (43, 44). However, the available data in several studies (45–48) show numerous examples of normal serum calcium in subjects with vitamin D-deficiency osteomalacia. In the subject of this study, the ability to maintain normocalcemia appears to be multi-factorial: (a) there was negligible urinary calcium excretion; (b) active bone mineralization was scant (Table II); (c) severe phosphate depletion probably increased mobilization of calcium from bone (49). Secondly, the presence of severe renal phosphate wasting without a measurable increase in parathyroid hormone was paradoxical. Although the radioimmunoassays employed may not reflect total circulating levels of active parathyroid hormone, the use of three separate assays with different antigenic specificities makes this unlikely. However, confirmation of normal parathyroid hormone activity by measurement of urinary cyclic

AMP excretion was precluded since tumor-secreted product(s) may independently alter urinary cyclic AMP. Nevertheless, phosphaturia may be a direct effect of 1α,25(OH)<sub>2</sub>D<sub>3</sub> deficiency. Recent studies support this possibility. DeLuca and associates (50, 51) have shown that 1α,25(OH)<sub>2</sub>D<sub>3</sub> increases renal phosphate reabsorption in thyroparathyroidectomized dogs. Further, Brautbar et al. (52) reported that 1α,25(OH)<sub>2</sub>D<sub>3</sub> likewise increased renal phosphate reabsorption in thyroparathyroidectomized animals supplemented with a constant infusion of small amounts of parathyroid hormone. Thus renal phosphate wasting is consistent with the effects of 1α,25(OH)<sub>2</sub>D<sub>3</sub> deficiency and normal parathyroid function. Although these observations provide an adequate explanation for the contrasting abnormalities of the oncogenic osteomalacia syndrome, we cannot exclude the possibility that a direct effect of other tumor-secreted product(s) contributes to the normocalcemia and renal phosphate wasting.

Thus oncogenic osteomalacia can be a form of vitamin-D-refractory osteomalacia due to altered vitamin D<sub>3</sub> metabolism. On the basis of our data we propose that the sequence of metabolic events underlying this disorder is: (a) a factor is synthesized and secreted by the tumor; (b) the factor decreases the synthesis of 1α,25(OH)<sub>2</sub>D<sub>3</sub> by inhibiting 25-hydroxycholecalciferol-1-hydroxylase activity; and (c) the resultant 1α,25(OH)<sub>2</sub>D<sub>3</sub> deficiency causes the osteomalacia and the attendant biochemical abnormalities. The role of a tumor in inducing the deficiency of 1α,25(OH)<sub>2</sub>D<sub>3</sub> not only has theoretical significance for tumor biology but in addition has potential practical importance in guiding therapy of surgically unmanageable cases.

#### ACKNOWLEDGMENTS

We are indebted to Dr. Jenifer Jowsey for performing the analyses of the bone biopsies; to Dr. Mark Haussler for measurement of 1α,25(OH)<sub>2</sub>D<sub>3</sub>; to Drs. Samuel Wells and Joel Habener for measurement of parathyroid hormone; to Drs. George J. Ellis III, Francis A. Neelon, and Kenneth A. McCarty, Jr., for referral of the patient and helpful discussions; to Dr. John Harrelson for surgical care of the patient; to Dr. Harold E. Lebovitz for generous support; and to Ms. Lu Ann Wingate and Ms. Holly B. Curtis for excellent technical assistance.

This study was supported by grants from the National Institute of Arthritis, Metabolic and Digestive Diseases of the National Institutes of Health (AM 01324, AM 07012), and by grant MO 1 FR 30 from the Clinical Research Center Branch Division of Research Facilities and Resources, U. S. Public Health Service.

#### REFERENCES

1. McCance, R. A. 1947. Osteomalacia with Looser's nodes (Milkman's syndrome) due to a raised resistance to vitamin D acquired about the age of 15 years. *Q. J. Med.* 16: 33–50.

2. Evans, D. J., and J. A. Azzopaidi. 1972. Distinctive tumours of bone and soft tissue causing acquired vitamin D-resistant osteomalacia. *Lancet*. **1**: 353-354.
3. Howard, J. E. 1965. Case records of the Massachusetts General Hospital (Case 38-1965). *N. Engl. J. Med.* **273**: 494-504.
4. Moser, C. R., and W. J. Fessel. 1974. Rheumatic manifestations of hypophosphatemia. *Arch. Intern. Med.* **134**: 674-678.
5. Olefsky, J., R. Kempson, H. Jones, and G. Reaven. 1972. "Tertiary" hyperparathyroidism and apparent "cure" of vitamin-D-resistant rickets after removal of an ossifying mesenchymal tumor of the pharynx. *N. Engl. J. Med.* **286**: 740-745.
6. Pollack, J. A., A. L. Schiller, and J. D. Crawford. 1973. Rickets and myopathy cured by removal of a nonossifying fibroma of bone. *Pediatrics*. **52**: 364-371.
7. Prader, A., R. Ielig, E. Uehlinger, and G. Stalder. 1959. Rachitis infolge Knochentumors. *Helv. Paediat. Acta*. **14**: 554-565.
8. Salassa, R. M., J. Jowsey, and C. D. Arnaud. 1970. Hypophosphatemic osteomalacia associated with "non-endocrine" tumors. *N. Engl. J. Med.* **283**: 65-70.
9. Yoshikawa, S., M. Kawabata, Y. Hatsuyama, O. Hosokawa, and T. Fujita. 1964. Atypical vitamin-D-resistant osteomalacia. Report of a case. *J. Bone Jt. Surg. Am. Vol.* **46-A**: 998-1007.
10. Linovitz, R. J., D. Resnick, P. Keissling, J. J. Kondon, B. Sehler, R. J. Wejdl, J. H. Rowe, and L. J. Deftos. 1976. Tumor-induced osteomalacia and rickets. A surgically curable syndrome. *J. Bone Jt. Surg. Am. Vol.* **58-A**: 419-423.
11. Wilhoite, D. R. 1975. Acquired rickets and solitary bone tumor: the question of a causal relationship. *Clin. Orthop. Relat. Res.* **109**: 210-211.
12. Dryer, R. L., A. R. Tammes, and J. I. Routh. 1957. The determination of phosphorus and phosphatase with *N*-phenyl-*p*-phenylenediamine. *J. Biol. Chem.* **225**: 177-183.
13. Friedel, R. O., and S. M. Schanberg. 1971. Incorporation *in vivo* of intracisternally injected <sup>32</sup>P into phospholipids of rat brain. *J. Neurochem.* **18**: 2191-2200.
14. Anker, R. M. 1954. The determination of creatine and creatinine in urine; a correction factor for the determination of twenty-four hour urinary excretion values. *J. Lab. Clin. Med.* **43**: 798-801.
15. Zumwalt, R. W., D. Roach, and C. W. Gehrke. 1971. The gas-liquid chromatography of amino acids in biological substances. *J. Chromatogr.* **54**: 171-193.
16. Van de Kamer, J. L., H. T. B. Hiurink, and H. E. Weyers. 1949. Rapid method for the determination of fat in feces. *J. Biol. Chem.* **177**: 347-355.
17. Roe, J. H., and E. W. Rice. 1948. A photometric method for the determination of free pentoses in animal tissues. *J. Biol. Chem.* **173**: 507-512.
18. Bijvoet, O. L. M. 1972. Renal phosphate excretion in man. *Folia Med. Neerl.* **15**: 84-93.
19. Arnaud, C. D., H. S. Tsao, and T. Littledike. 1971. Radioimmunoassay of human parathyroid hormone in serum. *J. Clin. Invest.* **50**: 21-34.
20. Fischer, J. A., U. Binswanger, and F. M. Dietrich. 1974. Human parathyroid hormone. Immunological characterization of antibodies against a glandular extract and the synthetic amino-terminal fragments 1-12 and 1-34 and their use in the determination of immunoreactive hormone in human sera. *J. Clin. Invest.* **54**: 1382-1394.
21. Habener, J. F., and J. T. Potts, Jr. 1976. Radioimmunoassay of parathyroid hormone. In *Hormones in Human Blood*. H. N. Antoniades, editor. Harvard University Press, Cambridge, Mass. 551-558.
22. Brumbaugh, P. F., D. H. Haussler, K. M. Bursac, and M. R. Haussler. 1974. Filter assay for 1 $\alpha$ ,25-dihydroxyvitamin D<sub>3</sub>. Utilization of the hormone's target tissue chromatin receptor. *Biochemistry*. **13**: 4091-4097.
23. Hughes, M.R., D. J. Baylink, P. G. Jones, and M. R. Haussler. 1976. Radioligand receptor assay for 25-hydroxyvitamin D<sub>2</sub>/D<sub>3</sub> and 1 $\alpha$ ,25-dihydroxyvitamin D<sub>2</sub>/D<sub>3</sub>. *J. Clin. Invest.* **58**: 61-70.
24. Jowsey, J. 1972. Calcium release from the skeleton of rachitic puppies. *J. Clin. Invest.* **51**: 9-15.
25. Jowsey, J., P. J. Kelly, B. L. Riggs, A. J. Bianco, Jr., D. A. Scholz, and J. Gershon-Cohen. 1965. Quantitative microradiographic studies of normal and osteoporotic bone. *J. Bone Jt. Surg. Am. Vol.* **47**: 785-806.
26. Reifenstein, E. C., Jr., F. Albright, and S. L. Wells. 1945. The accumulation, interpretation and presentation of data pertaining to metabolic balances, notably those of calcium, phosphorus, and nitrogen. *J. Clin. Endocrinol. Metab.* **5**: 367-395.
27. Linswiler, H. M., C. L. Joyce, and C. R. Anand. 1974. Calcium retention of young adult males as affected by level of protein and of calcium intake. *Trans. N. Y. Acad. Sci.* **36**: 333-340.
28. Husdan, H., and A. Rapoport. 1969. Estimation of calcium, magnesium, and phosphorus in diet and stool. *Clin. Chem.* **15**: 669-679.
29. MacGregor, M. E. 1968. Paediatric aspects of hypoparathyroidism. *Proc. R. Soc. Med.* **61**: 583-588.
30. Drezner, M. K., F. A. Neelon, M. Haussler, H. T. McPherson, and H. E. Lebovitz. 1976. 1,25-dihydroxycholecalciferol deficiency: the probable cause of hypocalcemia and metabolic bone disease in pseudohypoparathyroidism. *J. Clin. Endocrinol. Metab.* **42**: 621-628.
31. Fraser, D., S. W. Kooh, and C. R. Scriver. 1967. Hyperparathyroidism as the cause of hyperaminoaciduria and phosphaturia in human vitamin D deficiency. *Pediatr. Res.* **1**: 425-435.
32. Rasmussen, H., and P. Bordier. 1974. Vitamin D—biochemistry and physiology. In *The Physiological and Cellular Basis of Metabolic Bone Disease*. The Williams & Wilkins Company, Baltimore, Md. 207-249.
33. Brickman, A. S., J. W. Coburn, and A. W. Norman. 1972. Action of 1,25-dihydroxycholecalciferol, a potent kidney-produced metabolite of vitamin D<sub>3</sub>, in uremic man. *N. Engl. J. Med.* **287**: 891-895.
34. Mawer, E. B., J. Backhouse, C. M. Taylor, G. A. Lumb, and S. W. Stanbury. 1973. Failure of formation of 1,25-dihydroxycholecalciferol in chronic renal insufficiency. *Lancet*. **1**: 626-628.
35. Hahn, T. J., B. A. Hendin, C. R. Scharp, and J. G. Haddad, Jr. 1972. Effect of chronic anticonvulsant therapy on serum 25-hydroxycholecalciferol levels in adults. *N. Engl. J. Med.* **287**: 900-904.
36. Bouillon, R., J. Reynaert, J. H. Claes, W. Lissens, and P. DeMoor. 1975. The effect of anticonvulsant therapy on serum levels of 25-hydroxy-vitamin D, calcium and parathyroid hormone. *J. Clin. Endocrinol. Metab.* **41**: 1130-1135.
37. Fraser, D., S. W. Kooh, H. P. Kind, M. F. Holick, Y. Tanaka, and H. F. DeLuca. 1973. Pathogenesis of hereditary vitamin D-dependent rickets: an inborn error of vitamin D metabolism involving defective conversion of 25-hydroxyvitamin D to 1 $\alpha$ ,25-dihydroxyvitamin D. *N. Engl. J. Med.* **289**: 817-822.
38. Norman, A. W., and H. Henry. 1974. The role of the

- kidney and vitamin D metabolism in health and disease. *Clin. Orthop. Relat. Res.* **98**: 258–287.
39. Kooh, S. W., D. Fraser, H. F. DeLuca, M. F. Holick, R. E. Belsey, M. B. Clark, and T. M. Murray. 1975. Treatment of hypoparathyroidism and pseudo-hypoparathyroidism with metabolites of vitamin D: evidence for impaired conversion of 25-hydroxyvitamin D to 1 $\alpha$ ,25-dihydroxy-vitamin D. *N. Engl. J. Med.* **293**: 840–844.
  40. Brickman, A. S., J. W. Coburn, S. G. Massry, and A. W. Norman. 1974. 1,25-dihydroxy-vitamin D<sub>3</sub> in normal man and patients with renal failure. *Ann. Intern. Med.* **80**: 161–168.
  41. Russell, R. G. G., R. Smith, C. Preston, R. J. Walton, C. G. Woods, R. G. Henderson, and A. W. Norman. 1975. The effect of 1,25-dihydroxycholecalciferol on renal tubular reabsorption of phosphate, intestinal absorption of calcium and bone histology in hypophosphataemic renal tubular rickets. *Clin. Sci. Mol. Med.* **48**: 177–186.
  42. DeLuca, H. F. 1976. Vitamin D endocrinology. *Ann. Intern. Med.* **85**: 367–377.
  43. Rasmussen, H. 1974. Parathyroid hormone, calcitonin, and the calciferols. In *Textbook of Endocrinology*. R. H. Williams, editor, W. B. Saunders Co., Philadelphia, Pa. 5th edition. 660–773.
  44. Krane, S. M. 1977. Metabolic Bone Disease. In *Harrison's Principles of Internal Medicine*. G. W. Thorn, R. D. Adams, E. Braunwald, K. J. Isselbacher, and R. G. Petersdorf, editors. McGraw-Hill Book Company, New York. 2028–2038.
  45. Harris, F., R. Hoffenberg, and E. Black. 1965. Calcium kinetics in vitamin D deficiency rickets. 1. Plasma kinetic studies after intravenous and oral Ca<sup>47</sup>. *Metab. Clin. Exp.* **14**: 1101–1111.
  46. Morgan, D. B., C. R. Paterson, C. G. Woods, C. N. Pulvertaft, and P. Fourman. 1965. Osteomalacia after gastrectomy: a response to very small doses of vitamin D. *Lancet*. **II**: 1089–1091.
  47. Dent, C. E., and R. Smith. 1969. Nutritional osteomalacia. *Ot. I. Med.* **38**: 195–209.
  48. Arnstein, A. R., B. Frame, and H. M. Frost. 1967. Recent progress in osteomalacia and rickets. *Ann. Intern. Med.* **67**: 1296–1330.
  49. Lotz, M., E. Zisman, and F. C. Bartter. 1968. Evidence for a phosphorus-depletion syndrome in man. *N. Engl. J. Med.* **278**: 409–415.
  50. Tanaka, Y., and H. F. DeLuca. 1974. Role of 1,25-dihydroxyvitamin D<sub>3</sub> in maintaining serum phosphorus and curing rickets. *Proc. Natl. Acad. Sci. U. S. A.* **71**: 1040–1044.
  51. Puschett, J. B., P. C. Fernandez, I. T. Boyle, R. W. Gray, J. L. Omdahl, and H. F. DeLuca. 1972. The acute renal tubular effects of 1,25-dihydroxycholecalciferol. *Proc. Soc. Exp. Biol. Med.* **141**: 379–384.
  52. Brautbar, N., M. Yaron, and J. W. Coburn. 1977. Interactions between parathyroid hormone and 1,25(OH)<sub>2</sub>-vitamin D<sub>3</sub> on renal handling of phosphate by the dog. Proceedings of the Third Workshop on Vitamin D, 9–13 January 1977. Walter De Gruyter & Co., Berlin. (Abstr.)