

Beyond cytoarchitectonics: The internal and external connectivity structure of the caudate nucleus

Short title: Connectivity structure of the caudate nucleus

Sonja A. Kotz^{1,*}, Alfred Anwander¹, Hubertus Axer², and Thomas R. Knösche¹

¹Max Planck Institute for Human Cognitive and Brain Sciences, Leipzig, Germany

²Hans Berger Clinic for Neurology, Jena University Hospital, Friedrich-Schiller-University, Jena, Germany

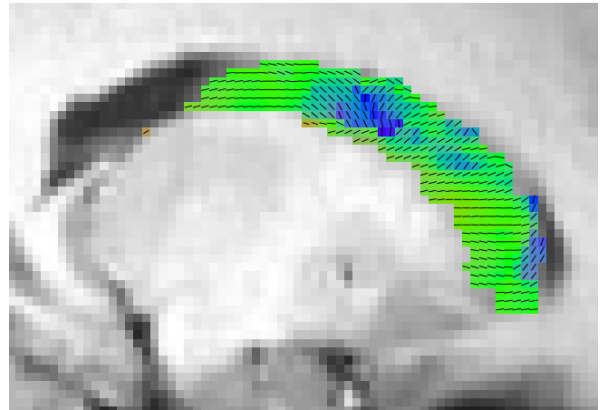
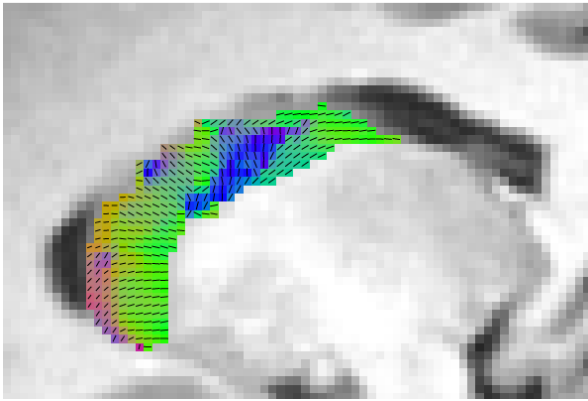
Supplementary material includes:

2 Figures

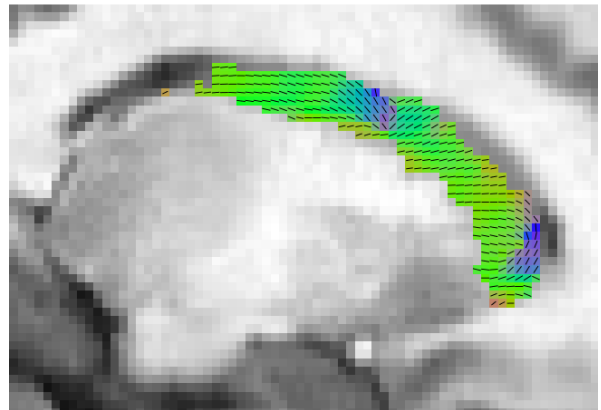
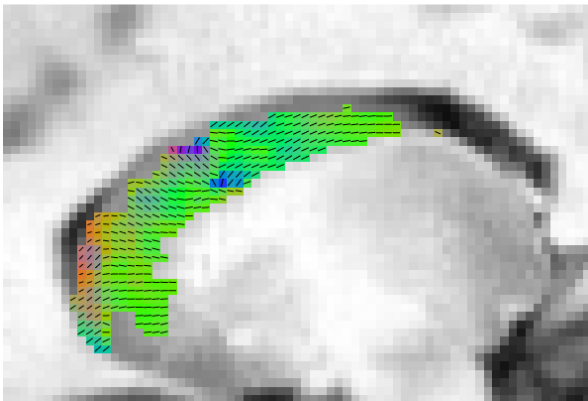
left CN

right CN

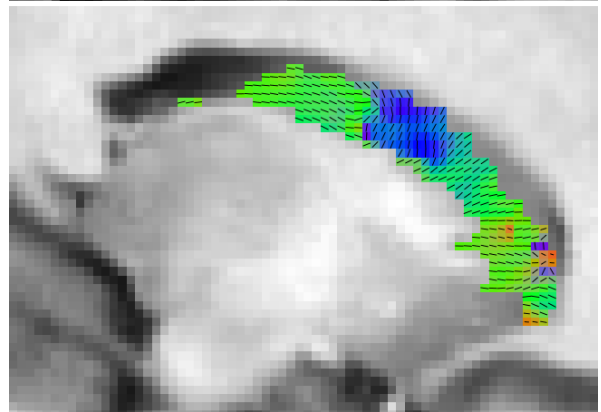
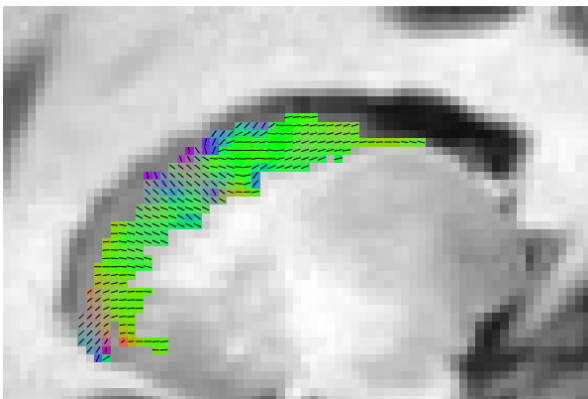
1



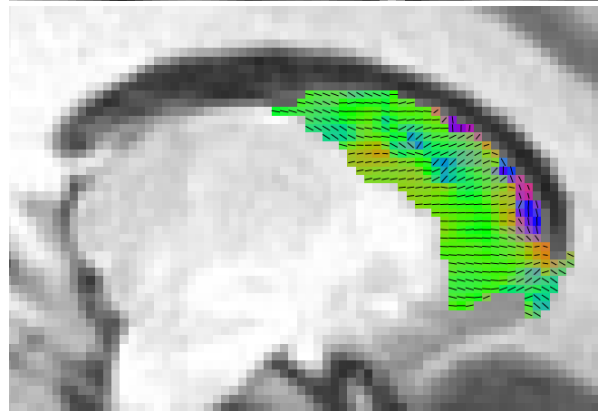
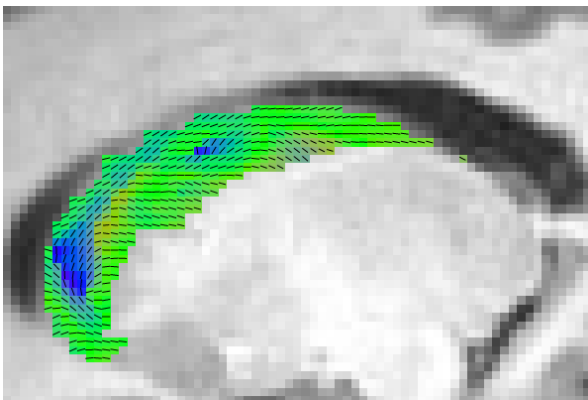
2



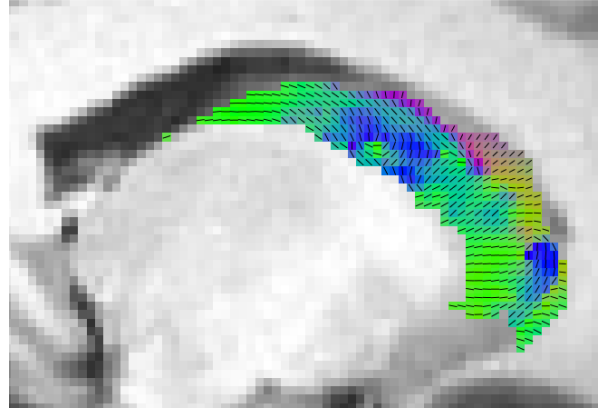

3





4



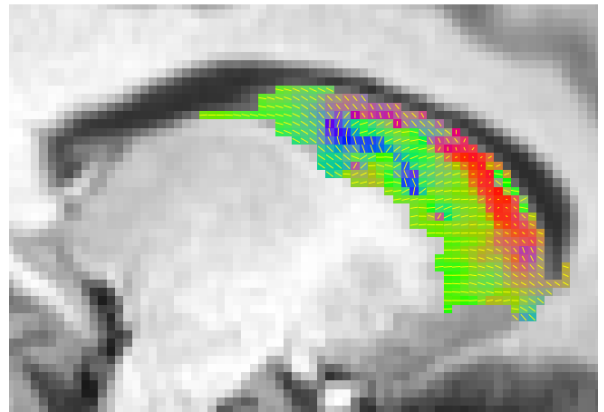
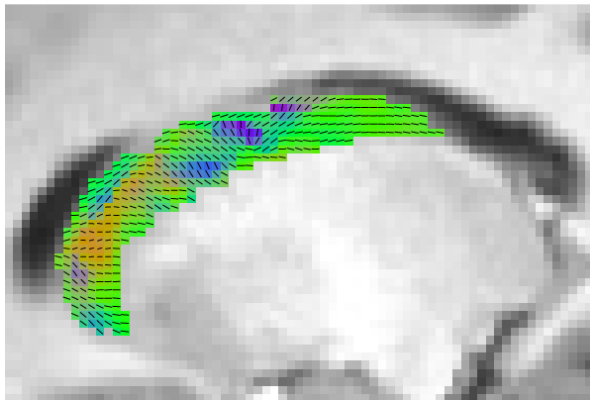
5



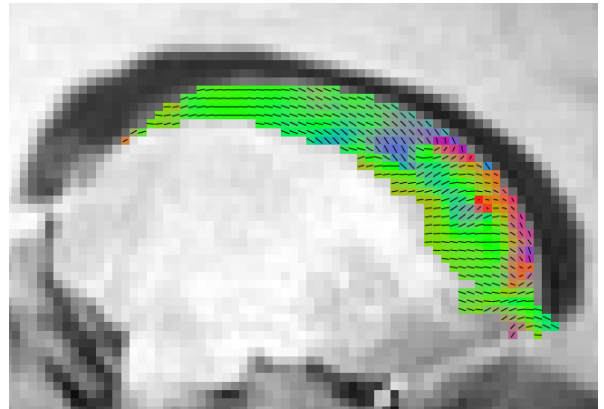
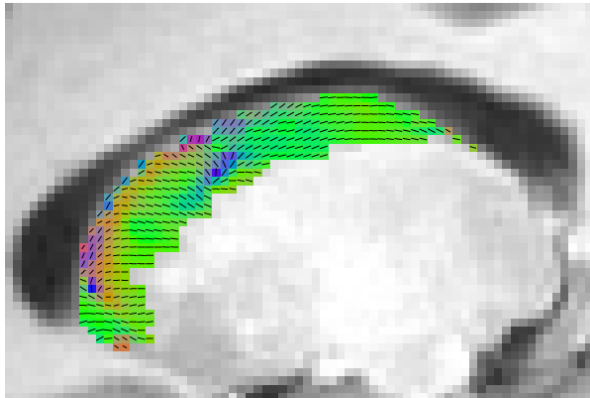
6



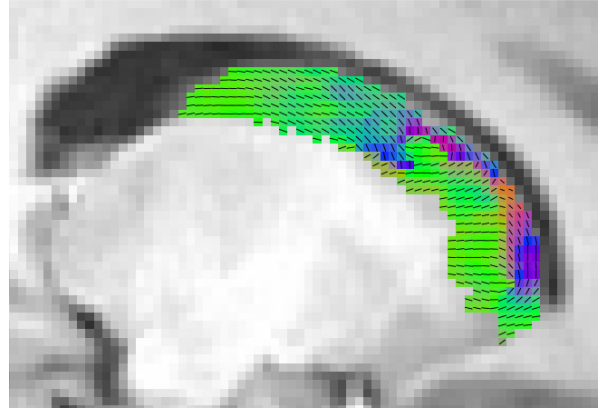
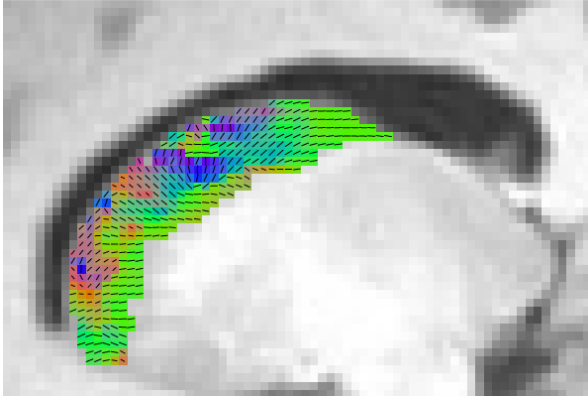
7



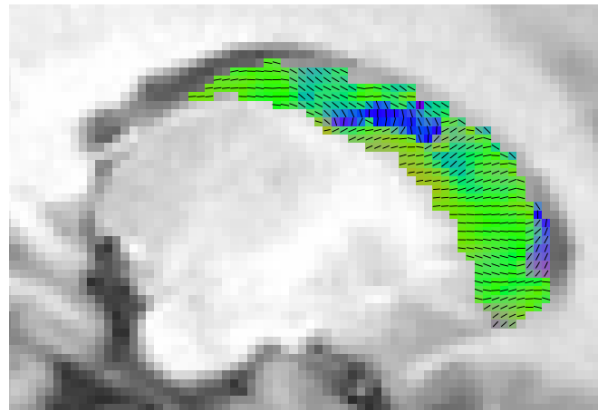
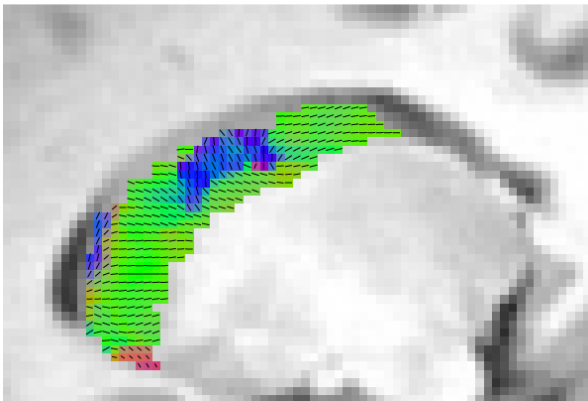
8



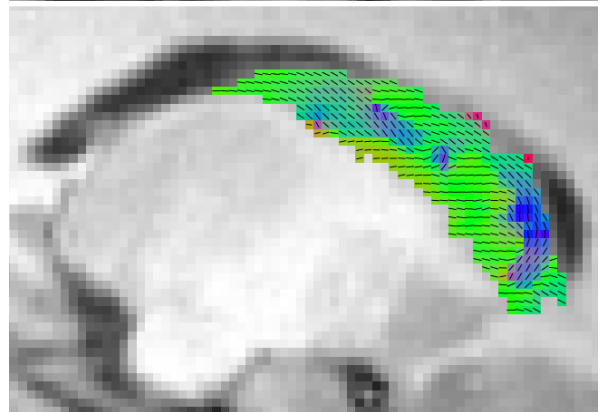

9



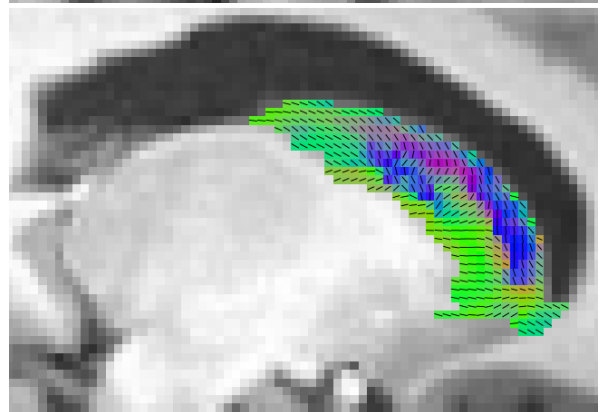
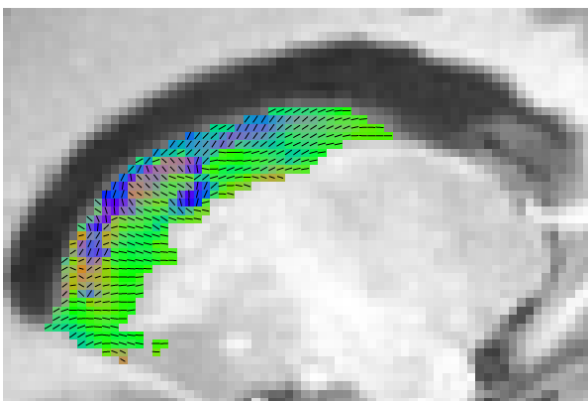
10



11



12



13

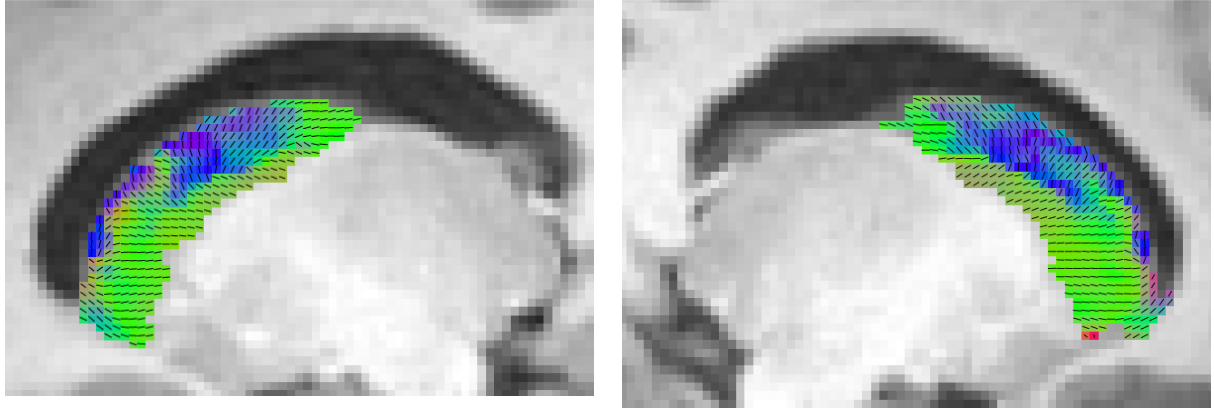

Figure S1: Direction-coded color images of the main diffusion direction derived from diffusion tensor imaging (DTI; blue: inferior-superior; red: left-right; green: posterior-anterior) of all participants, superimposed on sagittal anatomical slices (in Talairach space) of the left and right caudate nuclei. For each participant we show a central slice through the head and body of the CN. The representation shows only a central slice. For additional details see legend Figure 2.