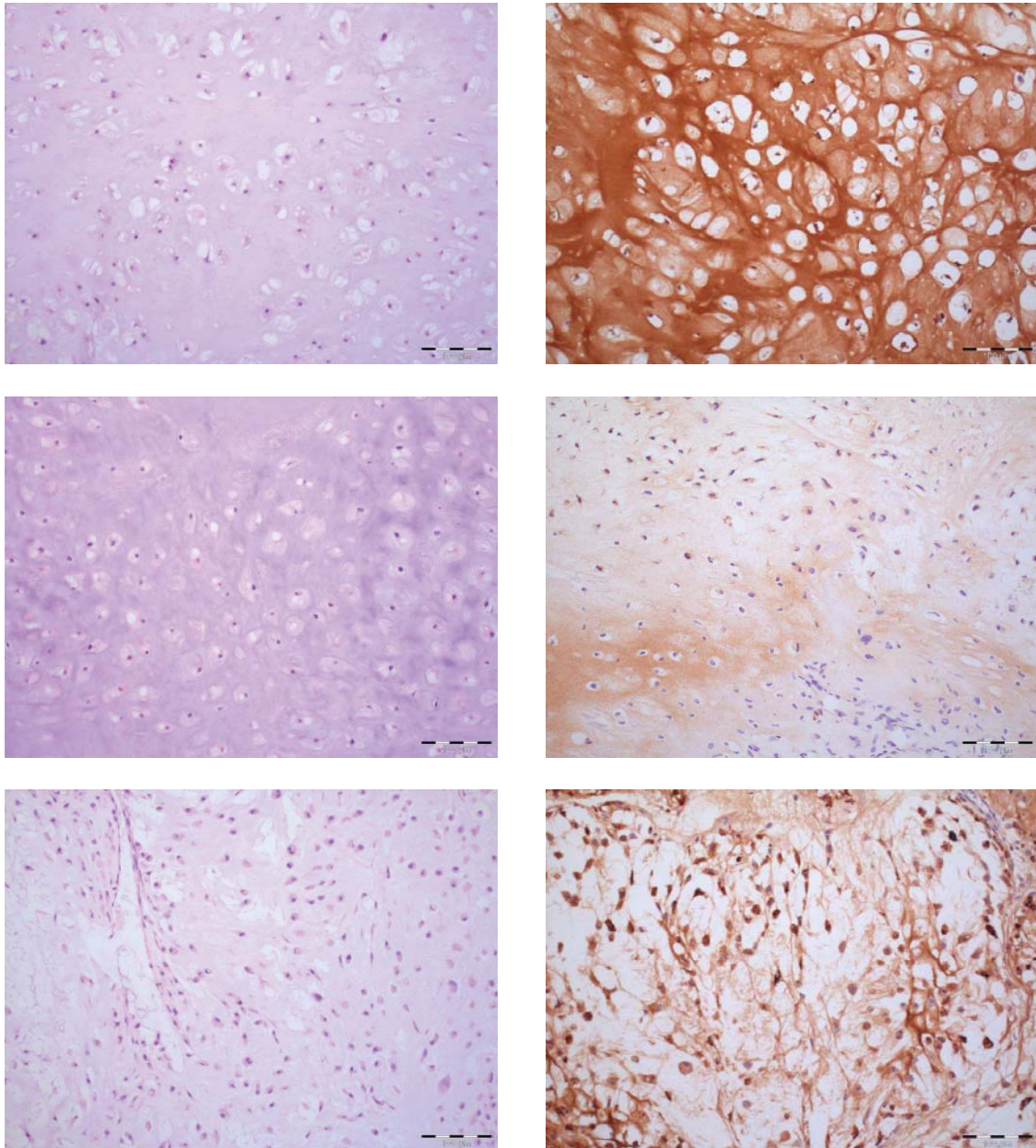


## Supplementary Figure 2

Immunohistochemical staining of COL2A1 in chondrosarcoma



Representative images of COL2A1 staining in chondrosarcoma. Left panel: haematoxylin and eosin stained sections. Right side of panel: COL2A1 staining by immunohistochemistry. Scale bar: 100  $\mu$ m.

(A) Diffuse matrix staining considered normal for cartilage

(B, C) Abnormal focal staining of matrix