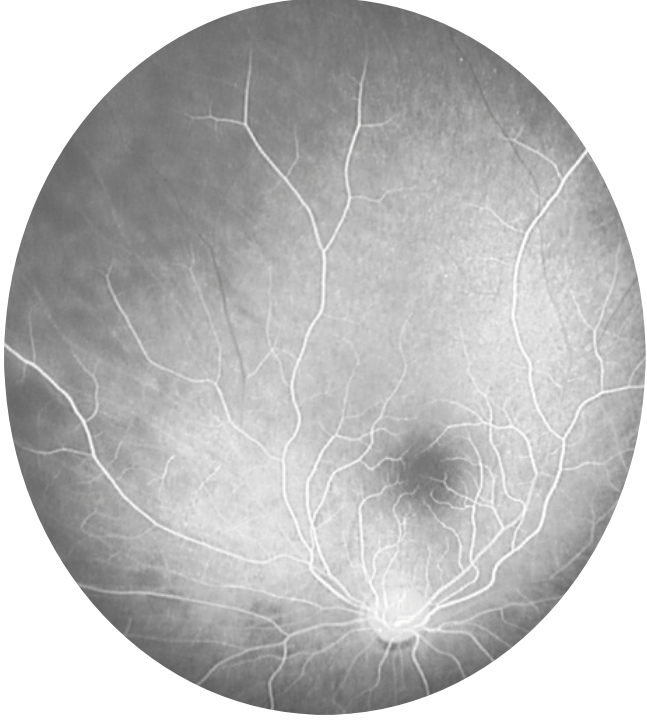
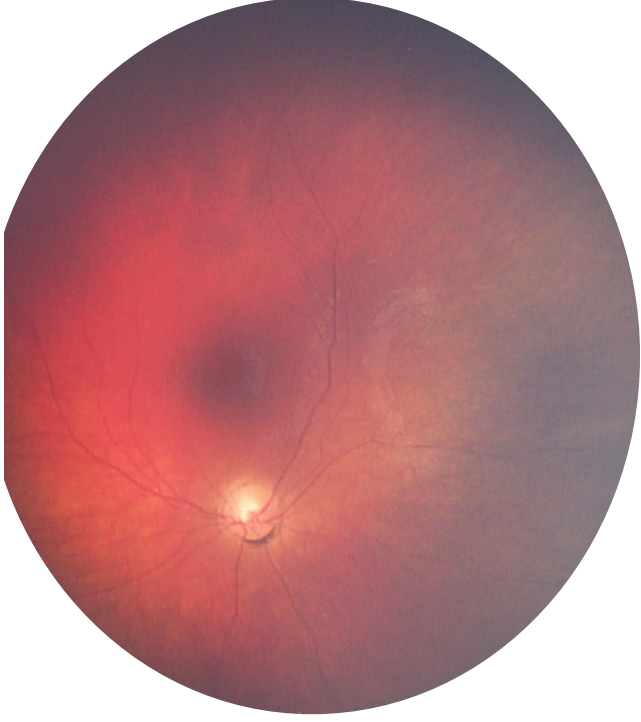
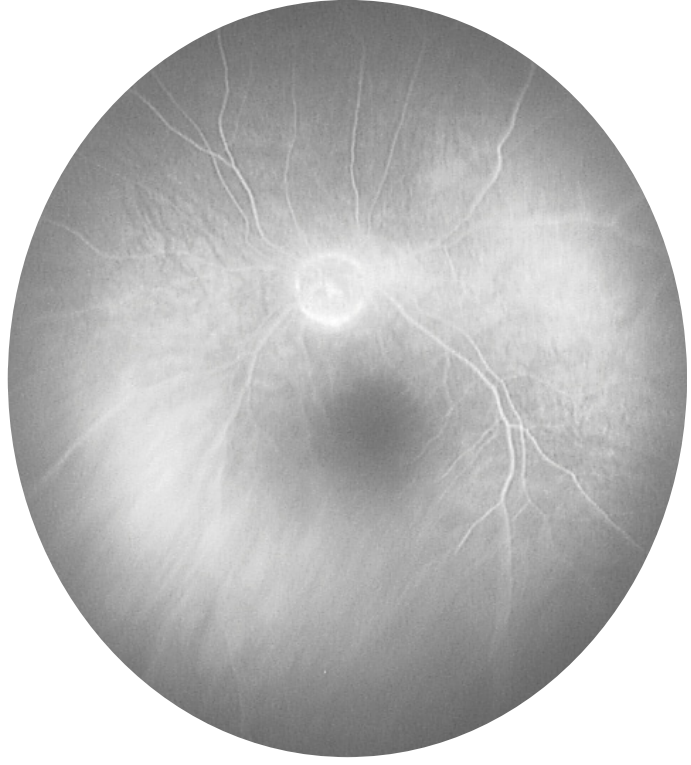
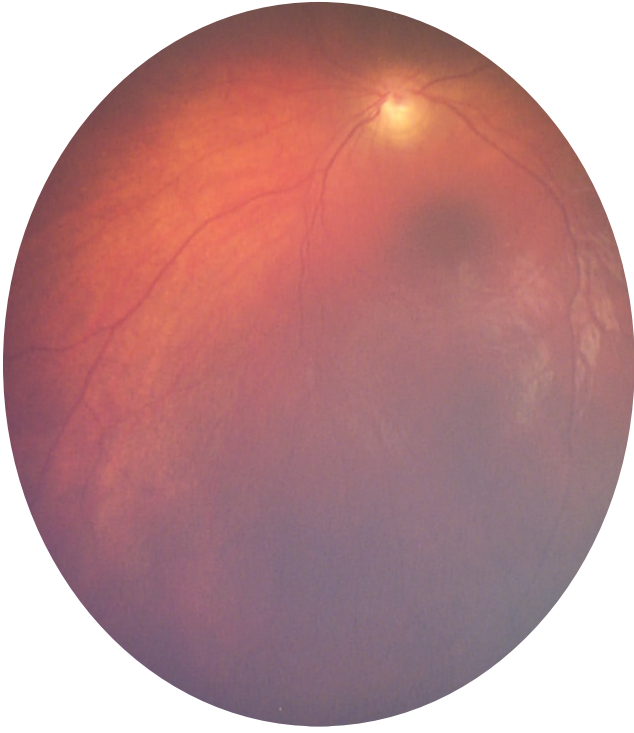
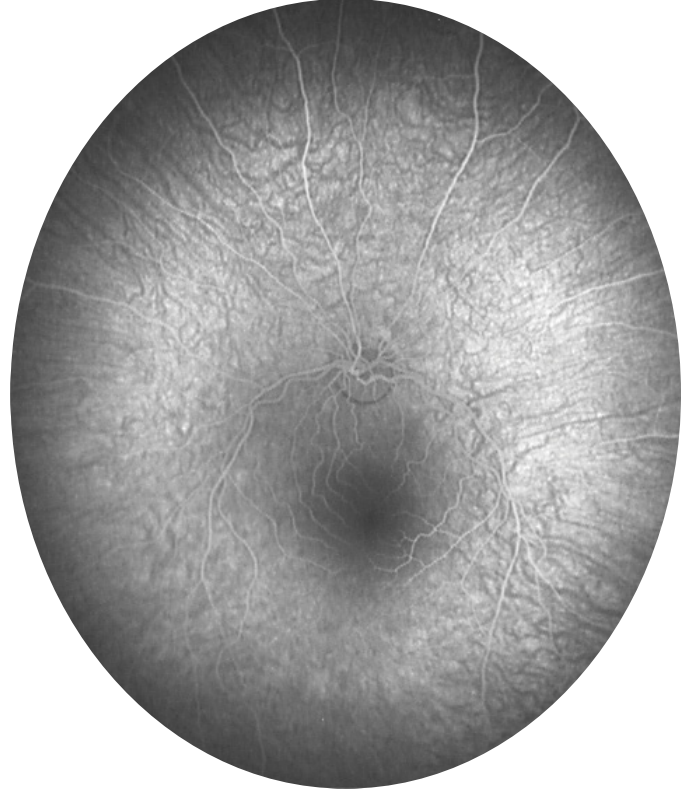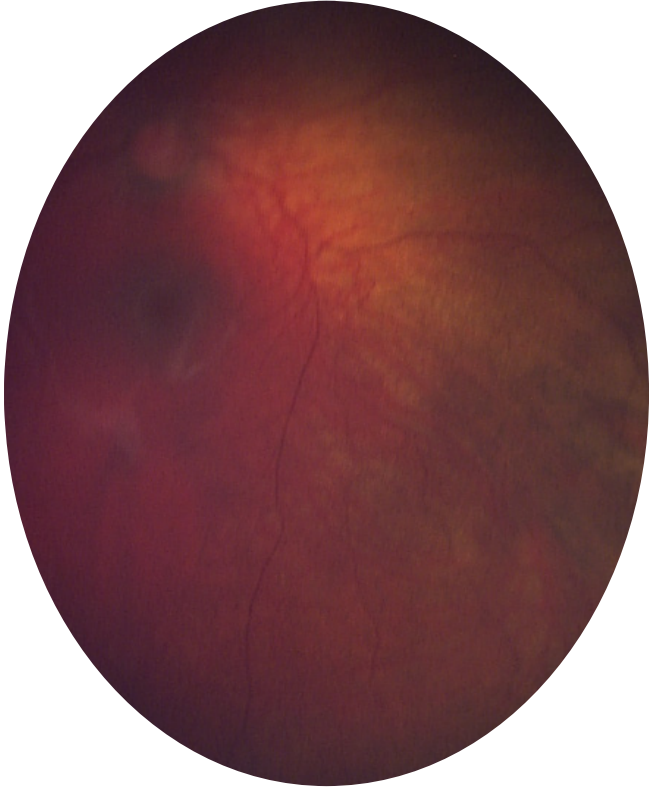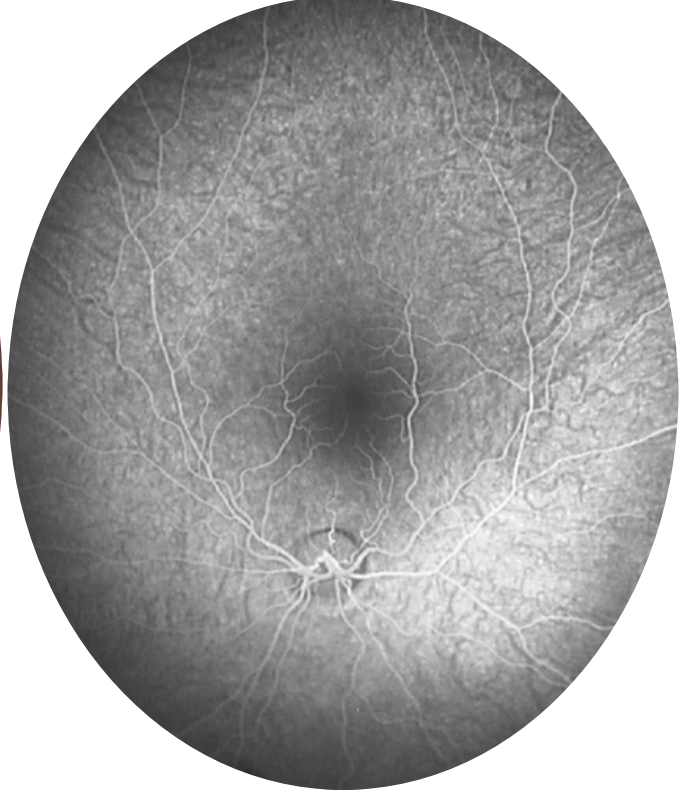


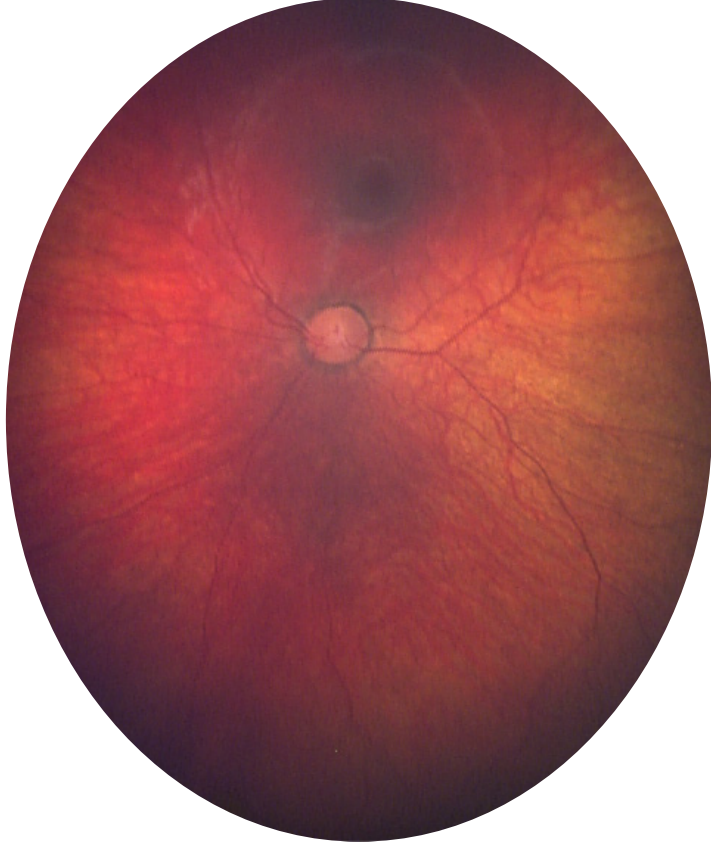Supplemental Figure Legend. Representative images from the 50 eyes of the 25 patients with LINCL. Patients 1, 2, 5 and 21 – 25 underwent dilated fundus photography and FA; Patients 3 and 6 had dilated fundus photography, FA and SD-OCT; Patients 4, 7 – 20 underwent the most comprehensive evaluation with dilated color photography, FA, ICGA and SD-OCT. FA – fluorescein angiogram, ICGA - indocyanine green angiogram, SD-OCT – spectral domain optical coherence tomography.

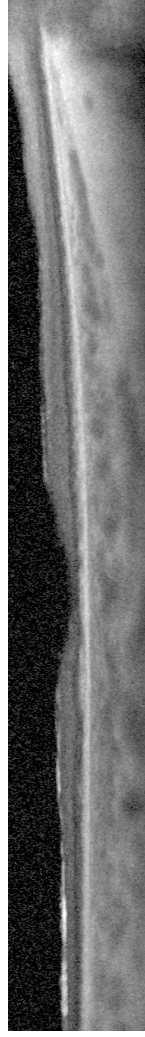
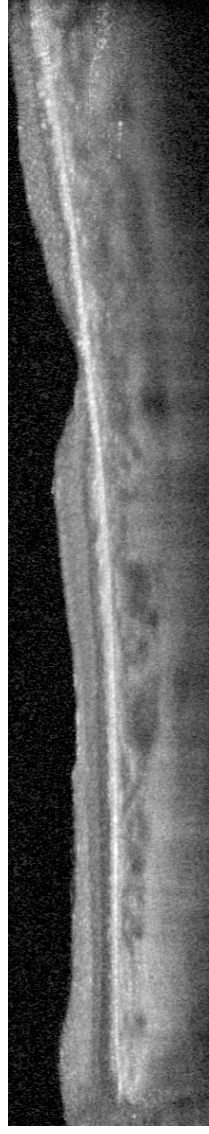
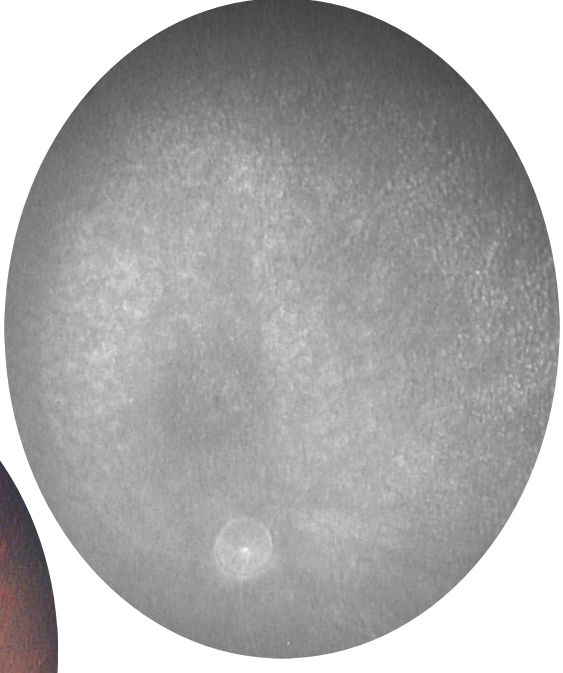
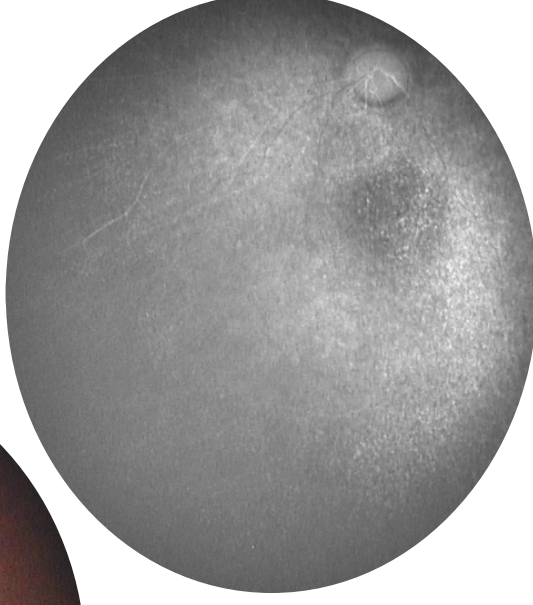
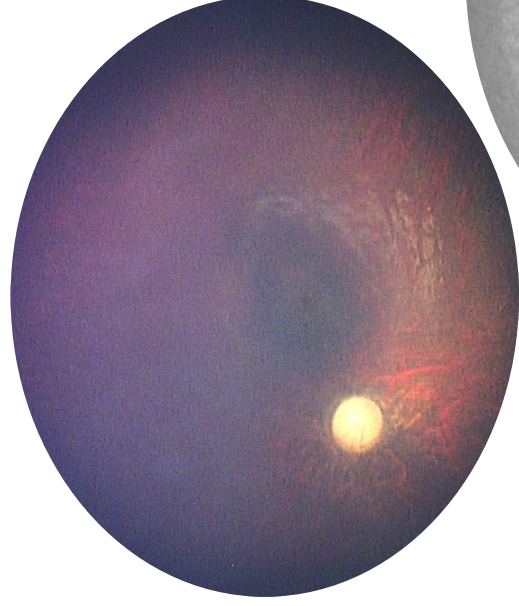
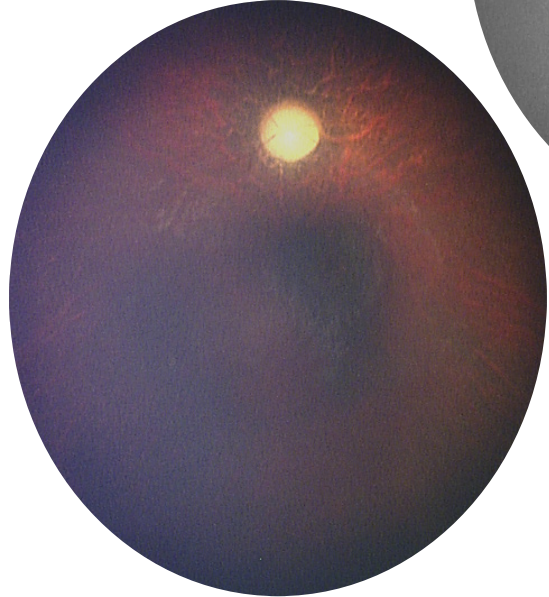
Subject 1 – BDrh-01-IW – Color, FA



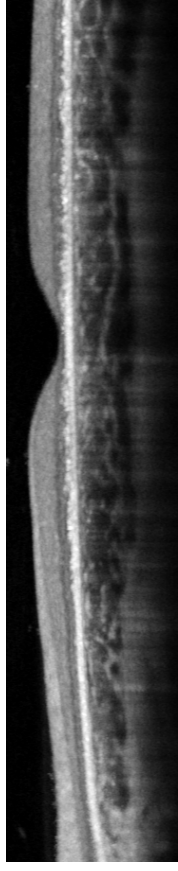
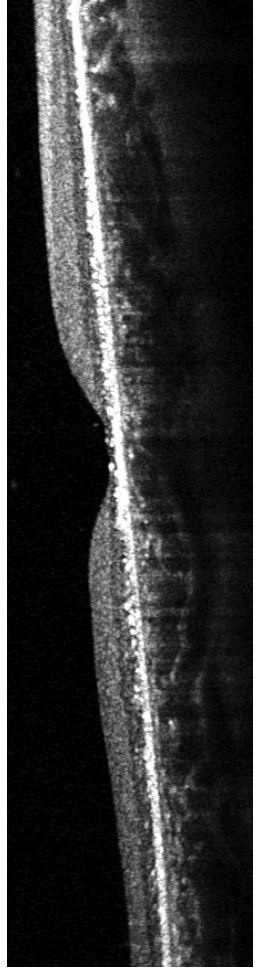
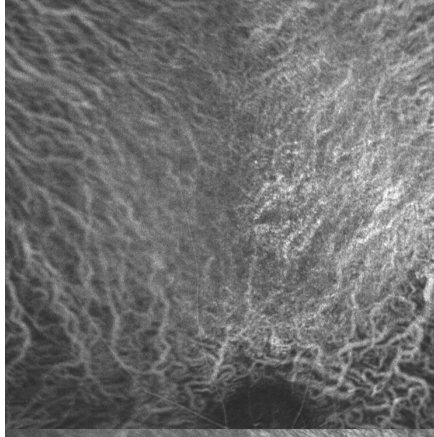
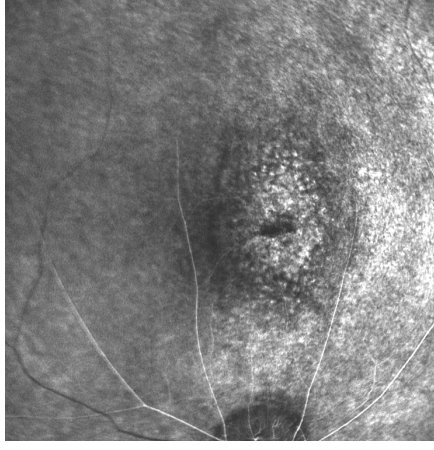
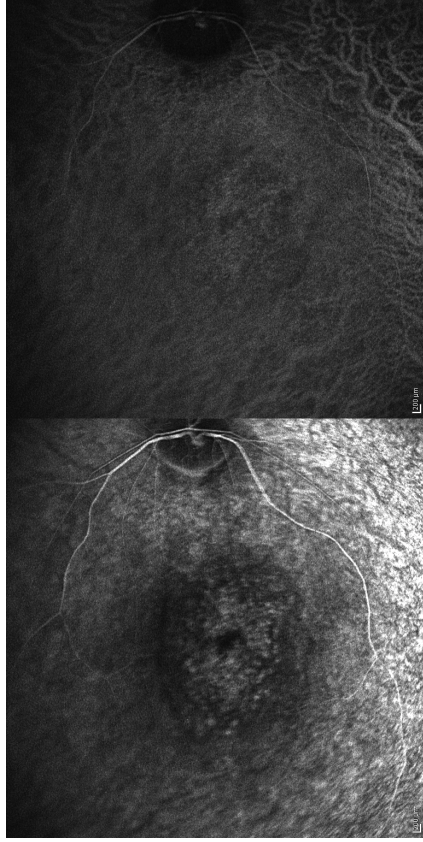
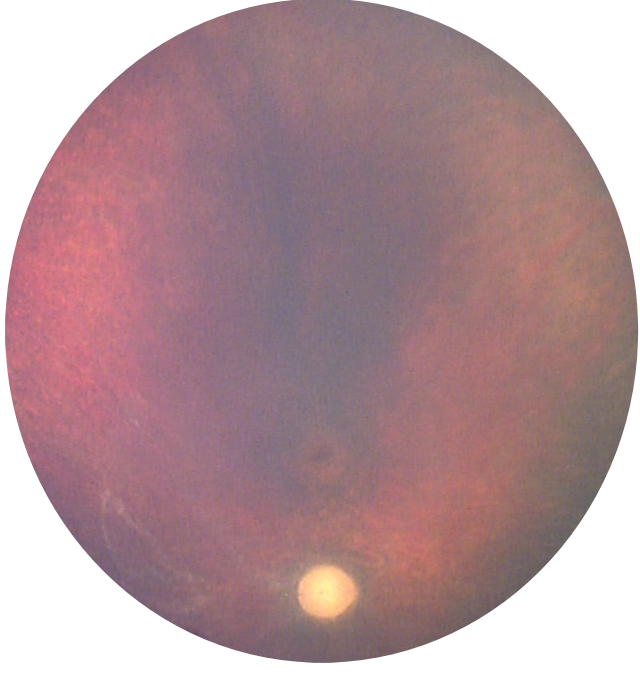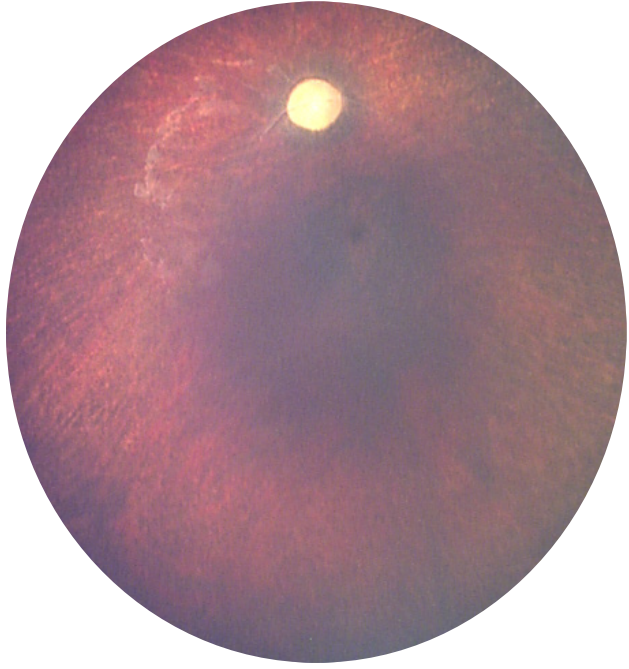
Subject 2 – BDrh-02-IN – Color, FA



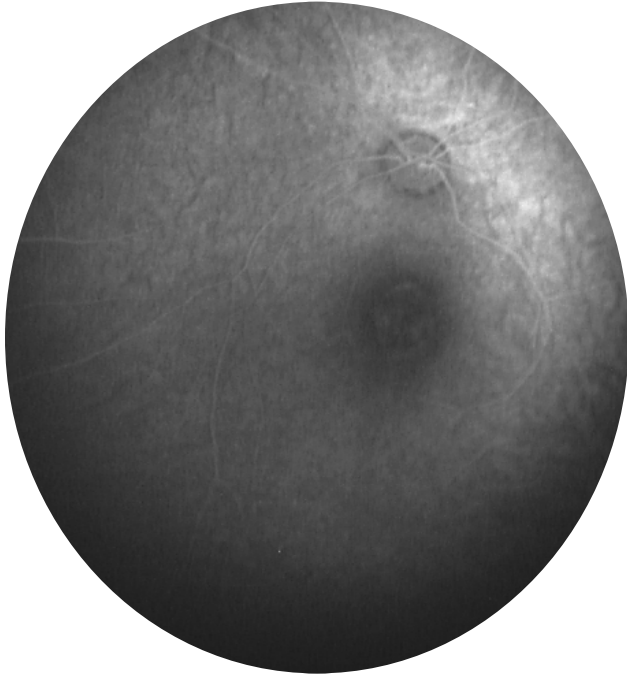
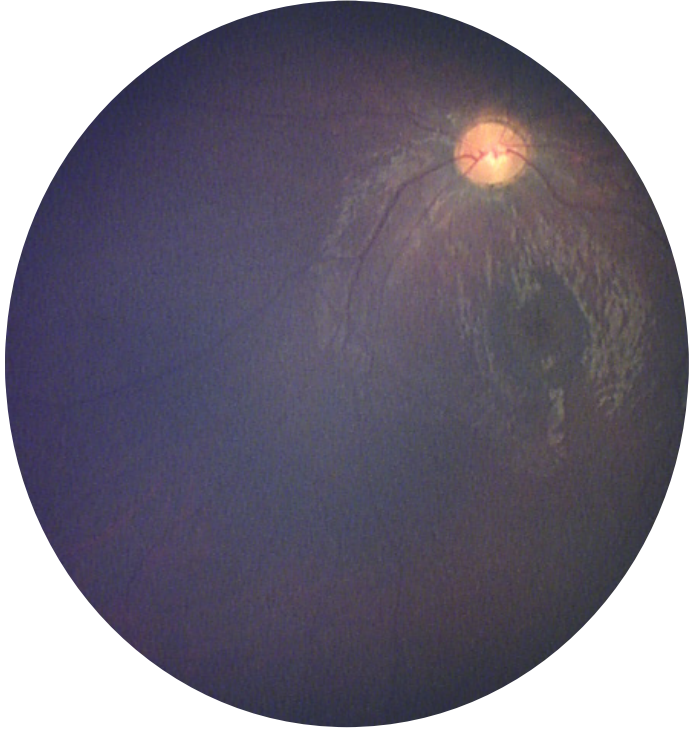
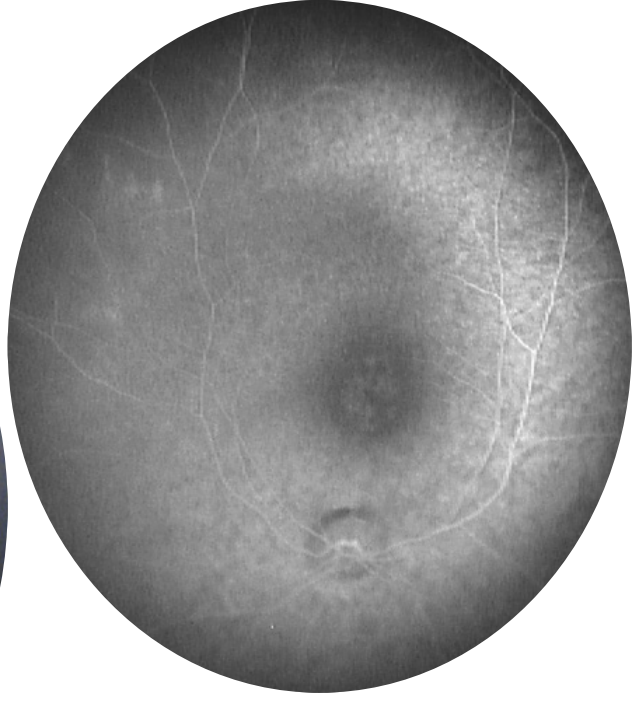
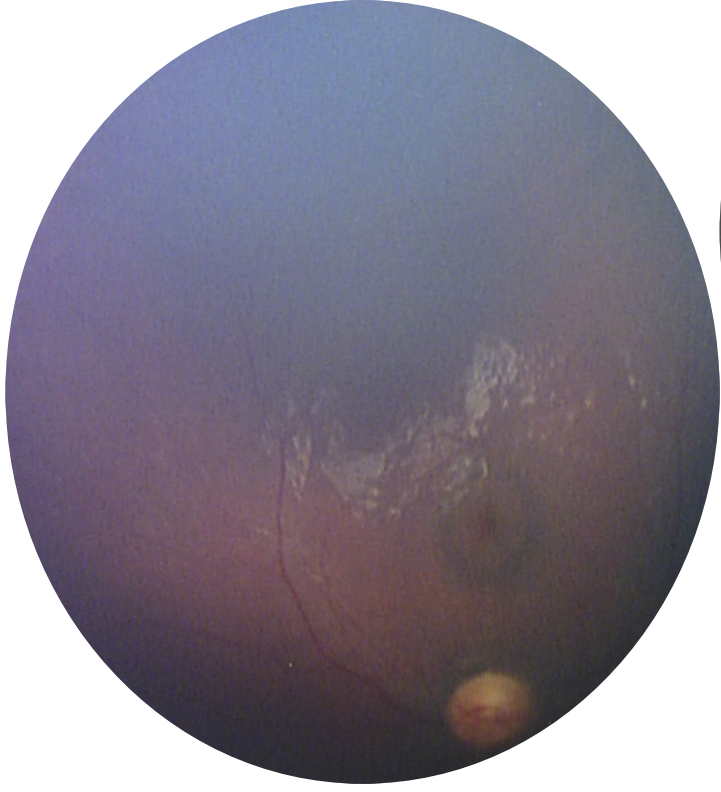
Subject 3 – BDrh-03-CI – Color, FA, OCT



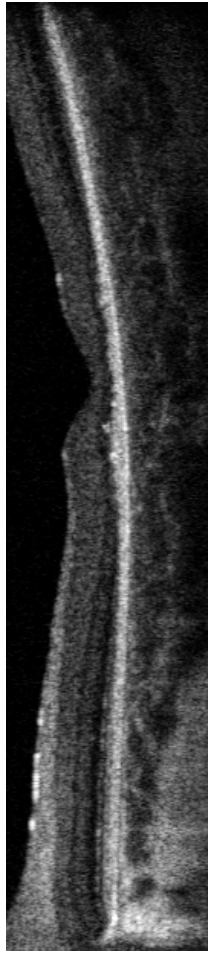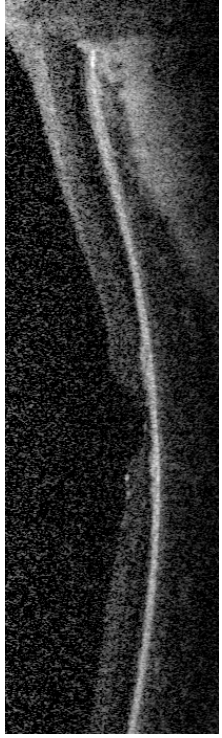
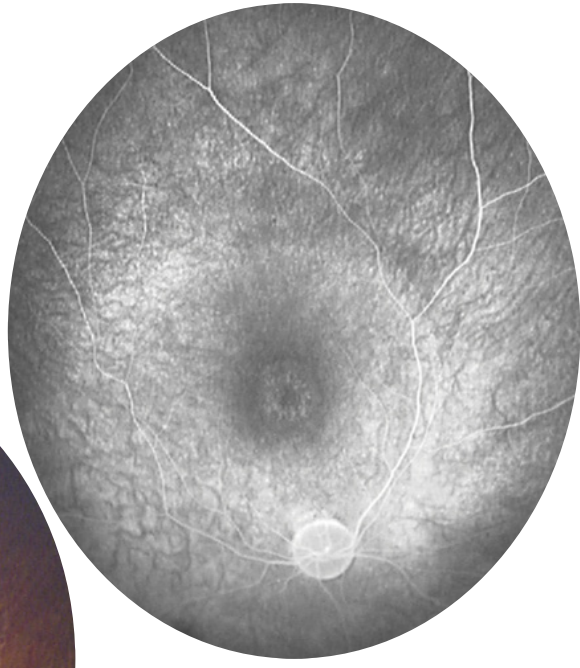
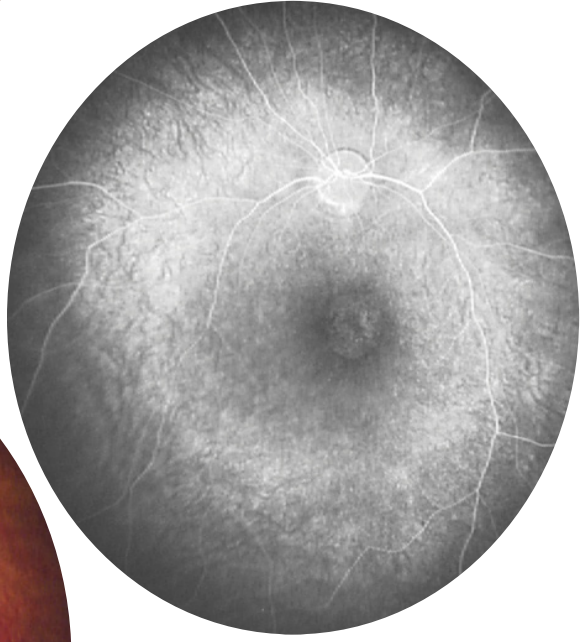
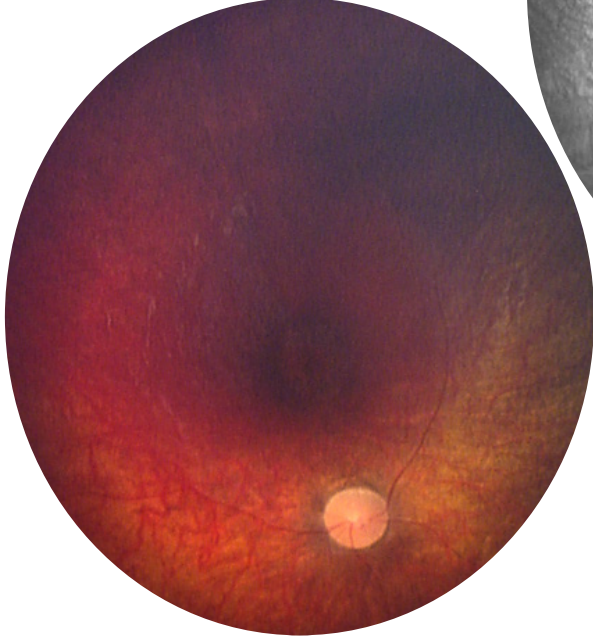
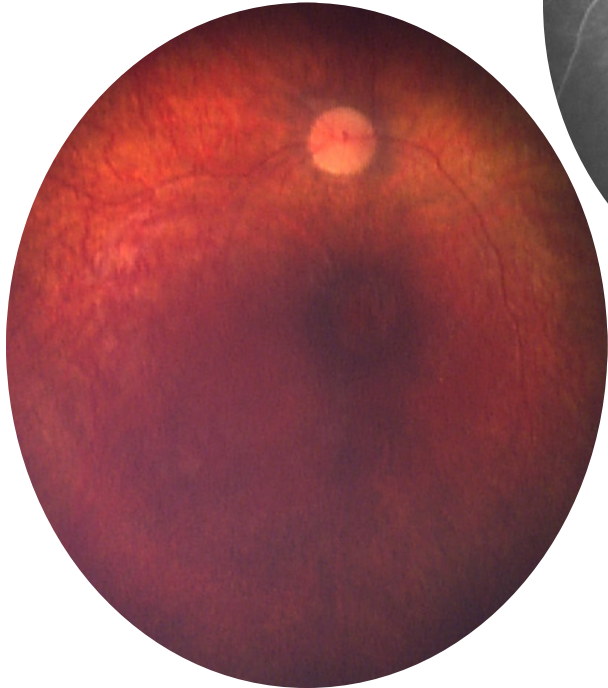
Subject 4 – BDrh-04-SI – Color, FA/ICGA, OCT



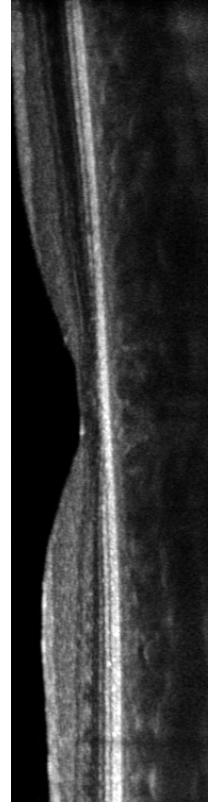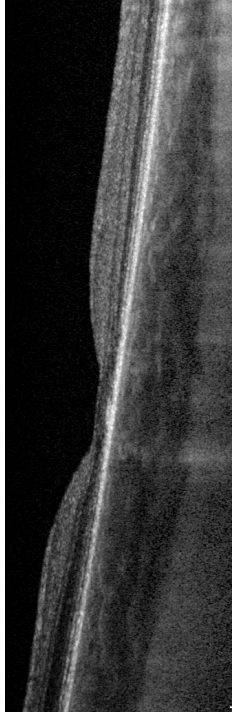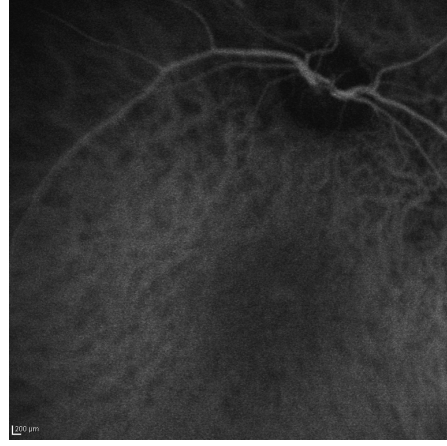
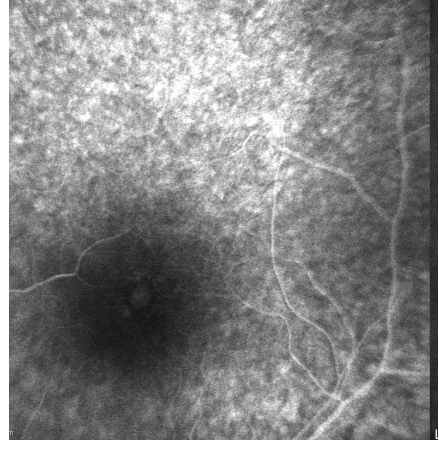
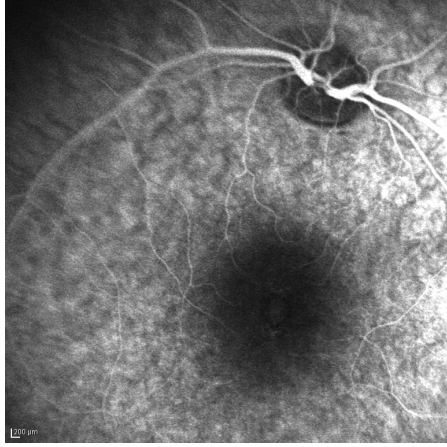
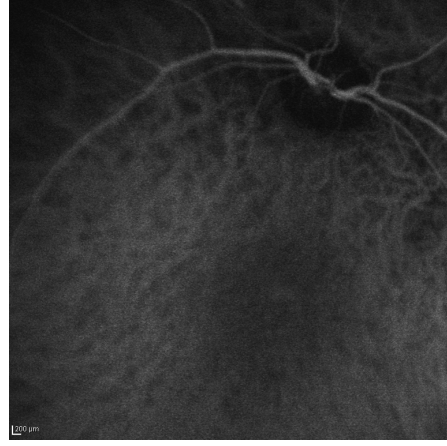
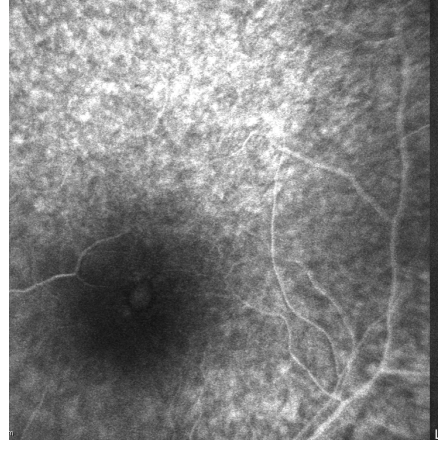
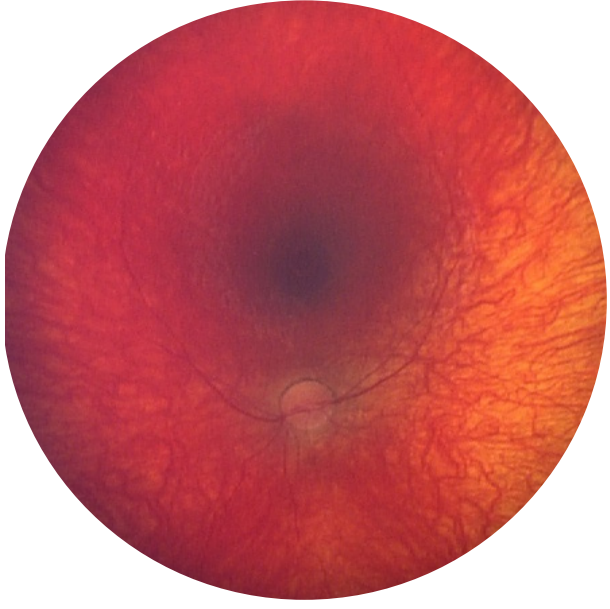Subject 5 – BDrh-05-CR – Color, FA



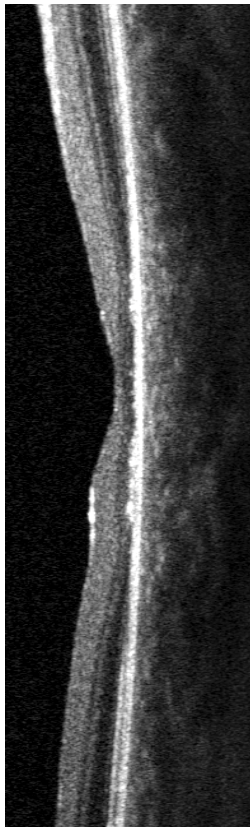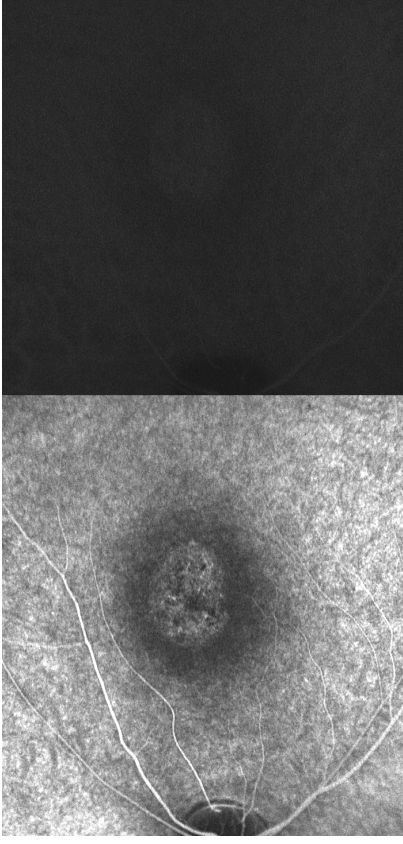
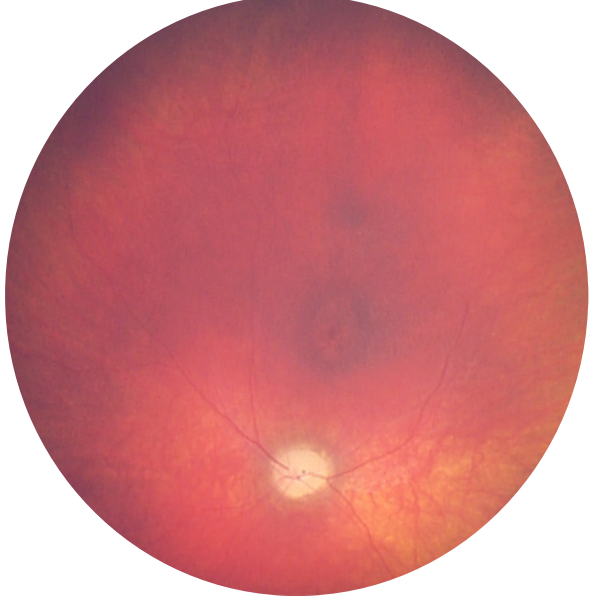
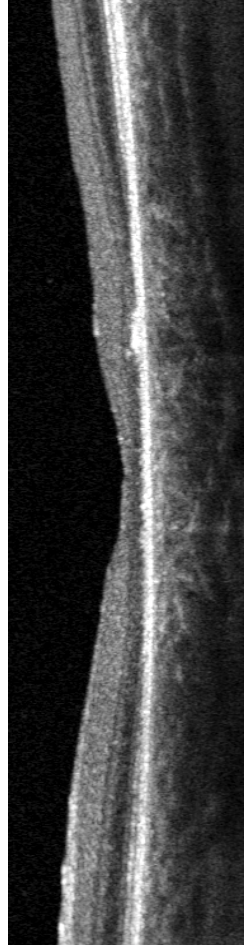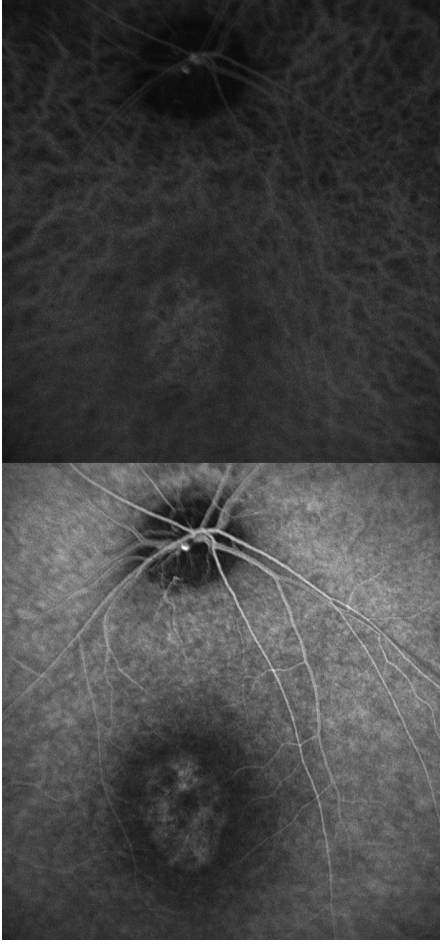
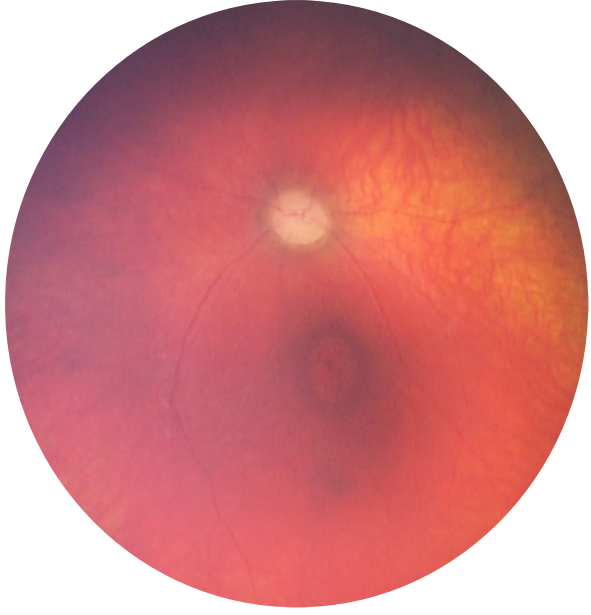
Subject 6 – BDrh-06-CF – Color, FA



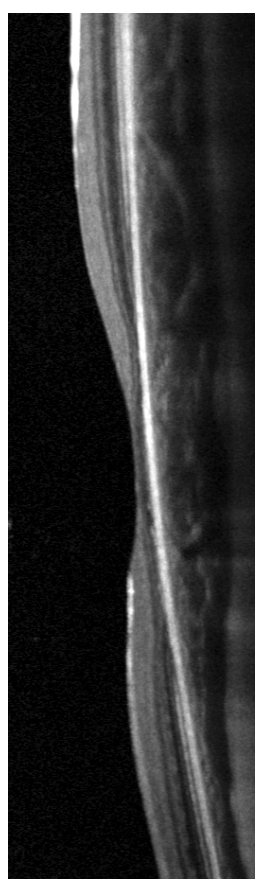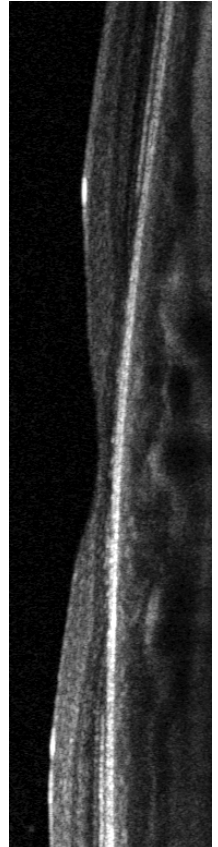
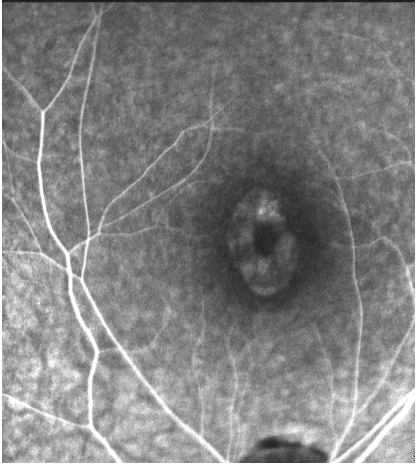
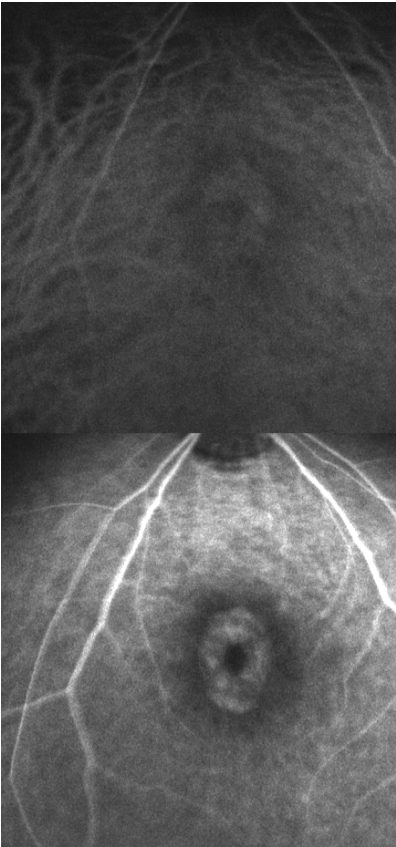
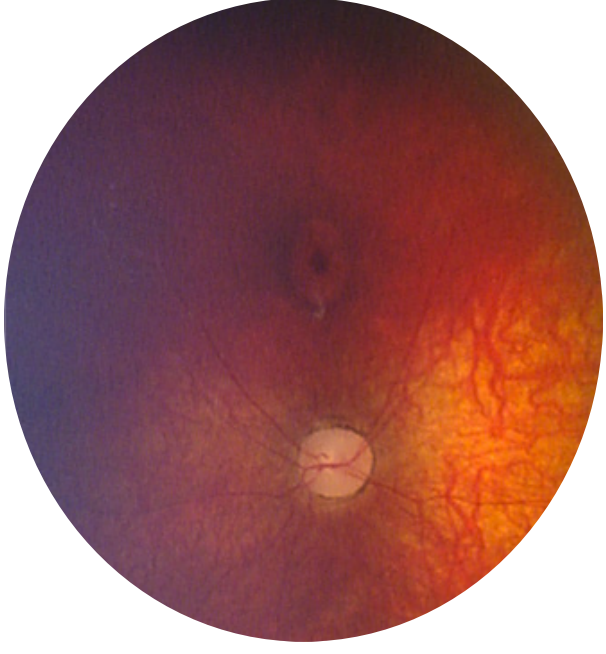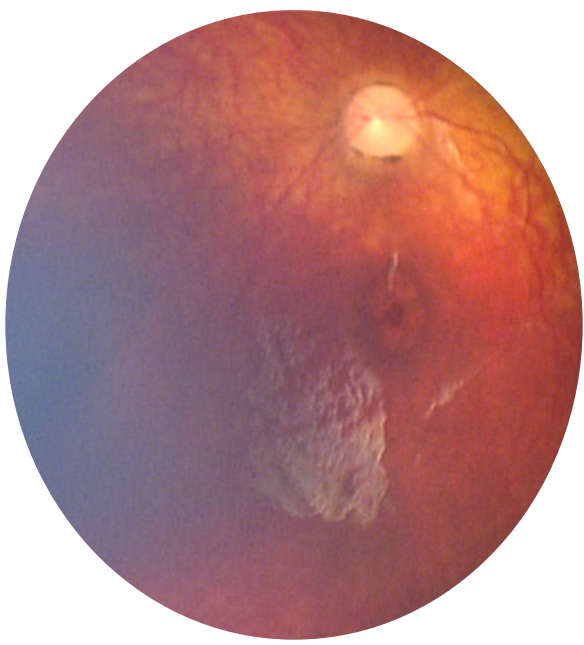
Subject 7 – BDrh-07-OF – Color, FA, ICGA, OCT



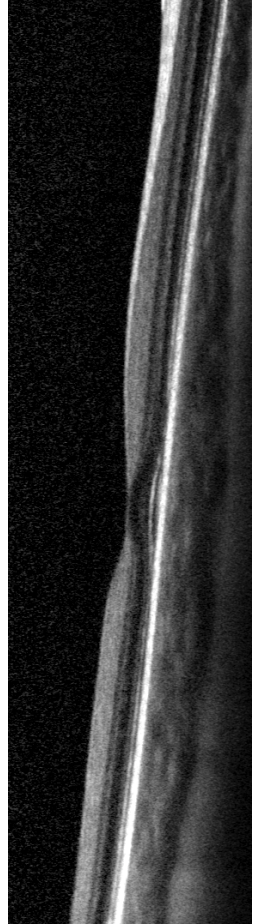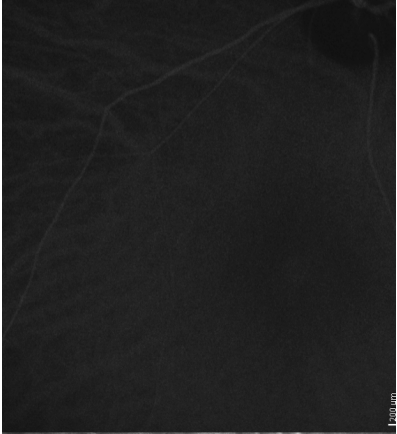
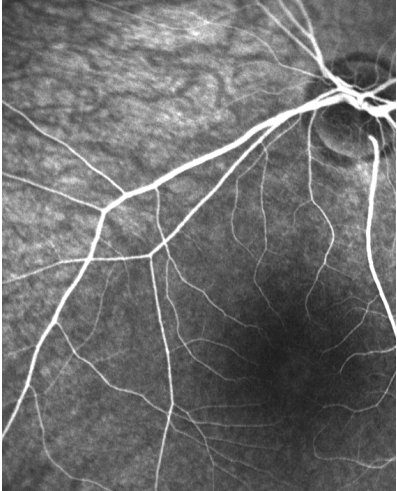
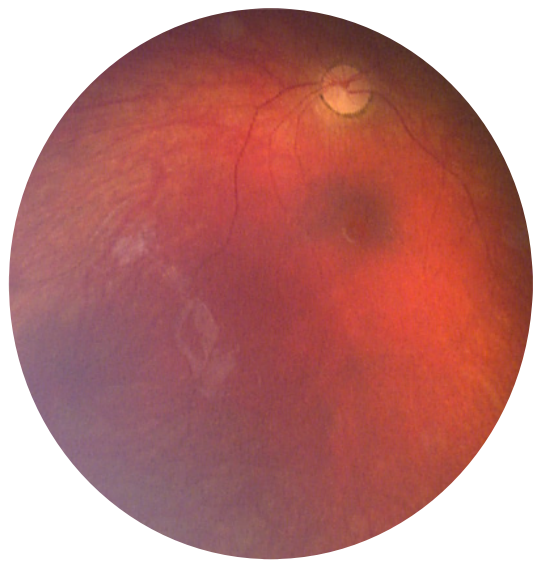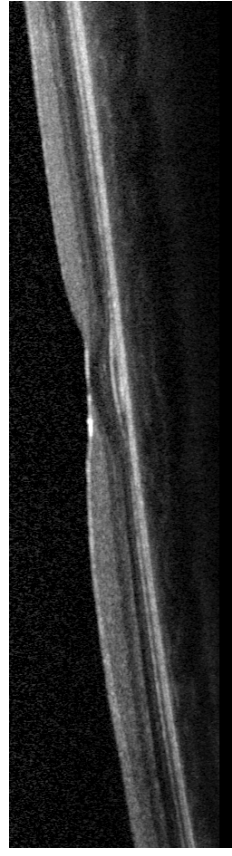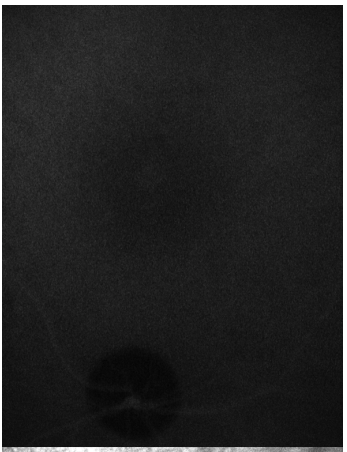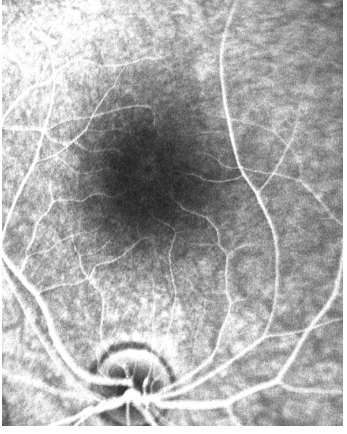
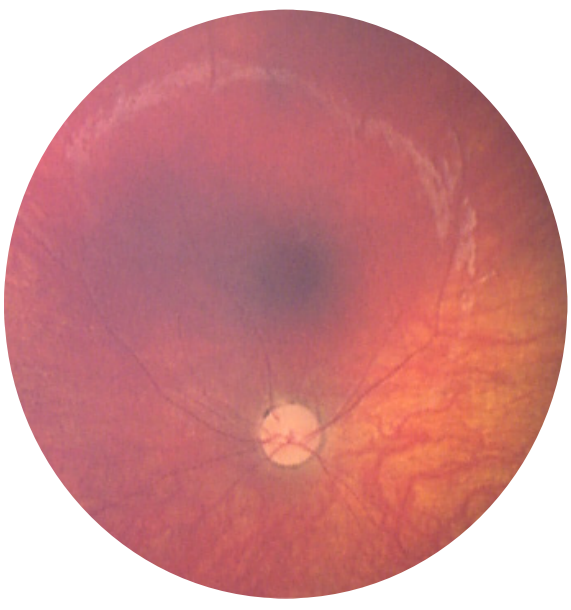Subject 8 – BDrh-09-FM – Color, FA, ICGA, OCT



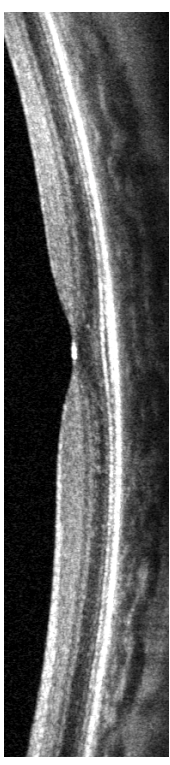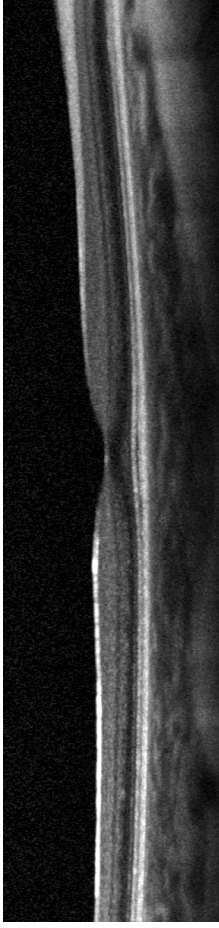
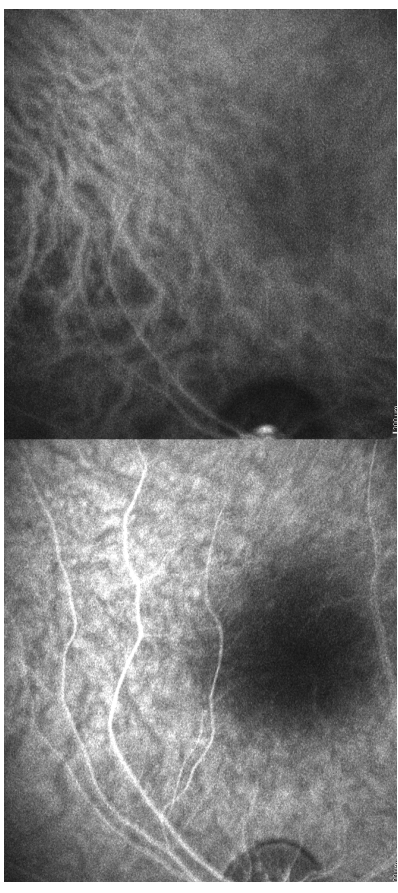
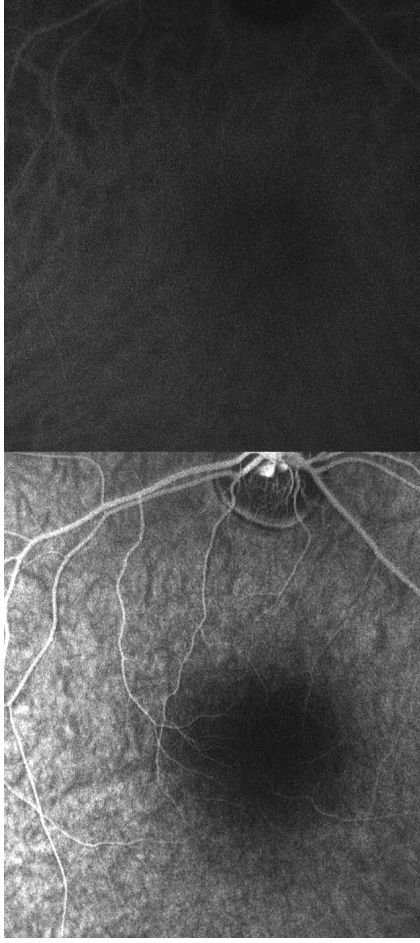
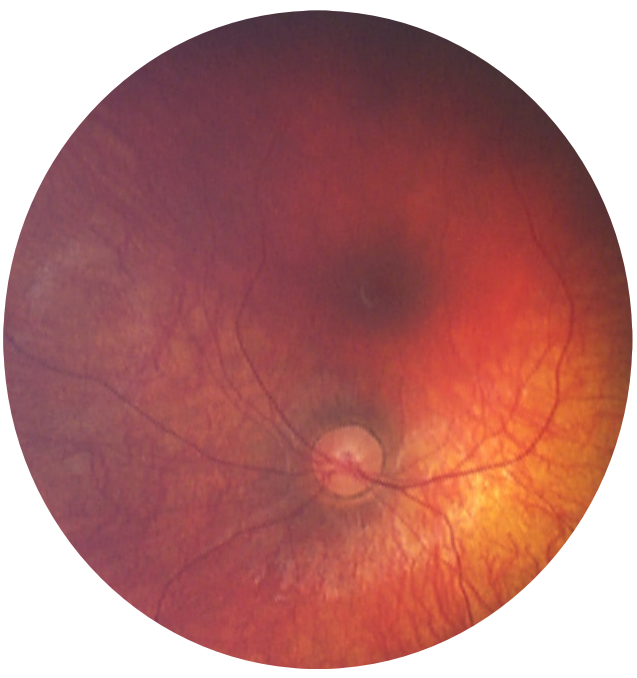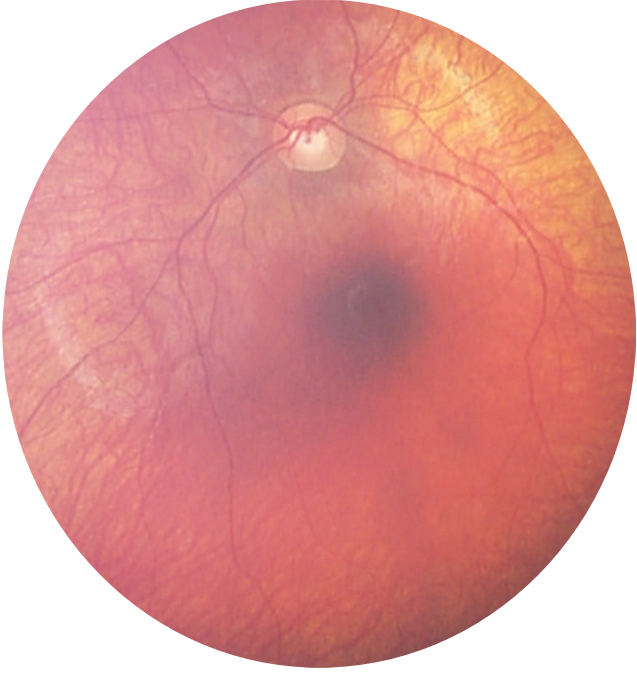Subject 9 – BDrh-10-SO – Color, FA, ICGA, OCT



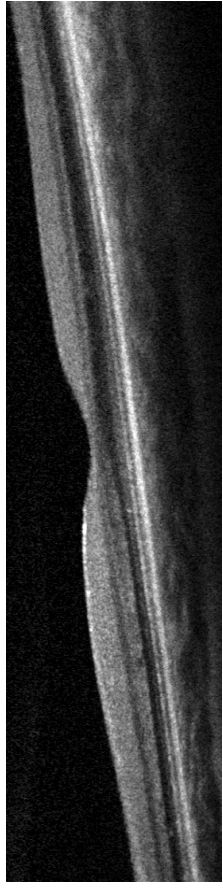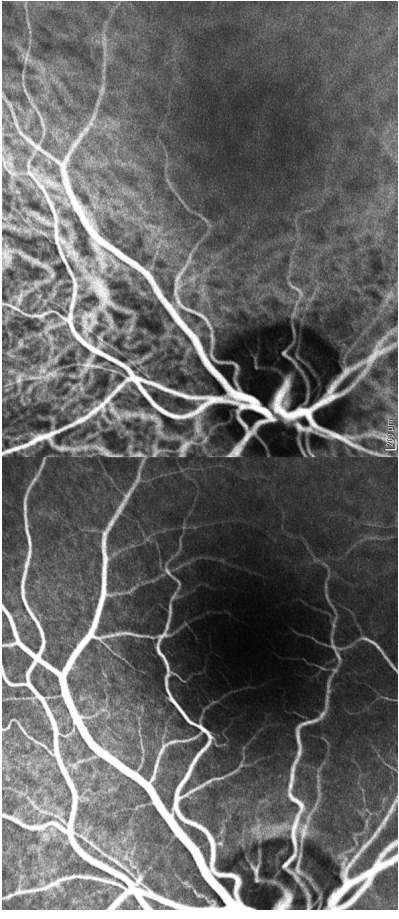
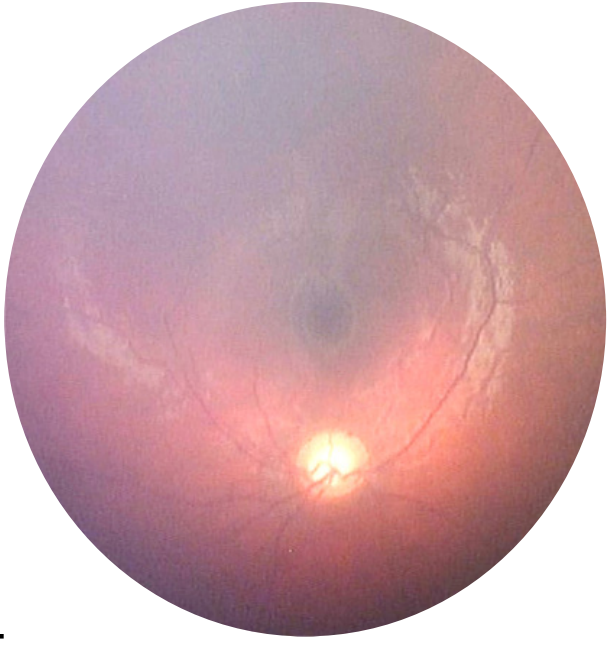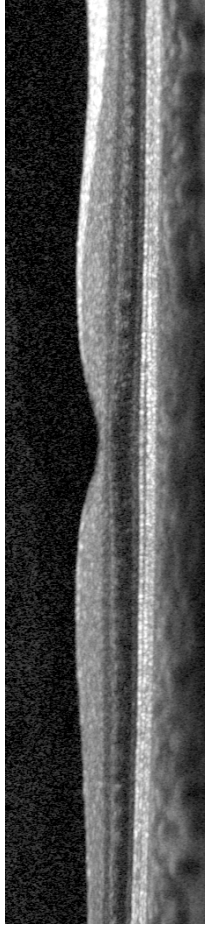
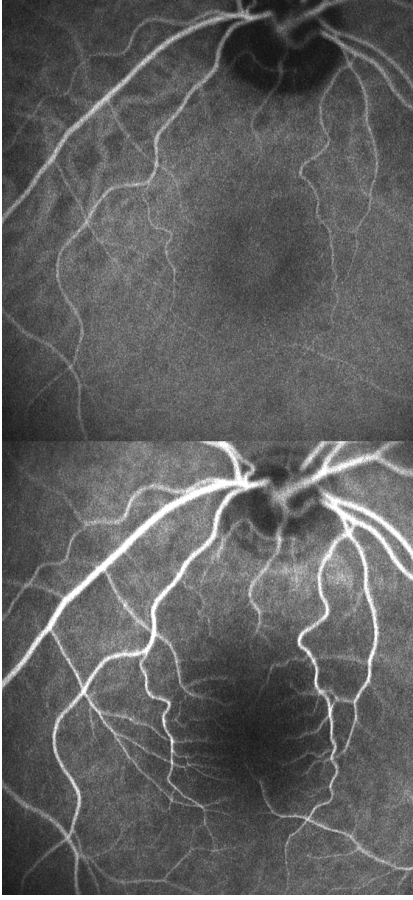
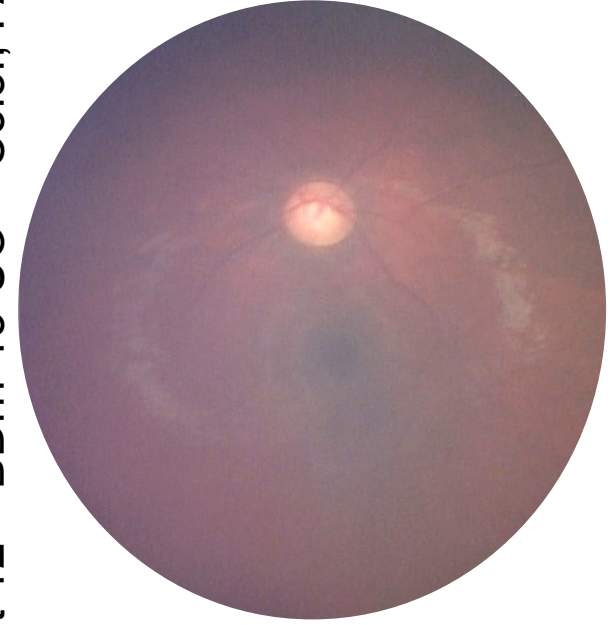
Subject 10 – BDrh-11-UC – Color, FA, ICGA, OCT



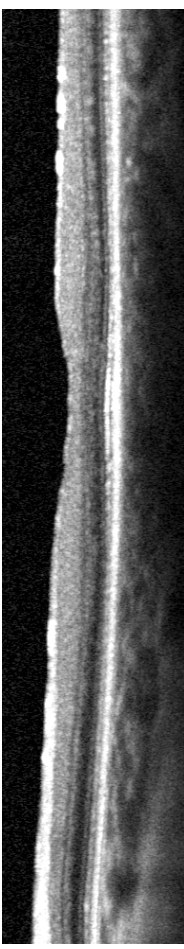
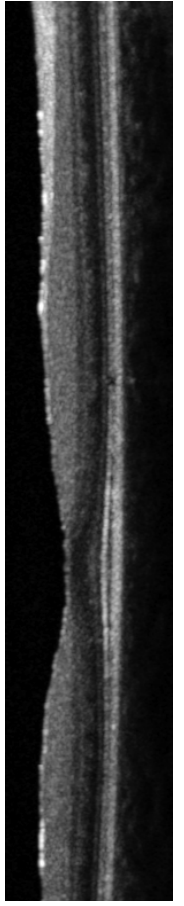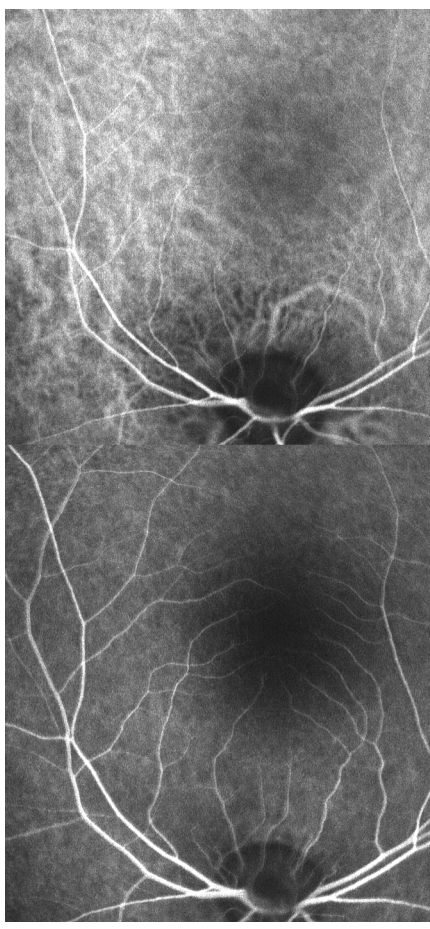
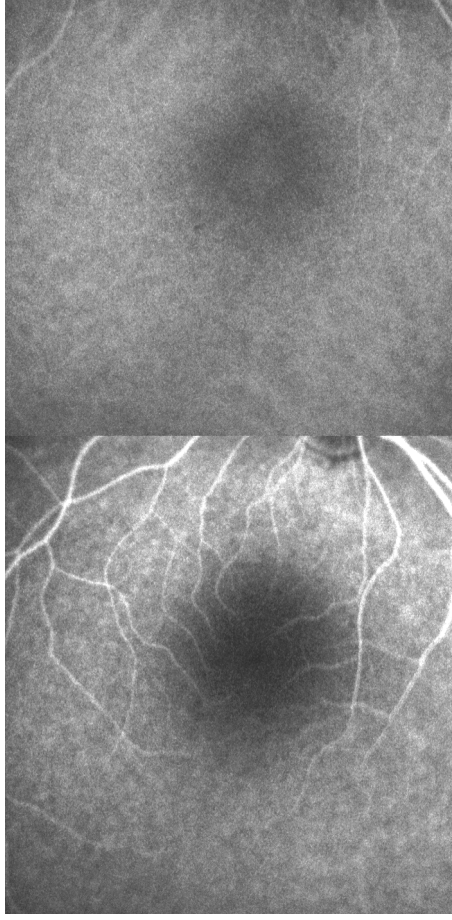
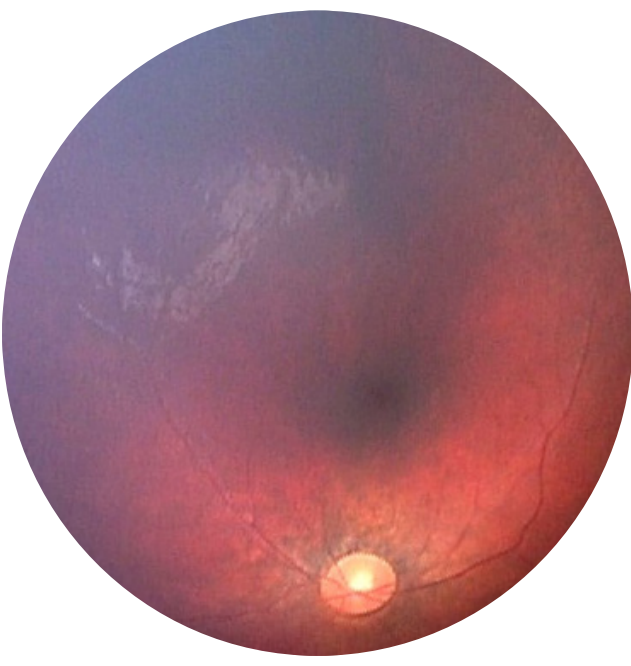
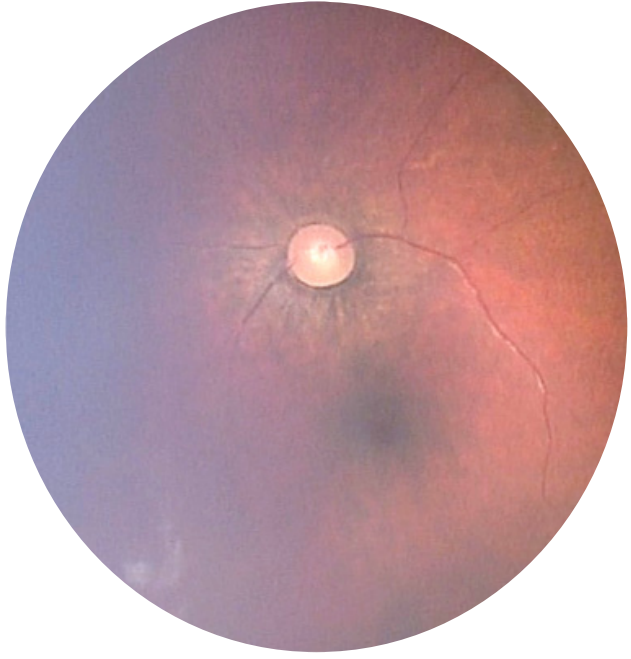
Subject 11 – BDrh-12-FB – Color, FA, ICGA, OCT



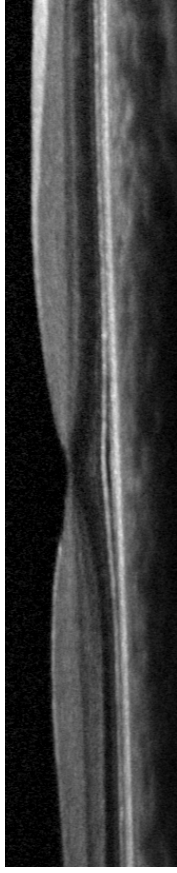
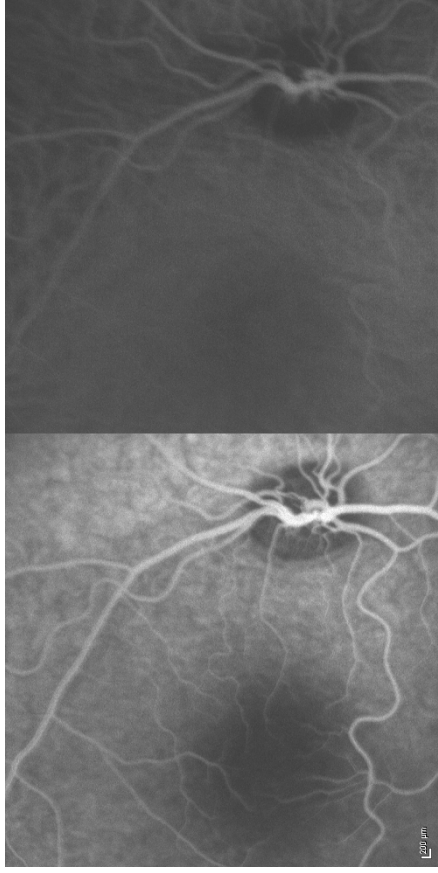
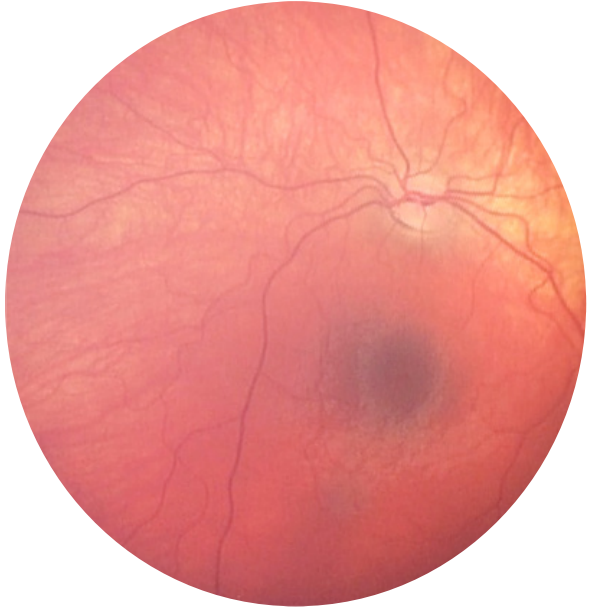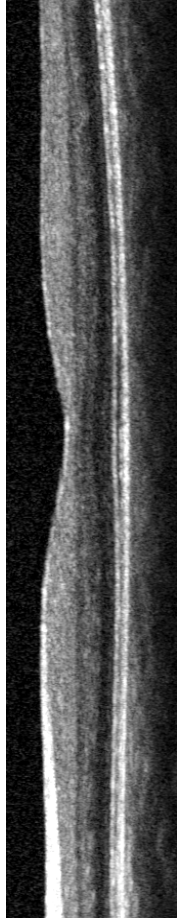
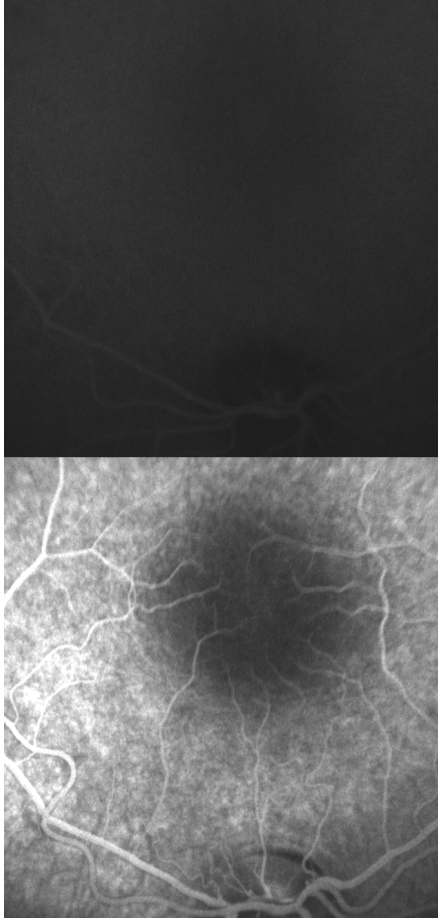
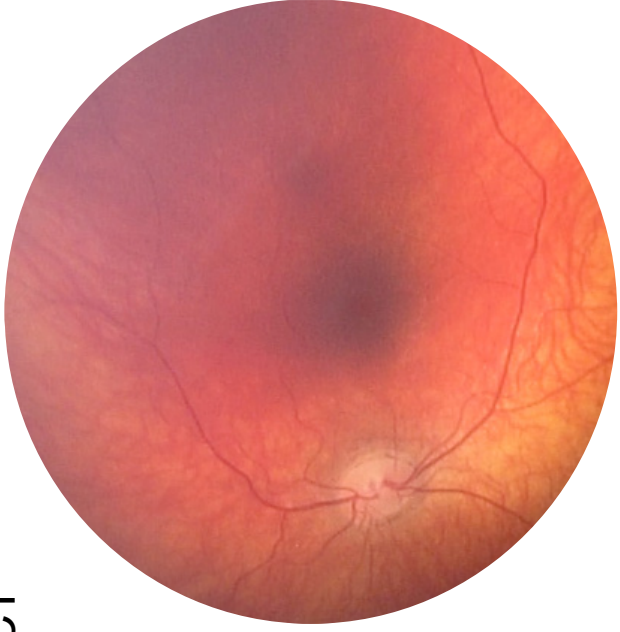Subject 12 – BDrh-13-UO – Color, FA, ICGA, OCT



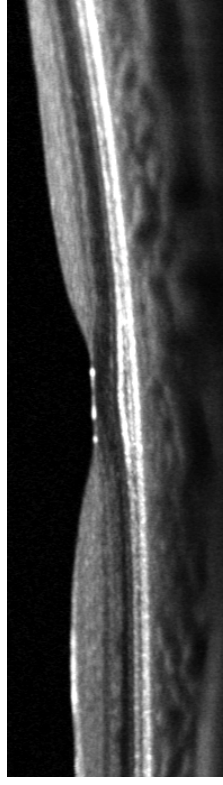
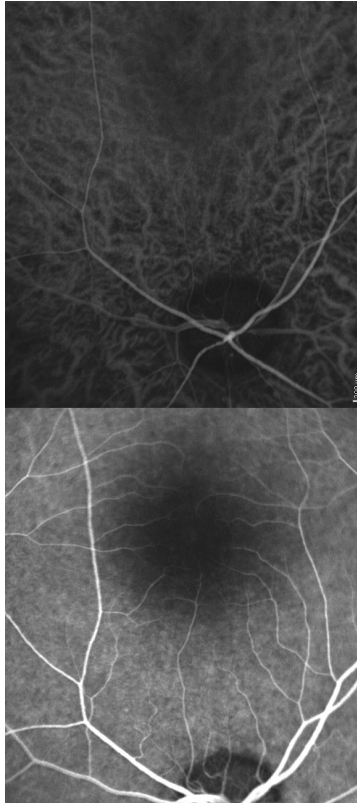
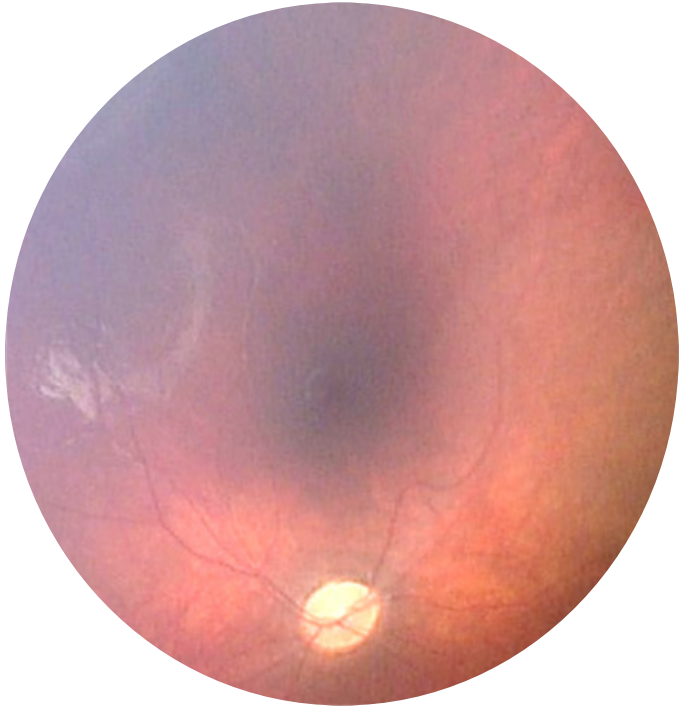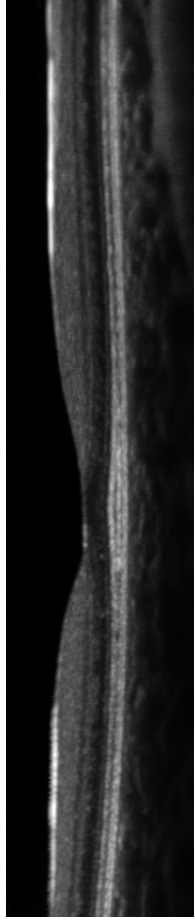
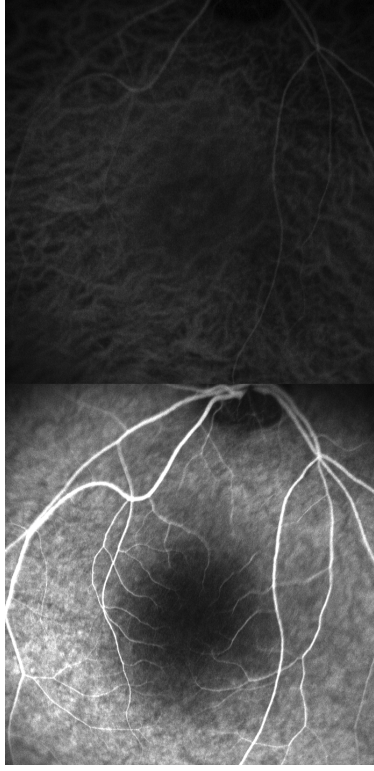
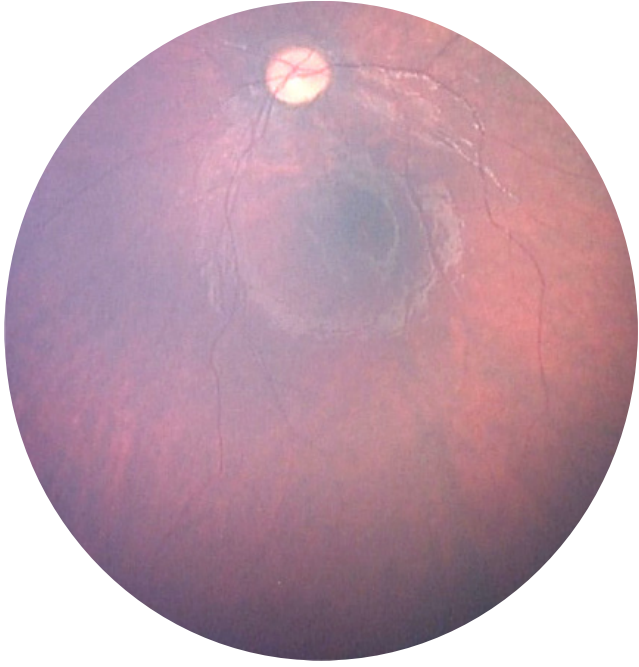
Subject 13 – BDrh-14-UC – Color, FA, ICGA, OCT



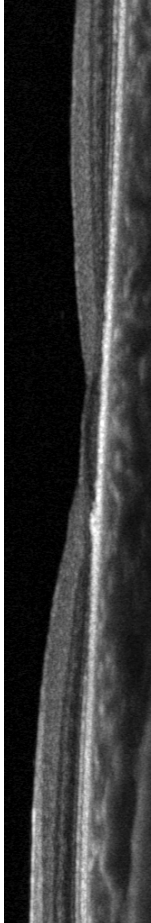
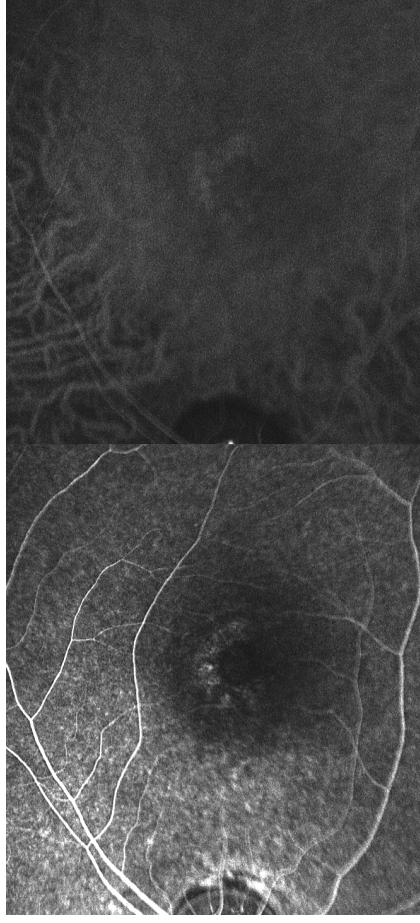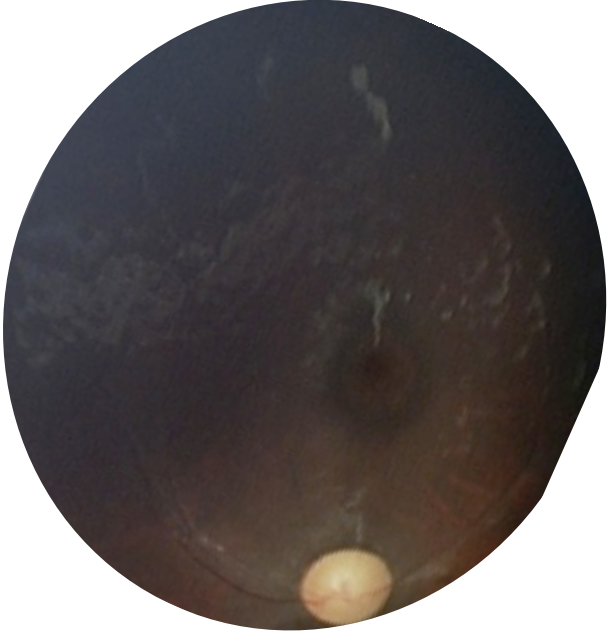
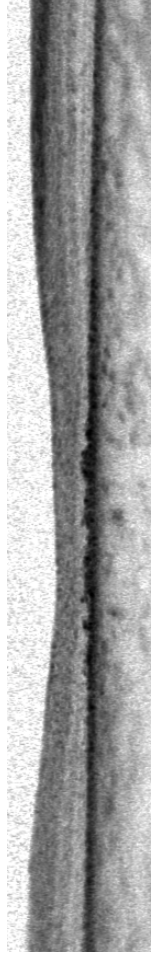
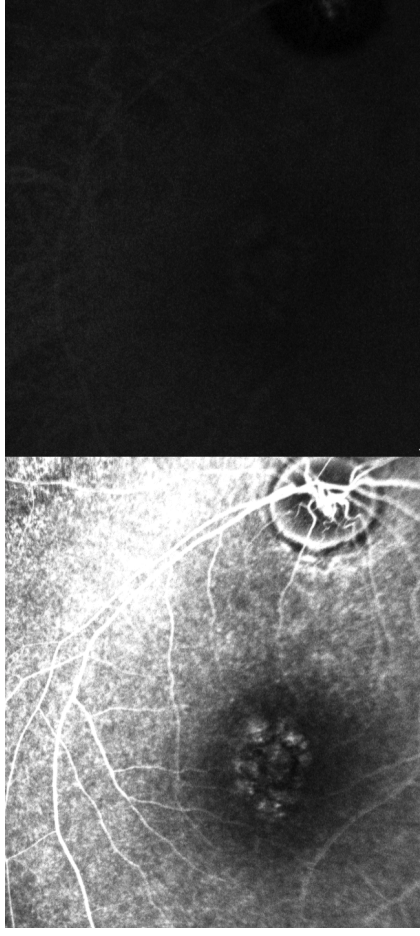
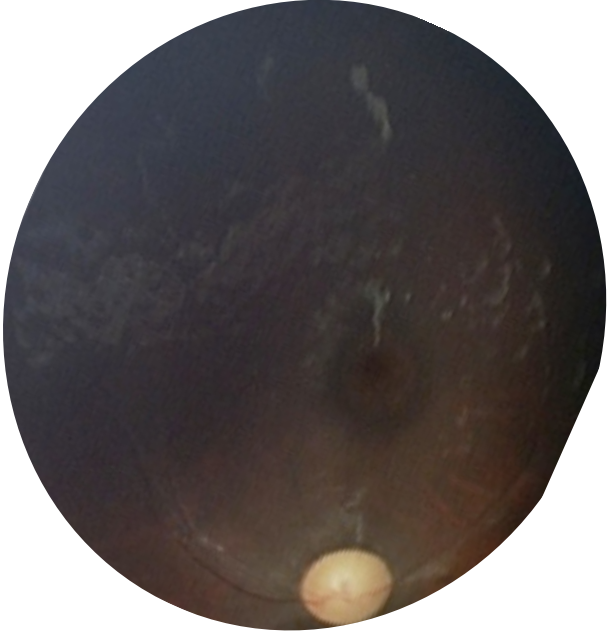
Subject 14 – BDrh-15-BG – Color, FA, ICGA, OCT



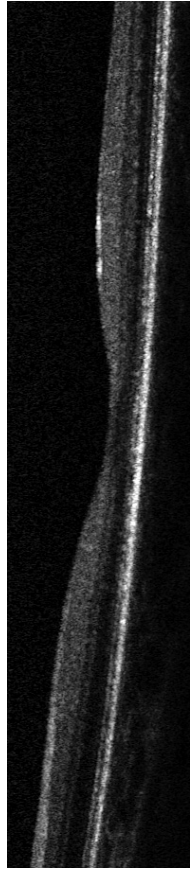
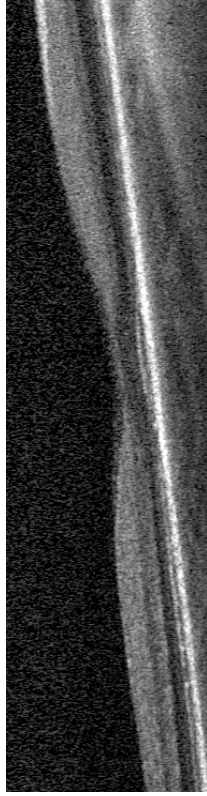
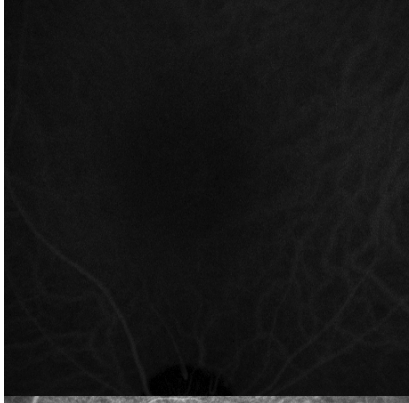
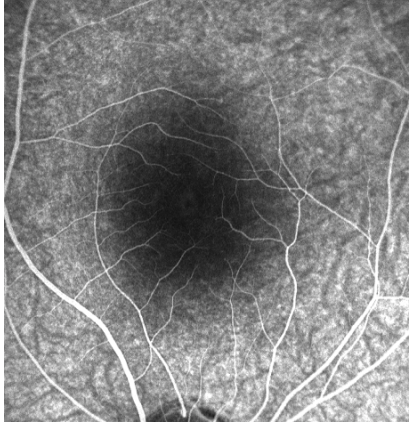
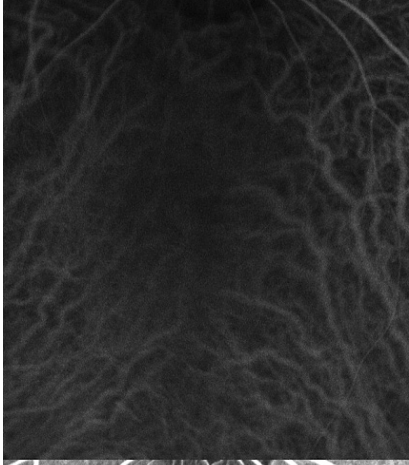
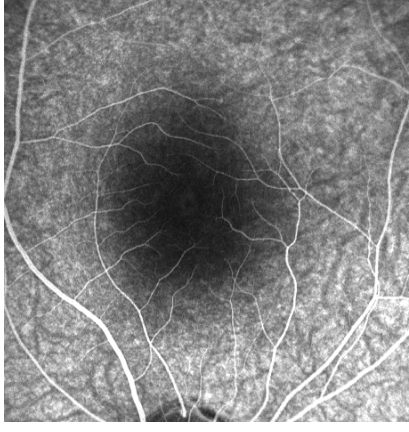
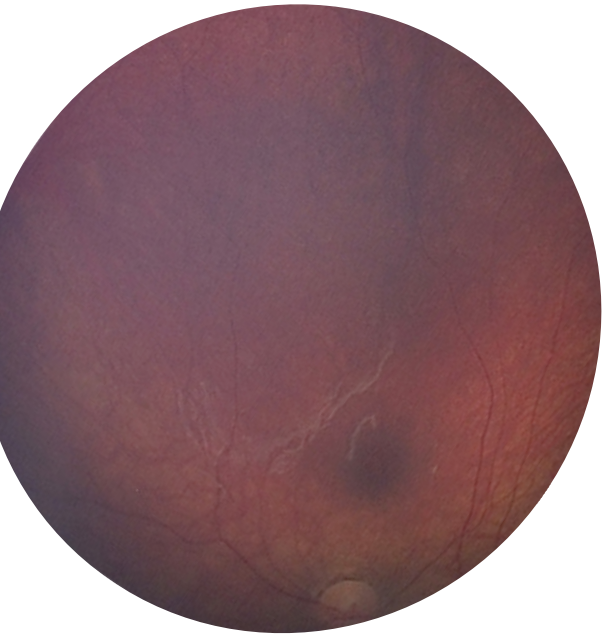
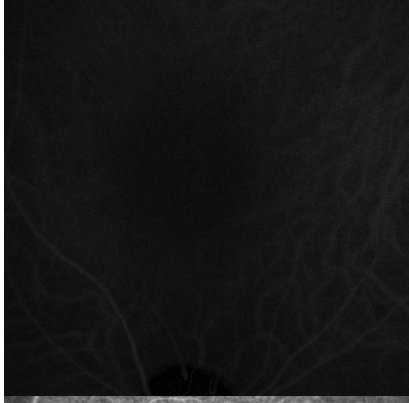
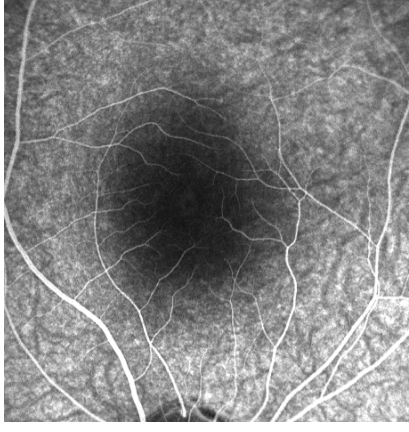
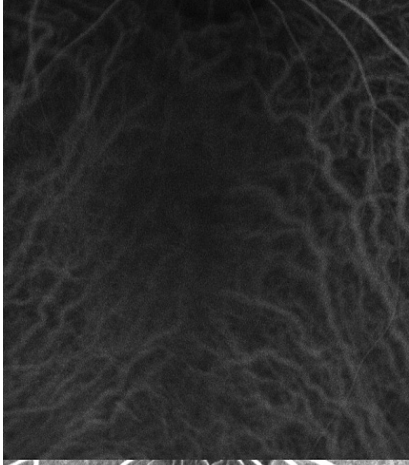
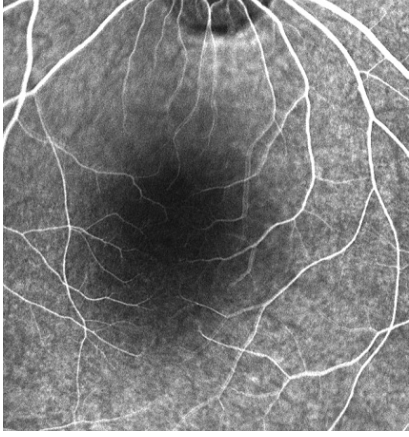
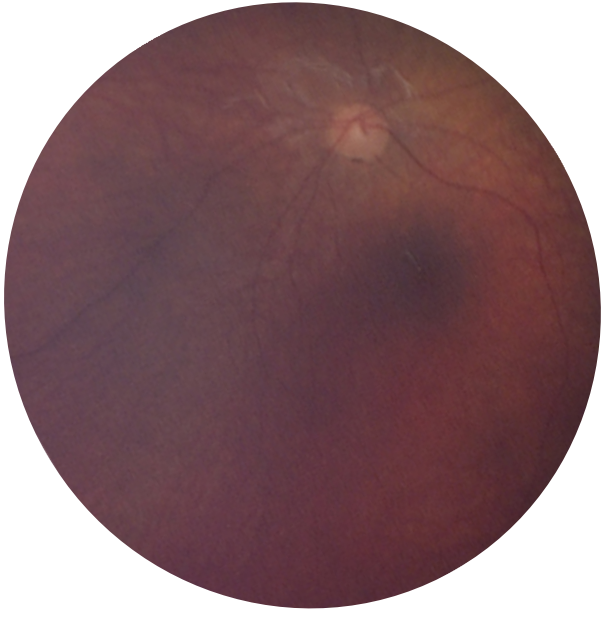
Subject 15 – BDrh-16-PS – Color, FA, ICGA, OCT



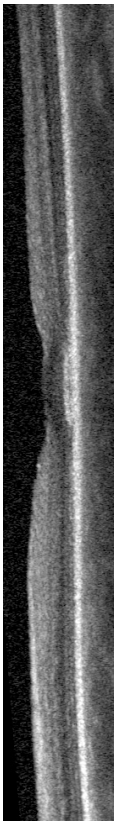
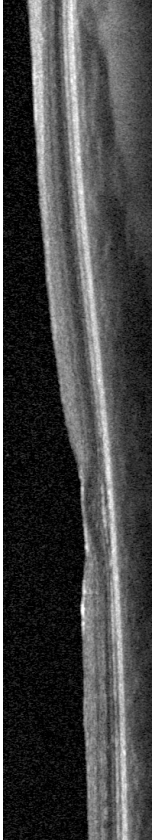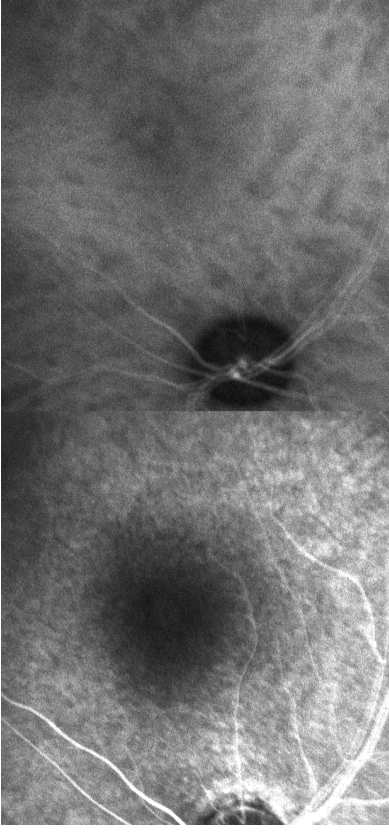
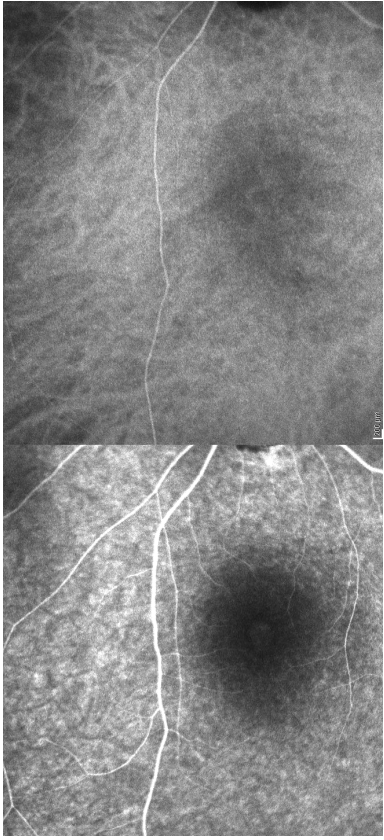
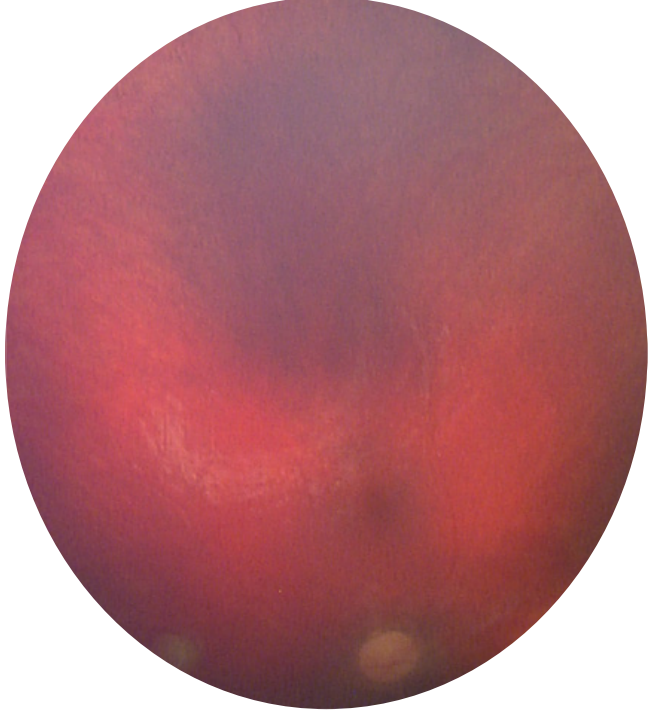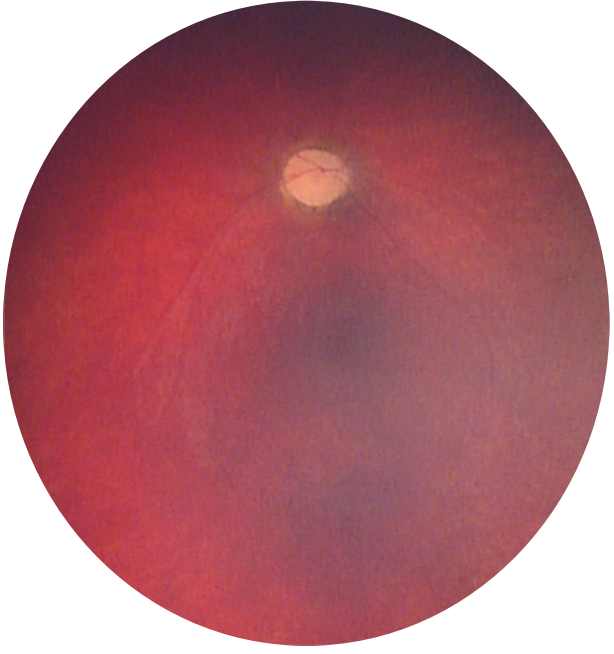
Subject 16 – BDrh-17-TS – Color, FA, ICGA, OCT



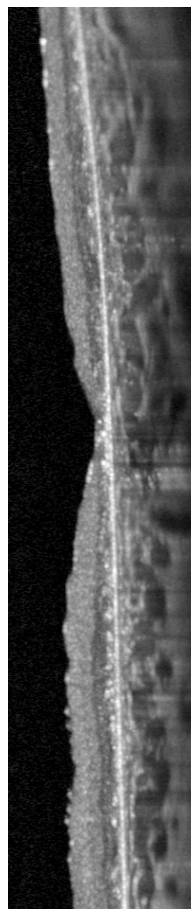
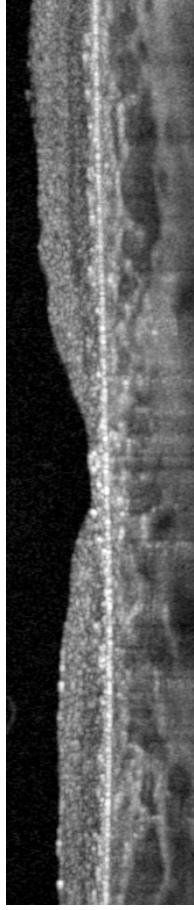
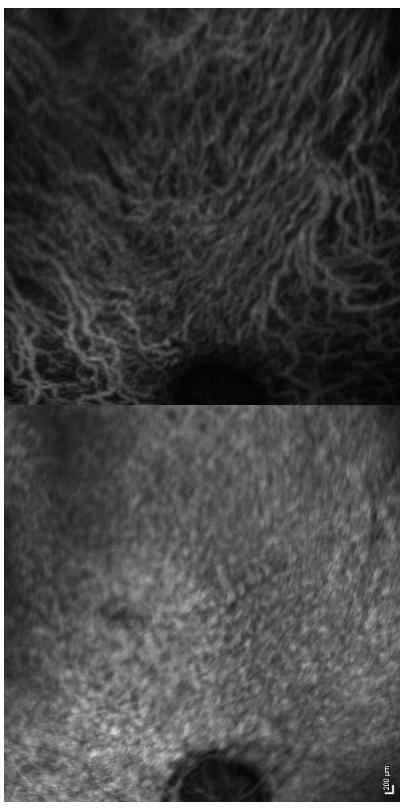
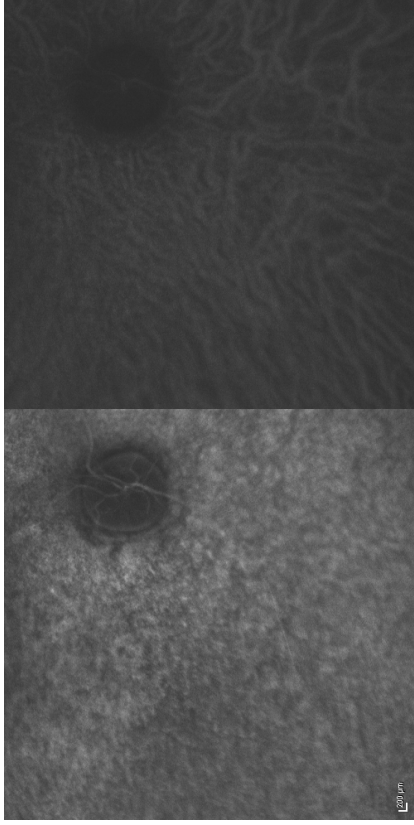
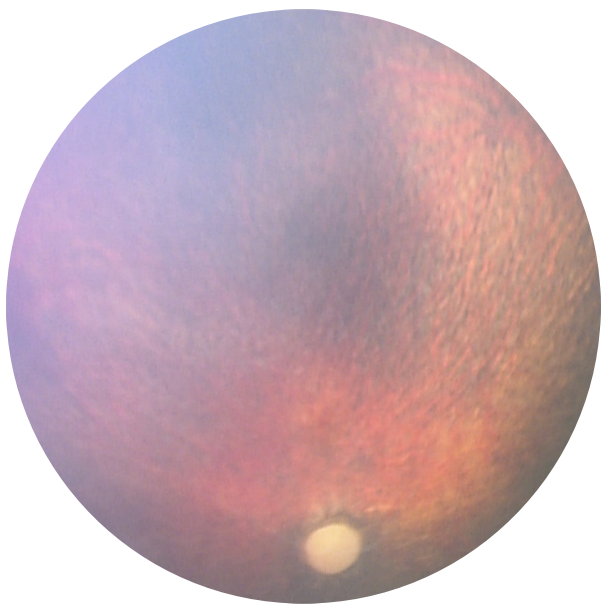
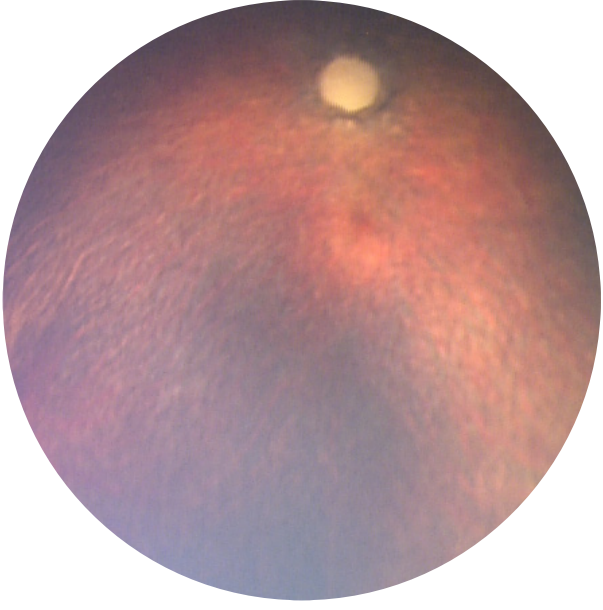
Subject 17 – BDrh-18-FD – Color, FA, ICGA, OCT



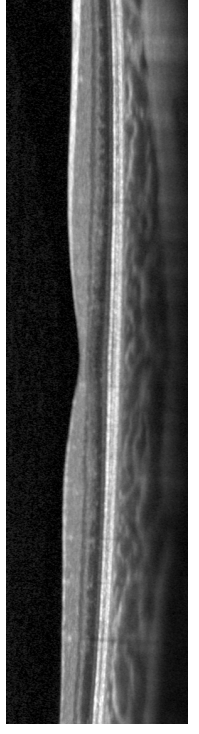
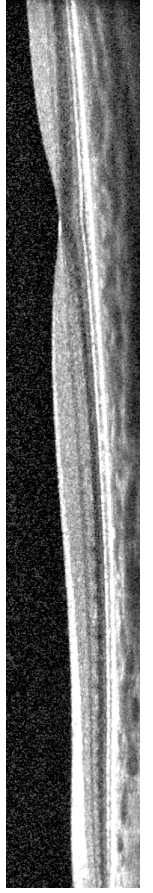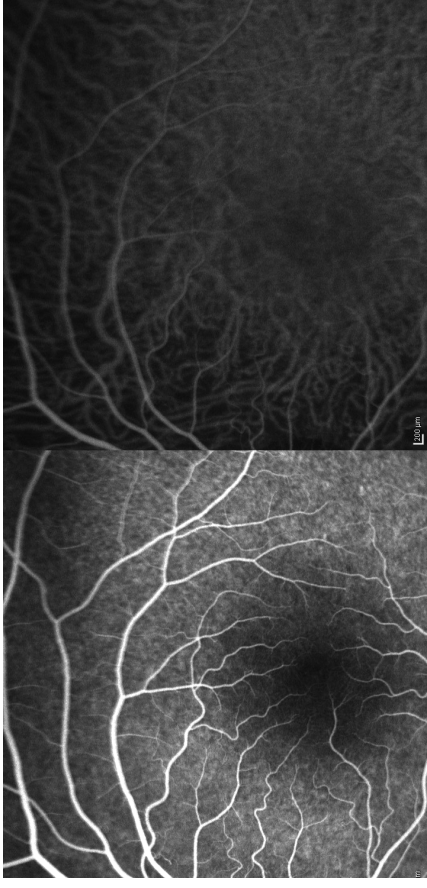
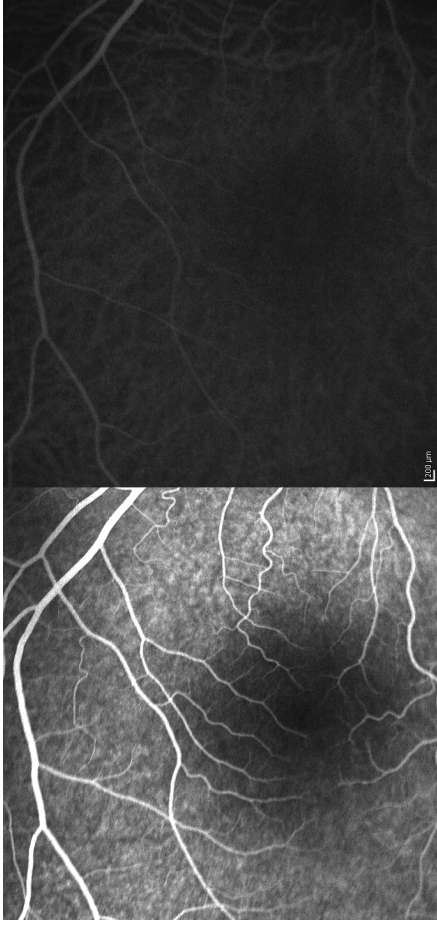
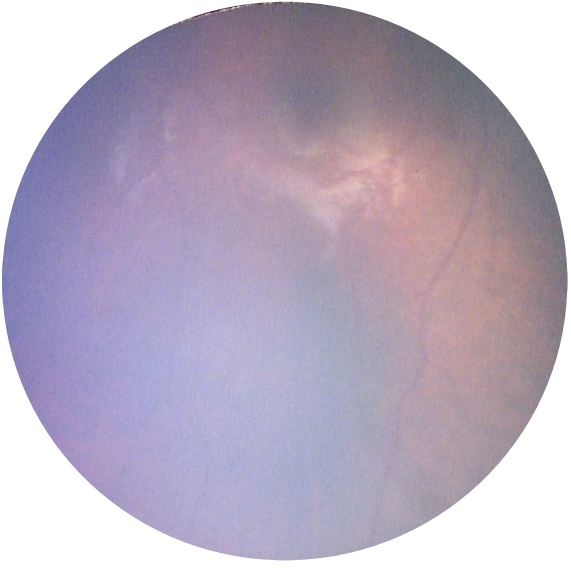
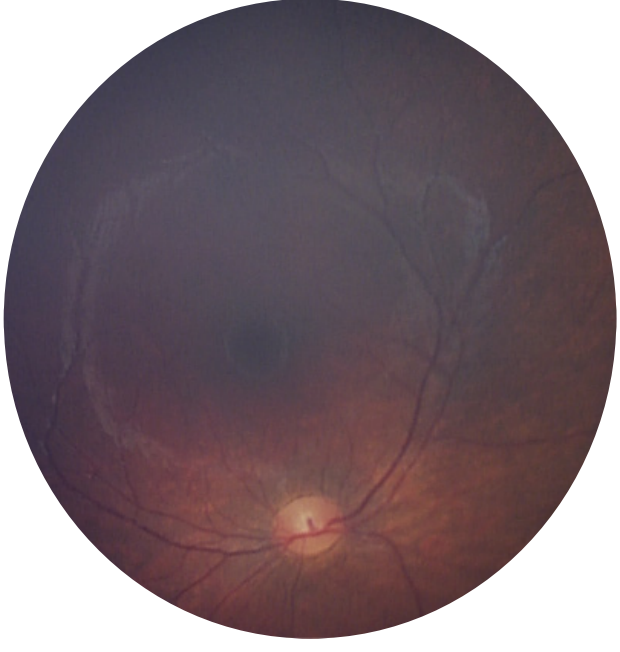
Subject 18 – BDrh-19-UF – Color, FA, ICGA, OCT



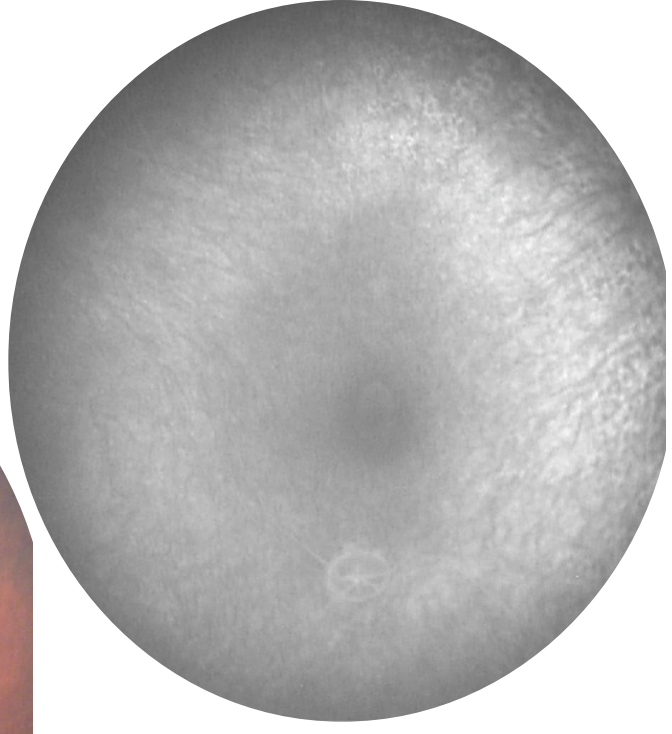
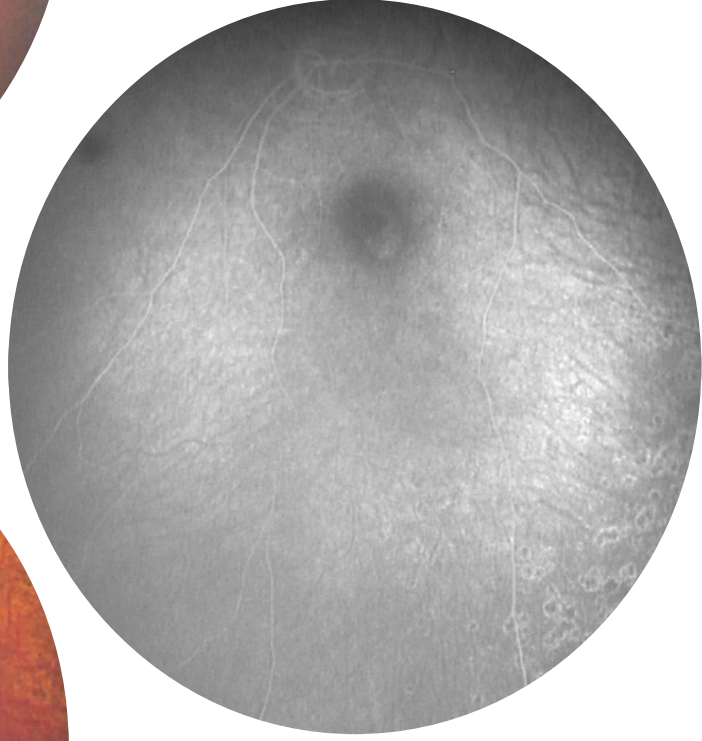
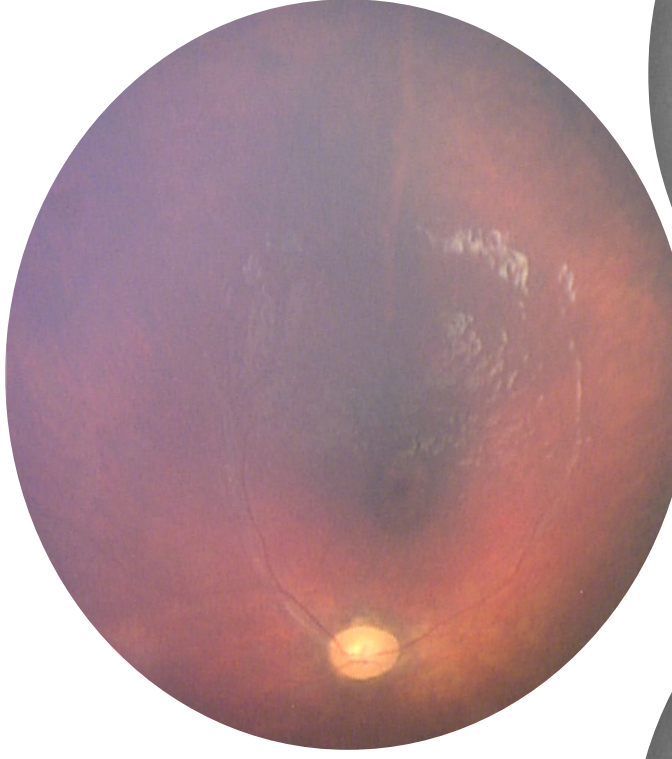
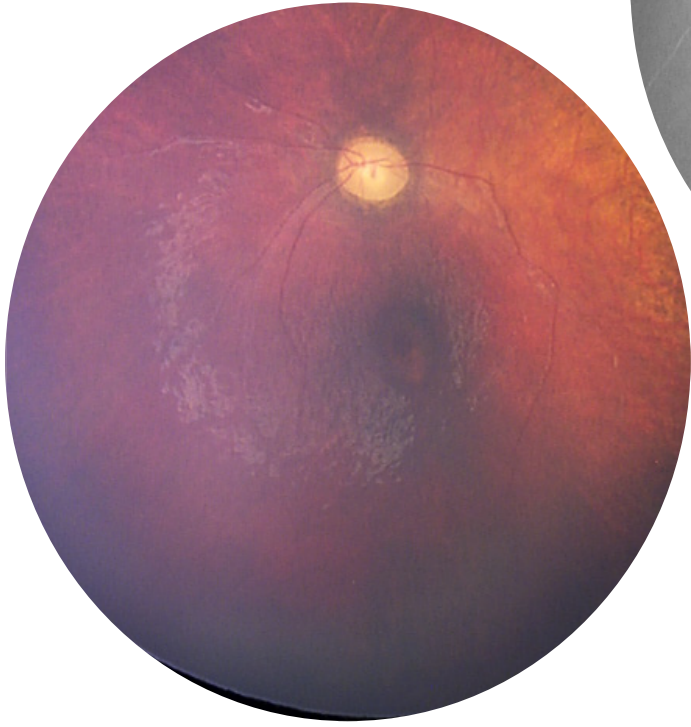
Subject 19 – BDrh-20-SH – Color, FA, ICGA, OCT



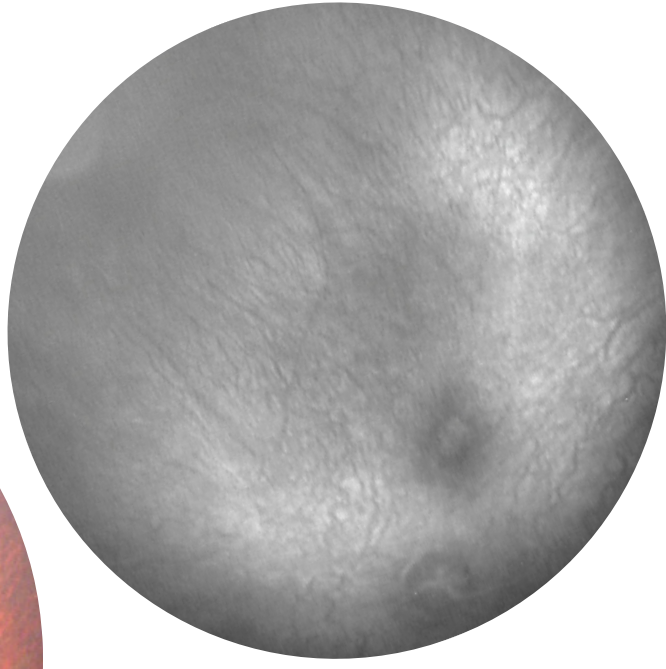
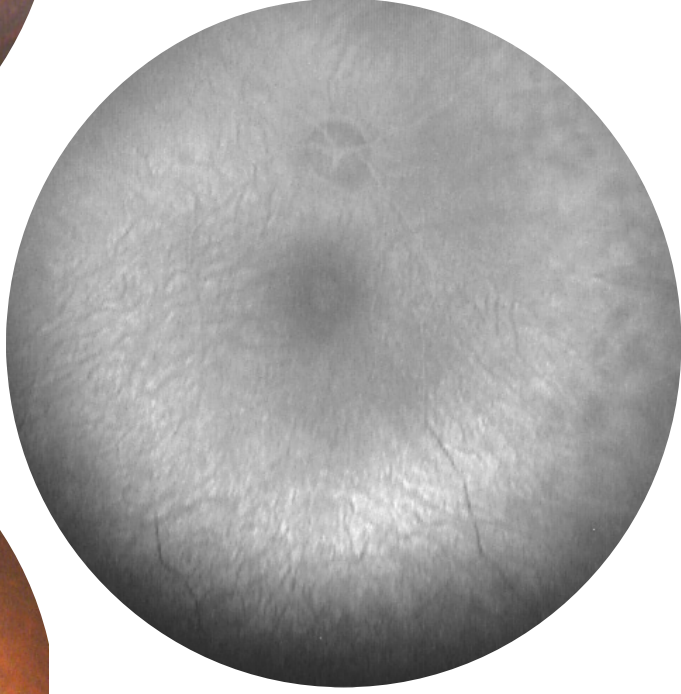
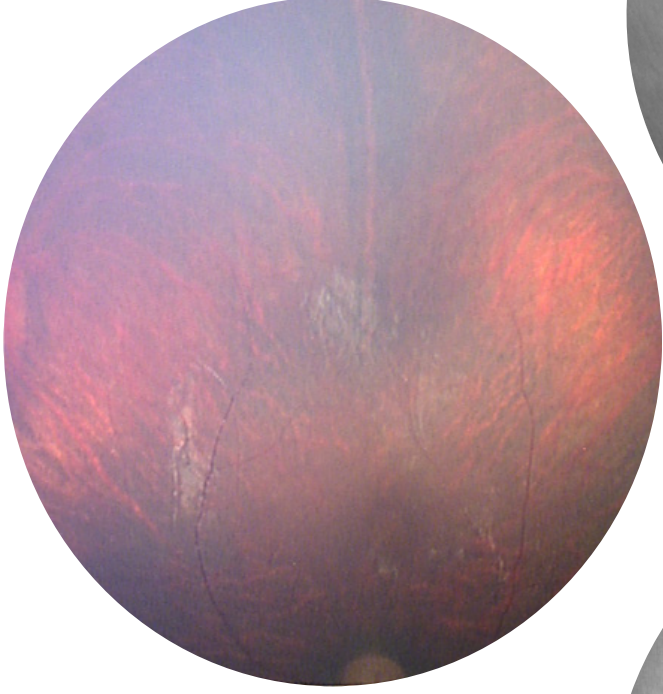
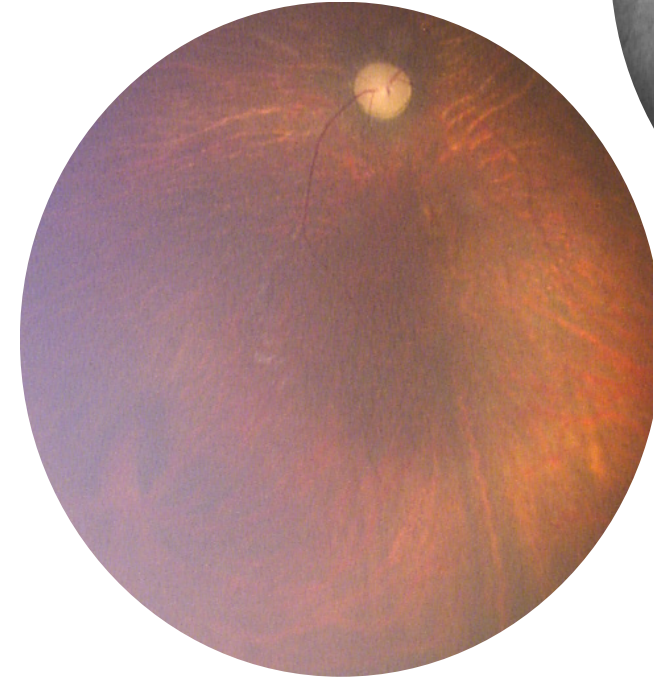
Subject 20 – BDrh-21-JT – Color, FA, ICGA, OCT



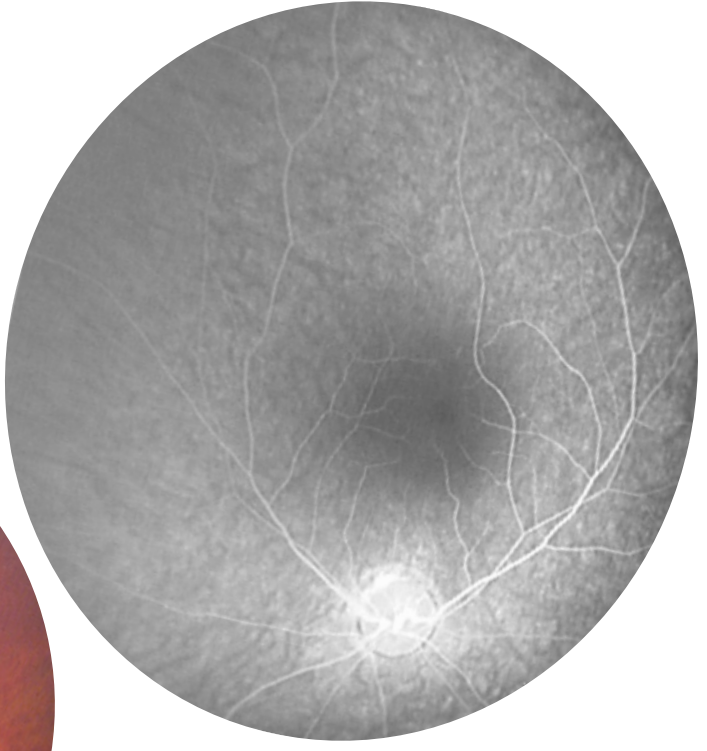
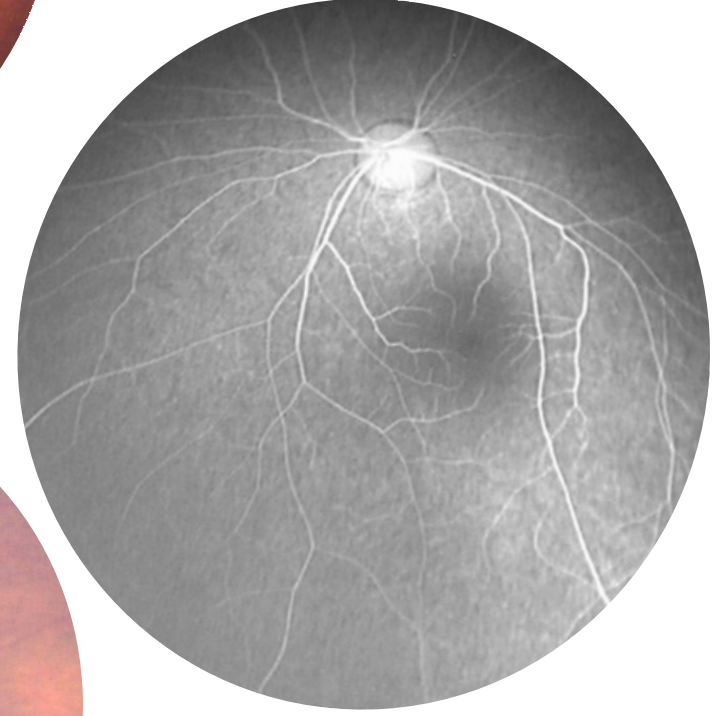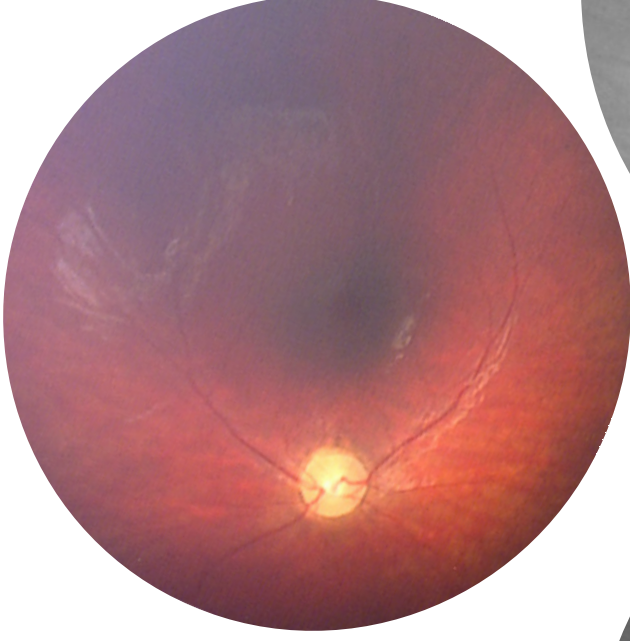
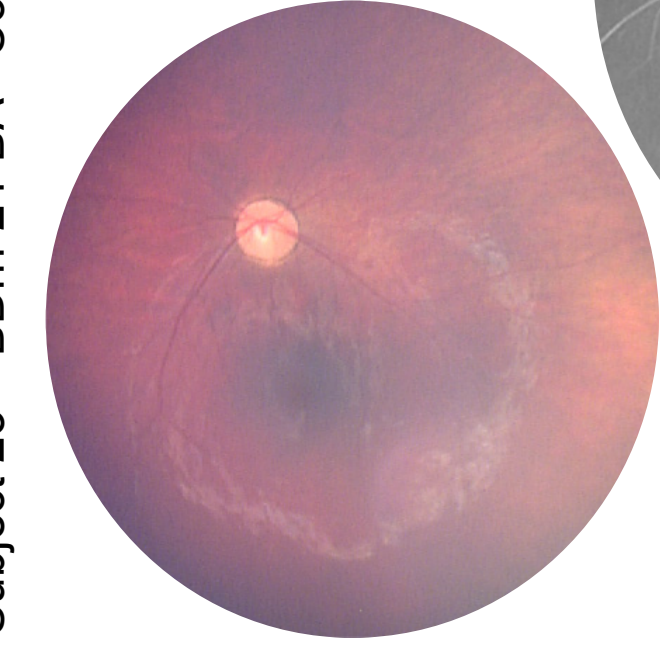
Subject 21 – BDrh-22-LK– Color, FA



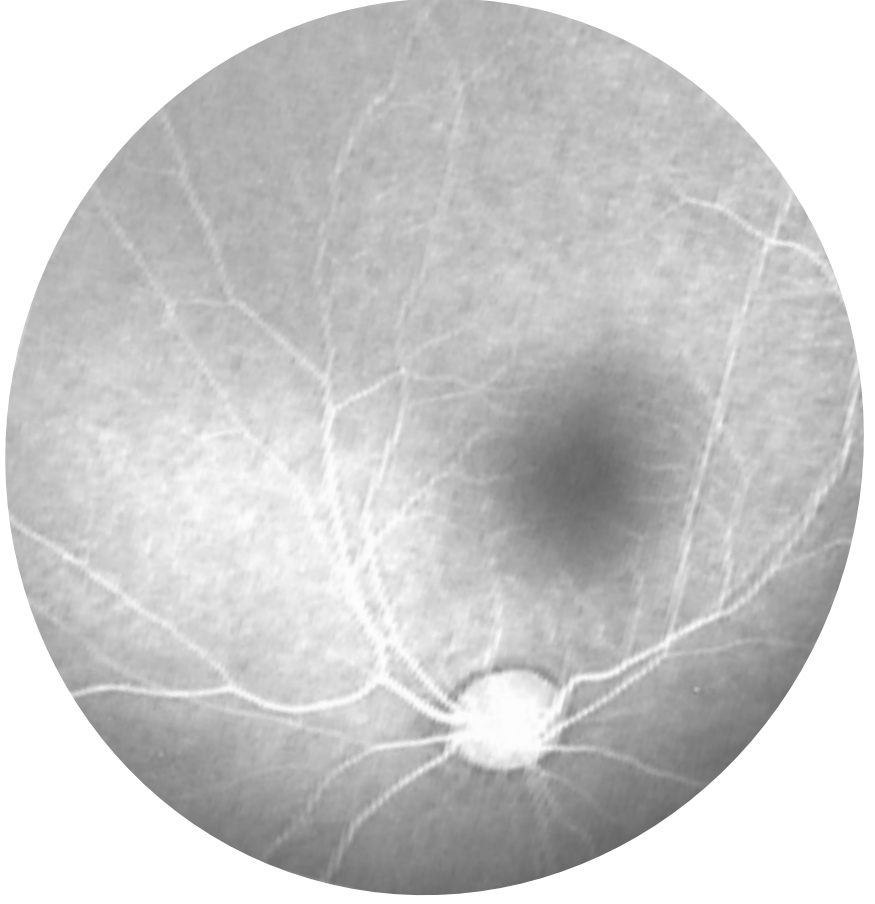
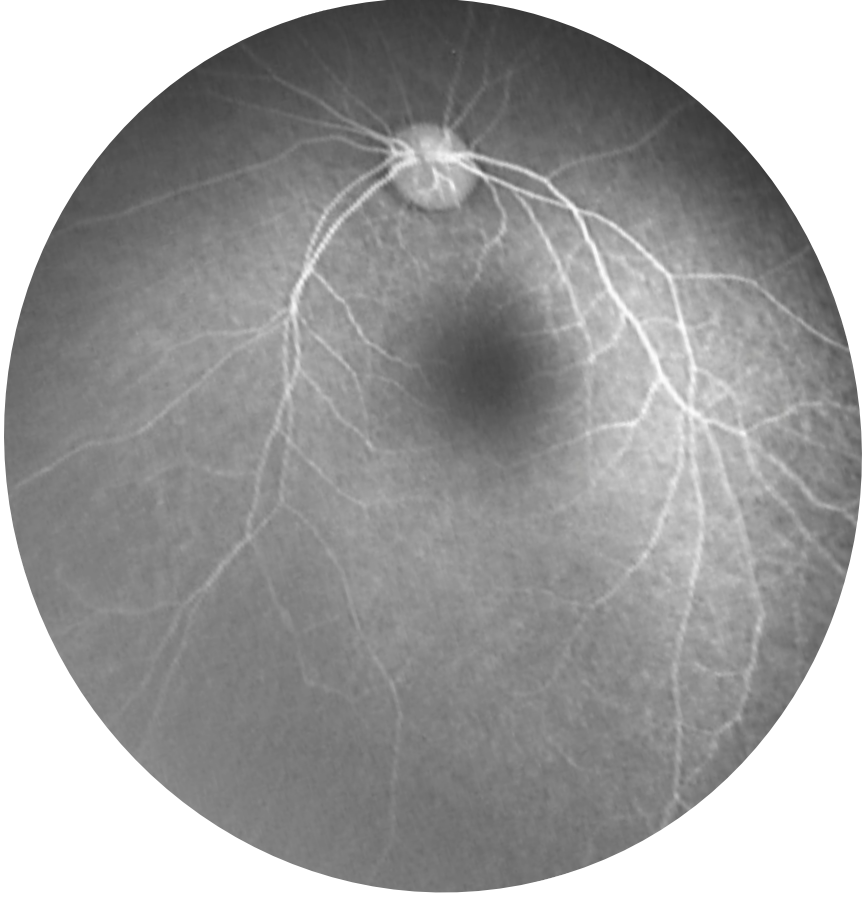Subject 22 – BDrh-23-SC– Color, FA



Subject 23 – BDrh-24-BA– Color, FA



Subject 24 – BDrh-25-MT– Color, FA



Subject 25 – BDrh-26-NV – Color, FA

