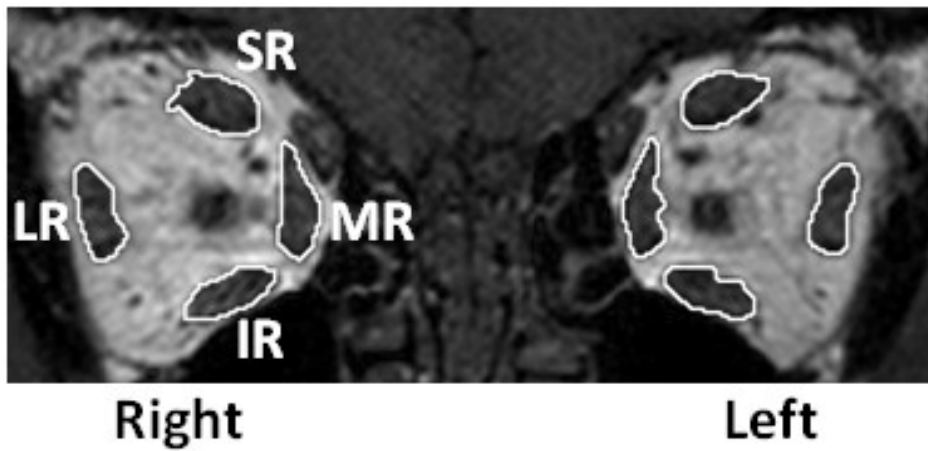


**Figure S2: Boundary delineation of extraocular muscle cross-sections**



Coronal T1-weighted spin-echo MRI slice through the orbit with the boundaries of the recti muscles outlined. IR = inferior rectus; LR = lateral rectus; MR = medial rectus; SR = superior rectus.