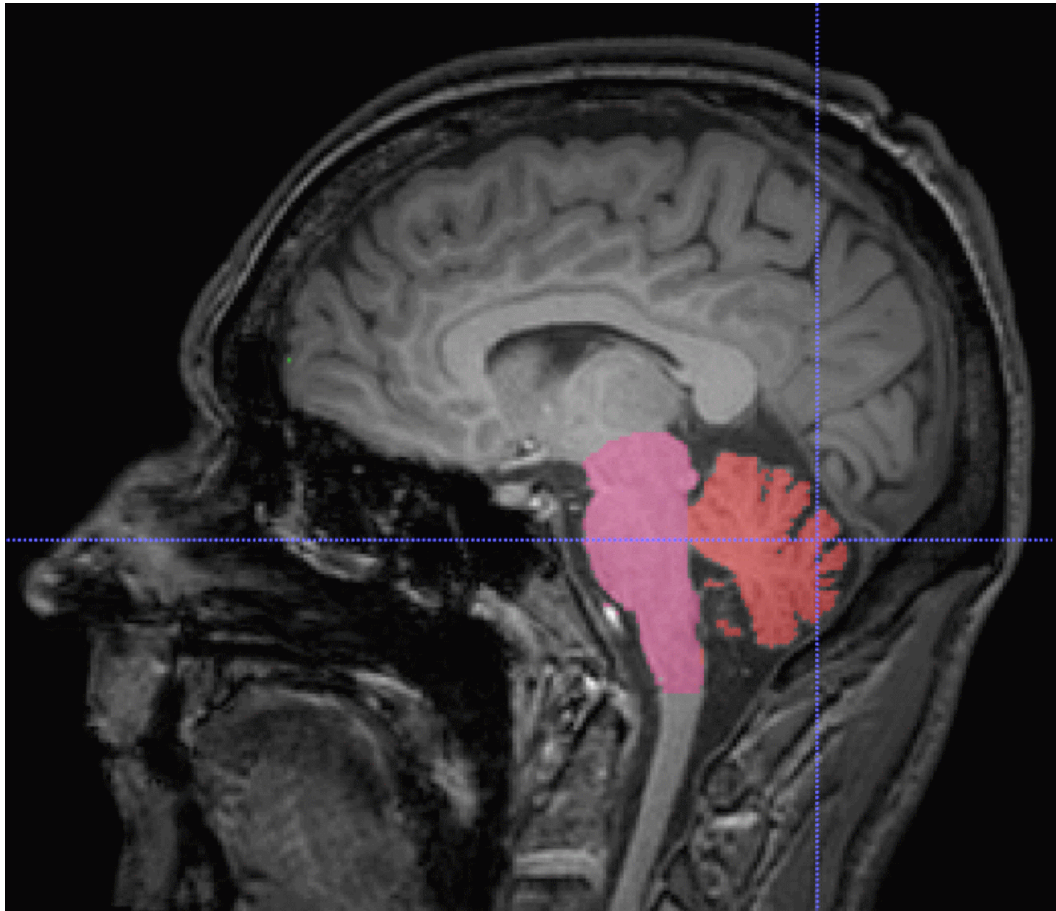


**Figure S3: Measurement protocol for brainstem and cerebellar volumes**



Sagittal T1-weighted MRI slice with the brainstem and cerebellar areas highlighted in pink and red, respectively.