

# Neural Disturbances in Chickens Caused by Dietary T-2 Toxin<sup>1</sup>

R. D. WYATT, W. M. COLWELL, P. B. HAMILTON, AND H. R. BURMEISTER

Department of Poultry Science and Department of Microbiology, North Carolina State University, Raleigh, North Carolina 27607, and Northern Regional Research Laboratory, Agricultural Research Service, U. S. Department of Agriculture, Peoria, Illinois 61604

Received for publication 23 July 1973

Graded concentrations of dietary T-2 toxin (0, 1, 2, 4, 8, and 16  $\mu\text{g/g}$ ) were fed to groups of 40 chickens. T-2 toxin was found to cause an abnormal positioning of the wings, hysteroid seizures, and impaired righting reflex in young chickens. The abnormal wing positioning occurred spontaneously or as the result of dropping from a height of 1 meter. The seizures could be elicited by rough handling or loud noises. The seizures and the abnormal wing posture would not occur again when the stimulus was repeated unless a rest period of 3 to 6 h was allowed. The loss of righting reflex could be demonstrated at any time. The total incidence of neural symptoms was dependent on the length of exposure to T-2 toxin and to its concentration. Neural toxicity occurred at dosages of 4, 8, and 16  $\mu\text{g}$  per g of diet, which are the same doses that retard growth. This neural toxicity of T-2 toxin in chickens is similar to the neural disturbances associated with alimentary toxic aleukia, a nutritional toxicosis of humans produced by eating moldy grain. T-2 toxin has been implicated also in moldy corn toxicosis which has neural manifestations in horses and swine.

T-2 toxin [4,15-diacetoxy-8-(3-methylbutyryloxy)-12,13-epoxy- $\Delta^9$ -trichothecen-3-ol] is a mycotoxin originally isolated from a strain of *Fusarium tricinctum* which was implicated in moldy corn toxicosis of farm animals (2). Subsequent reports have indicated that T-2 toxin also is produced by other fungi (3, 7). One of the outstanding properties of this toxin is its ability to act as a local irritant (13). Irritation and necroses of the skin have resulted from local application to the skin of rabbits (13), and laboratory workers investigating T-2 toxin have experienced a severe contact dermatitis (2). Dietary T-2 toxin causes oral lesions in chickens (21) resembling those found in the third or septic angina stage of alimentary toxic aleukia (ATA), a nutritional toxicosis of humans which was a major health problem in Russia for two decades (14, 15).

Another trait of T-2 toxin which has received less attention is its influence on the nervous system. It has been implicated in "bean-hulls poisoning" of horses which is characterized by staggering and other disturbances of the nervous system (19). In a thorough survey of T-2

toxin for its toxicological properties in rats, Kosuri et al. (12) found that T-2 caused prolonged pentobarbital and hexobarbital sleeping times and decreased the recovery phase of isolated gastrocnemius muscle preparations without altering the transmission of the applied stimulus. ATA, which generally is thought to be fusariotoxicosis (14) and which bears many similarities to T-2 toxicosis (21), has several features indicating a serious involvement of the nervous system. These features may include impaired reflexes, meningism, dermatographism, hyperesthesia, various neuropsychiatric manifestations, and encephalitic symptoms (9, 14). These functional disorders may be explained by the destructive changes in the neurons of the third ventricle and of the sympathetic ganglia. The general vascular hypotonia and insufficiency which dominate the clinical picture of fully developed ATA are thought to result from the diencephalic changes (14).

In an attempt to gain further information about T-2 toxin and its possible role in moldy corn toxicosis and in ATA, we investigated some of its effects on the nervous system of chickens. The present communication describes some of the neural symptomatology in chickens resulting from graded doses of dietary T-2 toxin.

<sup>1</sup> Paper Number 4122 of the Journal Series of the North Carolina State University Agricultural Experiment Station, Raleigh, N.C.

## MATERIALS AND METHODS

**Production of T-2 toxin.** *F. tricinctum* NRRL 3299 was grown on white corn grits (5). The toxin was extracted and purified by the method of Burmeister (5) to yield a crystalline product melting at 148 to 150 C.

**Animal husbandry.** One-day-old male broiler chicks were obtained commercially and were housed in electrically heated batteries under constant lighting. Feed and water were available ad libitum. The feed was a commercial broiler starter diet formulated to be free of all medications.

**Administration of toxin.** T-2 toxicosis was induced by adding known amounts of the toxin to the diet. This was accomplished by dissolving the toxin in 50% (vol/vol) aqueous alcohol and adding it to small portions of the diet. After drying at 100 C, these portions were mixed thoroughly into the remainder of the feed. The experimental diets were fed from hatching until the experiments were terminated at 3 weeks.

**Experimental design.** There were four replicates of 10 birds at each dose level. The treatments and birds were completely randomized (4). The dose levels were 0, 1, 2, 4, 8, and 16  $\mu\text{g}$  of T-2 toxin per g of diet.

**Neurological examination.** The birds were examined carefully at 4-day intervals for any visible manifestations of disturbances of the nervous system. Although any deviation from normal motor responses was interpreted as a positive indication of neural involvement, preliminary experiments indicated that there were three general types of impairment. These were abnormal positioning of the wings, impairment of the righting reflex, and seizures characterized by loss of normal voluntary motor abilities. Subsequent experiments determined the incidence of these symptoms with time in response to graded doses of dietary T-2 toxin.

## RESULTS

The most obvious neural sign of T-2 toxicosis was an abnormal positioning of the wings. Figure 1 is a photograph of a bird that exhibited such wing posture. The wings are elevated both dorsally and laterally from their normal position. This posture was induced by dropping the birds from a height of about 1 m. The posture would be maintained for only a few seconds. While this abnormal posture persisted, the birds remained on their landing spot in a squatting position. Control birds were completely unaffected by identical manipulation. Occasionally in treated birds the abnormal positioning of the wings occurred spontaneously in the cage, and these birds also would not move about until normal wing posture was regained. After the affected birds regained their normal posture, the abnormal position could not be induced if the birds were dropped again immediately. However, the response would occur if the birds were left undisturbed 3 to 6 h before being dropped.

The most dramatic effect of dietary T-2 toxin was the induction of susceptibility to hysteroid seizures which could be provoked by slamming the door to the cage containing the birds. During a seizure the birds fell on their sides or back and appeared to lose all voluntary motor responses (Fig. 2). However, the affected birds did display some brief uncoordinated and uncontrolled movements of the legs, wings, and head. These movements could not be described




FIG. 1. Abnormal wing posture produced by dietary T-2 toxin in young chickens. This chicken received 8  $\mu\text{g}$  of T-2 toxin per g of diet for 3 weeks, and this posture was induced by dropping the chicken from a height of 1 m. Notice the wings are elevated laterally and dorsally from the body.




FIG. 2. Hysteroid seizure in a chicken given dietary T-2 toxin. This chicken was fed 8  $\mu\text{g}$  of T-2 toxin per g of diet for 3 weeks, and the seizure was induced by a loud noise.

properly as tonic or clonic convulsions. The affected birds would lie in this recumbent position for 10 to 30 s before returning to a standing position. Once they regained an upright posture, the birds exhibited normal motor function and could not be distinguished from unaffected birds. As with the abnormal wing positioning, these seizures would not be repeated if the stimulus was applied again immediately. However, if the birds were left undisturbed for several hours, they would react again to the stimulus in a similar manner. It should be mentioned that these seizures could not be elicited by the sudden flash of a photograph flash bulb in a light or darkened room, nor would sudden or violent movement of objects adjacent to the birds cause the response. The character of the noise provoking the seizures played a role since they could not be induced by a shrill blast from a policeman's whistle. However, these seizures cannot be classified simply as audiogenic seizures since the seizures could be induced in a small number of the birds if they were handled roughly by tossing them rapidly from hand to hand while they were allowed to maintain their feet in contact with the flooring or by rolling them over rapidly several times. Considering the overall behavior of the chickens, the seizures could probably be more accurately described as hysteroid than epileptoid (11).

The other main neural sign exhibited by birds receiving dietary T-2 toxin was loss of the righting reflex. When manually placed on their backs, the affected birds were unable to regain their feet in the immediate manner of control birds. The affected birds lay quietly on their backs making occasional attempts to right themselves. An example is shown in Fig. 3. The recumbent birds appeared alert but exhibited a slight tremor in the wings and toes. Some birds remained in dorsal recumbency for more than 30 min before they were able to right themselves. Unlike the abnormal posture and seizures which required a period of rest before they could be induced again, the loss of righting reflex could be demonstrated whenever the birds were placed in dorsal recumbency. When the birds attained an upright position through their own efforts or those of the experimenter, they were able to walk and maneuver in a normal fashion.

The incidence of these neural abnormalities during T-2 toxicosis is shown in Table 1. The data refer to all birds showing any of the three abnormalities described. Some birds displayed all three abnormalities whereas others exhibited only one. The frequency of occurrence of the individual signs or their combinations are not

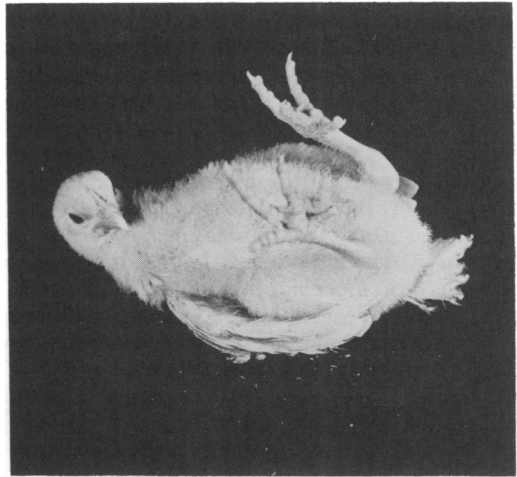


FIG. 3. Loss of righting reflex in chickens given dietary T-2 toxin. This chicken received 8  $\mu\text{g}$  of T-2 toxin per g of diet for 3 weeks before being placed in dorsal recumbency. The chicken remained in this recumbent position for 20 min before it was able to right itself.

TABLE 1. Effect of dietary T-2 toxin on the total incidence of neurological abnormalities in chickens

| T-2 toxin<br>( $\mu\text{g}/\text{g}$ ) | Incidence of abnormalities |      |      |      |      |       |
|---|----------------------------|------|------|------|------|-------|
|   | 1 <sup>a</sup>             | 5    | 9    | 13   | 17   | 21    |
| 0                                       | 0/40 <sup>b</sup>          | 0/40 | 0/40 | 0/40 | 0/40 | 0/40  |
| 1                                       | 0/40                       | 0/40 | 0/40 | 0/40 | 0/40 | 0/40  |
| 2                                       | 0/40                       | 0/40 | 0/40 | 0/40 | 0/40 | 0/40  |
| 4                                       | 0/40                       | 0/40 | 0/40 | 0/40 | 0/40 | 2/40  |
| 8                                       | 0/40                       | 0/40 | 0/40 | 0/40 | 4/40 | 4/40  |
| 16                                      | 0/40                       | 0/40 | 0/40 | 5/40 | 8/40 | 15/40 |

<sup>a</sup> Time in days.

<sup>b</sup> This number means that none of the 40 birds receiving this dose of toxin for this length of time displayed abnormal wing posture, loss of righting reflex, or hysteroid seizures.

shown separately because the frequencies varied markedly from day to day and from experiment to experiment. Indeed, birds that were affected one day might be unaffected the following day. However, the incidence of birds showing one or more of the abnormal neural responses was very repeatable. As shown in Table 1, the incidence of neural disturbances was dependent on the age of the birds as well as the dose of dietary T-2 toxin. Doses of 4, 8, or 16  $\mu\text{g}/\text{g}$  induced abnormalities, and the higher the dose the greater the incidence. Also, the onset of neural disturbances began at an earlier age as the doses were increased. It should be mentioned that the birds displaying these abnor-

malities had normal corneal reflexes and their vision was judged to be normal.

### DISCUSSION

The unusual array of neural symptoms described here and the previously described oral lesions (21) would appear to be beneficial in the diagnosis of T-2 toxicosis in chickens. To our knowledge these symptoms occur rarely in chickens. Although the righting reflex is lost in chickens with muscular dystrophy (1), the other symptoms appear unique. Despite their rare occurrence, the neural symptoms are not as sensitive and as certain an indicator of T-2 toxicosis in chickens as is the occurrence of oral lesions. Dietary T-2 toxin at levels as low as 1  $\mu\text{g/g}$  will cause characteristic raised yellowish lesions in the mouths of 100% of the birds receiving that level of toxin (21). Even at 16  $\mu\text{g/g}$ , T-2 toxin caused visible neural symptoms in only 37.5% of the birds.

These neural symptoms should aid in an assessment of the role of T-2 toxin in moldy corn toxicosis. Although the toxin was isolated as the result of an investigation of the disease (2, 10), the original description of the disease in chickens (9) does not mention neural symptoms. However, moldy corn toxicosis was reported to cause a staggering gait in swine (9) and a leukoencephalomalacia characterized by liquefaction necrosis of the brain in horses (18). A similar situation exists with the oral lesions caused by T-2 toxin. The original descriptions of moldy corn toxicosis (9, 10) make no mention of oral lesions; however, oral lesions apparently identical to those caused by T-2 toxin have been reported since that time in field cases in chickens and pigeons (20) and in laboratory studies of fusariotoxicosis in turkeys (8) and goslings (17). Additional field cases in which the affected animals are specifically examined for neural symptoms and oral lesions should aid in a more accurate definition of the role of T-2 toxin in moldy corn toxicosis.

The status of ATA is uncertain despite its being a major health concern in Russia for about two decades (14, 15). It is generally accepted that this nutritional toxicosis is caused by the ingestion of grain infected with *Fusarium* sp. (9, 15, 21), although the toxic principle(s) responsible for the disease do not appear to have been isolated (15, 21). Wyatt et al. (21) pointed out many similarities between T-2 toxicosis and ATA, and they suggested that T-2 toxin might be involved in ATA. The present observations on the occurrence of neural disturbances during T-2 toxicosis of chickens

support this suggestion. Although neural disturbances are not obvious in all cases of ATA, there is ample evidence that they are a major underlying problem in severe cases (14). Also, grain that caused ATA in man caused a syndrome in geese characterized by nervous disorders—convulsion-like signs, rigidity, dropping to one side, and ataxia (15). The present observations are in keeping with the symptoms of "bean-hulls poisoning" of horses in which T-2 toxin has been implicated (19), and with the laboratory studies on the toxicology of T-2 toxin in rats (12).

Because *Fusarium* and related fungi produce several other toxins closely related to T-2 toxin (3, 6, 16, 19), it would seem appropriate to investigate them more thoroughly both individually and with regard to their possible interactions. In particular, the neurotoxicity of these fusariotoxins would appear to be interesting and fruitful areas of inquiry. Then, perhaps, the responsibility for ATA and moldy corn toxicosis can be assigned to specific chemical entities, and the current ill-defined status of these important diseases can be dispelled.

### ACKNOWLEDGMENTS

We thank Sharon West, G. Whittaker, and Nancy Goodwin for technical assistance.

### LITERATURE CITED

1. Albuquerque, E. X., and J. E. Warnick. 1971. Electrophysiological observations in normal and dystrophic chicken muscles. *Science* 172:1260-1263.
2. Bamberg, J. R., N. V. Riggs, and F. M. Strong. 1968. The structures of toxins from two strains of *Fusarium tricinctum*. *Tetrahedron* 24:3329-3336.
3. Bamberg, J. R., and F. M. Strong. 1969. Mycotoxins of the tricothecane family reproduced by *Fusarium tricinctum* and *Trichoderma lignorum*. *Phytochemistry* 8:2405-2410.
4. Bruning, J. L., and B. L. Kintz. 1968. Computational handbook of statistics. Scott Foresman Co., Glenview, Ill.
5. Burmeister, H. R. 1971. T-2 toxin production by *Fusarium tricinctum* on solid substrate. *Appl. Microbiol.* 21:739-742.
6. Burmeister, H. R., J. J. Ellis, and S. G. Yates. 1971. Correlation of biological to chromatographic data for two mycotoxins elaborated by *Fusarium*. *Appl. Microbiol.* 21:673-675.
7. Burmeister, H. R., J. J. Ellis, and C. W. Hesseltine. 1972. Survey for fusaria that elaborate T-2 toxin. *Appl. Microbiol.* 23:1165-1166.
8. Christensen, C. M., R. A. Meronuck, G. H. Nelson, and J. C. Behrens. 1972. Effects on turkey poults of rations containing corn invaded by *Fusarium tricinctum* (Cda.) Syn. & Hans. *Appl. Microbiol.* 23:177-179.
9. Forgacs, J., and W. L. Carll. 1972. Mycotoxicoses. *Advan. Vet. Sci.* 7:273-382.
10. Gilgan, M. W., E. B. Smalley, and F. M. Strong. 1966. Isolation and partial characterization of a toxin from *Fusarium tricinctum* on moldy corn. *Arch. Biochem. Biophys.* 114:1-3.

11. Gowers, W. R. 1964. Epilepsy and other chronic convulsive diseases: their causes, symptoms, and treatment. Dover Publication Inc., New York.
12. Kosuri, N. R., E. B. Smalley, and R. E. Nichols. 1971. Toxicologic studies of *Fusarium tricinctum* (Corda) Snyder et Hansen from moldy corn. *Amer. J. Vet. Res.* **32**:1843-1850.
13. Marasas, W. F. O., J. R. Bamburg, E. B. Smalley, F. M. Strong, W. L. Ragland, and P. E. Degurse. 1969. Toxic effects on trout, rats, and mice of T-2 toxin produced by the fungus *Fusarium tricinctum* (Cd.) Synd. *Hans. Toxicol. Appl. Pharmacol.* **15**:471-482.
14. Mayer, C. F. 1953. Endemic panmyelotoxicosis in the Russian grain belt. I. The clinical aspects of alimentary toxic aleukia (ATA); a comprehensive review. *Mil. Surg.* **113**:173-189.
15. Mayer, C. F. 1953. Endemic panmyelotoxicosis in the Russian grain belt. II. The botany, phytopathology, and toxicology of Russian cereal Food. *Mil. Surg.* **113**:295-315.
16. Mirocha, C. J., C. M. Christensen, and G. H. Nelson. 1968. Toxic metabolites produced by fungi implicated in mycotoxicoses. *Biotech. Bioeng.* **10**:469-482.
17. Palyusik, M., I. Szep, and F. Szoke. 1968. Data on susceptibility to mycotoxins on day-old goslings. *Acta Vet. Med. Hung. Tomus* **18**:363-372.
18. Schwarte, L. H., H. E. Biester, and C. Murray. 1937. A disease of horses caused by feeding moldy corn. *J. Amer. Vet. Med. Ass.* **90**:76-85.
19. Ueno, Y., K. Ishii, K. Sakai, S. Kanaeda, H. Tsunoda, T. Tanaka and M. Enomoto. 1972. Toxicological approaches to the metabolites of Fusaria. IV. Microbial survey on "bean-hulls poisoning of horses" with the isolation of toxic trichothecenes, neosolaniol and T-2 toxin of *Fusarium solani* M-1-1. *Jap. J. Exp. Med.* **42**:187-203.
20. Wyatt, R. D., J. R. Harris, P. B. Hamilton, and H. R. Burmeister. 1972. Possible outbreaks of fusariotoxicosis in avians. *Avian Dis.* **16**:1123-1130.
21. Wyatt, R. D., B. A. Weeks, P. B. Hamilton, and H. R. Burmeister. 1972. Severe oral lesions in chickens caused by ingestion of dietary fusariotoxin T-2. *Appl. Microbiol.* **24**:251-257.