

Figure S4. Histology of infected murine brains

Figure S4 (A)

(A) Hematoxylin and eosin (H&E) stained brain sections were scored for meningoencephalomyelitis using a scale of 0 to 5 (n=4). $p < 0.05$ WT vs $\Delta cst1::cst1^{\Delta muc}$

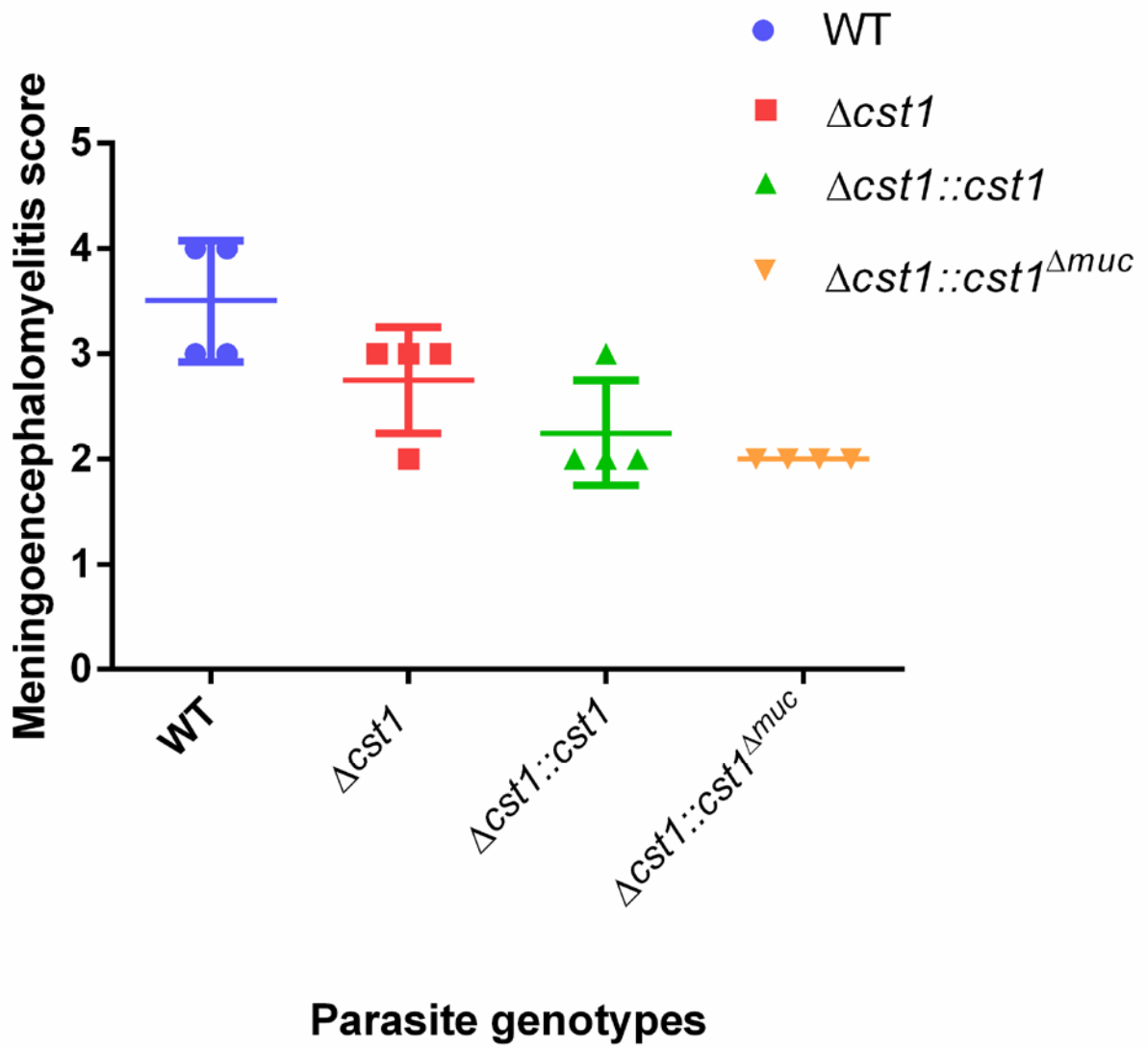


Figure S4. (B) Brains from mice infected with WT, $\Delta cst1$, $\Delta cst1::cst1$, or $\Delta cst1::cst1^{\Delta muc}$ parasites for 4 weeks were sectioned and stained with H&E. Photomicrographs were obtained at 4X, 10X and 20X magnifications. Tissue cysts are indicated by a red arrow on 20X magnification images.

