

# MALE PELVIS Normal Tissue RTOG Consensus Contouring Guidelines

# GU

Organ	Standardized TPS Name	Tumor Category	Consensus Definition
rectum	Rectum	GU	Inferiorly from the lowest level of the ischial tuberosities (right or left). Contouring ends superiorly before the rectum loses its round shape in the axial plane and connects anteriorly with the sigmoid. The Rectum is used with the BowelBag.
bowel bag	BowelBag	GU	<p>* Inferiorly from the most inferior small or large bowel loop, or above the Rectum (GU) or AnoRectum (GYN), whichever is most inferior. If when following the bowel loop rule the Rectum or AnoRectum is present in that axial slice, it should be included as part of the bag; otherwise it should be excluded.</p> <p>Tips: Contour the abdominal contents excluding muscle and bones. Contour every other slice when the contour is not changing rapidly, and interpolate and edit as necessary. Finally, subtract any overlapping non-GI normal structures. If the TPS does not allow subtraction leave as is.</p>

\*Stop contouring the BowelBag, SmallBowel, and Colon 1 cm above PTV for most coplanar beam plans, but the choice will depend on the treatment technique. Stop these PTVs at distances much greater than 1 cm for non-coplanar beam plans depending on the beam angle and path. Tomotherapy plans will require stopping from 1 to 5 cm above the PTV, depending on the selected field size, which is often 2.5 cm.

Abbreviations: TPS = treatment planning software

# GU / GI

Organ	Standardized TPS Name	Tumor Category	Consensus Definition
bladder	Bladder	GU, GI	Inferiorly from its base, and superiorly to the dome
prostate	Prostate	GU	<p>Inferiorly from its apex and superiorly to its base. If the capsule is visible, the muscles and soft tissues abutting the capsule are not included as “prostate”.</p> <p>Tips: The apex is above the hourglass or slit shape that results from the in-bowing of the levator ani just below. Refer to article by McLaughlin <i>et al.</i> PubMed ID: 19515511</p>
seminal vesicles	SeminalVesc	GU	Entire seminal vesicles including those slices that also have prostate identified.
penile bulb	PenileBulb	GU	<p>That portion of the bulbous spongiosum of the penis immediately inferior to the GU diaphragm. Do not extend this structure anteriorly into the shaft or pendulous portion of the penis.</p> <p>Tips: The penile bulb is best identified with MRI (bright on T2) or CT when there is contrast in the urethra. On CT, the penile bulb will be posterior to the urethra and has a round shape. Refer to article by Wallner <i>et al.</i> PubMed ID: 12095559</p>
proximal femurs	Femur_R Femur_L	GU, GI	<p>The proximal femur inferiorly from the lowest level of the ischial tuberosities (right or left) and superiorly to the top of the ball of the femur, including the trochanters.</p> <p>Tips: Auto-contouring threshold parameters with bone can facilitate this process, but requires editing any auto-contouring artifacts.</p>

# GI

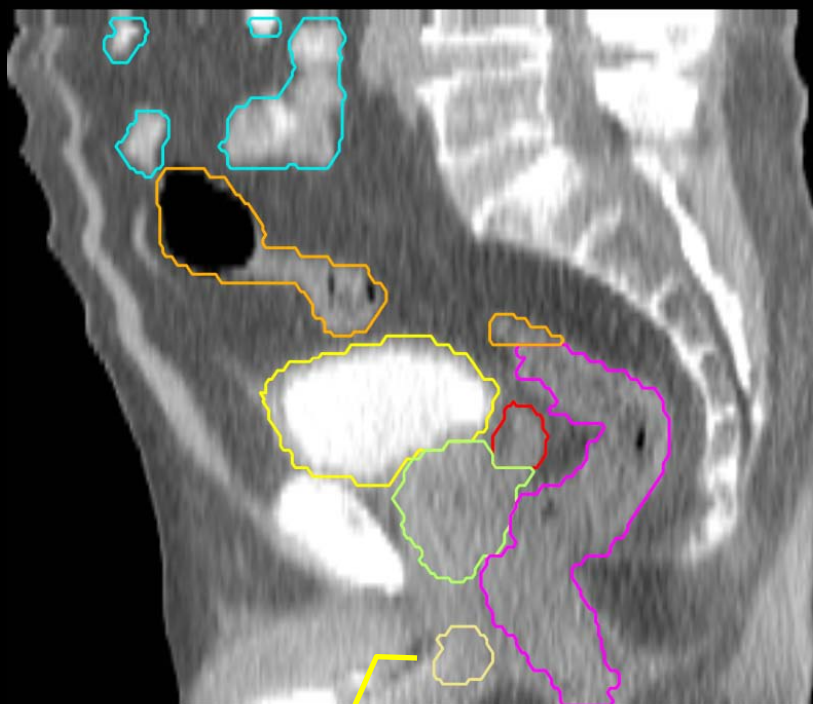
Organ	Standardized TPS Name	Tumor Category	Consensus Definition
small bowel	SmallBowel	GI	* In order to distinguish from large bowel, the use of oral contrast is encouraged. After administration of contrast (e.g. 3 oz gastrograffin and 3 oz water/barium mixture) 30 minutes prior to scanning, the small bowel can be outlined as loops containing contrast.
colon	Colon	GI	* Large bowel continuing where the AnoRectumSig contour ended. Depending on the volume treated, this will include portions or all of the ascending, transverse, descending and sigmoid colon.

\* Stop contouring the BowelBag, SmallBowel, and Colon 1 cm above PTV for most coplanar beam plans, but the choice will depend on the treatment technique. Stop these PTVs at distances much greater than 1 cm for non-coplanar beam plans depending on the beam angle and path. Tomotherapy plans will require stopping from 1 to 5 cm above the PTV, depending on the selected field size, which is often 2.5 cm.

# GI - target

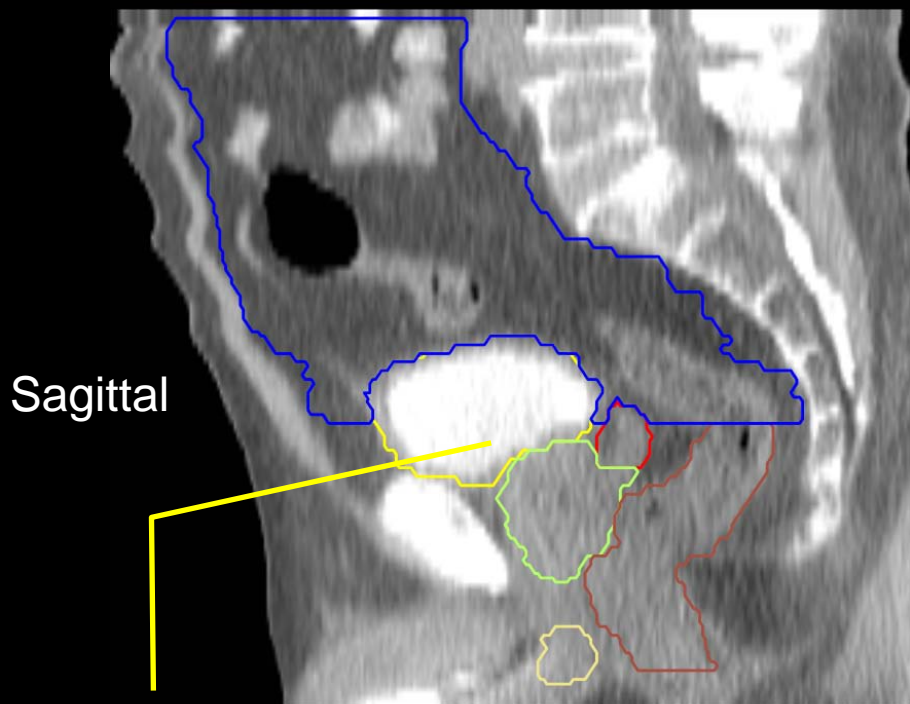
Organ	Standardized TPS Name	Tumor Category	Consensus Definition
anus + rectum + rectosigmoid <b>(target)</b>	AnoRectumSig	GI	Target structure. Inferiorly from the anal verge as marked with a radiopaque marker at time of simulation. Contouring ends superiorly at the rectosigmoid flexure after the mesorectum disappears. The AnoRectumSig is used with the Small Bowel and Colon.
mesorectum <b>(target)</b>	Mesorectum	GI	<p>Target structure for anal and rectal cancer. The rectum inferiorly below where the mesorectal fat disappears, and continuing superiorly and encompassing the mesorectal fat until the mesorectal fascia disappears. For these entities, the AnoRectoSig (anus + rectum + rectosigmoid), unlike the rest of the alimentary canal, is NOT an avoidance structure.</p> <p>In cases where it is difficult to visualize the mesorectum, the anatomical borders of the mesorectum include: cranial, the level of the recto-sigmoid junction; caudal, the anorectal junction defined by where the levator muscles fuse with the external sphincter muscles (or where the mesorectal fat/space can no longer be seen tapering inferiorly); posterior, pre-sacral space; anterior, GU/GYN organs with an internal margin of 10 mm to the anterior mesorectal border on the axial slices of the bladder to account for bladder volume variation on this boundary; lateral-medial edge of the levator ani in the lower pelvis and pelvic brim in upper (excluding any non-target muscle).</p> <p>Tip: Adjusting the windowing level may facilitate visualizing the mesorectum.</p>

Contour BowelBag, Colon and SmallBowel the suggested cm above PTV, not necessarily this high



PenileBulb has a rounded shape

- PenileBulb
- SmallBowel
- Bladder
- SeminalVesc
- Prostate
- AnoRectumSig
- Colon

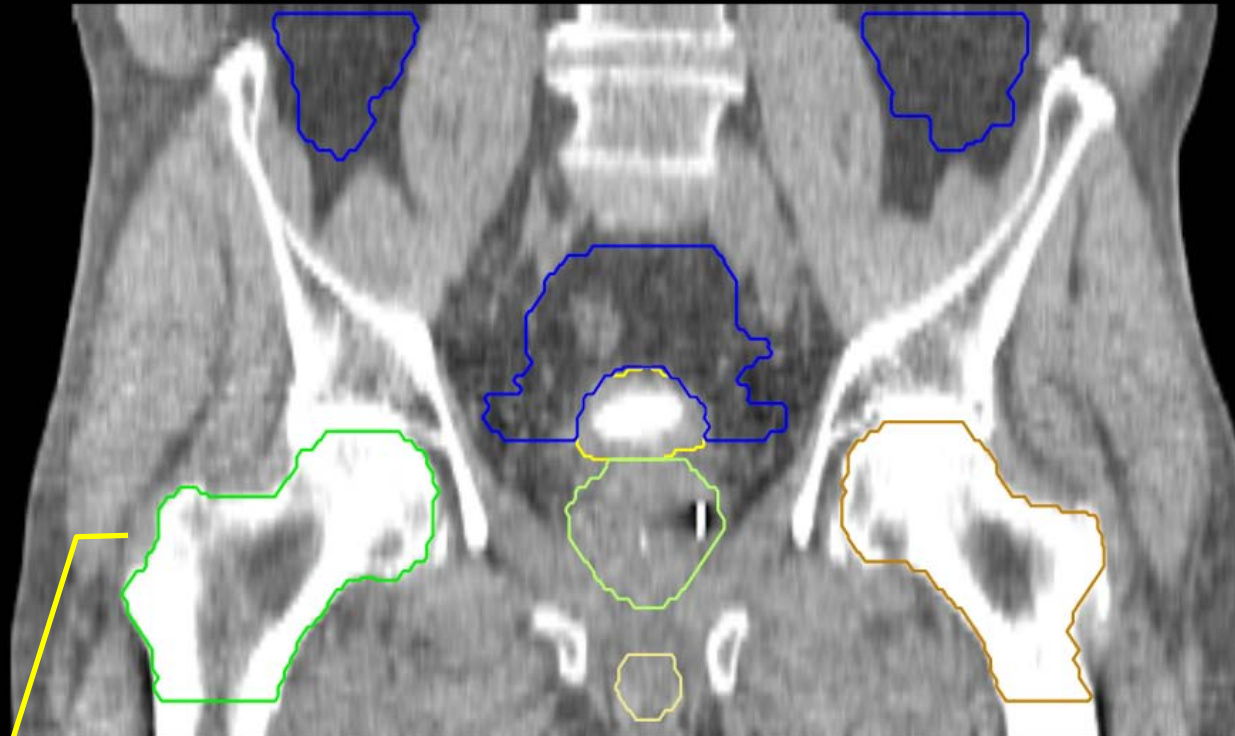


Sagittal

subtract any overlapping non-GI normal structures from BowelBag

- PenileBulb
- Bladder
- SeminalVesc
- Prostate
- Rectum
- BowelBag

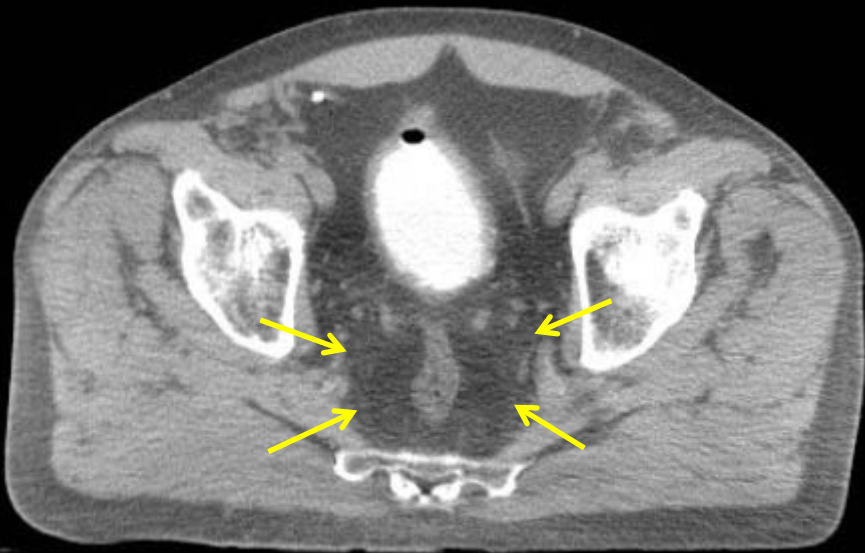
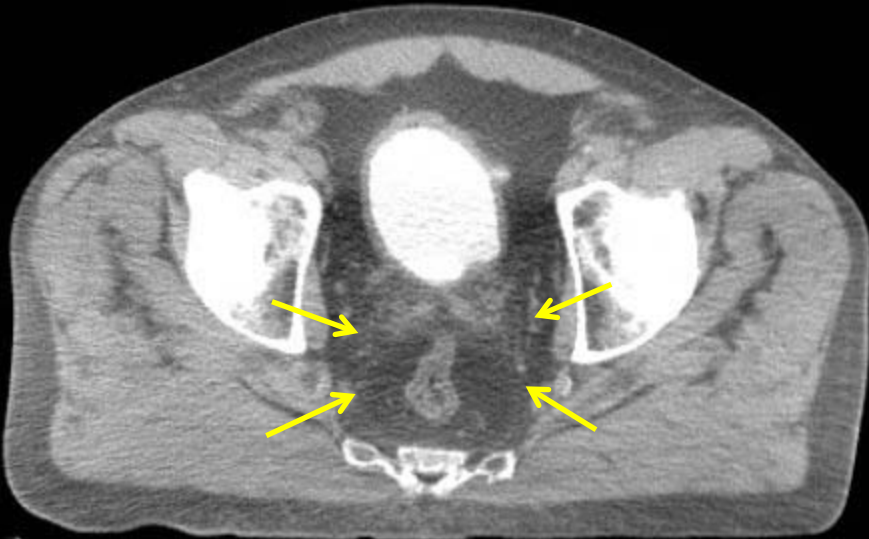
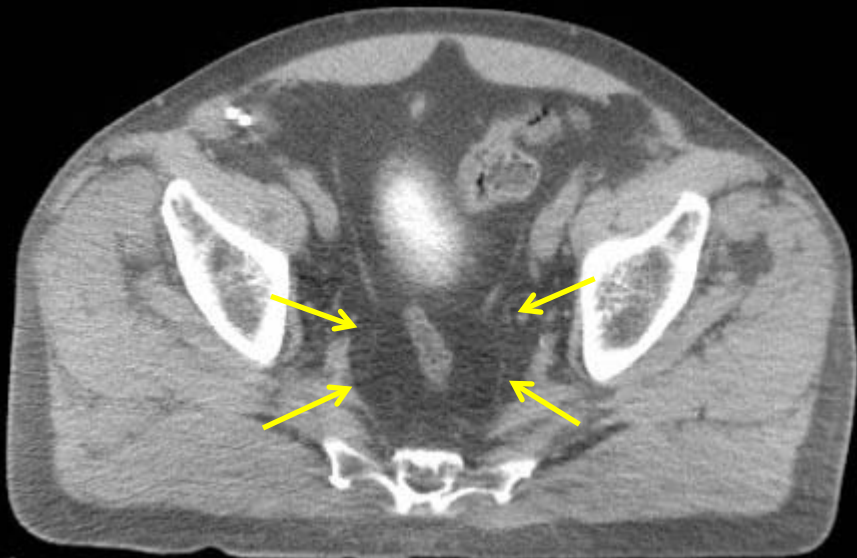
- PenileBulb
- Bladder
- Prostate
- Femur\_L
- Femur\_R
- BowelBag



Femur\_R and Femur\_L include the proximal femur, not just the ball of the femur

Coronal

Arrows, mesorectal fascia





GU:

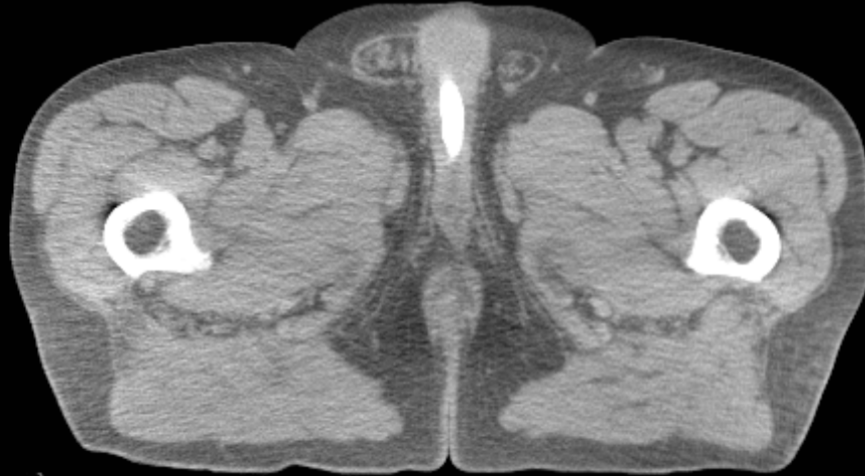
- Rectum
- BowelBag

GU/GI:

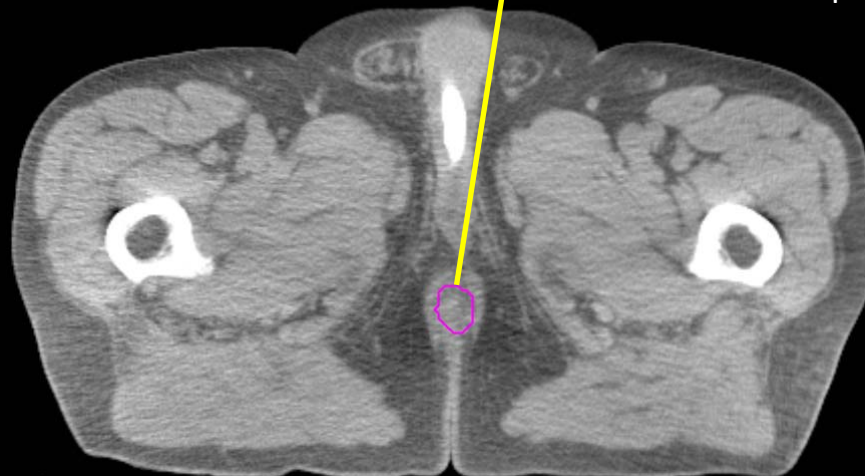
- PenileBulb
- Bladder
- SeminalVesc
- Prostate
- Femur\_L
- Femur\_R

GI:

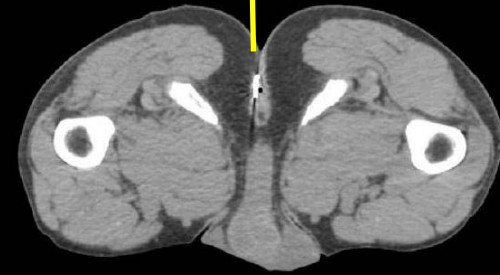
- Small Bowel
- AnoRectumSig
- Colon
- Mesorectum



Axial



The anus and the AnoRectumSig start caudally but this CT data set did not go more inferiorly. A radiopaque marker, as in the other patient below, would have helped identify the anal verge.



GU:

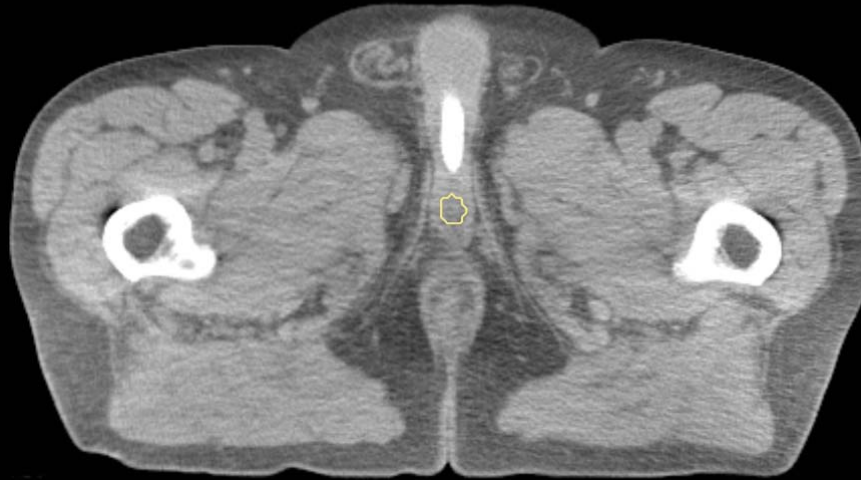
- Rectum
- BowelBag

GU/GI:

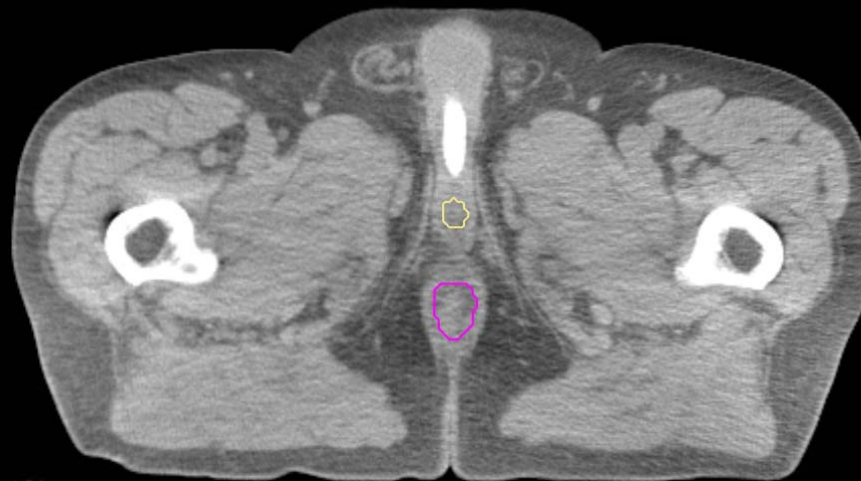
- PenileBulb
- Bladder
- SeminalVesc
- Prostate
- Femur\_L
- Femur\_R

GI:

- Small Bowel
- AnoRectumSig
- Colon
- Mesorectum



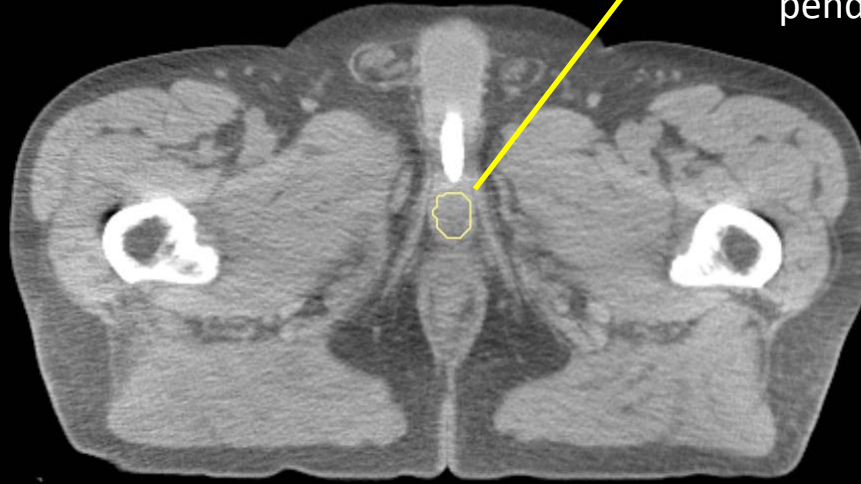It is an excellent habit to always use the standardized nomenclature, even if the patient is not in a protocol



GU:

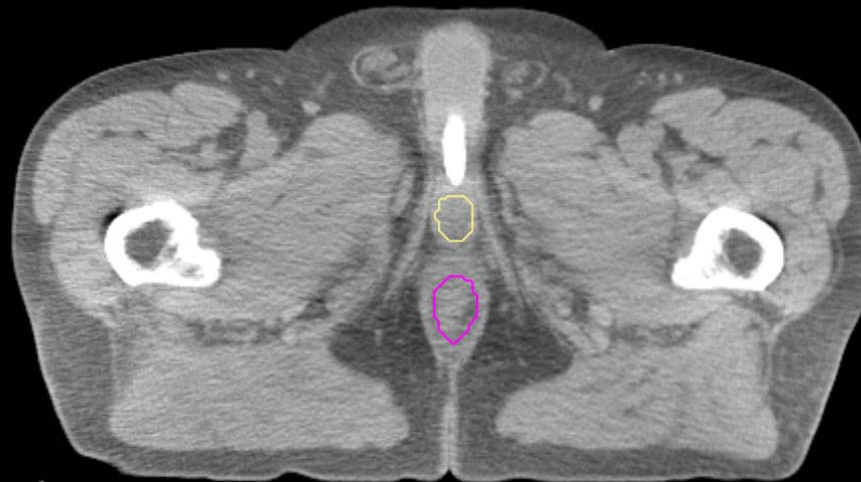
- Rectum
- BowelBag

Do not extend the penile bulb anteriorly into the shaft or pendulous portion of the penis.



GU/GI:

- PenileBulb
- Bladder
- SeminalVesc
- Prostate
- Femur\_L
- Femur\_R



GI:

- Small Bowel
- AnoRectumSig
- Colon
- Mesorectum

GU:

- Rectum
- BowelBag

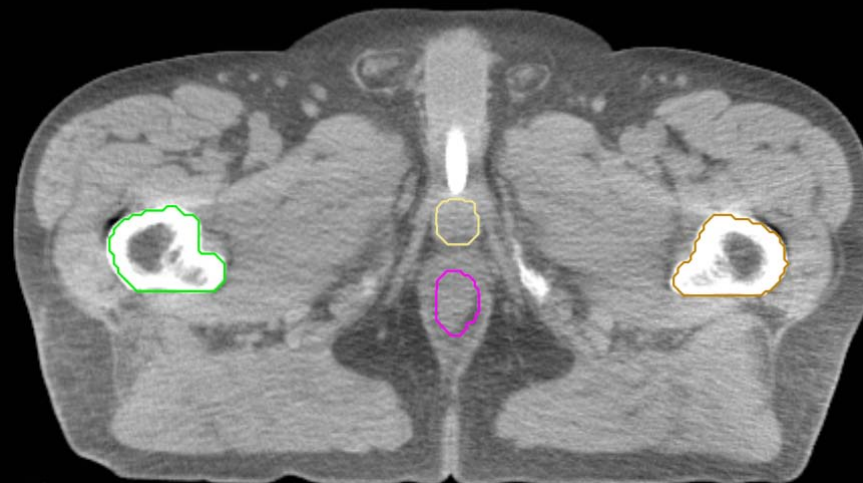
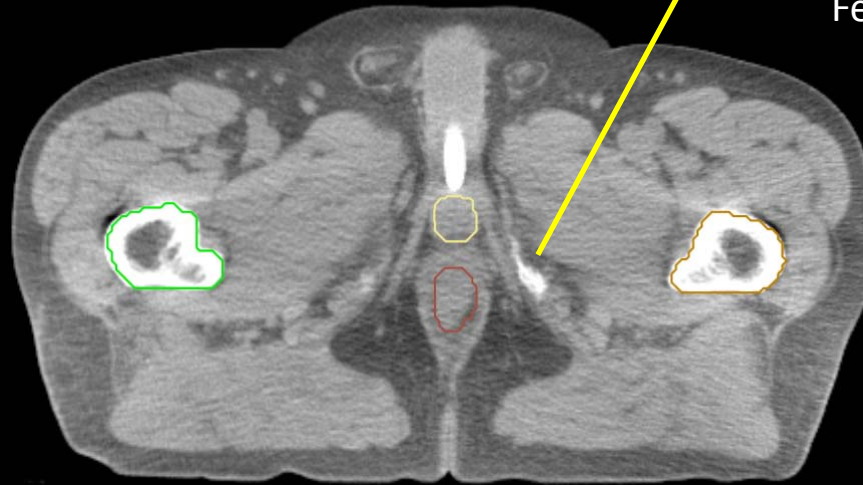
GU/GI:

- PenileBulb
- Bladder
- SeminalVesc
- Prostate
- Femur\_L
- Femur\_R

GI:

- Small Bowel
- AnoRectumSig
- Colon
- Mesorectum

lowest level of ischial tuberosities,  
this is where the Rectum,  
Femur\_L, and Femur\_R start



GU:

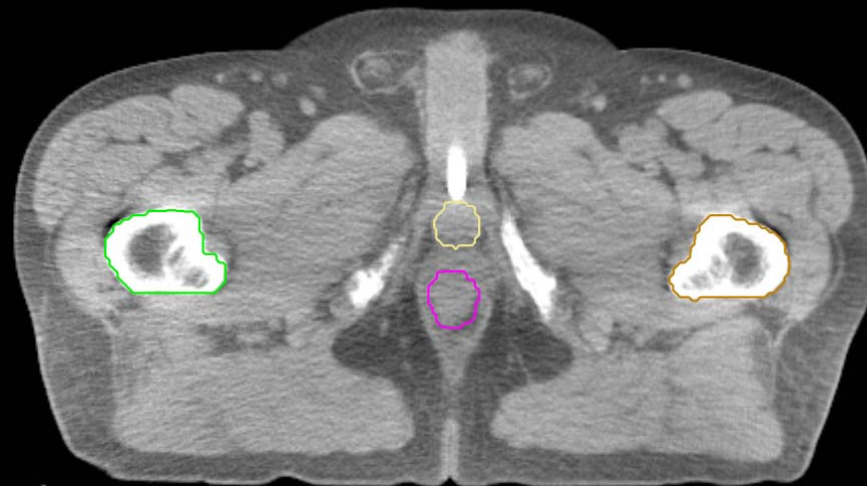
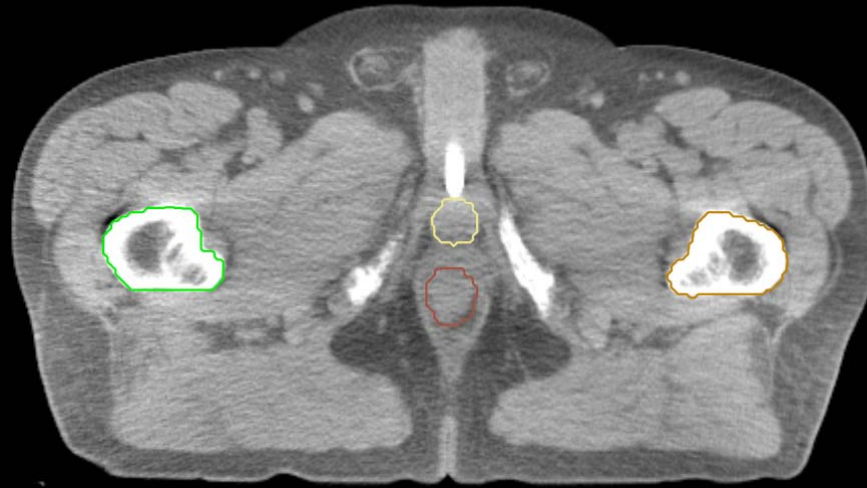- Rectum
- BowelBag

GU/GI:

- PenileBulb
- Bladder
- SeminalVesc
- Prostate
- Femur\_L
- Femur\_R

GI:

- Small Bowel
- AnoRectumSig
- Colon
- Mesorectum



GU:

- Rectum
- BowelBag

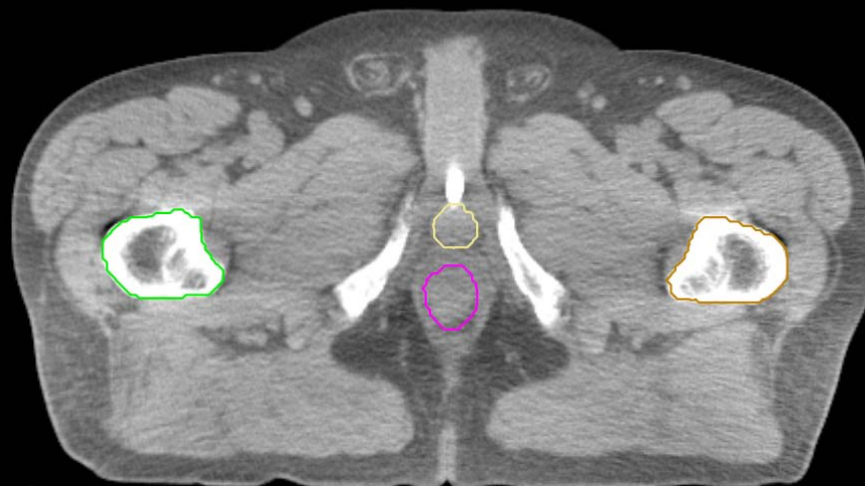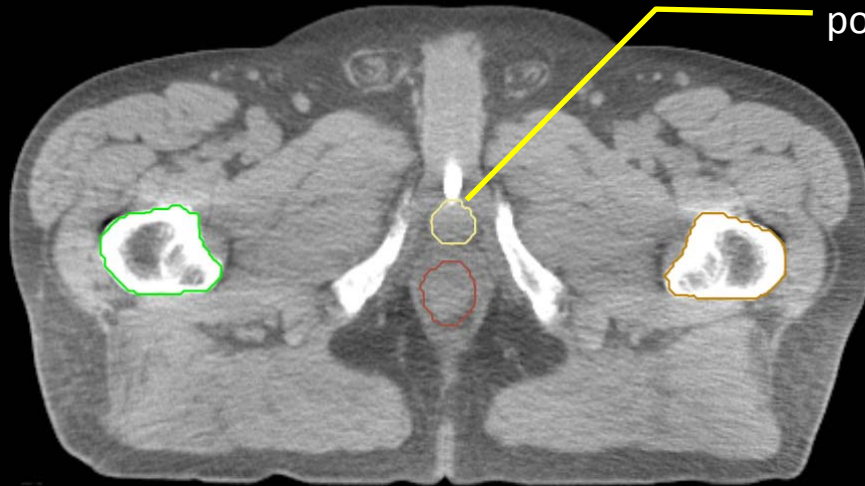
GU/GI:

- PenileBulb
- Bladder
- SeminalVesc
- Prostate
- Femur\_L
- Femur\_R

GI:

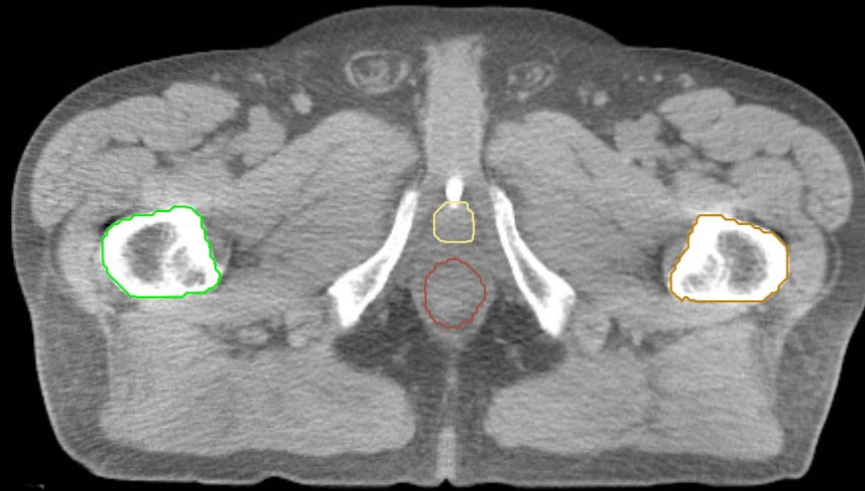
- Small Bowel
- AnoRectumSig
- Colon
- Mesorectum

PenileBulb is round and posterior to the urethra. On MRI, bright on T2.



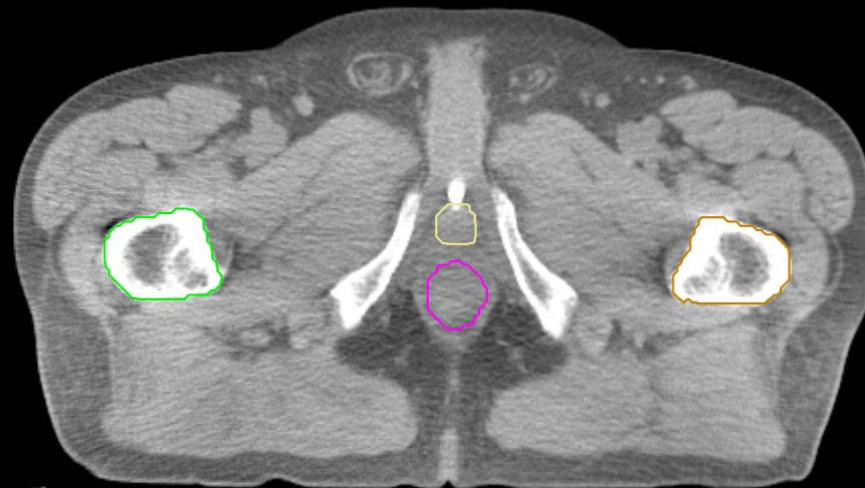
GU:

- Rectum
- BowelBag



GU/GI:

- PenileBulb
- Bladder
- SeminalVesc
- Prostate
- Femur\_L
- Femur\_R



GI:

- Small Bowel
- AnoRectumSig
- Colon
- Mesorectum

GU:

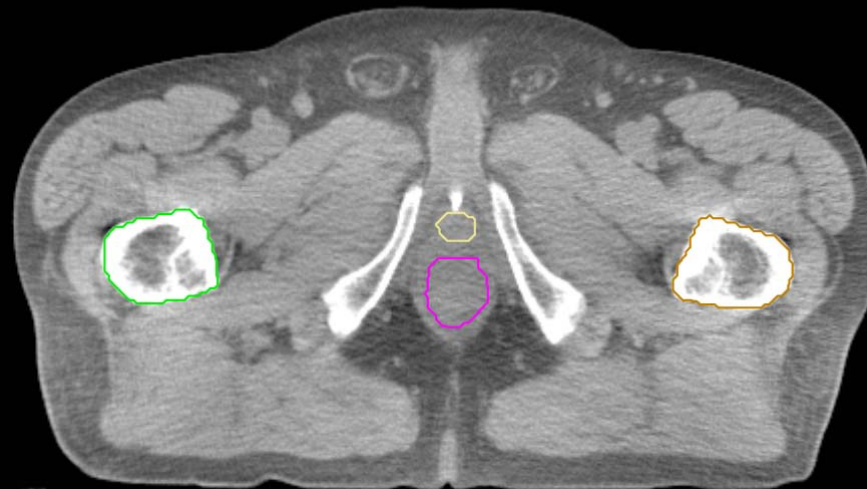
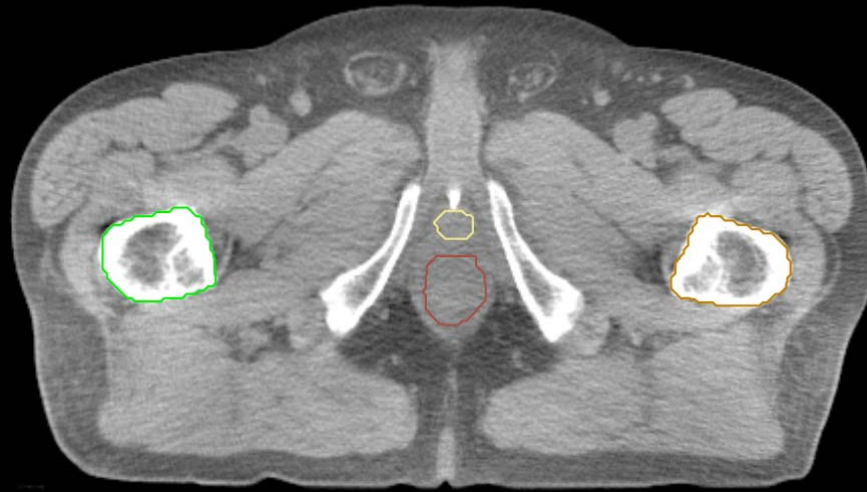- Rectum
- BowelBag

GU/GI:

- PenileBulb
- Bladder
- SeminalVesc
- Prostate
- Femur\_L
- Femur\_R

GI:

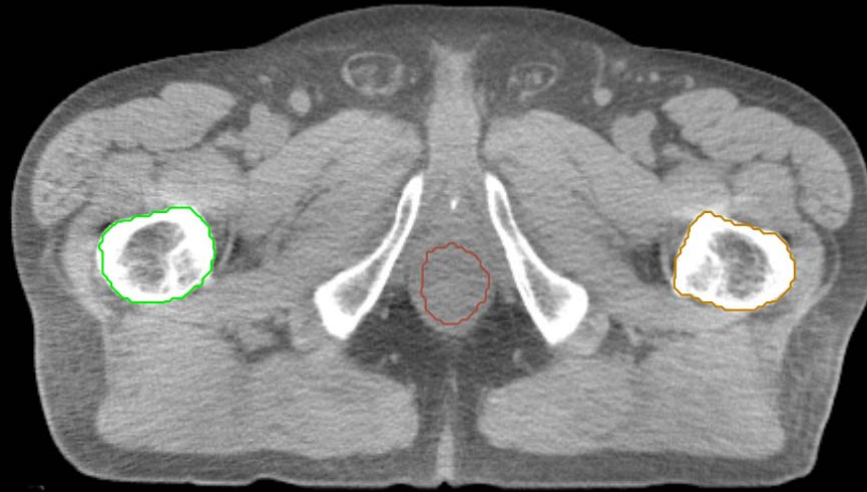- Small Bowel
- AnoRectumSig
- Colon
- Mesorectum





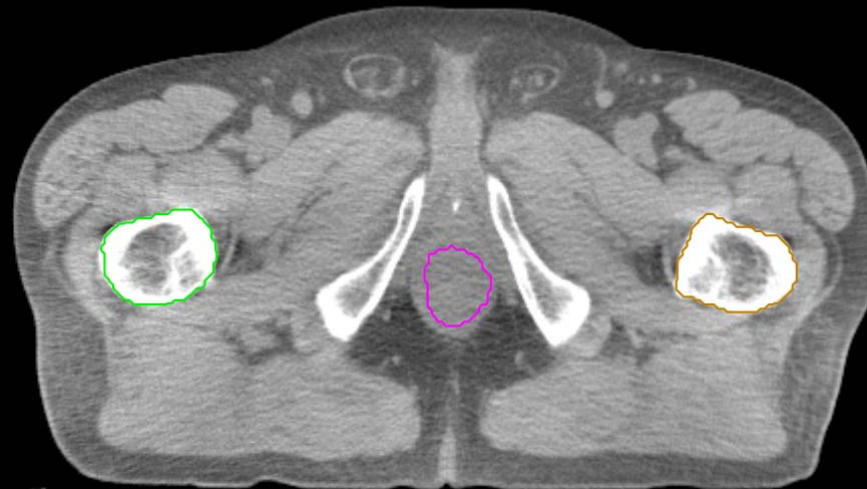
GU:

- Rectum
- BowelBag



GU/GI:

- PenileBulb
- Bladder
- SeminalVesc
- Prostate
- Femur\_L
- Femur\_R

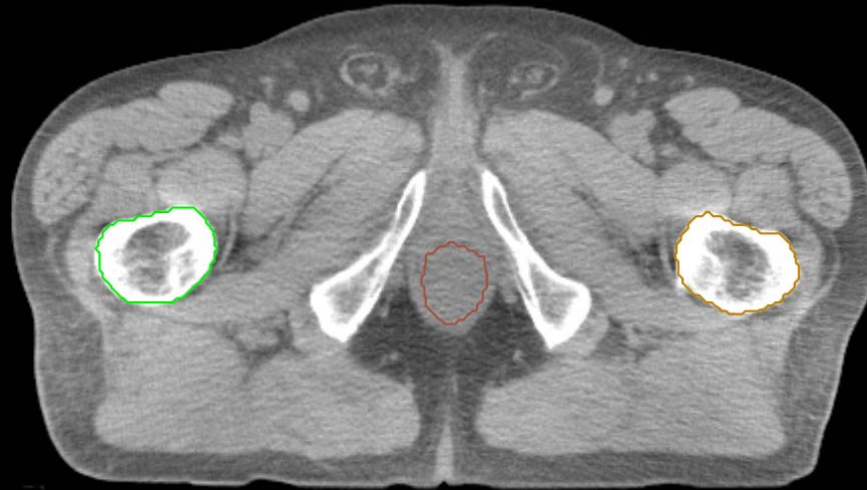


GI:

- Small Bowel
- AnoRectumSig
- Colon
- Mesorectum

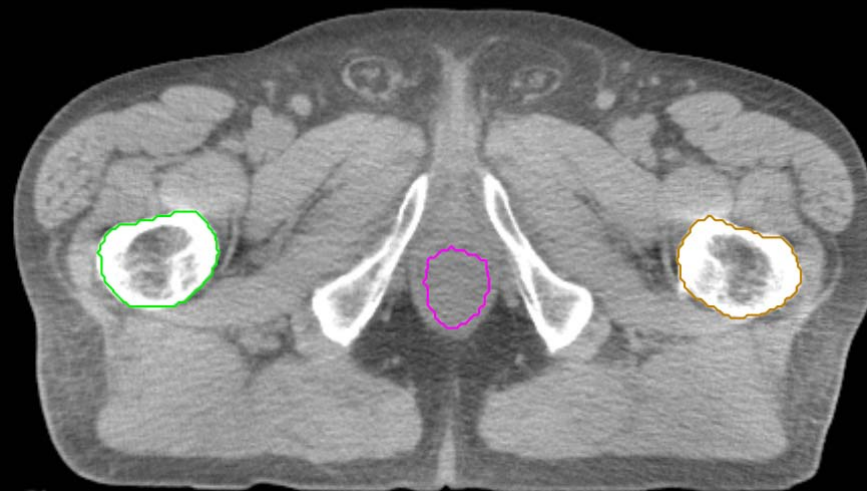
GU:

- Rectum
- BowelBag



GU/GI:

- PenileBulb
- Bladder
- SeminalVesc
- Prostate
- Femur\_L
- Femur\_R

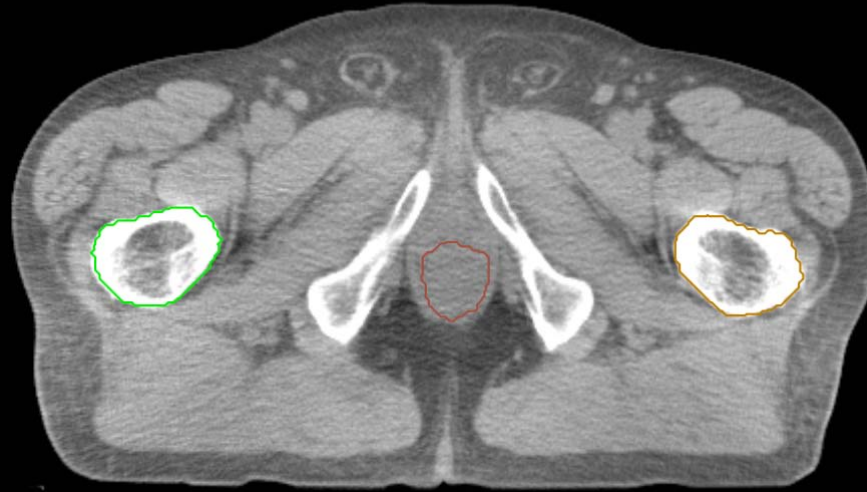


GI:

- Small Bowel
- AnoRectumSig
- Colon
- Mesorectum

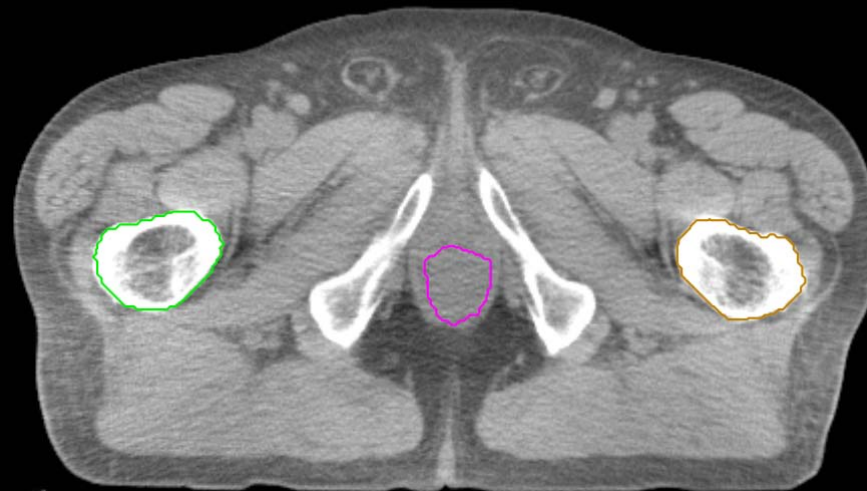
GU:

- Rectum
- BowelBag



GU/GI:

- PenileBulb
- Bladder
- SeminalVesc
- Prostate
- Femur\_L
- Femur\_R

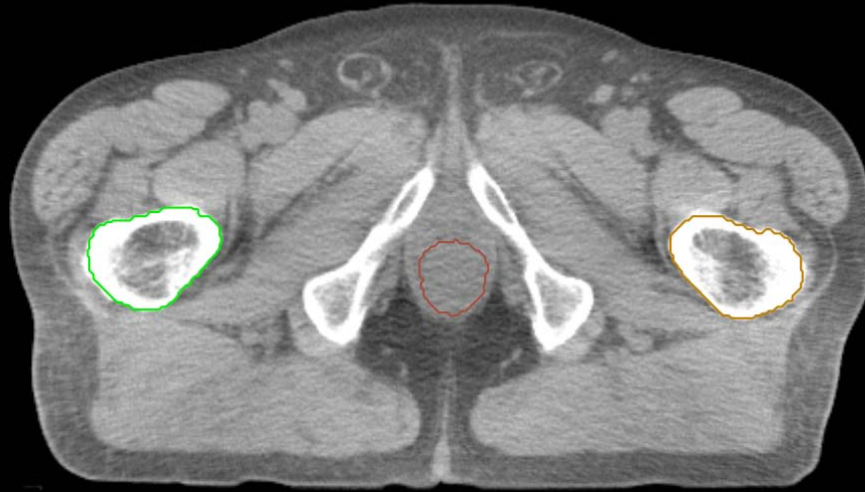


GI:

- Small Bowel
- AnoRectumSig
- Colon
- Mesorectum

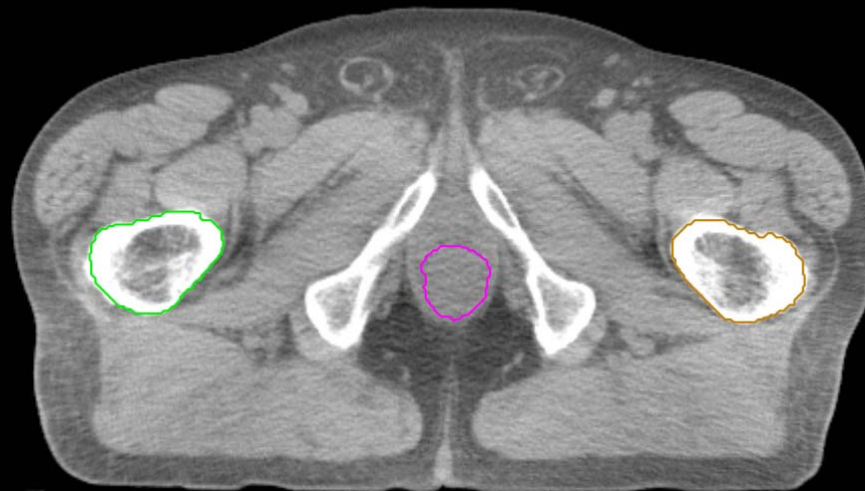
GU:

- Rectum
- BowelBag



GU/GI:

- PenileBulb
- Bladder
- SeminalVesc
- Prostate
- Femur\_L
- Femur\_R

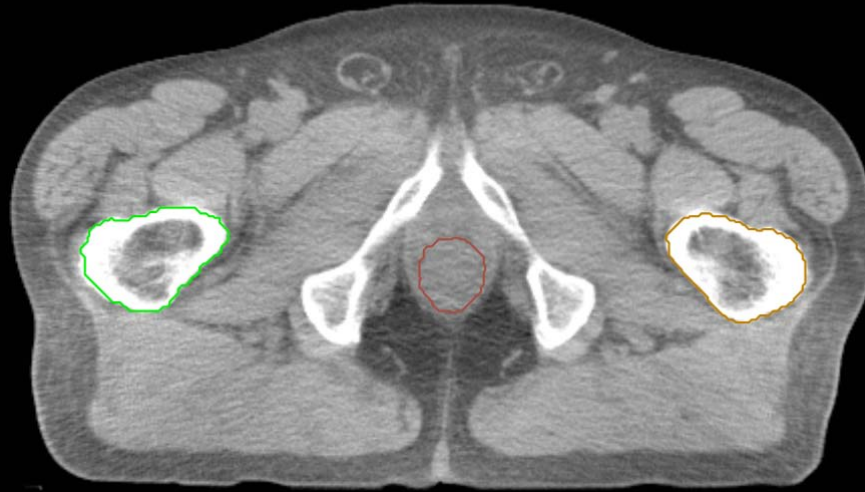


GI:

- Small Bowel
- AnoRectumSig
- Colon
- Mesorectum

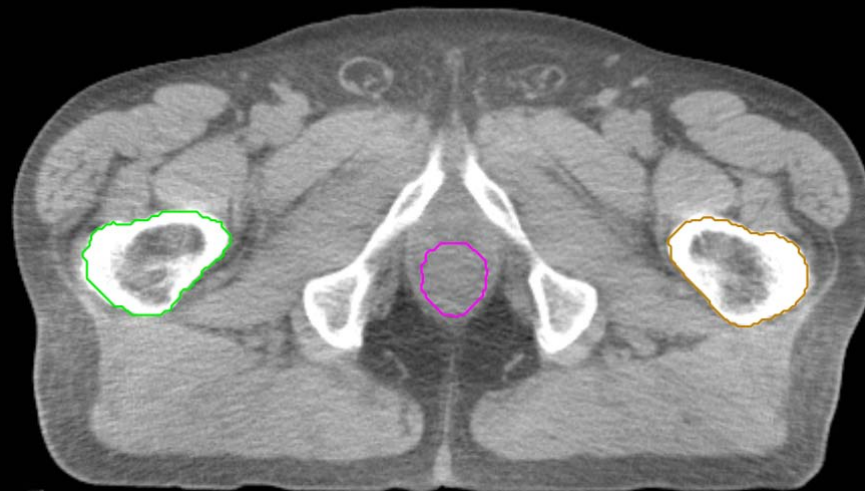
GU:

- Rectum
- BowelBag



GU/GI:

- PenileBulb
- Bladder
- SeminalVesc
- Prostate
- Femur\_L
- Femur\_R



GI:

- Small Bowel
- AnoRectumSig
- Colon
- Mesorectum

GU:

- Rectum
- BowelBag

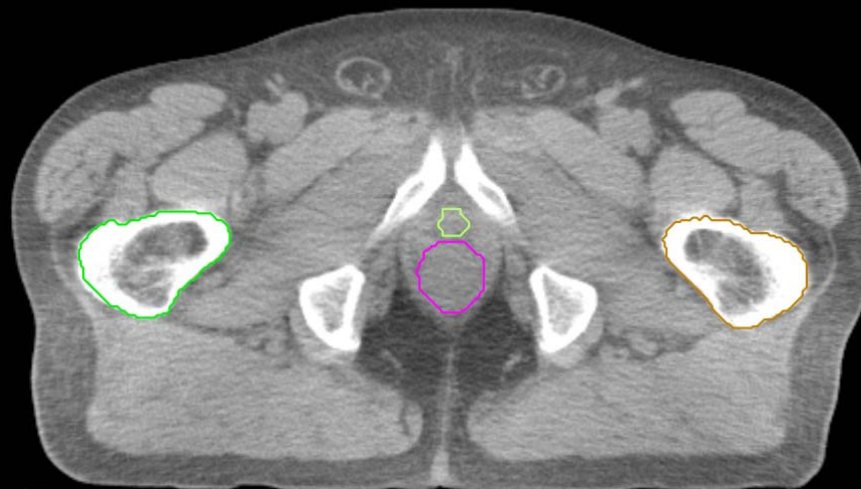
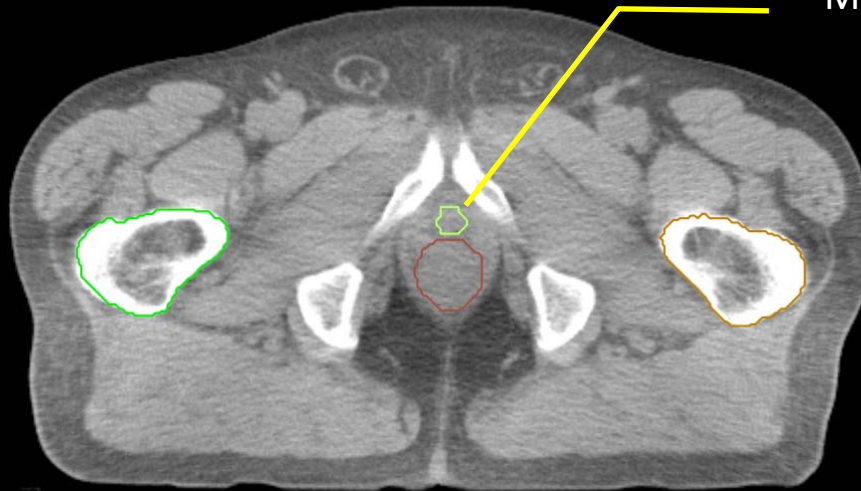
GU/GI:

- PenileBulb
- Bladder
- SeminalVesc
- Prostate
- Femur\_L
- Femur\_R

GI:

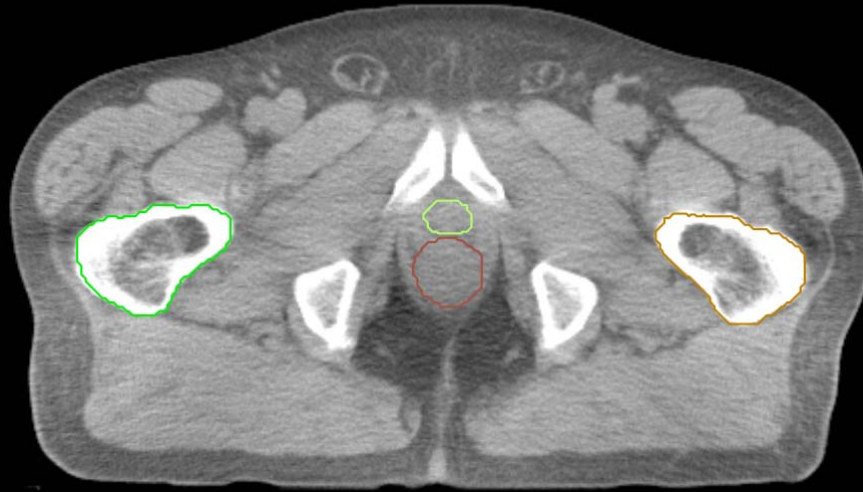
- Small Bowel
- AnoRectumSig
- Colon
- Mesorectum

MRI can help identify the prostate apex



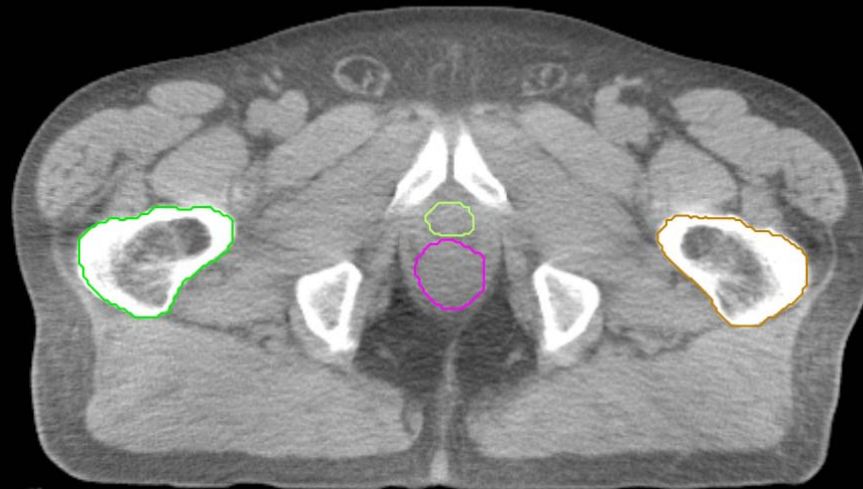GU:

- Rectum
- BowelBag



GU/GI:

- PenileBulb
- Bladder
- SeminalVesc
- Prostate
- Femur\_L
- Femur\_R

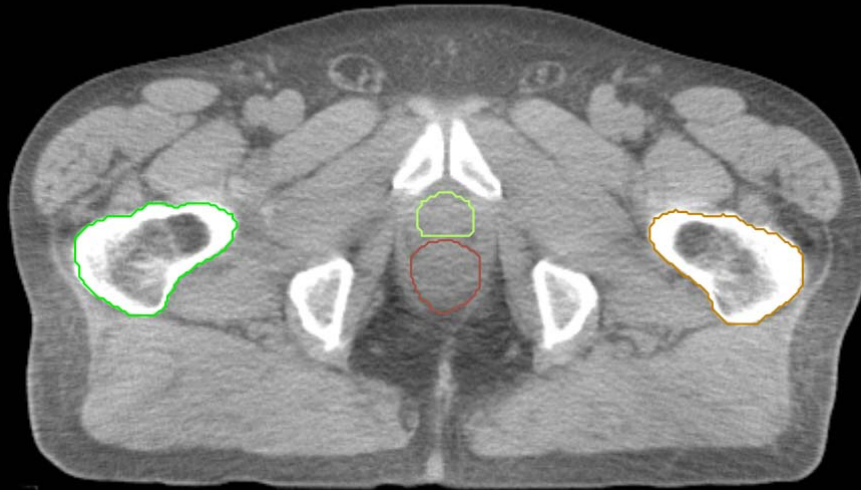


GI:

- Small Bowel
- AnoRectumSig
- Colon
- Mesorectum

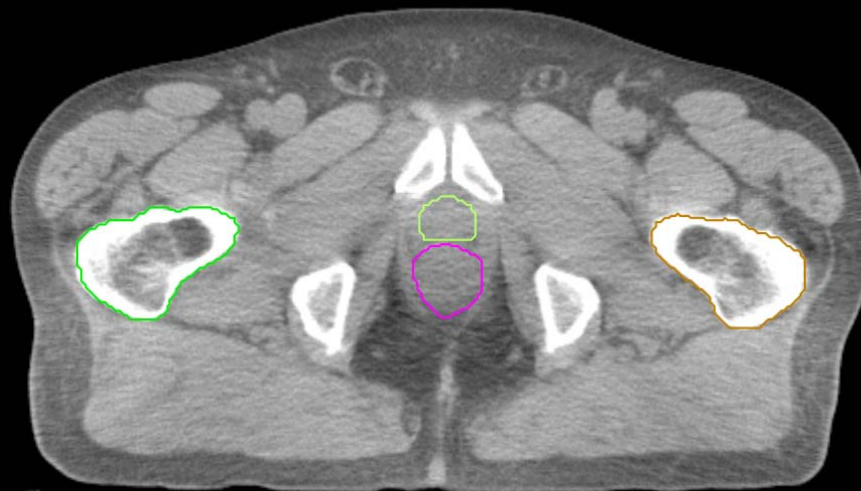
GU:

- Rectum
- BowelBag



GU/GI:

- PenileBulb
- Bladder
- SeminalVesc
- Prostate
- Femur\_L
- Femur\_R



GI:

- Small Bowel
- AnoRectumSig
- Colon
- Mesorectum



GU:

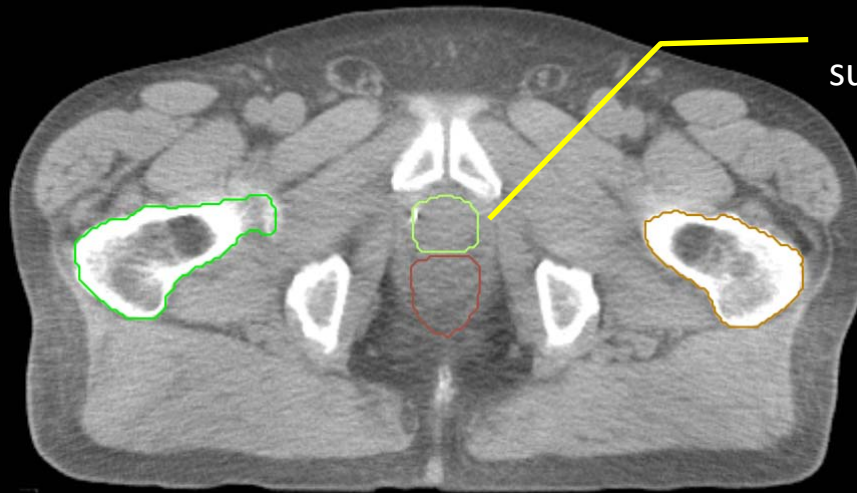
- Rectum
- BowelBag

GU/GI:

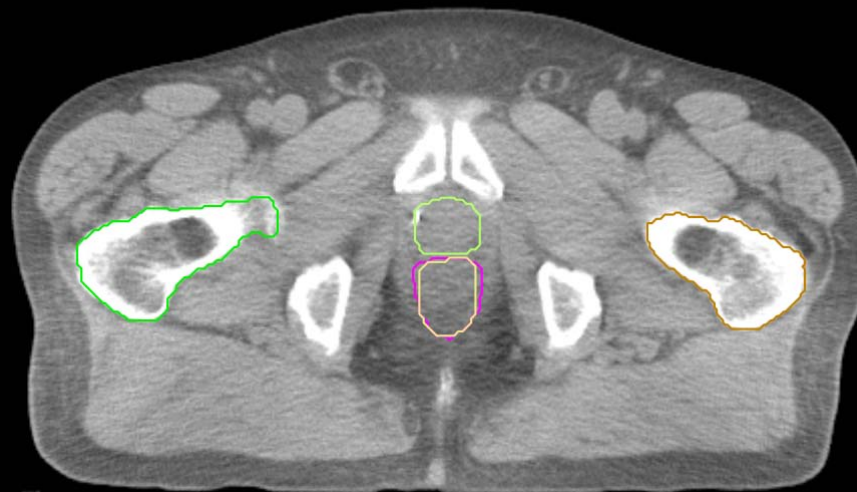- PenileBulb
- Bladder
- SeminalVesc
- Prostate
- Femur\_L
- Femur\_R

GI:

- Small Bowel
- AnoRectumSig
- Colon
- Mesorectum

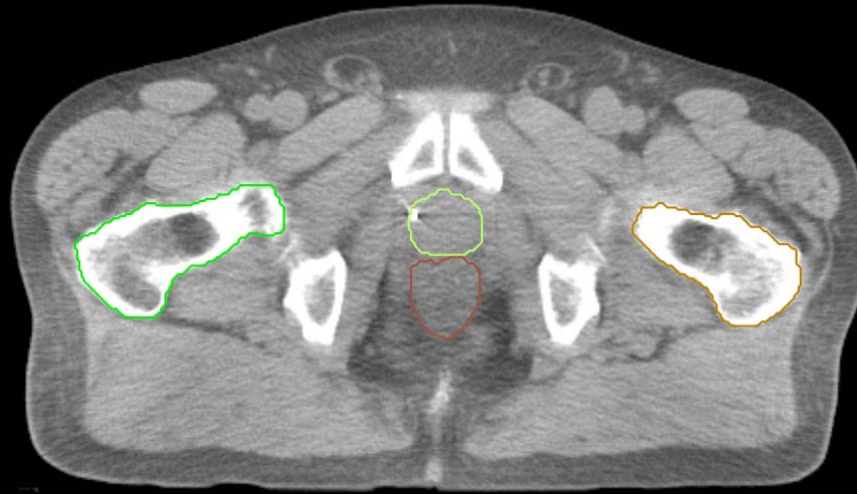

Prostate excludes  
surrounding pelvic muscles



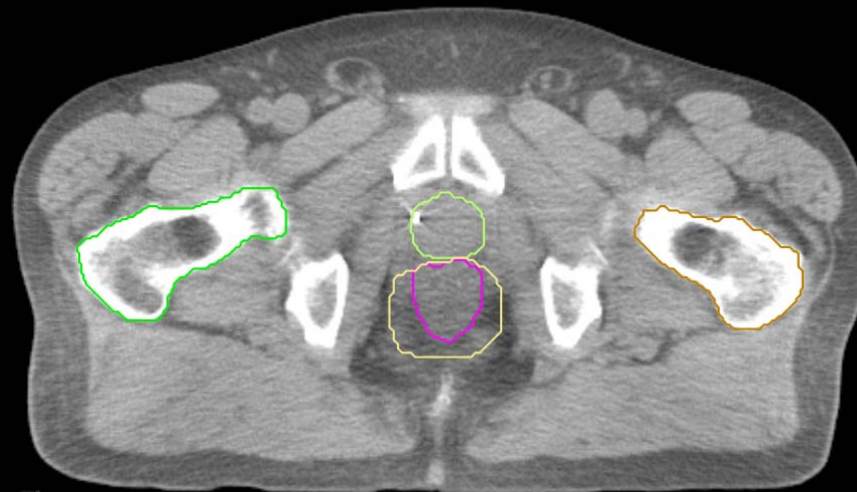GU:

- Rectum
- BowelBag



GU/GI:

- PenileBulb
- Bladder
- SeminalVesc
- Prostate
- Femur\_L
- Femur\_R

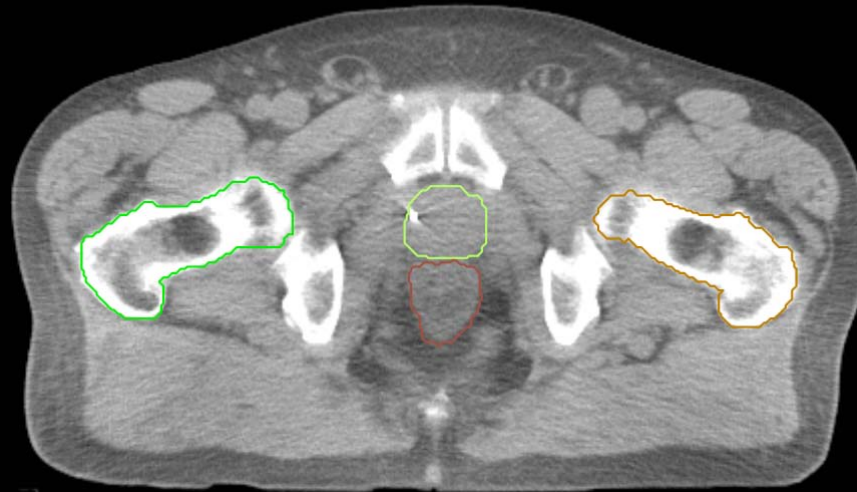


GI:

- Small Bowel
- AnoRectumSig
- Colon
- Mesorectum

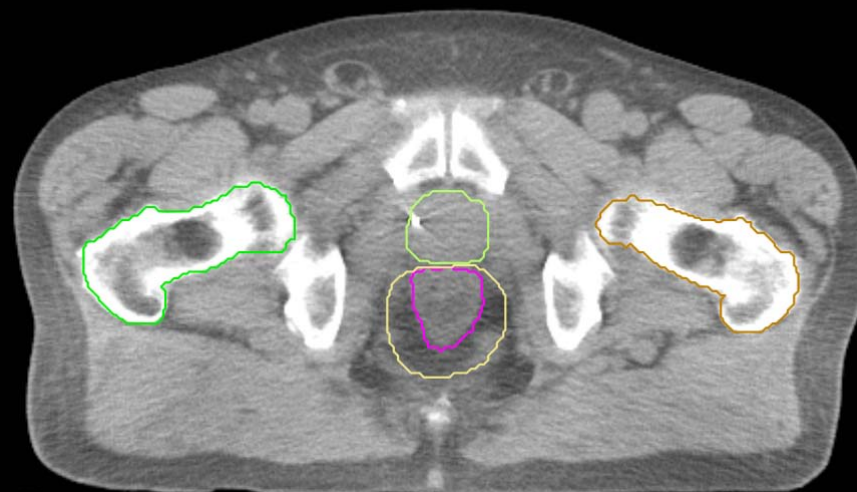GU:

- Rectum
- BowelBag



GU/GI:

- PenileBulb
- Bladder
- SeminalVesc
- Prostate
- Femur\_L
- Femur\_R

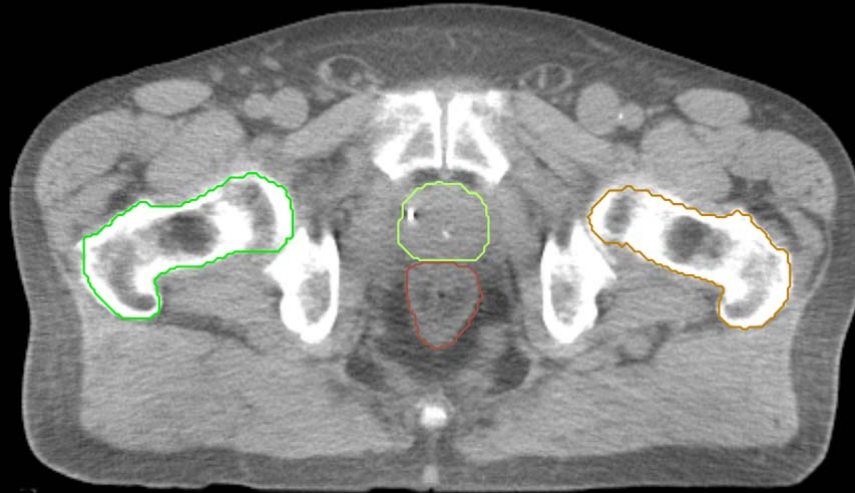


GI:

- Small Bowel
- AnoRectumSig
- Colon
- Mesorectum

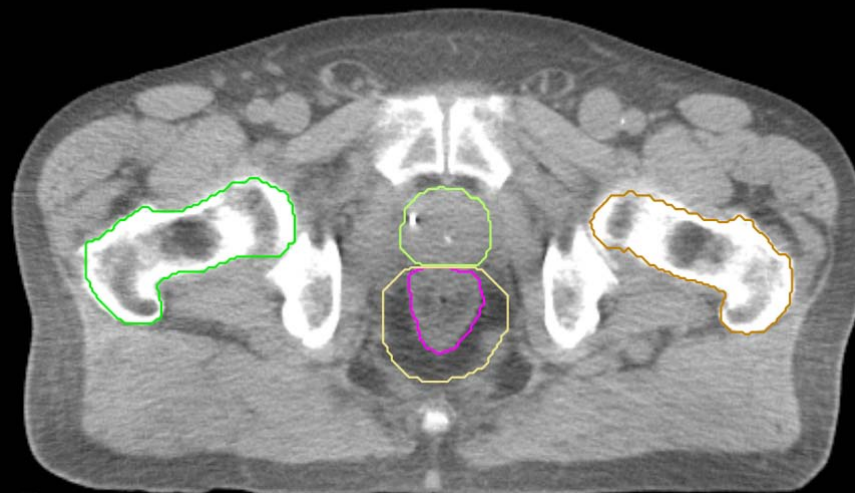GU:

- Rectum
- BowelBag



GU/GI:

- PenileBulb
- Bladder
- SeminalVesc
- Prostate
- Femur\_L
- Femur\_R

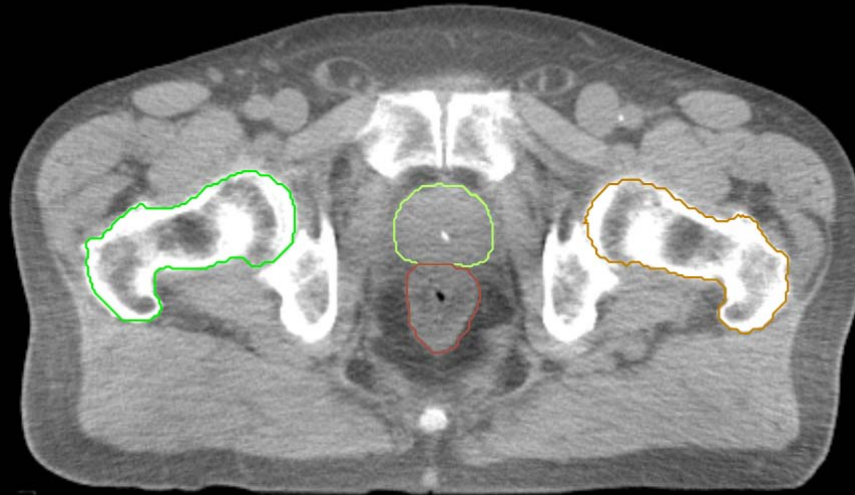


GI:

- Small Bowel
- AnoRectumSig
- Colon
- Mesorectum

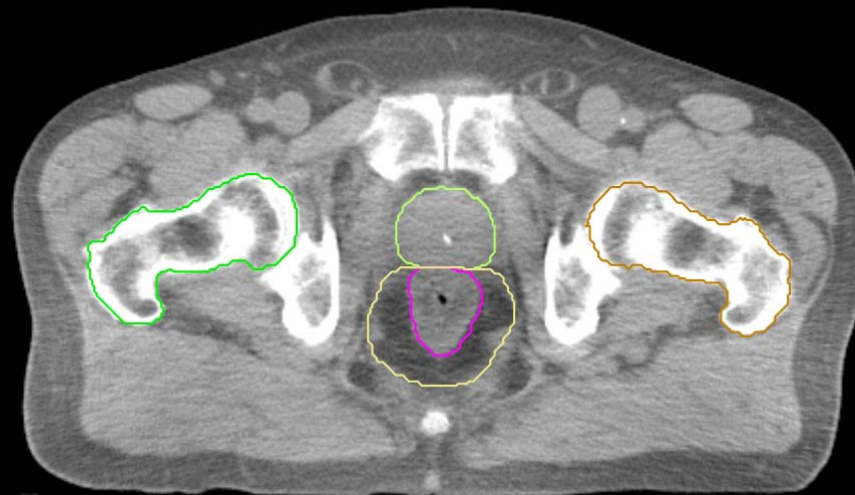
GU:

- Rectum
- BowelBag



GU/GI:

- PenileBulb
- Bladder
- SeminalVesc
- Prostate
- Femur\_L
- Femur\_R

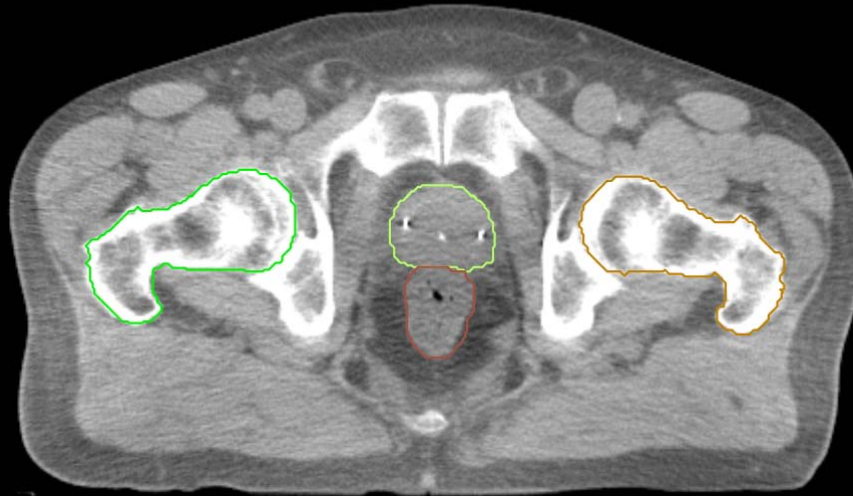


GI:

- Small Bowel
- AnoRectumSig
- Colon
- Mesorectum

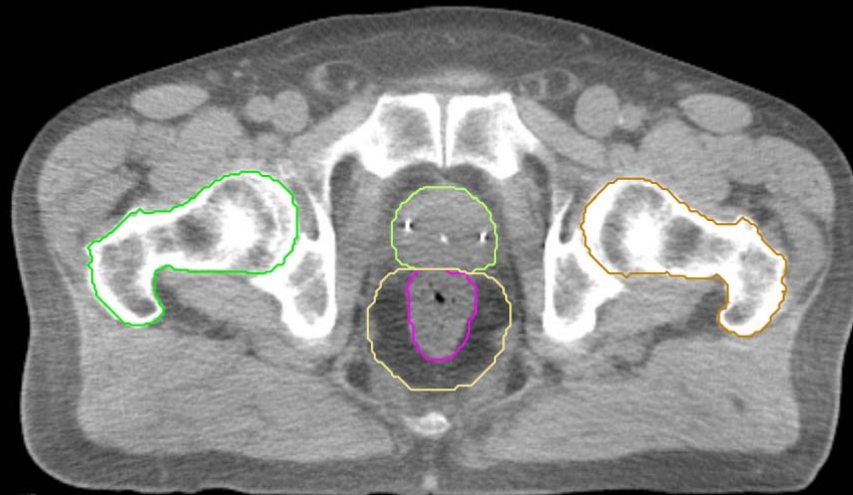
GU:

- Rectum
- BowelBag



GU/GI:

- PenileBulb
- Bladder
- SeminalVesc
- Prostate
- Femur\_L
- Femur\_R

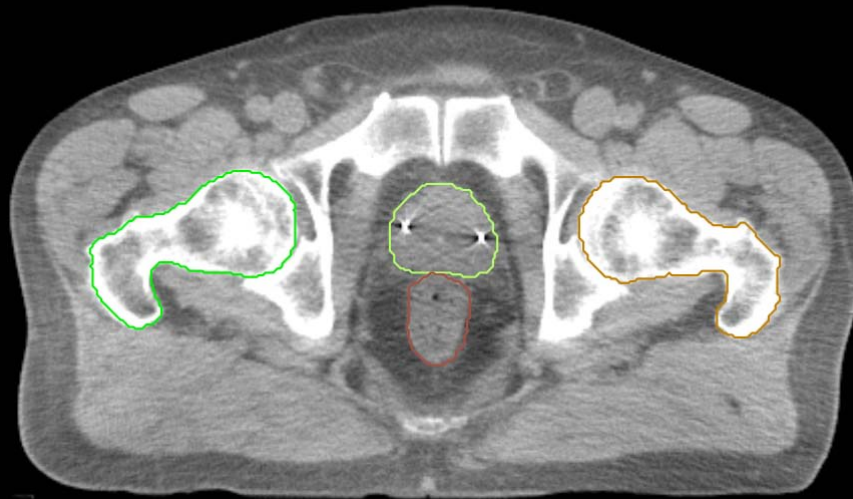


GI:

- Small Bowel
- AnoRectumSig
- Colon
- Mesorectum

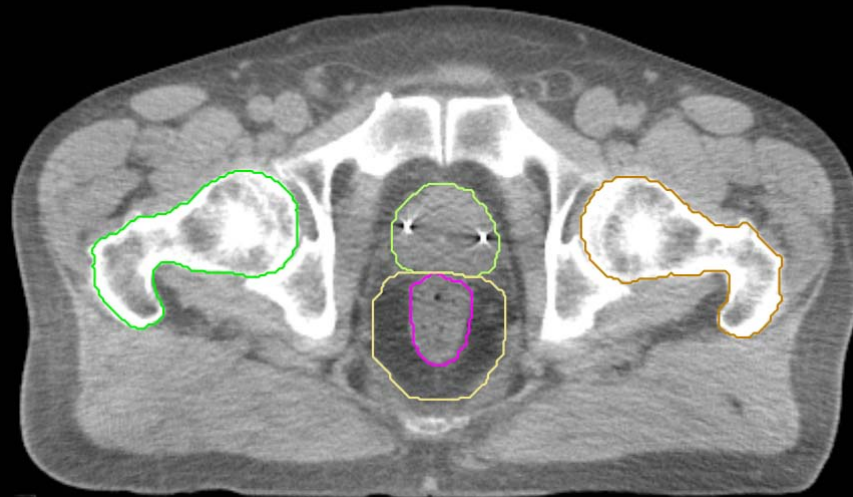
GU:

- Rectum
- BowelBag



GU/GI:

- PenileBulb
- Bladder
- SeminalVesc
- Prostate
- Femur\_L
- Femur\_R

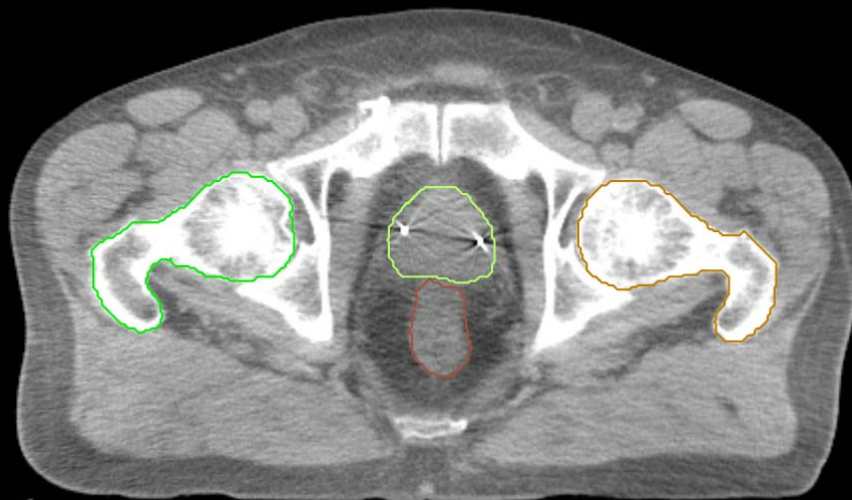


GI:

- Small Bowel
- AnoRectumSig
- Colon
- Mesorectum

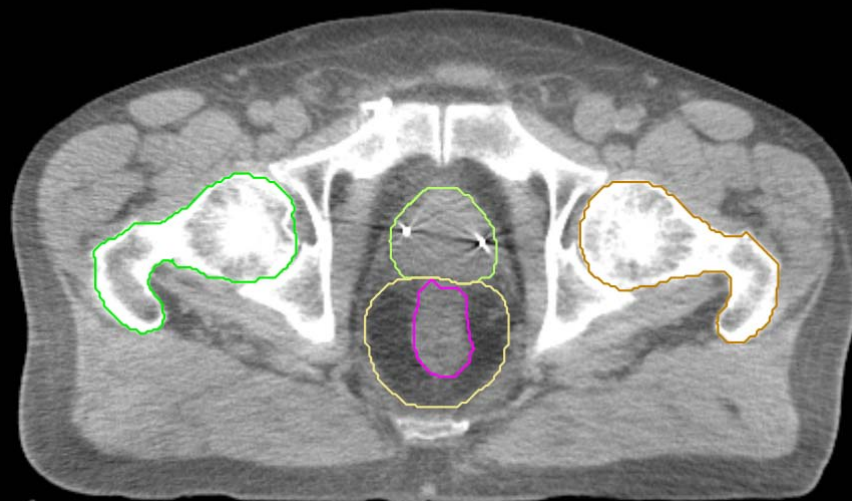
GU:

- Rectum
- BowelBag



GU/GI:

- PenileBulb
- Bladder
- SeminalVesc
- Prostate
- Femur\_L
- Femur\_R



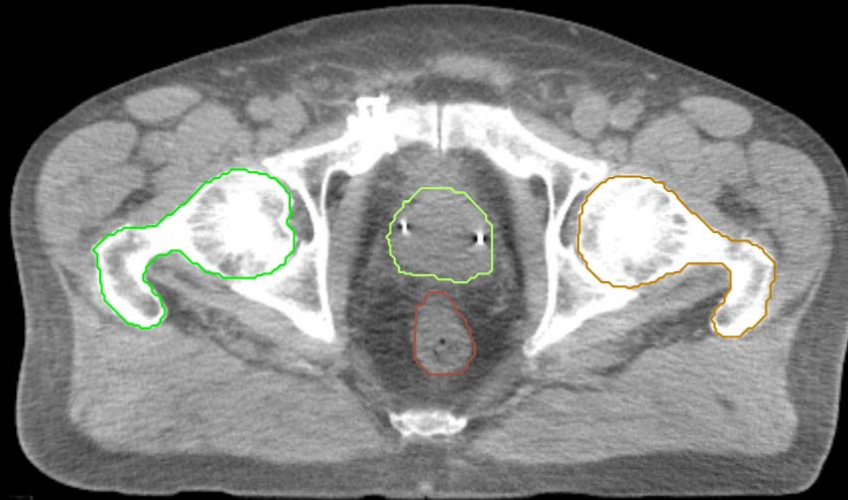
GI:

- Small Bowel
- AnoRectumSig
- Colon
- Mesorectum



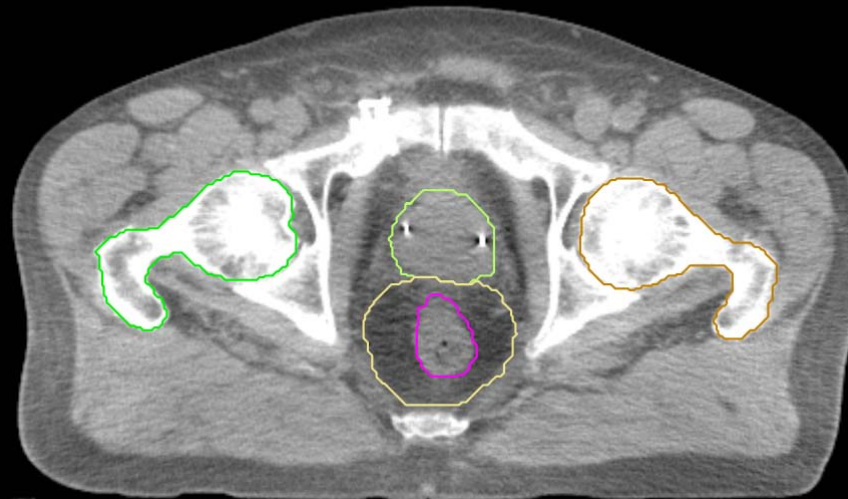
GU:

- Rectum
- BowelBag



GU/GI:

- PenileBulb
- Bladder
- SeminalVesc
- Prostate
- Femur\_L
- Femur\_R



GI:

- Small Bowel
- AnoRectumSig
- Colon
- Mesorectum

GU:

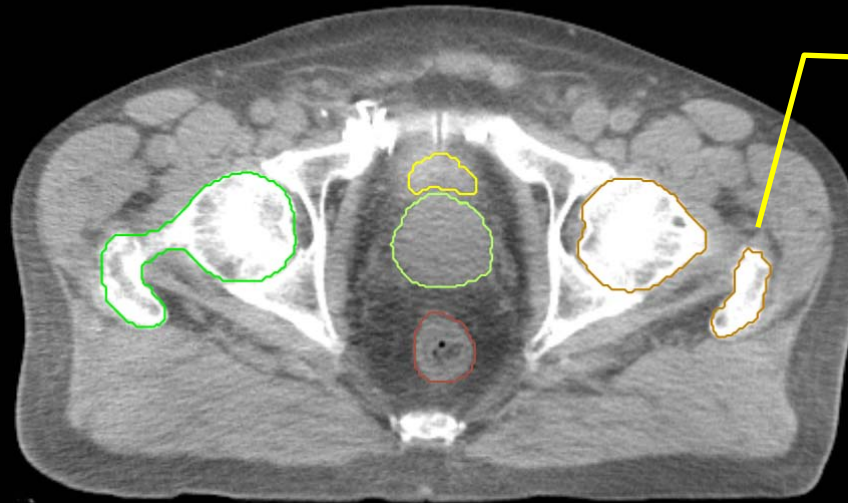
- Rectum
- BowelBag

GU/GI:

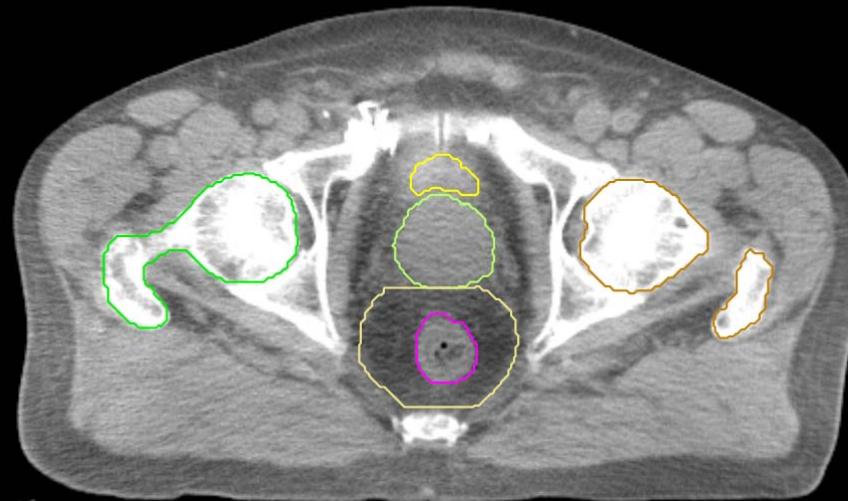
- PenileBulb
- Bladder
- SeminalVesc
- Prostate
- Femur\_L
- Femur\_R

GI:

- Small Bowel
- AnoRectumSig
- Colon
- Mesorectum



this is also part of Femur\_L



GU:

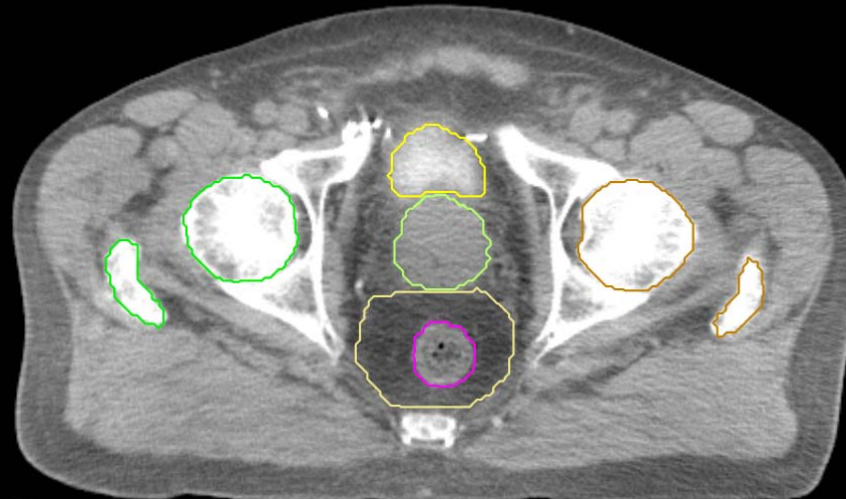
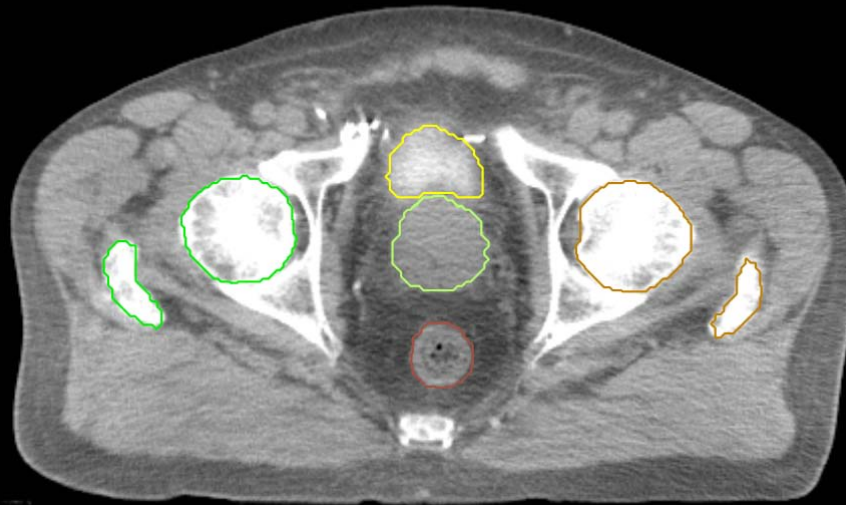
- Rectum
- BowelBag

GU/GI:

- PenileBulb
- Bladder
- SeminalVesc
- Prostate
- Femur\_L
- Femur\_R

GI:

- Small Bowel
- AnoRectumSig
- Colon
- Mesorectum



GU:

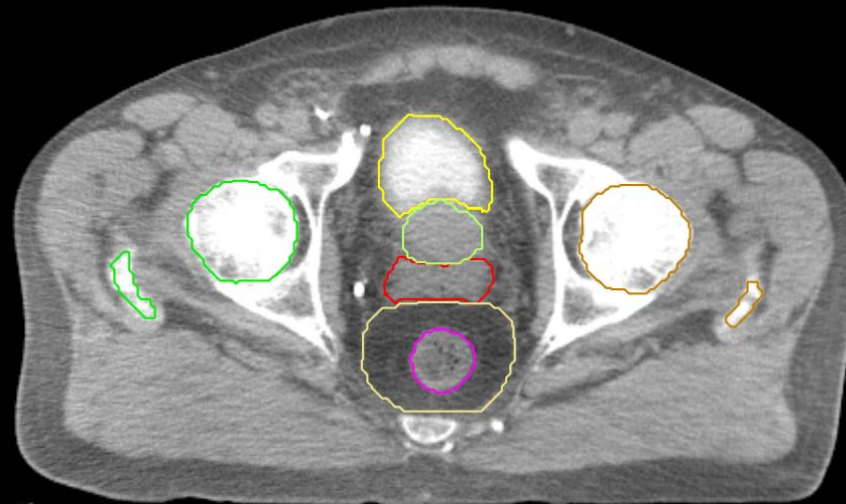
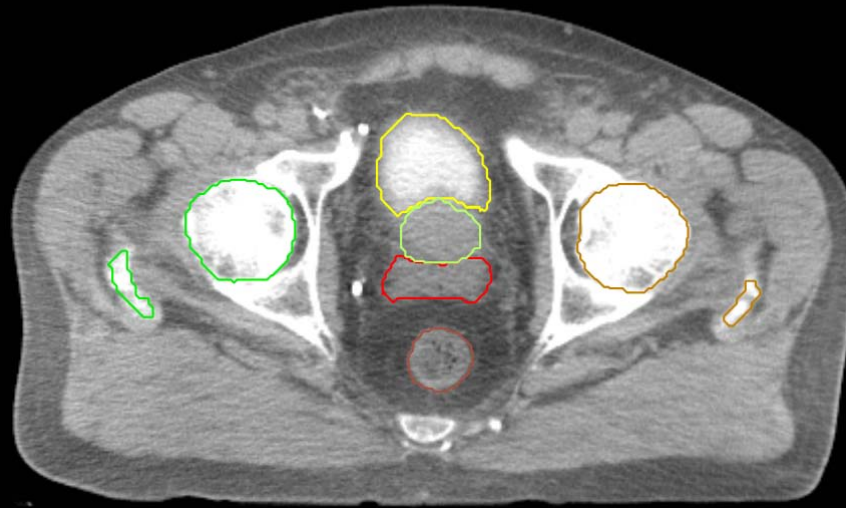
- Rectum
- BowelBag

GU/GI:

- PenileBulb
- Bladder
- SeminalVesc
- Prostate
- Femur\_L
- Femur\_R

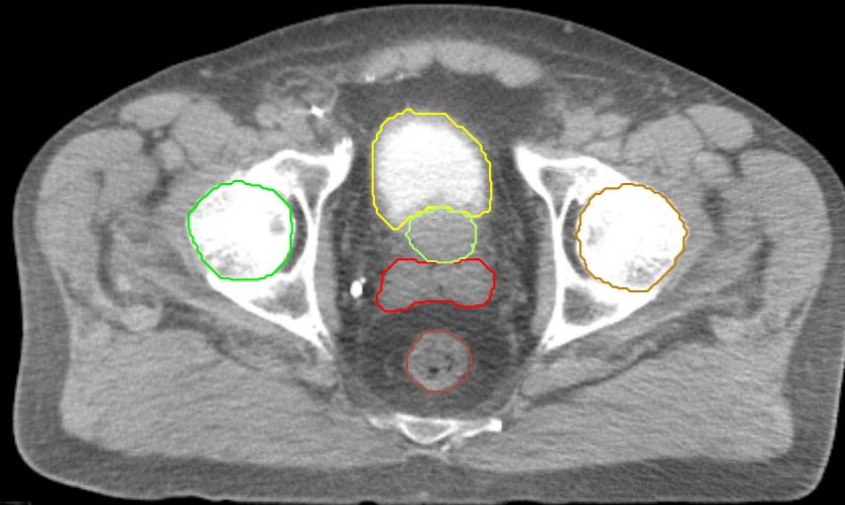
GI:

- Small Bowel
- AnoRectumSig
- Colon
- Mesorectum



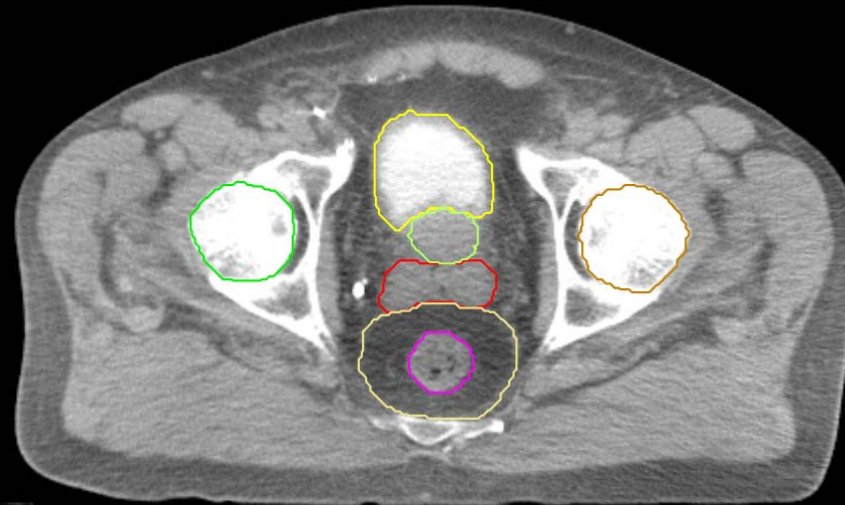
GU:

- Rectum
- BowelBag



GU/GI:

- PenileBulb
- Bladder
- SeminalVesc
- Prostate
- Femur\_L
- Femur\_R



GI:

- Small Bowel
- AnoRectumSig
- Colon
- Mesorectum

GU:

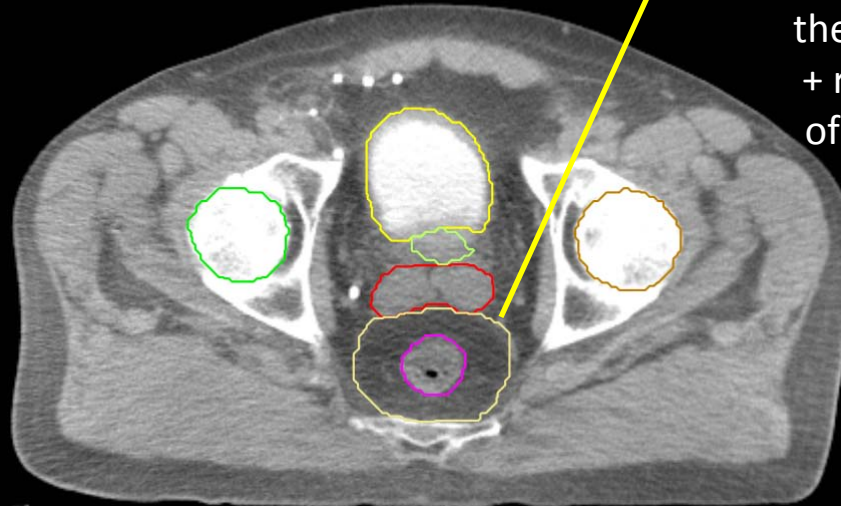
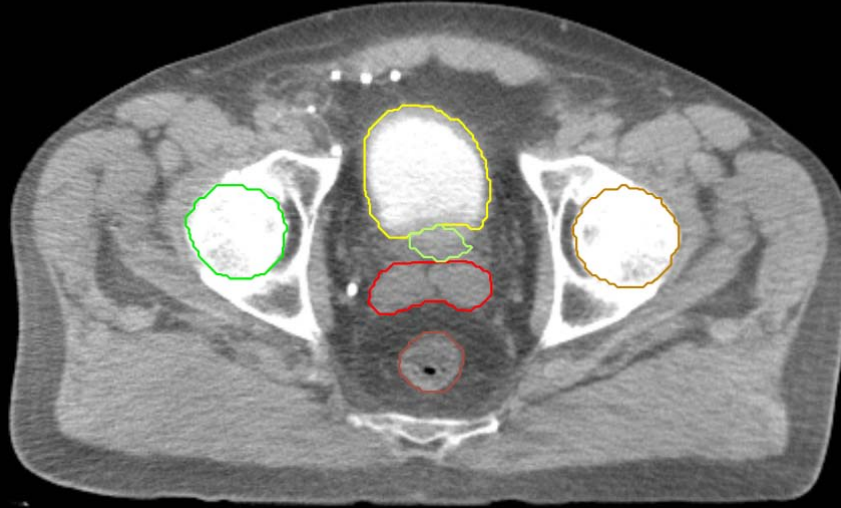
- Rectum
- BowelBag

GU/GI:

- PenileBulb
- Bladder
- SeminalVesc
- Prostate
- Femur\_L
- Femur\_R

GI:

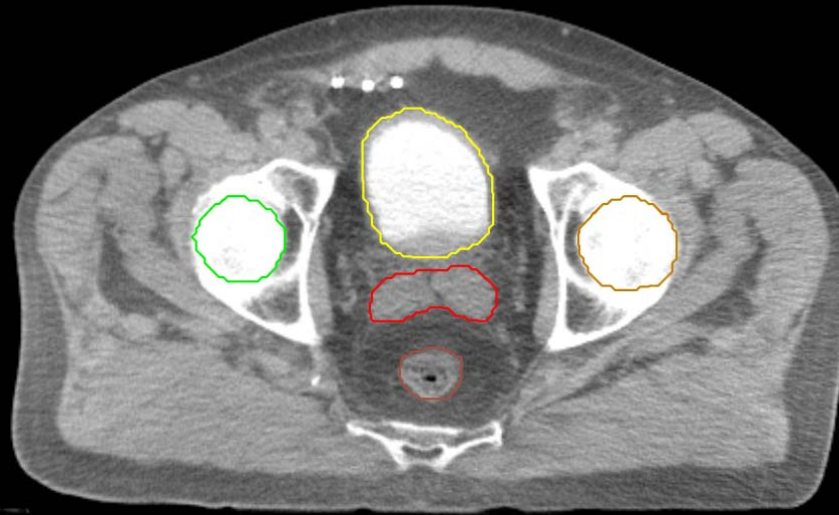
- Small Bowel
- AnoRectumSig
- Colon
- Mesorectum



The mesorectal compartment is a target structure for anal and rectal cancer. For these entities, the AnoRectoSig (anus + rectum + rectosigmoid), unlike the rest of the alimentary canal, is NOT an avoidance structure.

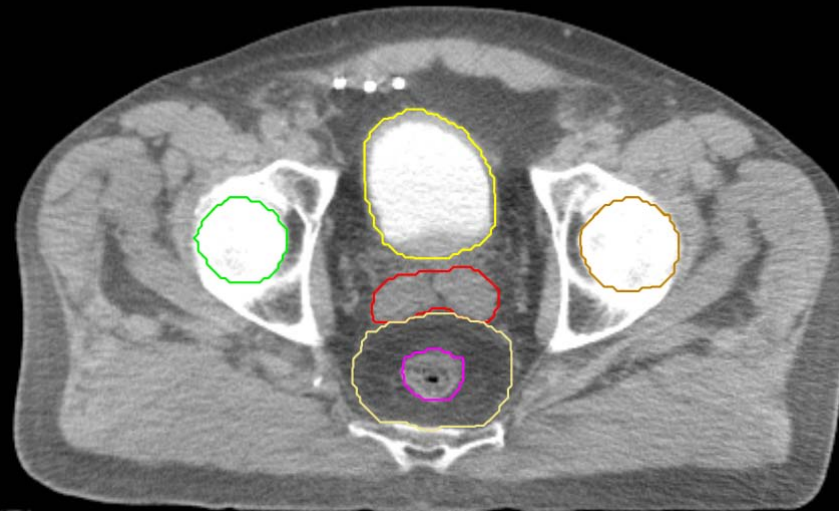
GU:

- Rectum
- BowelBag



GU/GI:

- PenileBulb
- Bladder
- SeminalVesc
- Prostate
- Femur\_L
- Femur\_R



GI:

- Small Bowel
- AnoRectumSig
- Colon
- Mesorectum

GU:

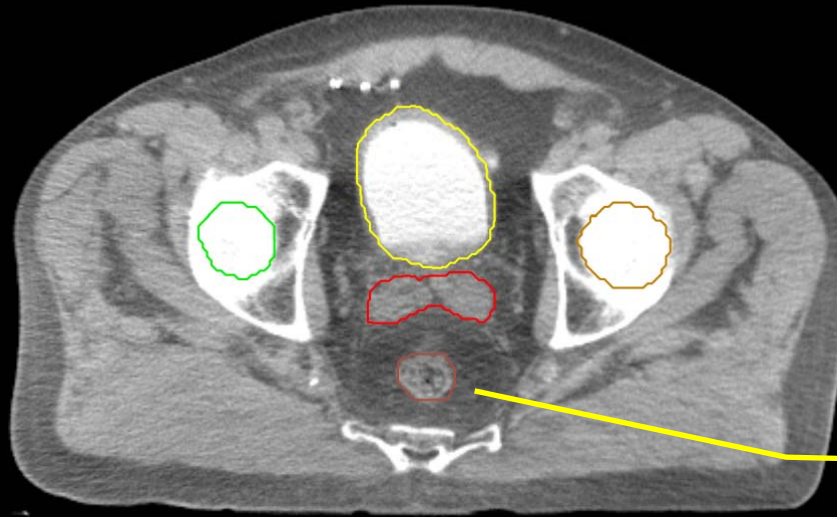
- Rectum
- BowelBag

GU/GI:

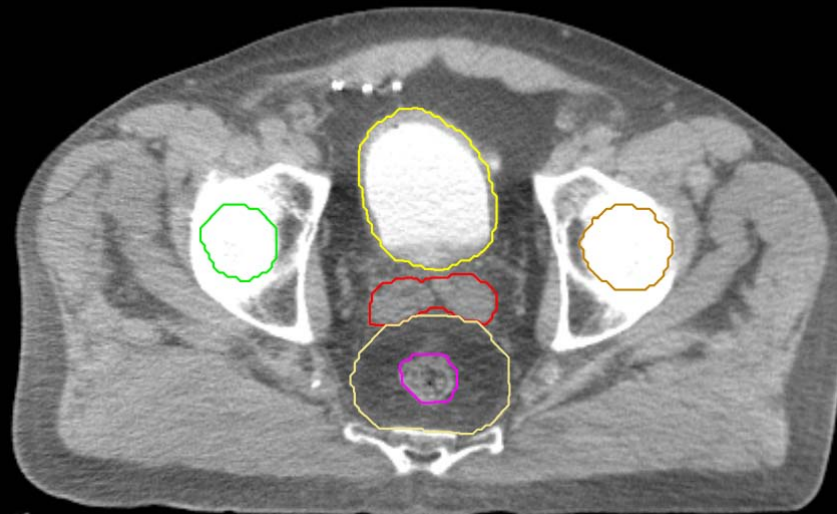
- PenileBulb
- Bladder
- SeminalVesc
- Prostate
- Femur\_L
- Femur\_R

GI:

- Small Bowel
- AnoRectumSig
- Colon
- Mesorectum



Rectum stops here since this is the last cut it has a round shape

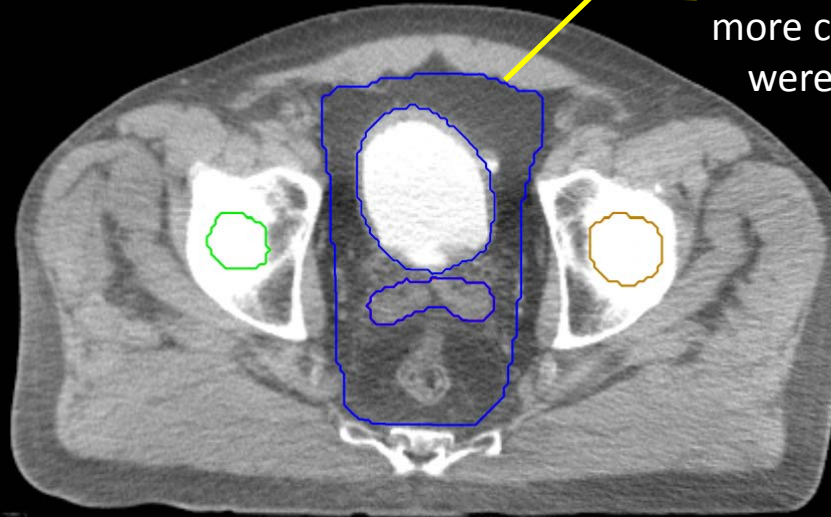




GU:

- Rectum
- BowelBag

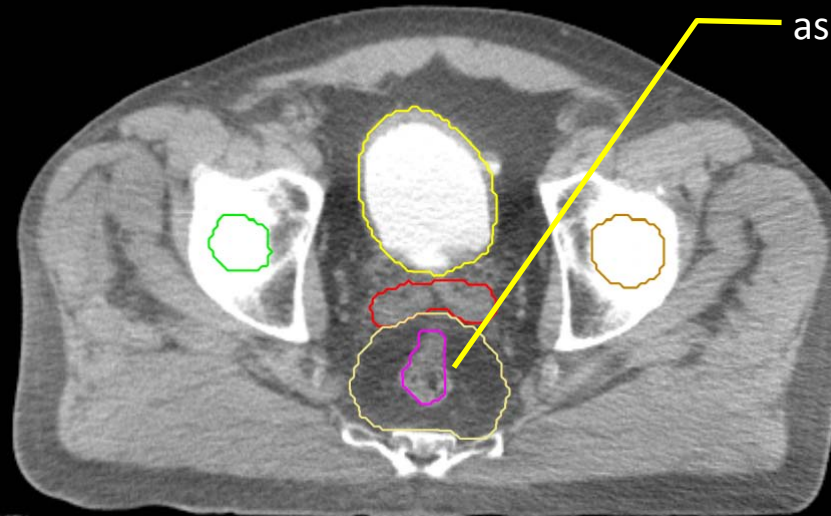
in this case, the BowelBag starts above Rectum (it could have started more caudal if SmallBowel or Colon were visible at an inferior level)



GU/GI:

- PenileBulb
- Bladder
- SeminalVesc
- Prostate
- Femur\_L
- Femur\_R

rectum becomes elongated as it connects anteriorly with the rectosigmoid

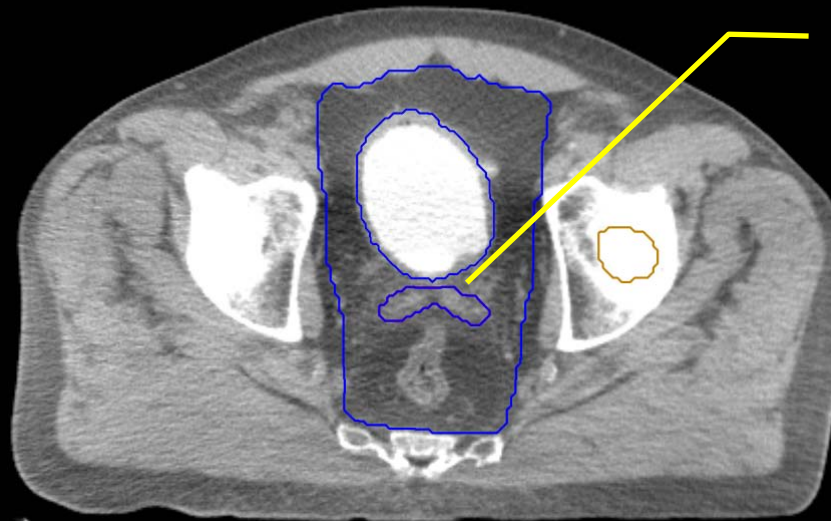


GI:

- Small Bowel
- AnoRectumSig
- Colon
- Mesorectum

GU:

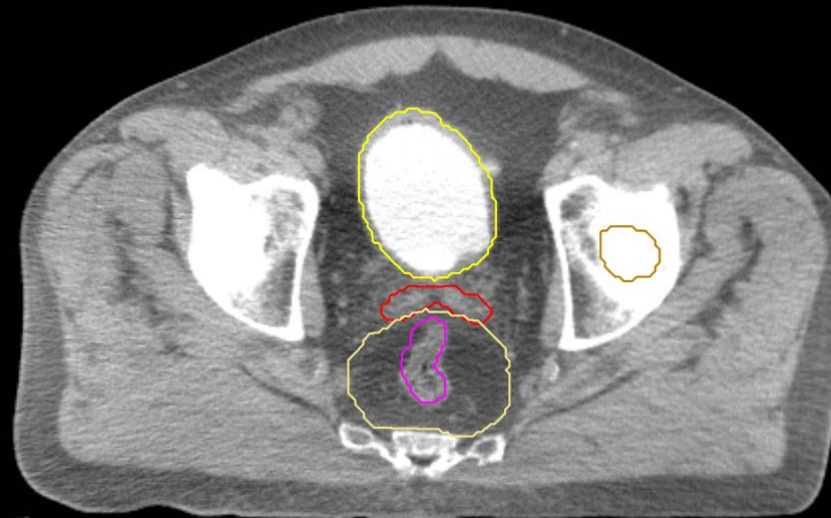
- Rectum
- BowelBag



Bladder and SeminalVesc  
excluded from BowelBag

GU/GI:

- PenileBulb
- Bladder
- SeminalVesc
- Prostate
- Femur\_L
- Femur\_R

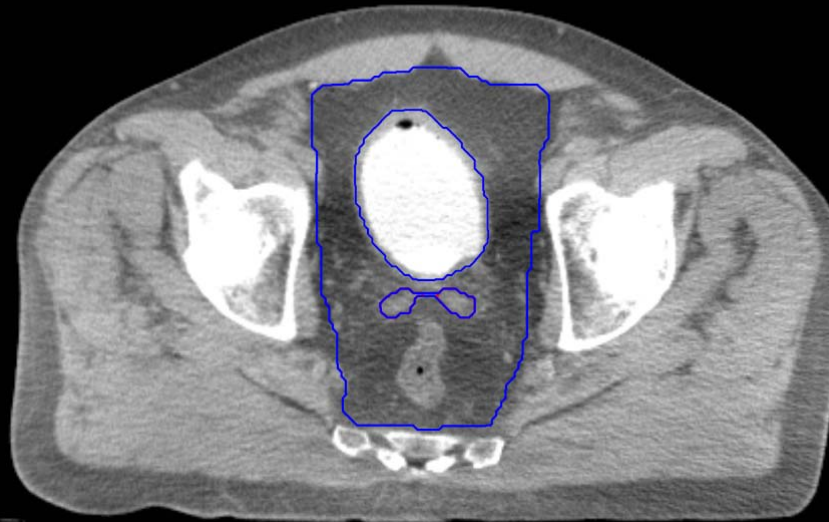


GI:

- Small Bowel
- AnoRectumSig
- Colon
- Mesorectum

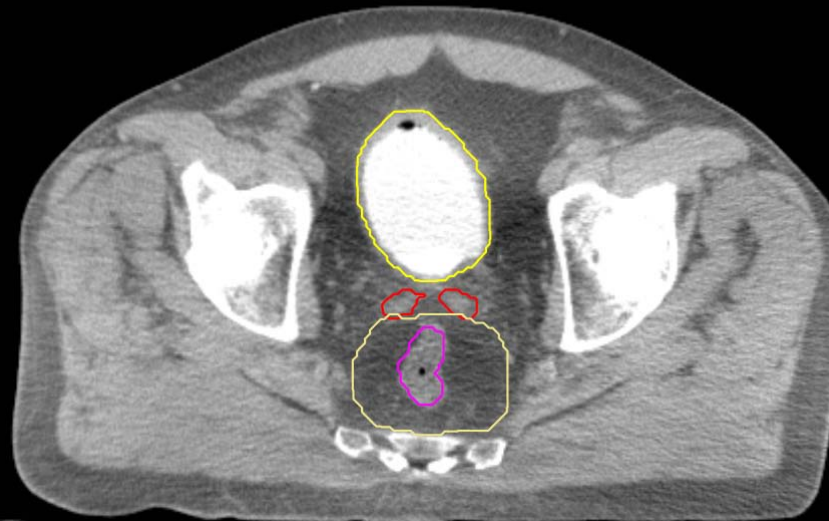
GU:

- Rectum
- BowelBag



GU/GI:

- PenileBulb
- Bladder
- SeminalVesc
- Prostate
- Femur\_L
- Femur\_R

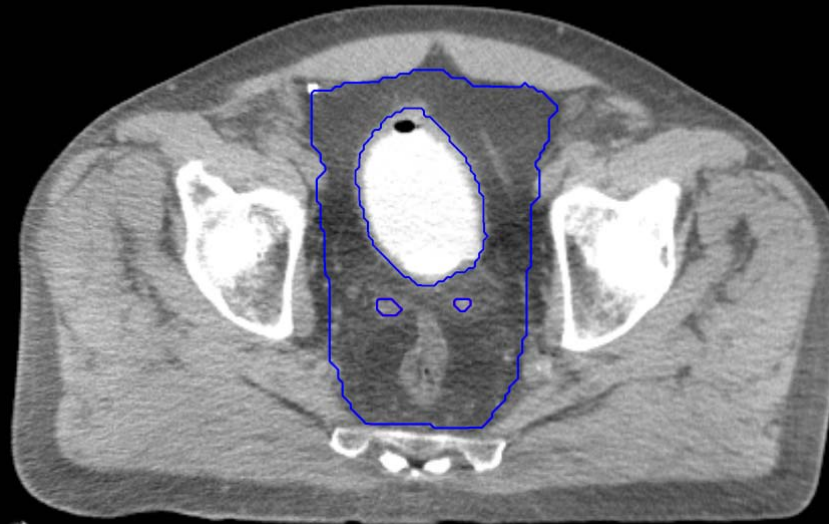


GI:

- Small Bowel
- AnoRectumSig
- Colon
- Mesorectum

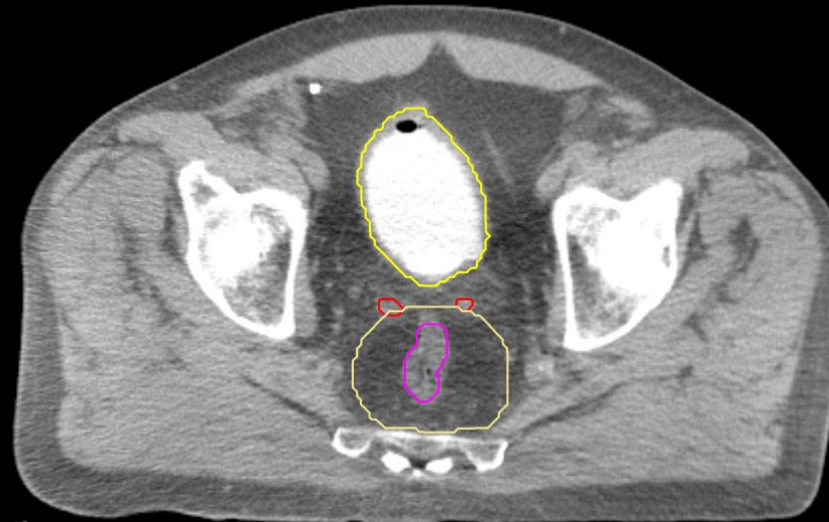GU:

- Rectum
- BowelBag



GU/GI:

- PenileBulb
- Bladder
- SeminalVesc
- Prostate
- Femur\_L
- Femur\_R

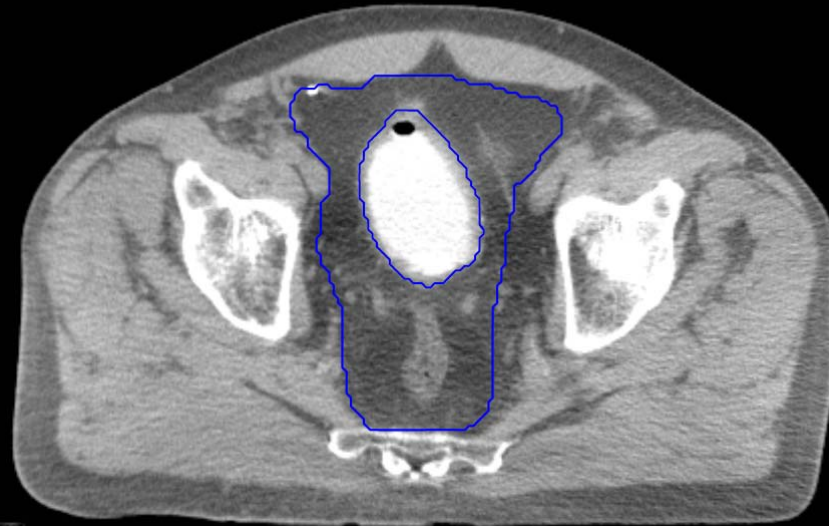

GI:

- Small Bowel
- AnoRectumSig
- Colon
- Mesorectum

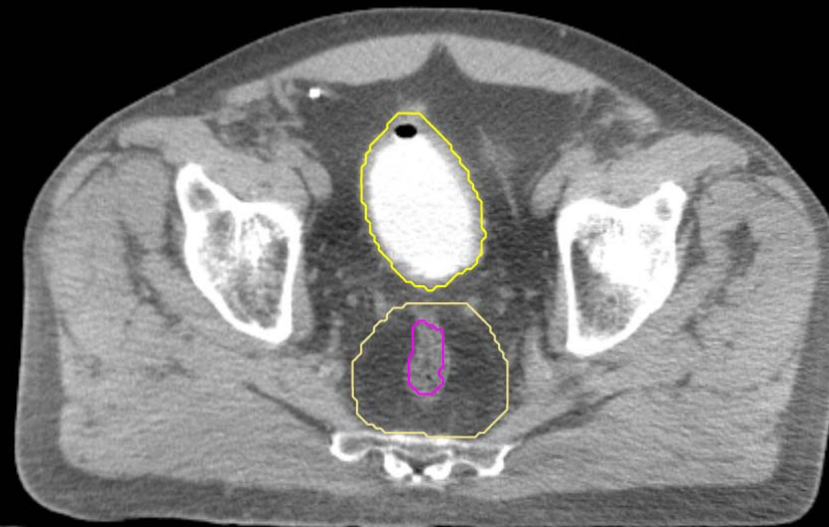GU:

- Rectum
- BowelBag



GU/GI:

- PenileBulb
- Bladder
- SeminalVesc
- Prostate
- Femur\_L
- Femur\_R

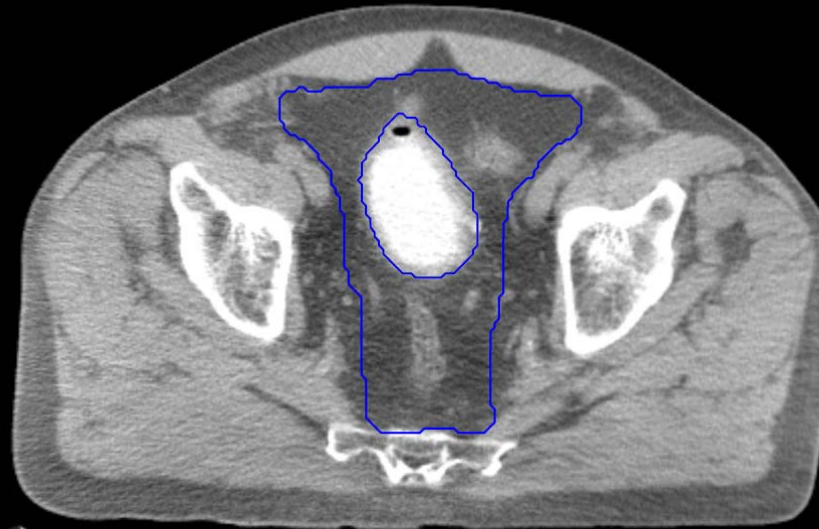


GI:

- Small Bowel
- AnoRectumSig
- Colon
- Mesorectum

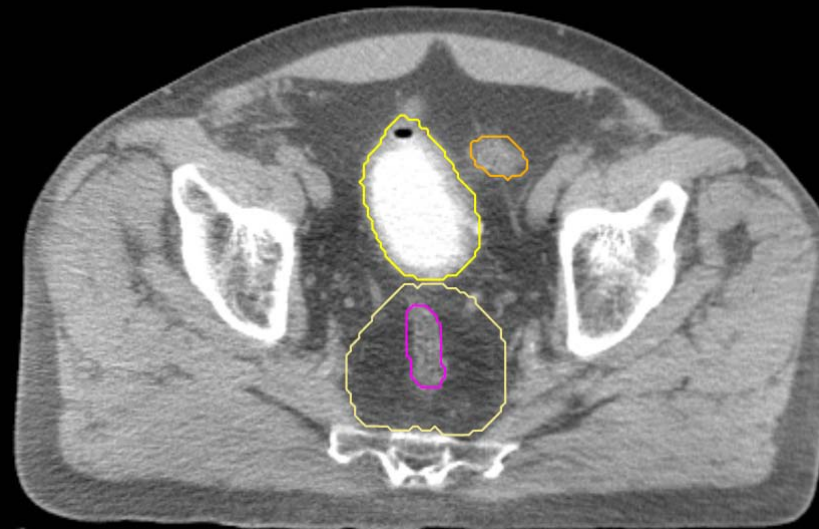
GU:

- Rectum
- BowelBag



GU/GI:

- PenileBulb
- Bladder
- SeminalVesc
- Prostate
- Femur\_L
- Femur\_R

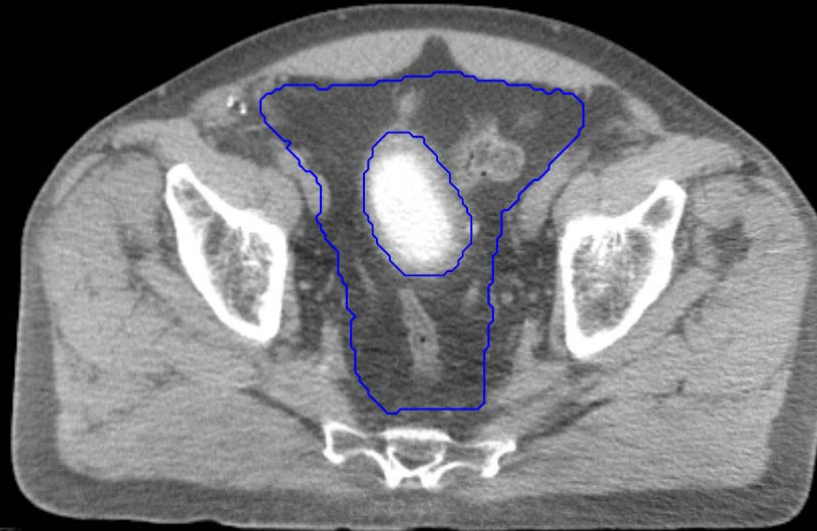


GI:

- Small Bowel
- AnoRectumSig
- Colon
- Mesorectum

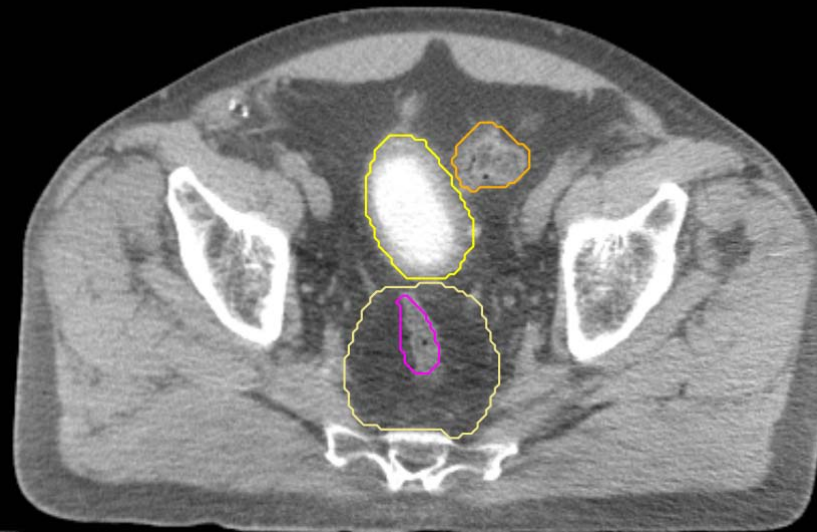
GU:

- Rectum
- BowelBag



GU/GI:

- PenileBulb
- Bladder
- SeminalVesc
- Prostate
- Femur\_L
- Femur\_R

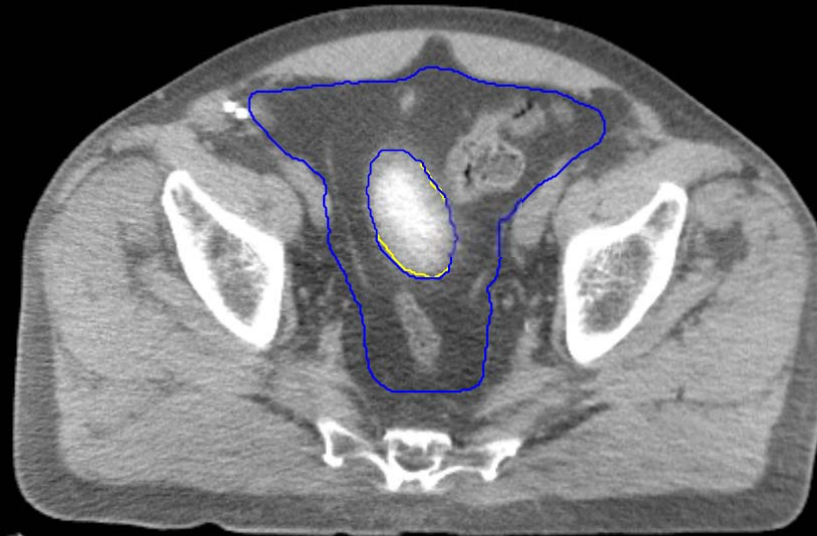


GI:

- Small Bowel
- AnoRectumSig
- Colon
- Mesorectum

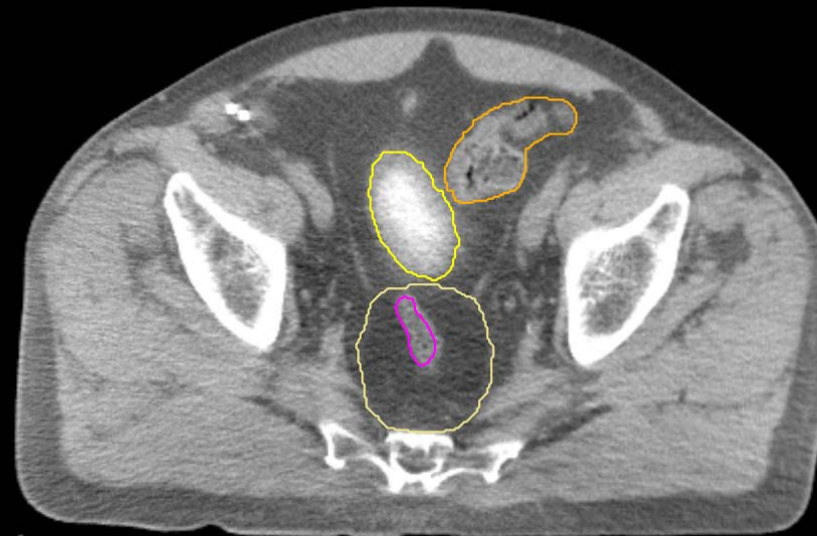
GU:

- Rectum
- BowelBag



GU/GI:

- PenileBulb
- Bladder
- SeminalVesc
- Prostate
- Femur\_L
- Femur\_R



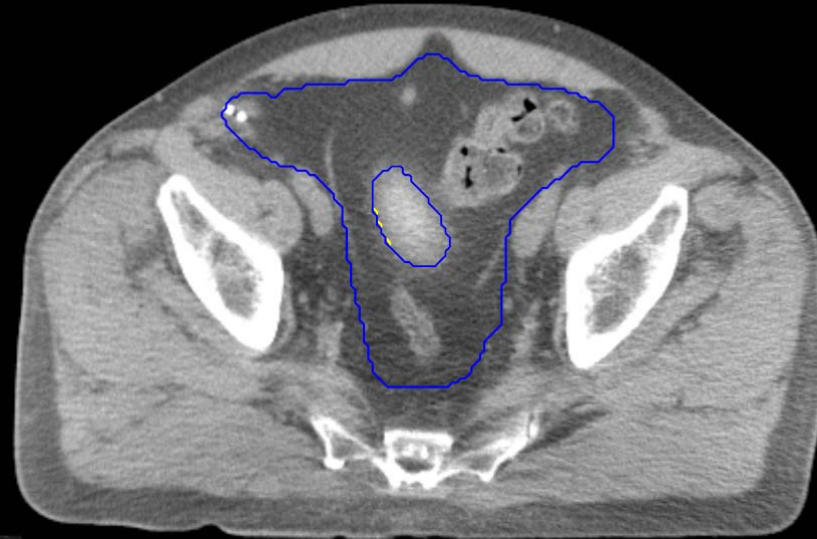GI:

- Small Bowel
- AnoRectumSig
- Colon
- Mesorectum



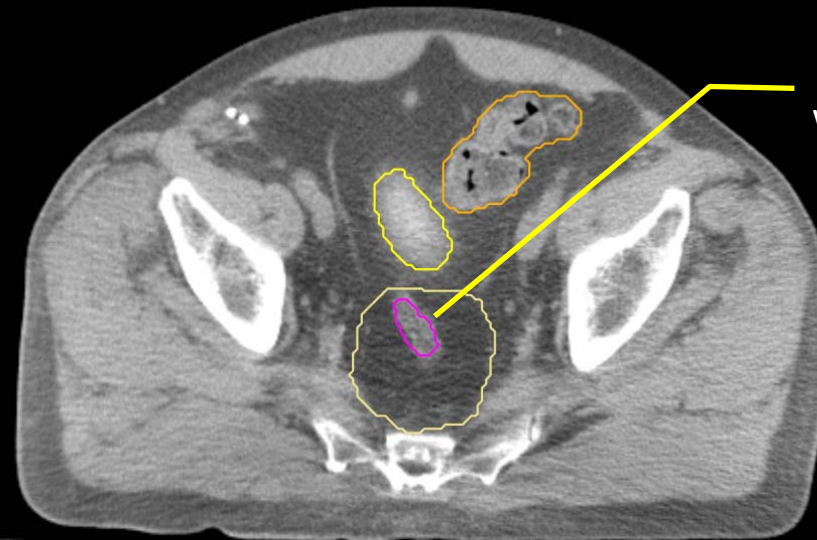
GU:

- Rectum
- BowelBag



GU/GI:

- PenileBulb
- Bladder
- SeminalVesc
- Prostate
- Femur\_L
- Femur\_R



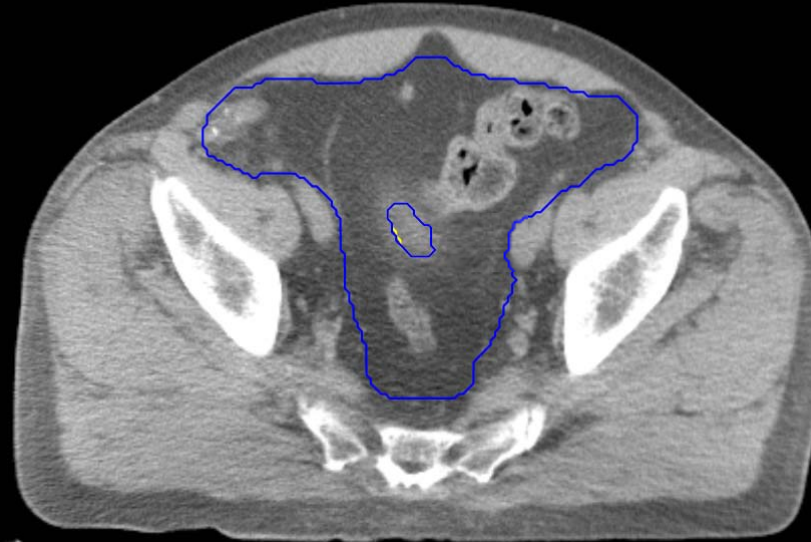AnoRectumSig stops here because this is the last cut where the mesorectal fascia is visible

GI:

- Small Bowel
- AnoRectumSig
- Colon
- Mesorectum

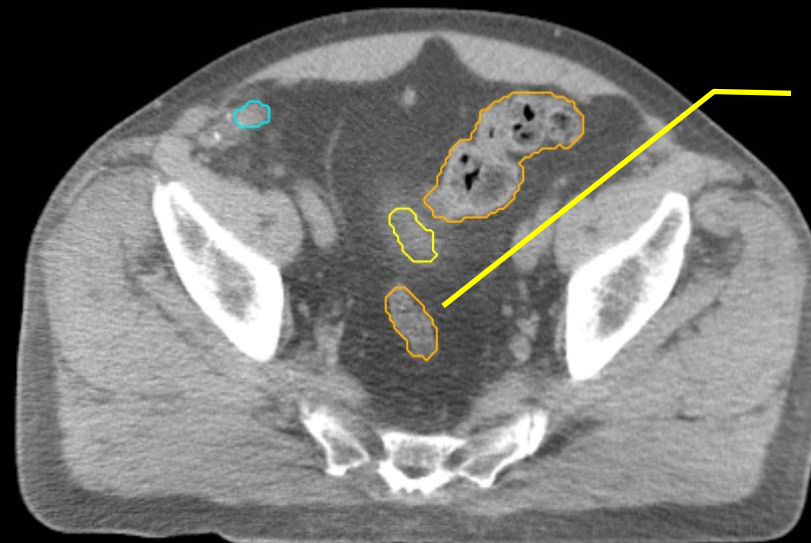
GU:

- Rectum
- BowelBag



GU/GI:

- PenileBulb
- Bladder
- SeminalVesc
- Prostate
- Femur\_L
- Femur\_R



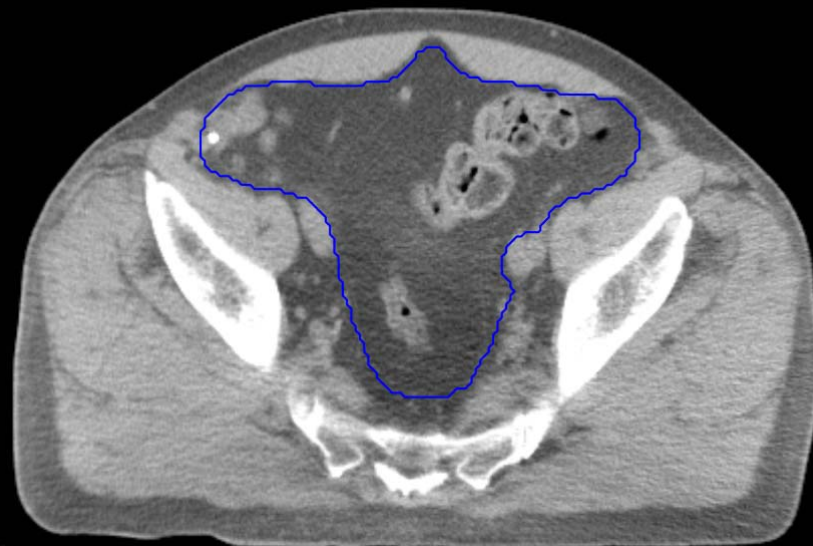GI:

- Small Bowel
- AnoRectumSig
- Colon
- Mesorectum

Colon connects with the  
AnoRectumSig inferiorly

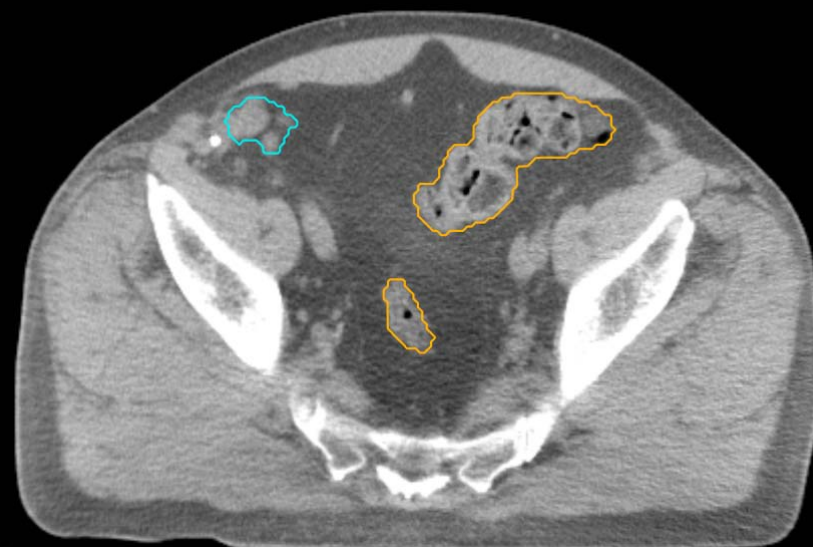
GU:

- Rectum
- BowelBag



GU/GI:

- PenileBulb
- Bladder
- SeminalVesc
- Prostate
- Femur\_L
- Femur\_R

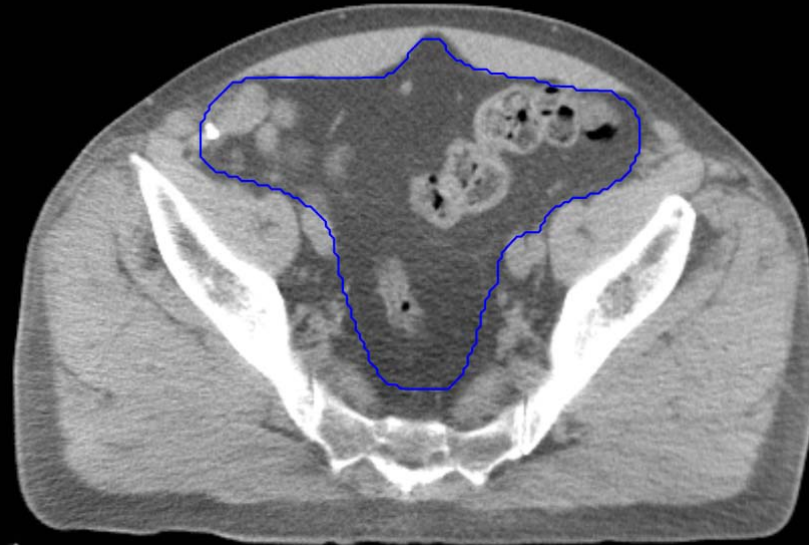

GI:

- Small Bowel
- AnoRectumSig
- Colon
- Mesorectum

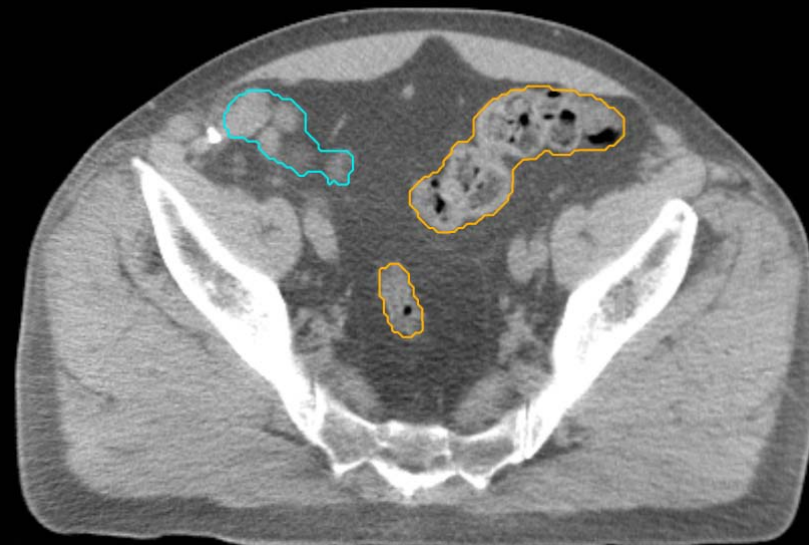
GU:

- Rectum
- BowelBag



GU/GI:

- PenileBulb
- Bladder
- SeminalVesc
- Prostate
- Femur\_L
- Femur\_R

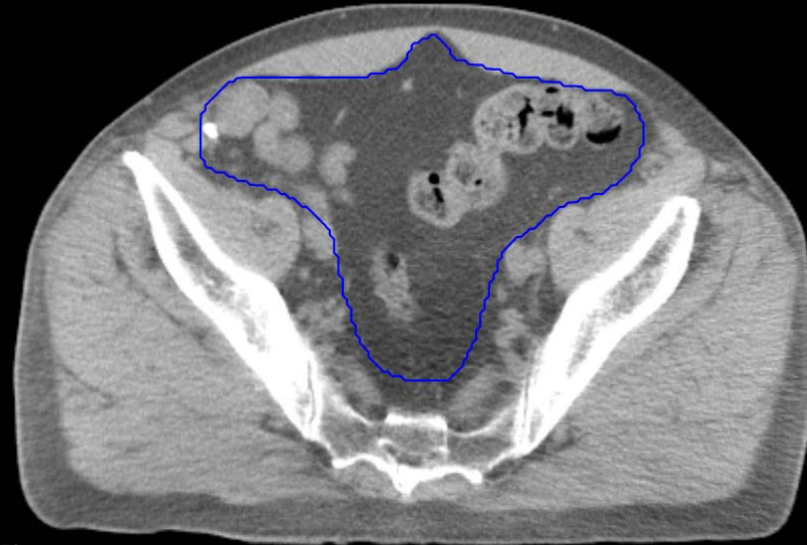


GI:

- Small Bowel
- AnoRectumSig
- Colon
- Mesorectum

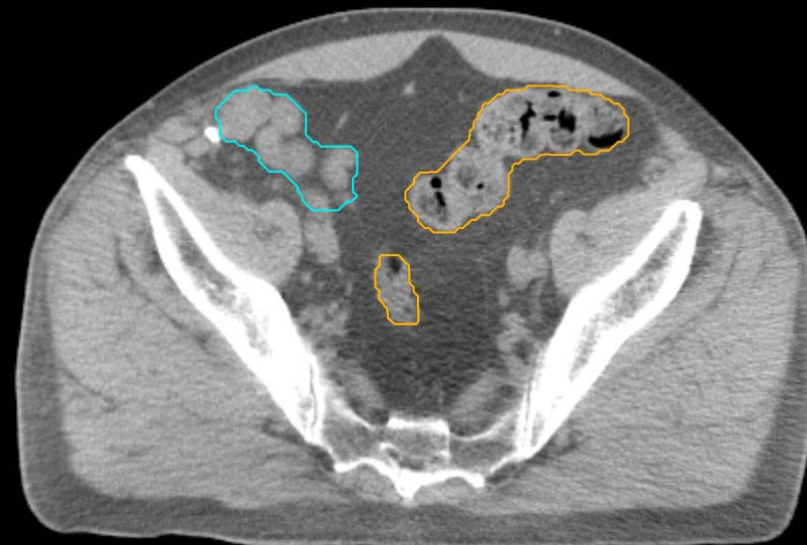
GU:

- Rectum
- BowelBag



GU/GI:

- PenileBulb
- Bladder
- SeminalVesc
- Prostate
- Femur\_L
- Femur\_R

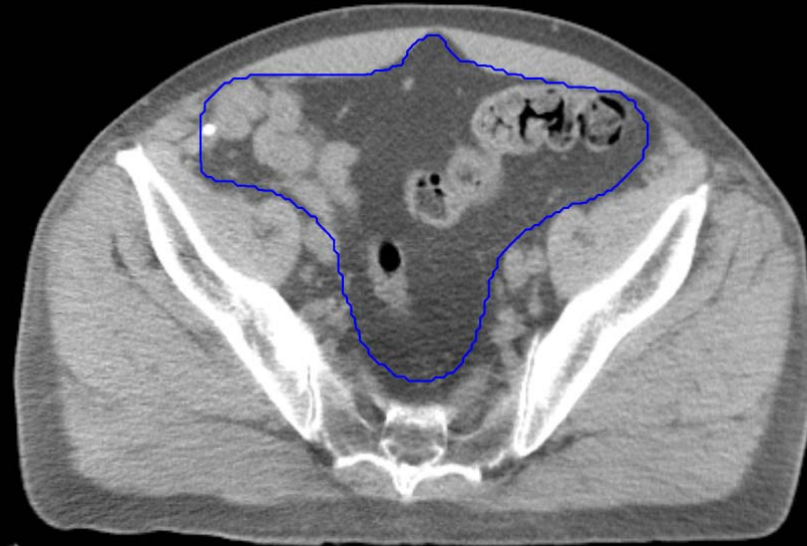

GI:

- Small Bowel
- AnoRectumSig
- Colon
- Mesorectum

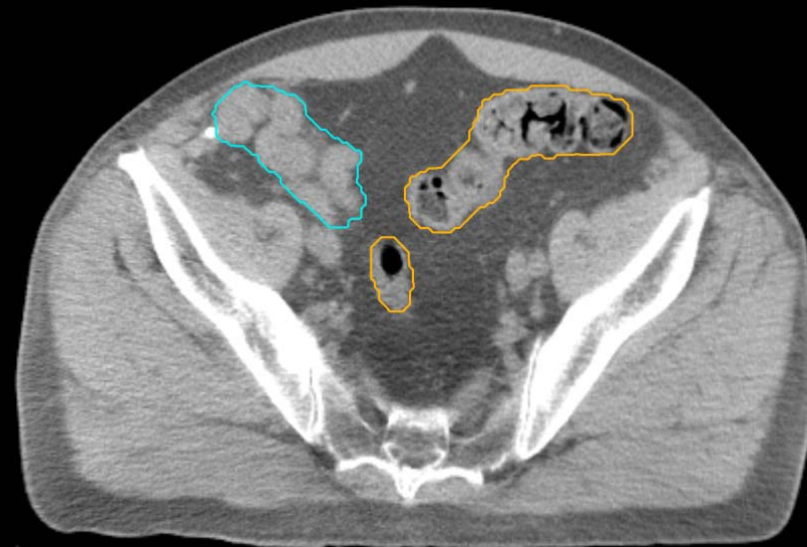
GU:

- Rectum
- BowelBag



GU/GI:

- PenileBulb
- Bladder
- SeminalVesc
- Prostate
- Femur\_L
- Femur\_R



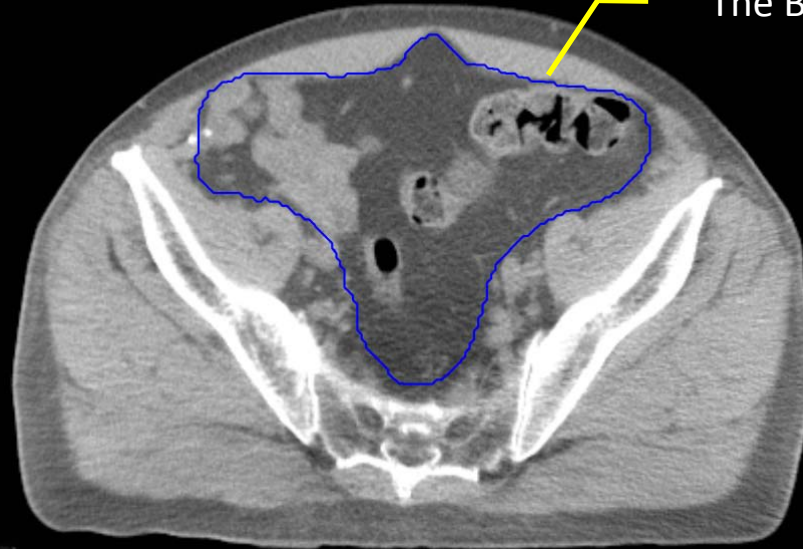
GI:

- Small Bowel
- AnoRectumSig
- Colon
- Mesorectum

GU:

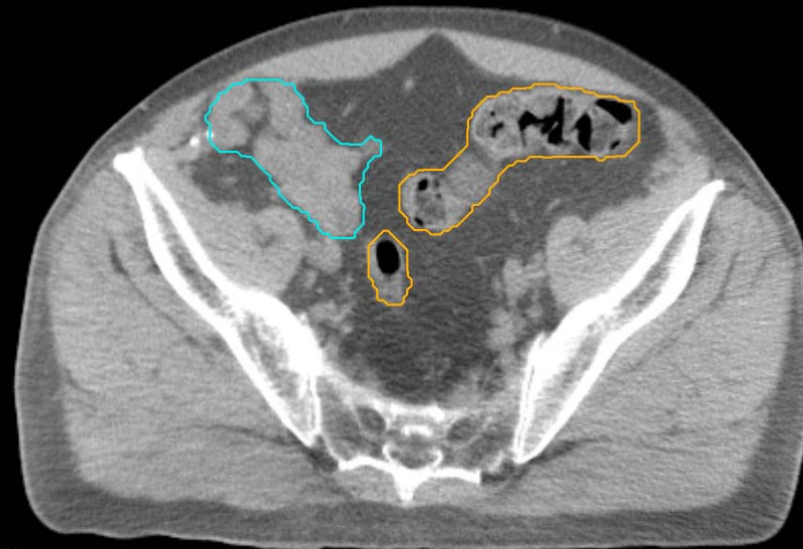
- Rectum
- BowelBag

The BowelBag is bounded by the muscles and bone.



GU/GI:

- PenileBulb
- Bladder
- SeminalVesc
- Prostate
- Femur\_L
- Femur\_R

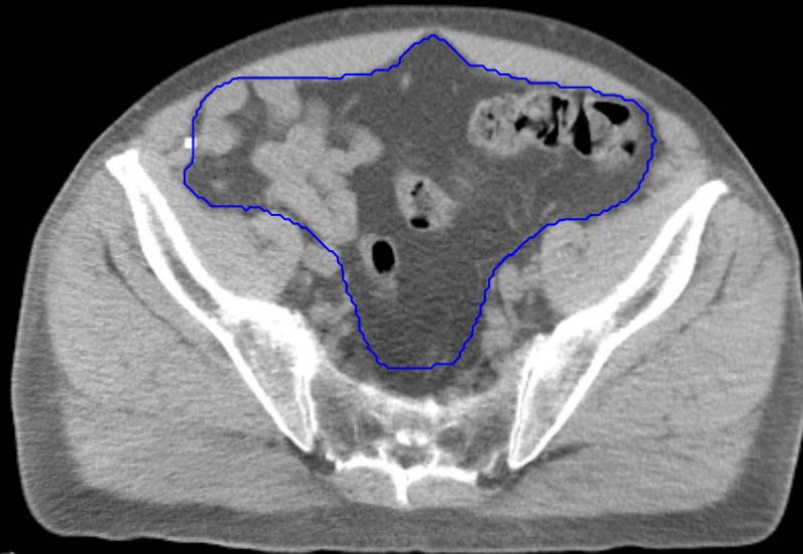


GI:

- Small Bowel
- AnoRectumSig
- Colon
- Mesorectum

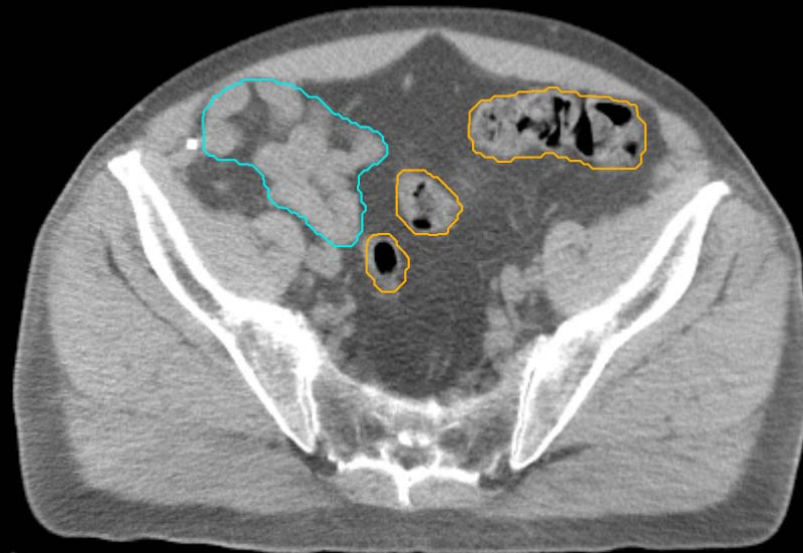
GU:

- Rectum
- BowelBag



GU/GI:

- PenileBulb
- Bladder
- SeminalVesc
- Prostate
- Femur\_L
- Femur\_R



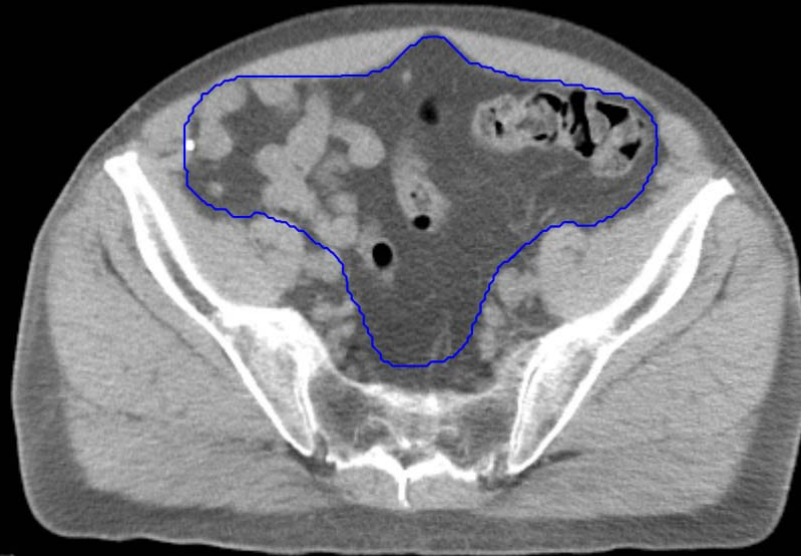GI:

- Small Bowel
- AnoRectumSig
- Colon
- Mesorectum



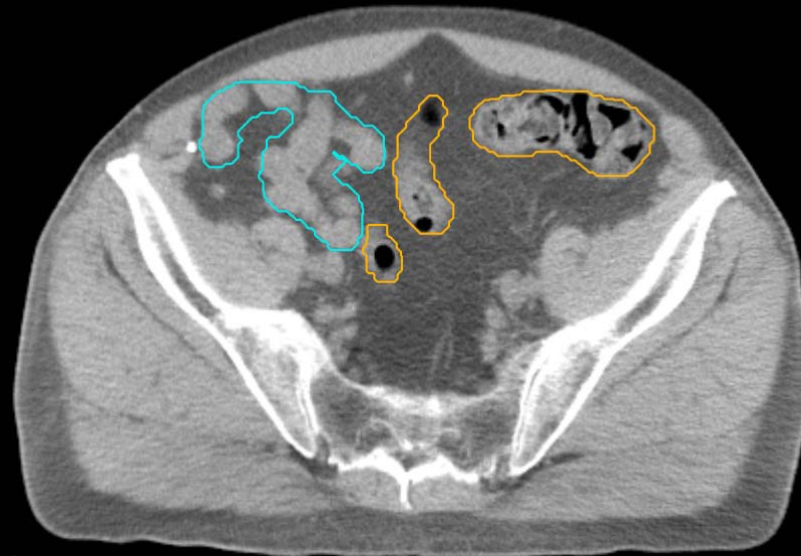
GU:

- Rectum
- BowelBag



GU/GI:

- PenileBulb
- Bladder
- SeminalVesc
- Prostate
- Femur\_L
- Femur\_R

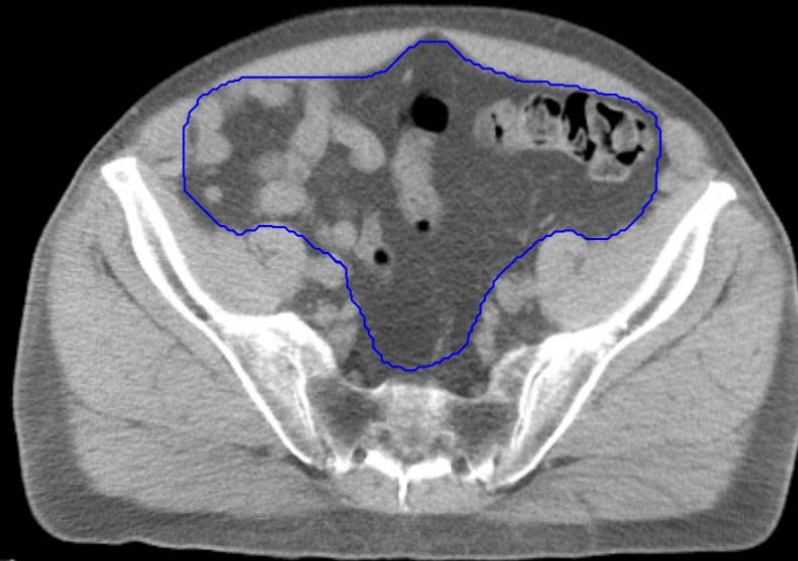


GI:

- Small Bowel
- AnoRectumSig
- Colon
- Mesorectum

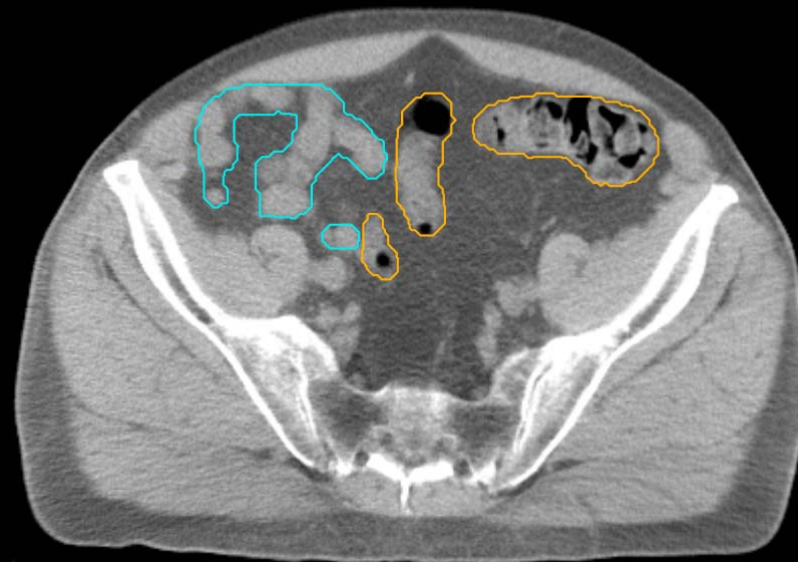
GU:

- Rectum
- BowelBag



GU/GI:

- PenileBulb
- Bladder
- SeminalVesc
- Prostate
- Femur\_L
- Femur\_R

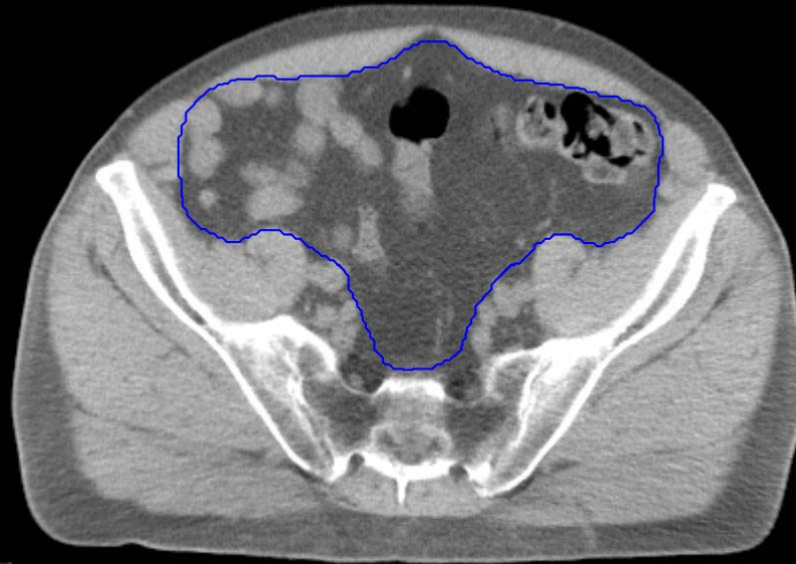


GI:

- Small Bowel
- AnoRectumSig
- Colon
- Mesorectum

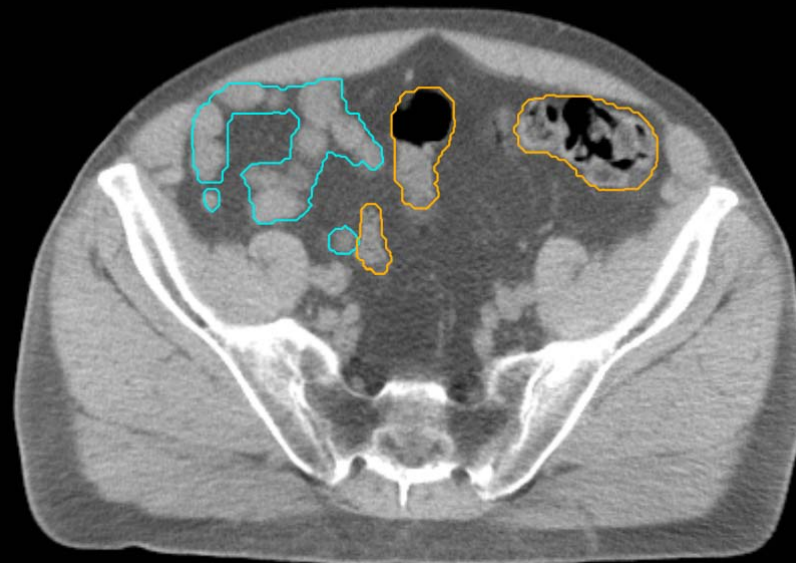
GU:

- Rectum
- BowelBag



GU/GI:

- PenileBulb
- Bladder
- SeminalVesc
- Prostate
- Femur\_L
- Femur\_R

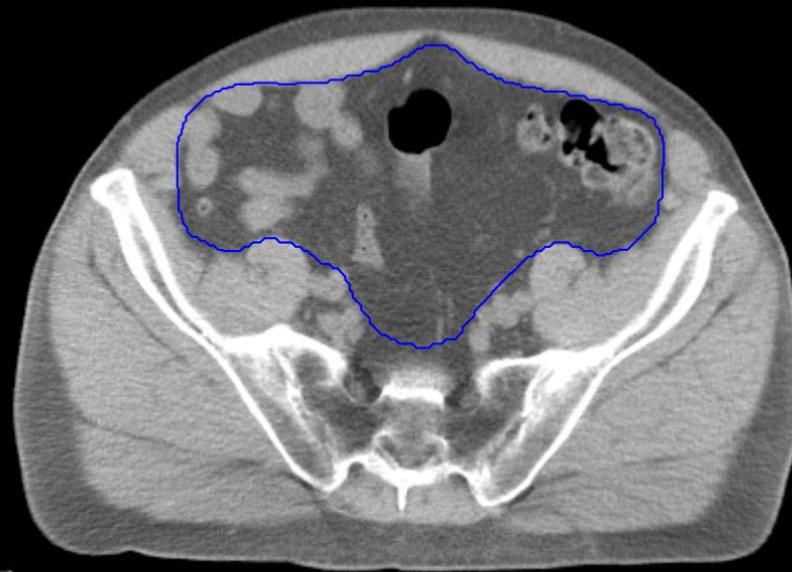


GI:

- Small Bowel
- AnoRectumSig
- Colon
- Mesorectum

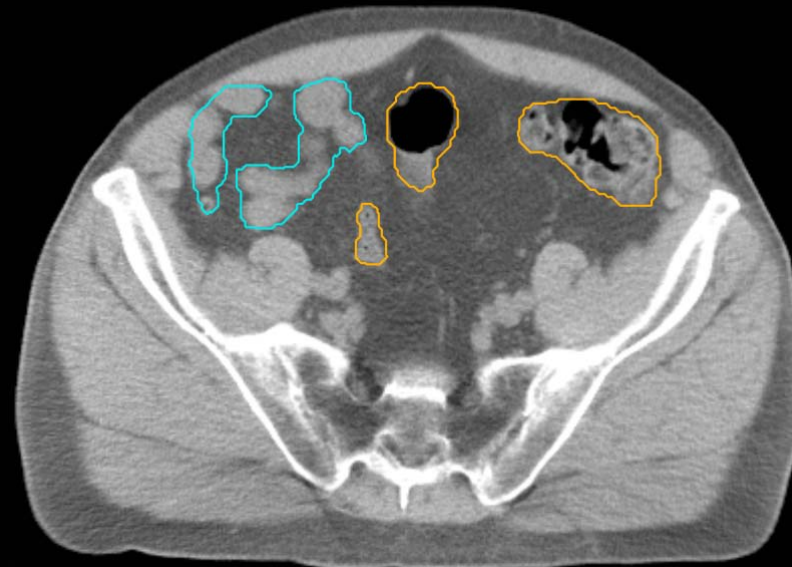
GU:

- Rectum
- BowelBag



GU/GI:

- PenileBulb
- Bladder
- SeminalVesc
- Prostate
- Femur\_L
- Femur\_R

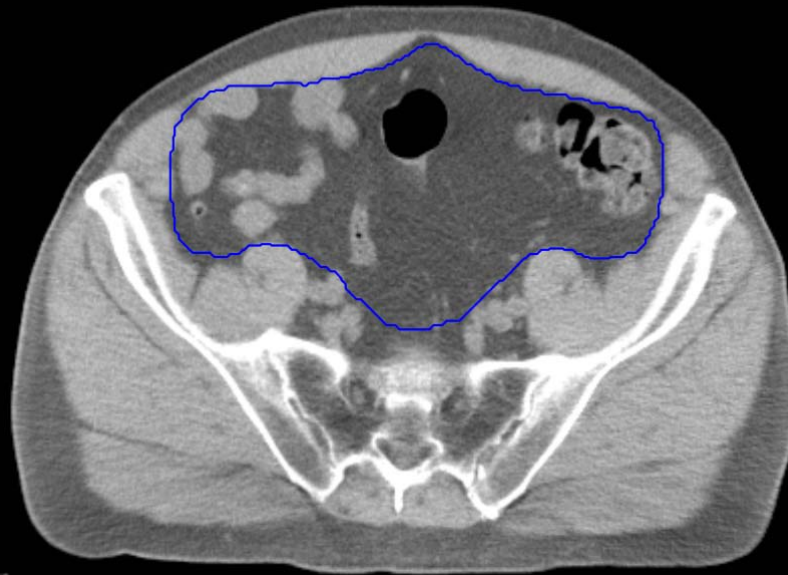


GI:

- Small Bowel
- AnoRectumSig
- Colon
- Mesorectum

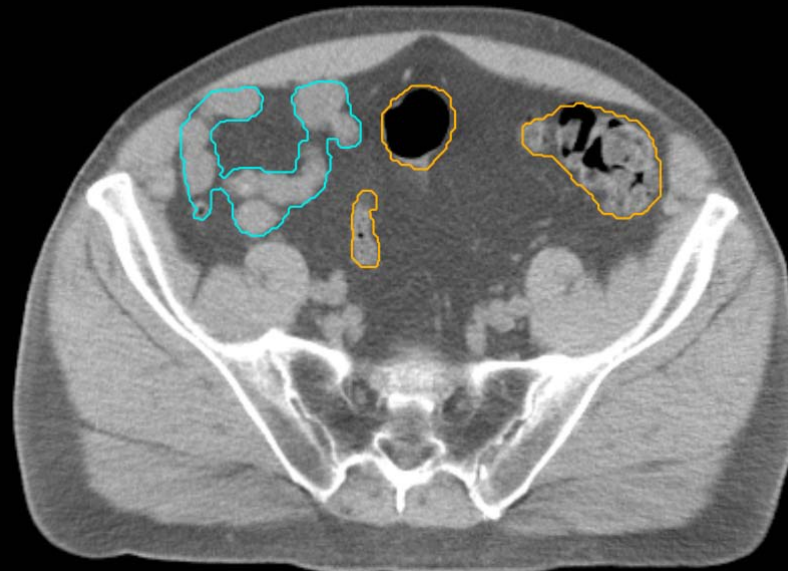
GU:

- Rectum
- BowelBag



GU/GI:

- PenileBulb
- Bladder
- SeminalVesc
- Prostate
- Femur\_L
- Femur\_R

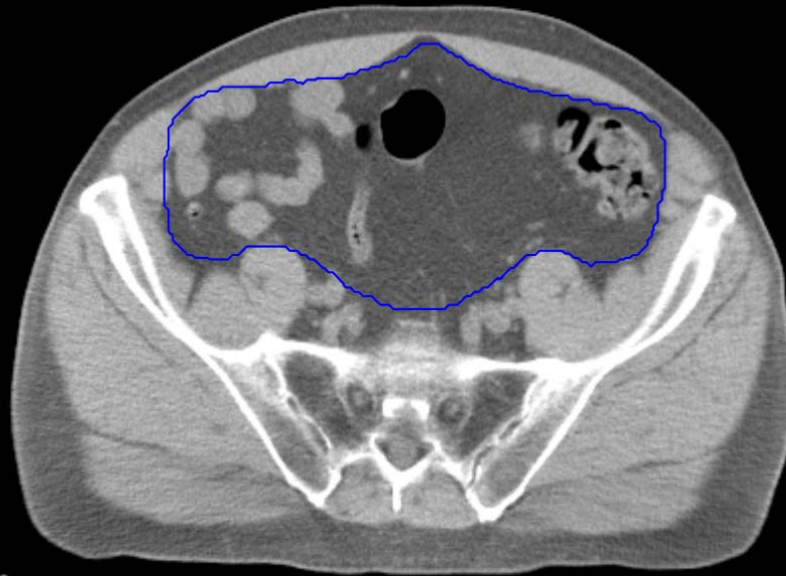


GI:

- Small Bowel
- AnoRectumSig
- Colon
- Mesorectum

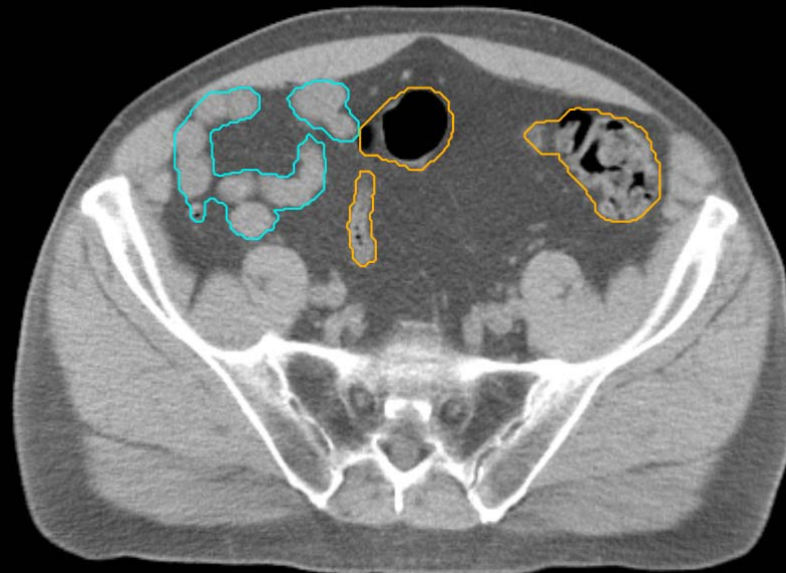
GU:

- Rectum
- BowelBag



GU/GI:

- PenileBulb
- Bladder
- SeminalVesc
- Prostate
- Femur\_L
- Femur\_R

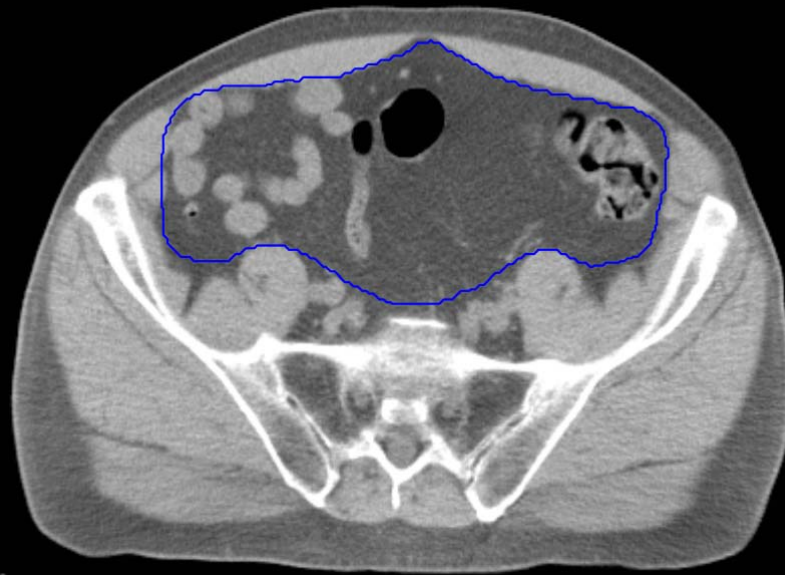


GI:

- Small Bowel
- AnoRectumSig
- Colon
- Mesorectum

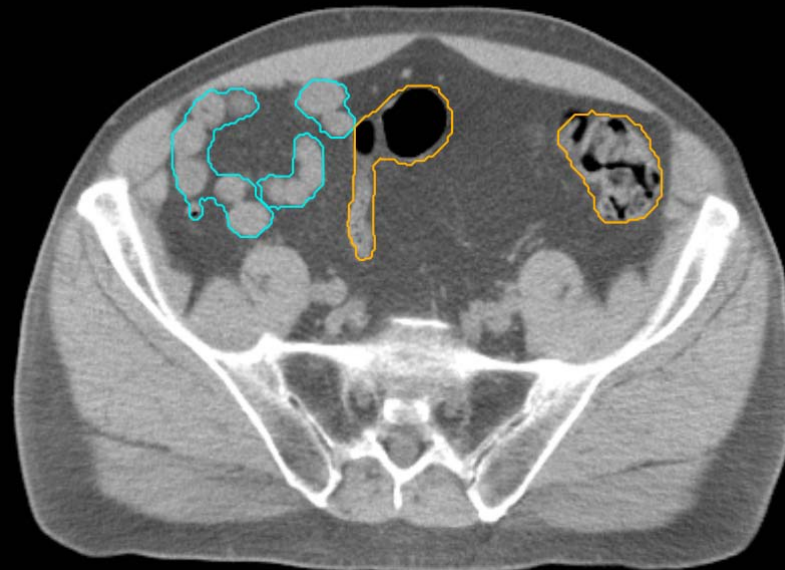
GU:

- Rectum
- BowelBag



GU/GI:

- PenileBulb
- Bladder
- SeminalVesc
- Prostate
- Femur\_L
- Femur\_R

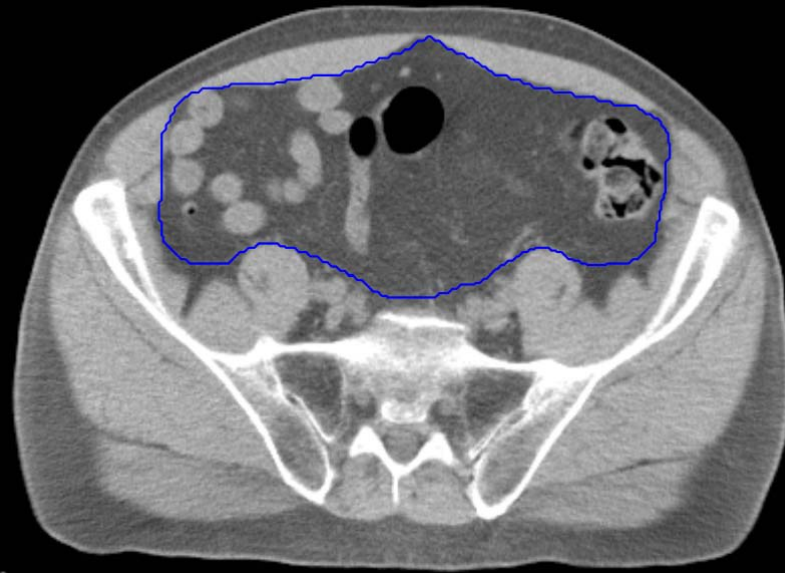


GI:

- Small Bowel
- AnoRectumSig
- Colon
- Mesorectum

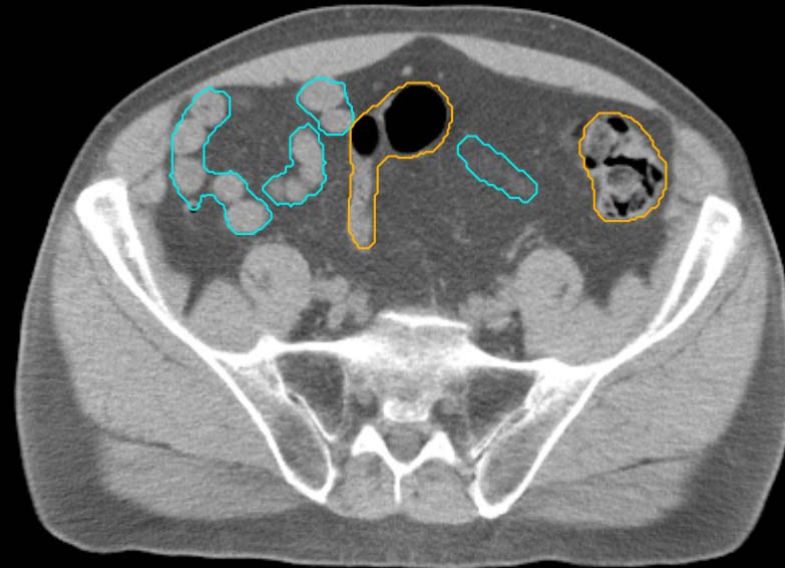
GU:

- Rectum
- BowelBag



GU/GI:

- PenileBulb
- Bladder
- SeminalVesc
- Prostate
- Femur\_L
- Femur\_R



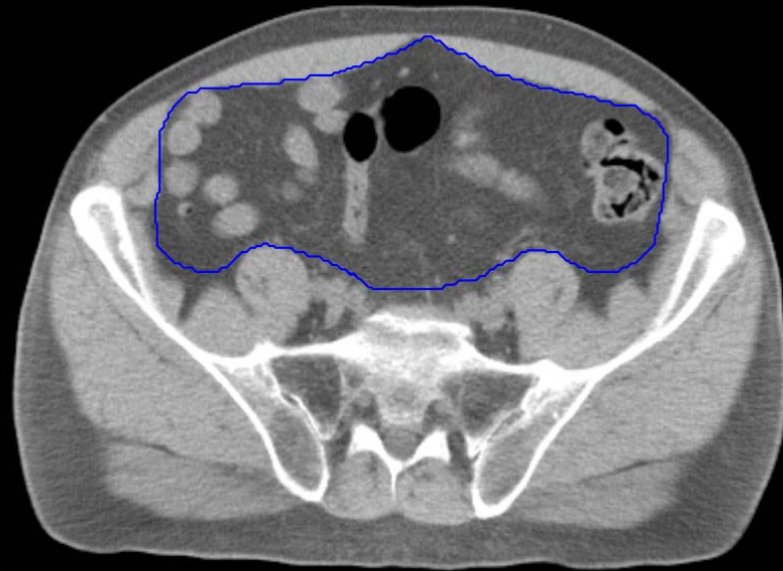
GI:

- Small Bowel
- AnoRectumSig
- Colon
- Mesorectum



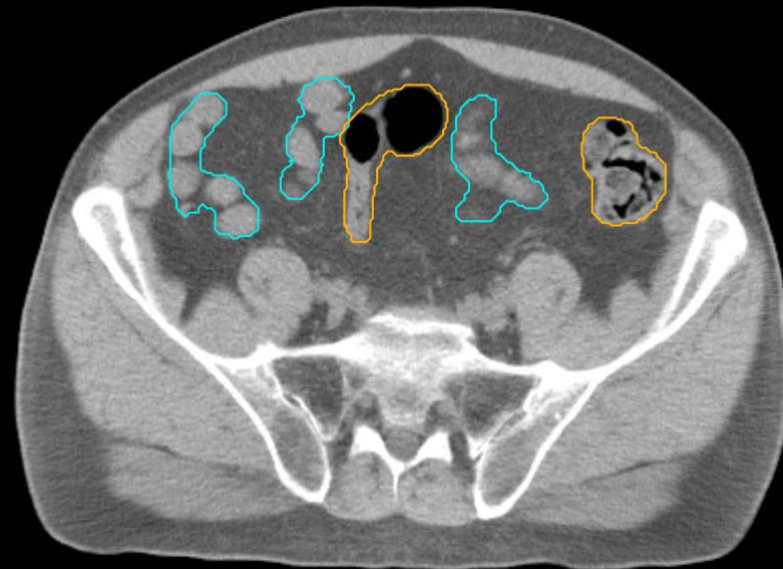
GU:

- Rectum
- BowelBag



GU/GI:

- PenileBulb
- Bladder
- SeminalVesc
- Prostate
- Femur\_L
- Femur\_R

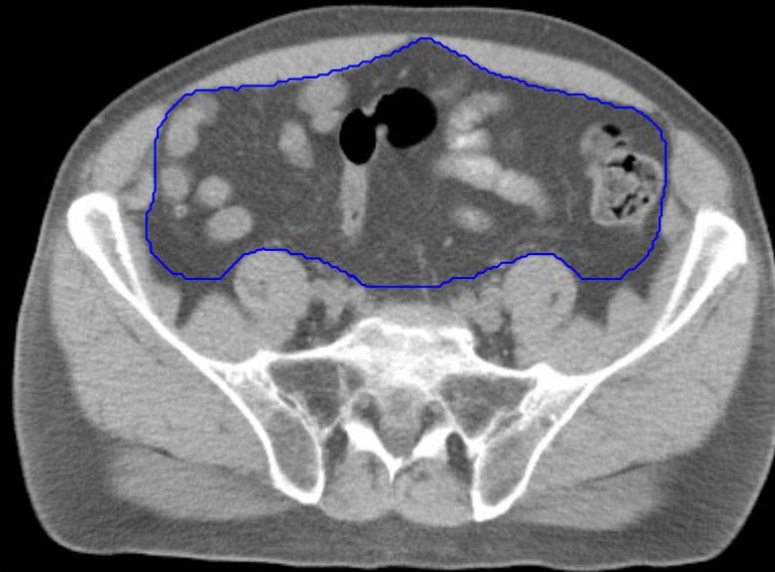


GI:

- Small Bowel
- AnoRectumSig
- Colon
- Mesorectum

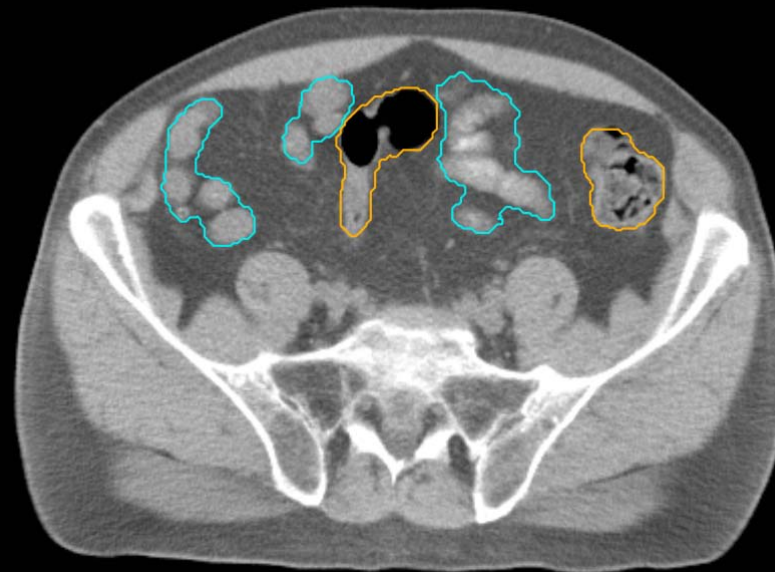
GU:

- Rectum
- BowelBag



GU/GI:

- PenileBulb
- Bladder
- SeminalVesc
- Prostate
- Femur\_L
- Femur\_R

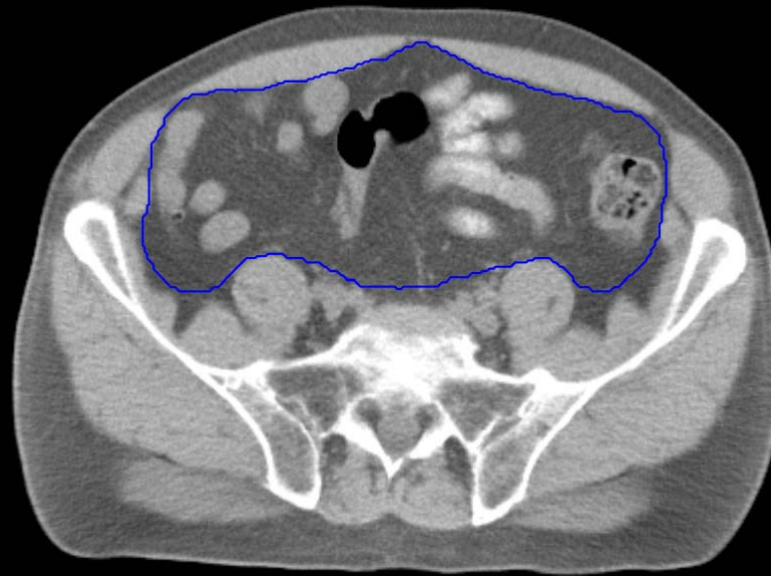


GI:

- Small Bowel
- AnoRectumSig
- Colon
- Mesorectum

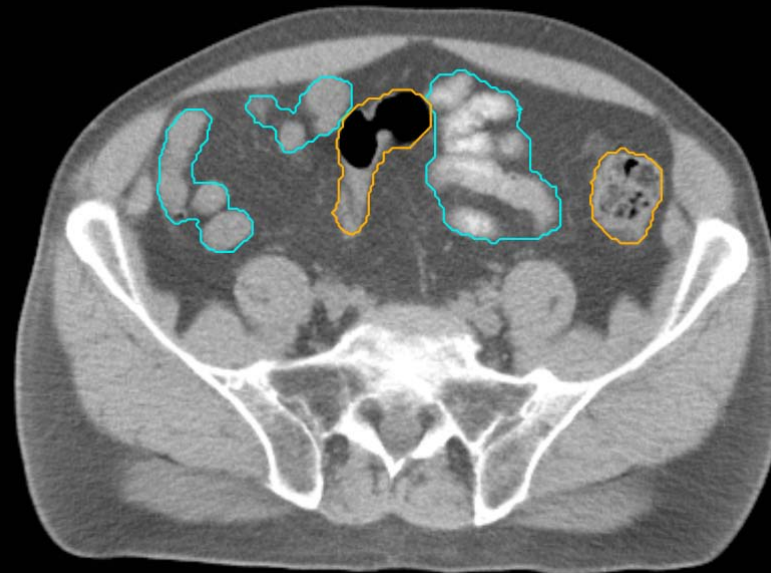
GU:

- Rectum
- BowelBag



GU/GI:

- PenileBulb
- Bladder
- SeminalVesc
- Prostate
- Femur\_L
- Femur\_R

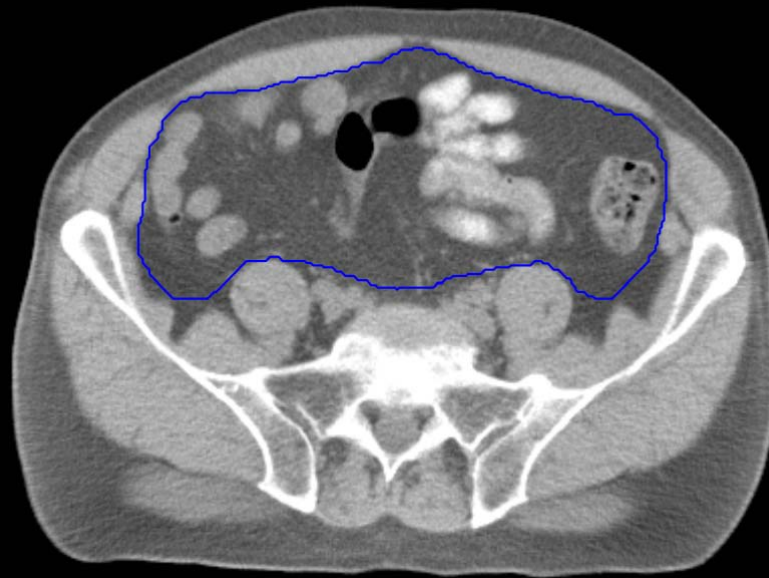


GI:

- Small Bowel
- AnoRectumSig
- Colon
- Mesorectum

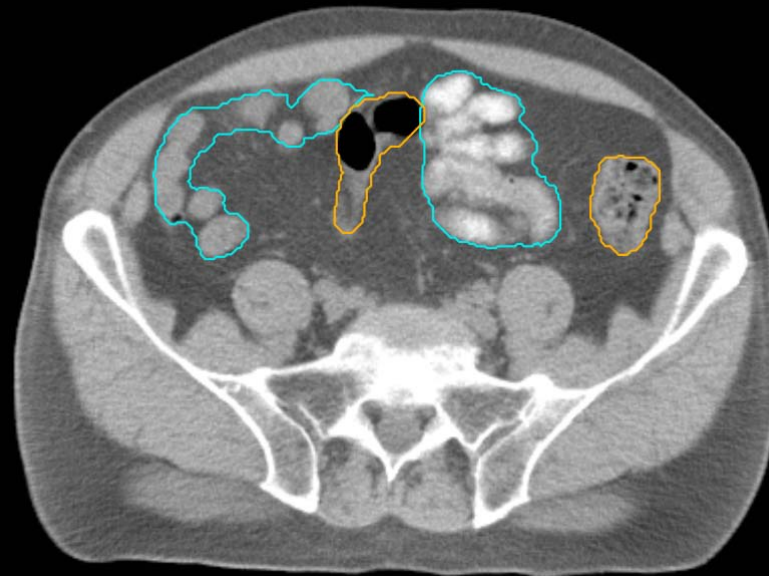
GU:

- Rectum
- BowelBag



GU/GI:

- PenileBulb
- Bladder
- SeminalVesc
- Prostate
- Femur\_L
- Femur\_R

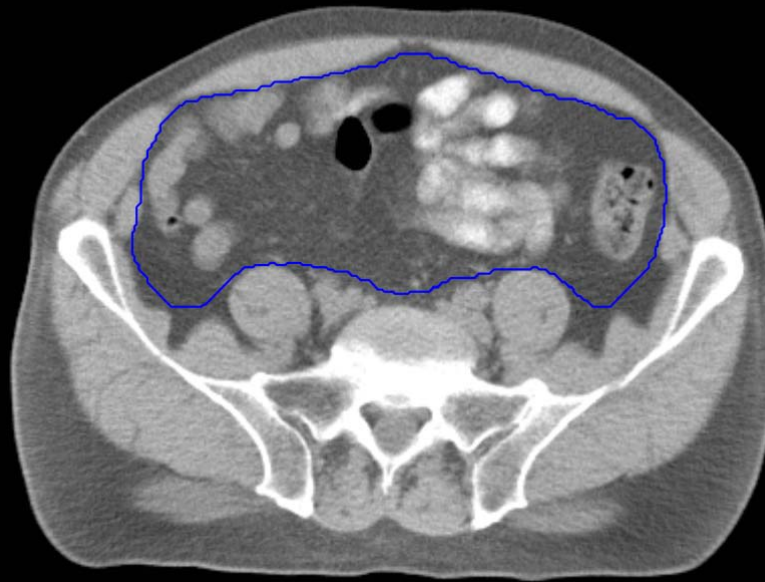


GI:

- Small Bowel
- AnoRectumSig
- Colon
- Mesorectum

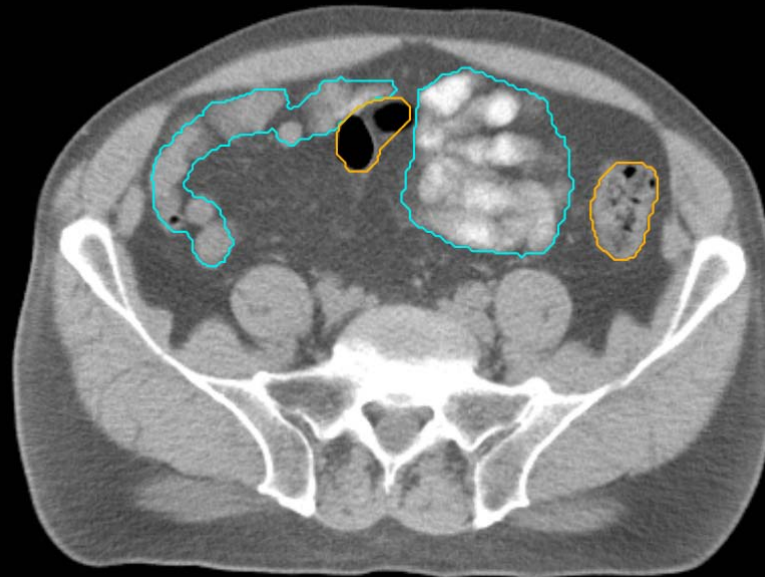
GU:

- Rectum
- BowelBag



GU/GI:

- PenileBulb
- Bladder
- SeminalVesc
- Prostate
- Femur\_L
- Femur\_R

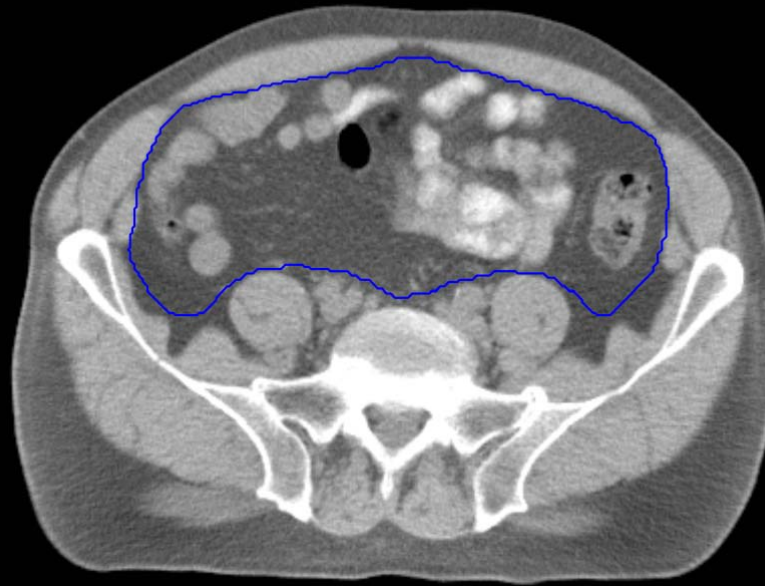


GI:

- Small Bowel
- AnoRectumSig
- Colon
- Mesorectum

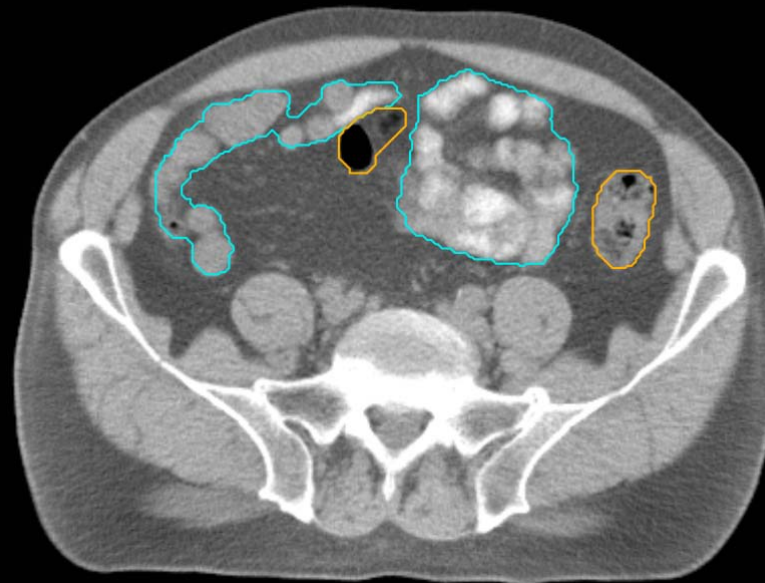
GU:

- Rectum
- BowelBag



GU/GI:

- PenileBulb
- Bladder
- SeminalVesc
- Prostate
- Femur\_L
- Femur\_R

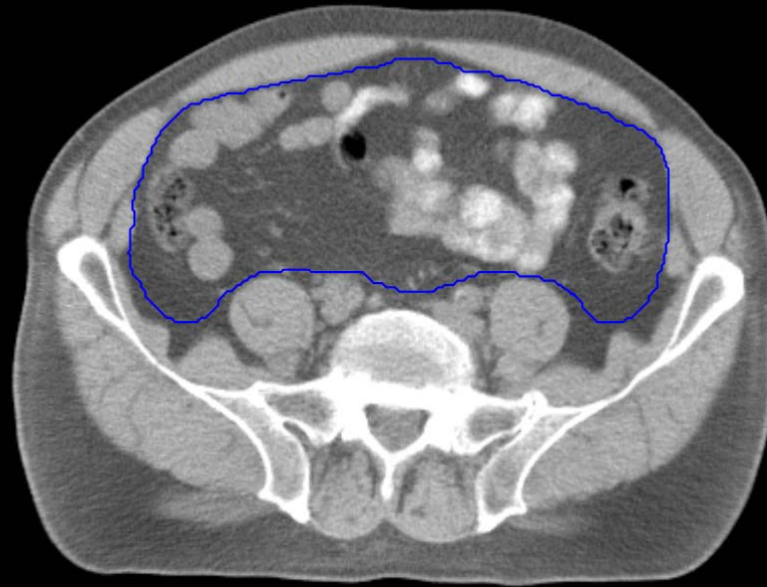


GI:

- Small Bowel
- AnoRectumSig
- Colon
- Mesorectum

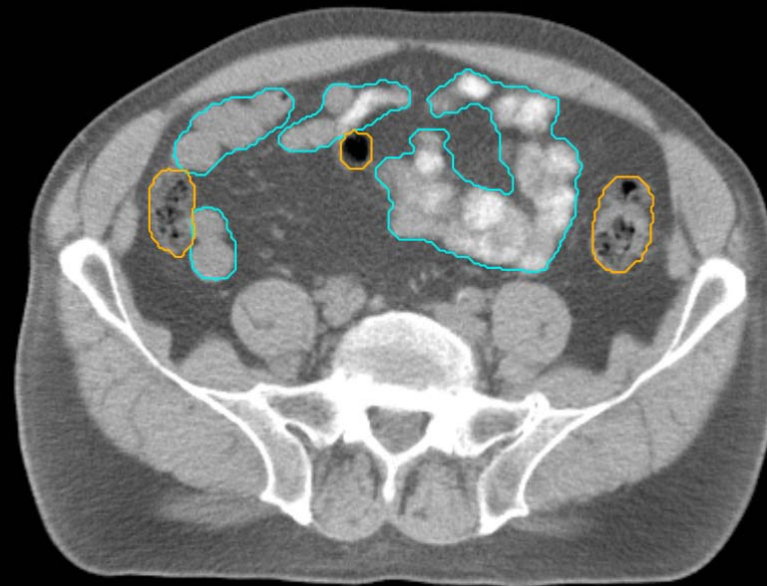
GU:

- Rectum
- BowelBag



GU/GI:

- PenileBulb
- Bladder
- SeminalVesc
- Prostate
- Femur\_L
- Femur\_R

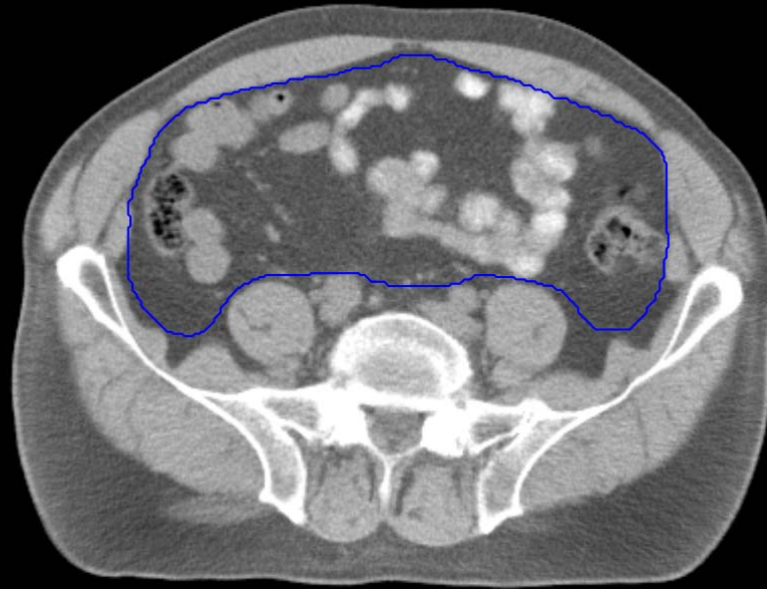


GI:

- Small Bowel
- AnoRectumSig
- Colon
- Mesorectum

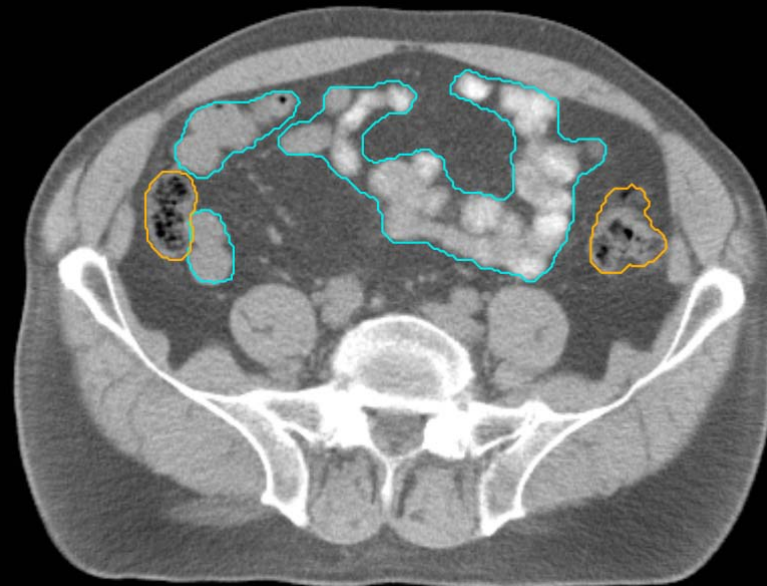
GU:

- Rectum
- BowelBag



GU/GI:

- PenileBulb
- Bladder
- SeminalVesc
- Prostate
- Femur\_L
- Femur\_R



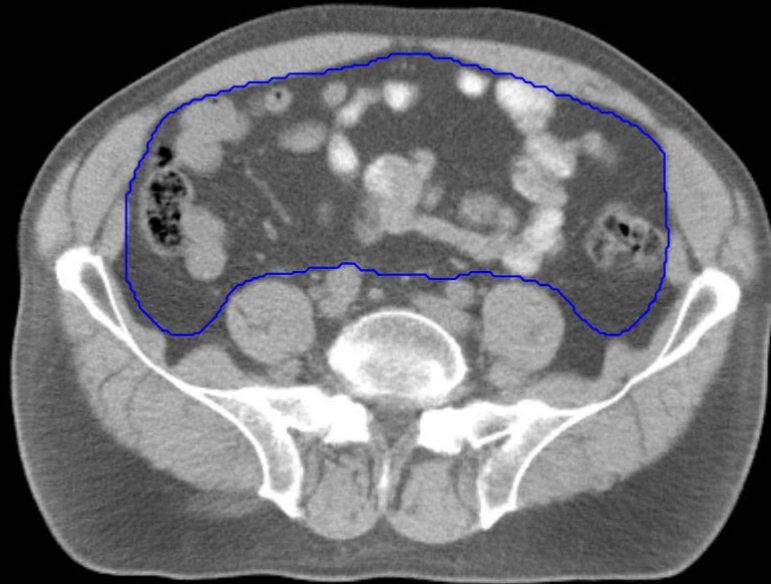
GI:

- Small Bowel
- AnoRectumSig
- Colon
- Mesorectum



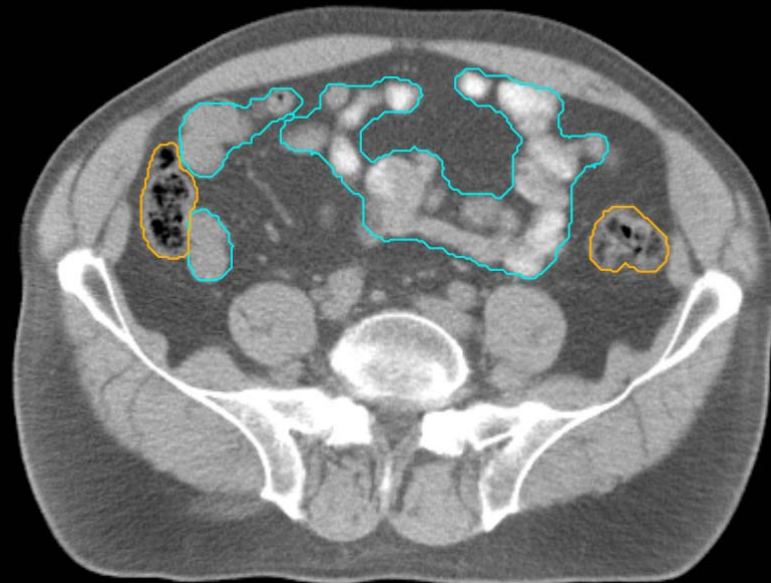
GU:

- Rectum
- BowelBag



GU/GI:

- PenileBulb
- Bladder
- SeminalVesc
- Prostate
- Femur\_L
- Femur\_R

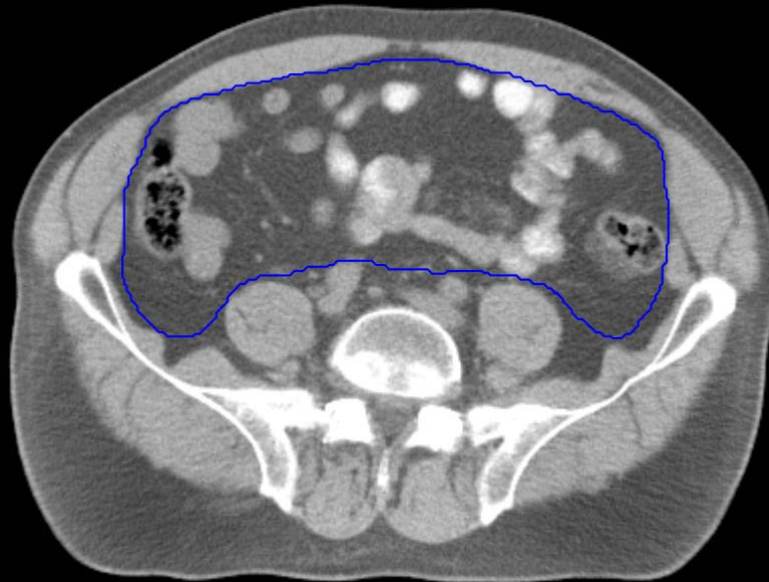


GI:

- Small Bowel
- AnoRectumSig
- Colon
- Mesorectum

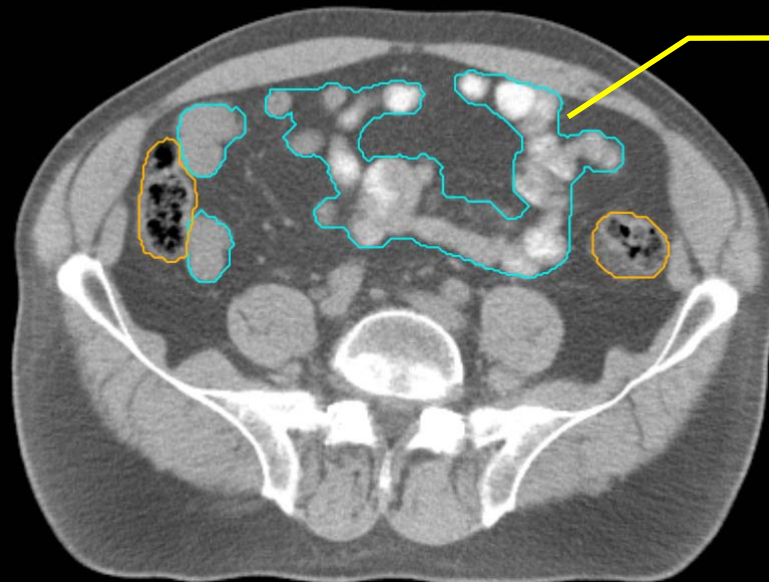
GU:

- Rectum
- BowelBag



GU/GI:

- PenileBulb
- Bladder
- SeminalVesc
- Prostate
- Femur\_L
- Femur\_R



Oral contrast helps identify SmallBowel

GI:

- Small Bowel
- AnoRectumSig
- Colon
- Mesorectum

GU:

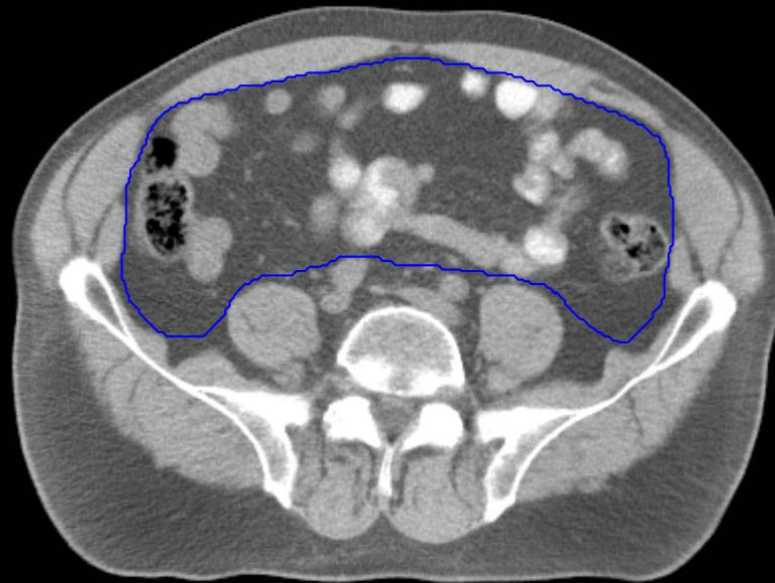
- Rectum
- BowelBag

GU/GI:

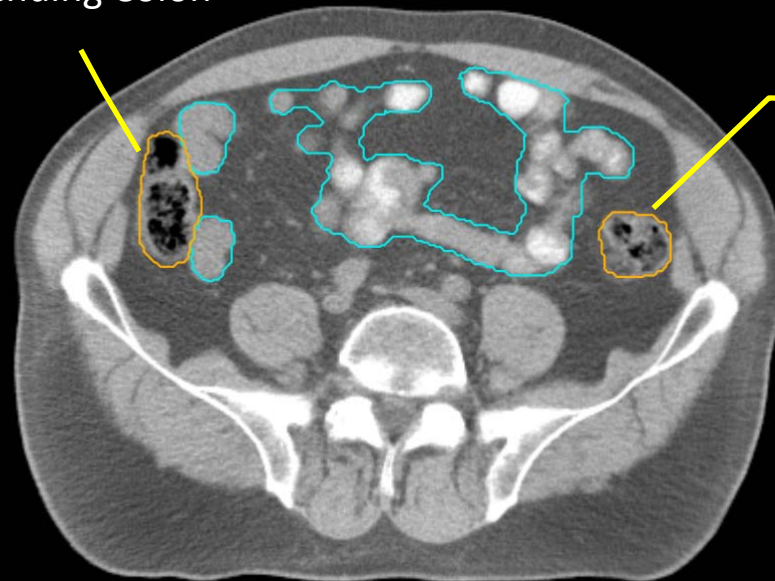
- PenileBulb
- Bladder
- SeminalVesc
- Prostate
- Femur\_L
- Femur\_R

GI:

- Small Bowel
- AnoRectumSig
- Colon
- Mesorectum



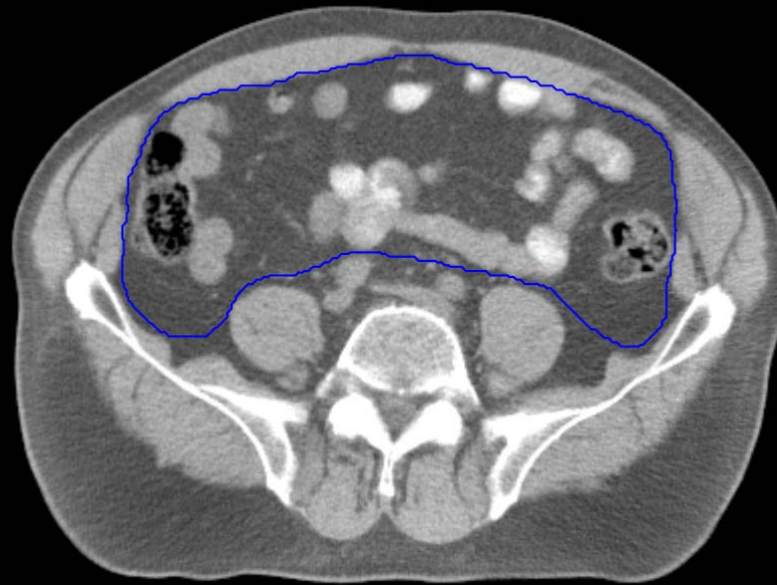
Ascending Colon



Descending Colon

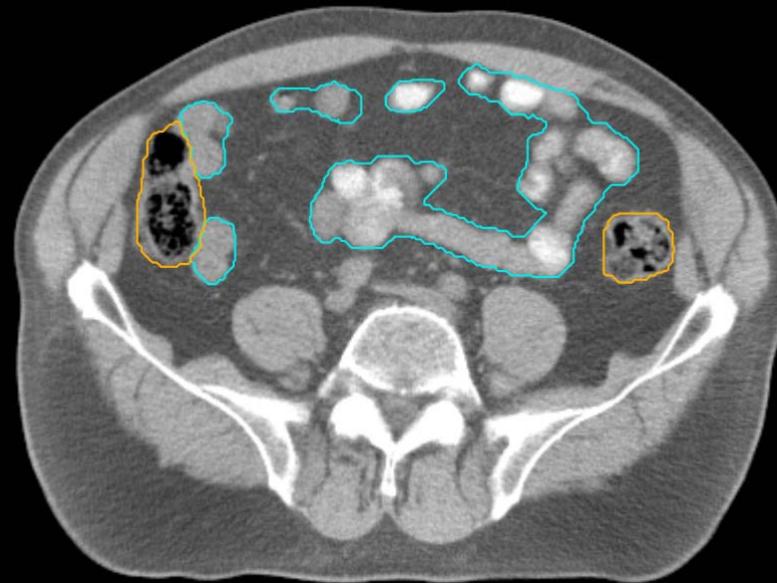
GU:

- Rectum
- BowelBag



GU/GI:

- PenileBulb
- Bladder
- SeminalVesc
- Prostate
- Femur\_L
- Femur\_R

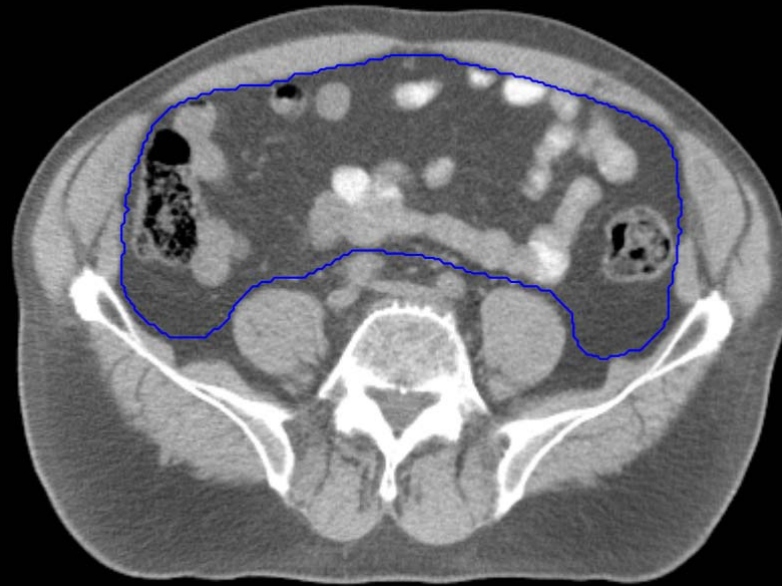


GI:

- Small Bowel
- AnoRectumSig
- Colon
- Mesorectum

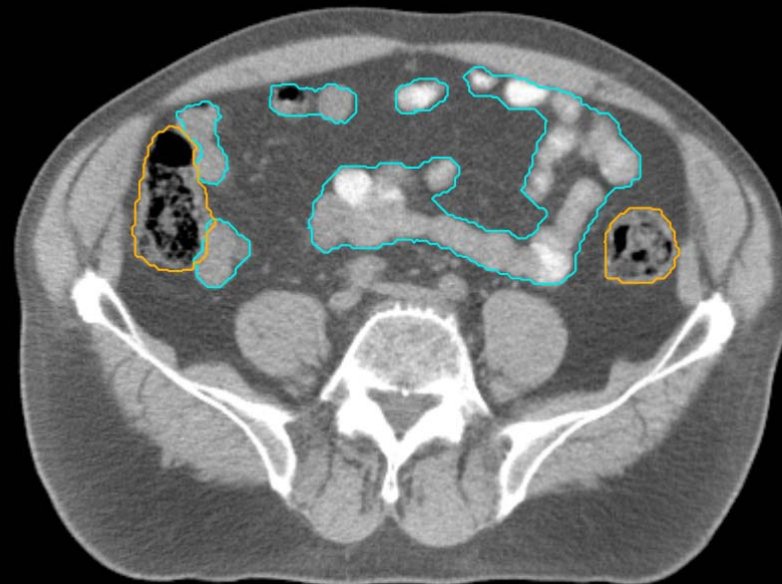
GU:

- Rectum
- BowelBag



GU/GI:

- PenileBulb
- Bladder
- SeminalVesc
- Prostate
- Femur\_L
- Femur\_R

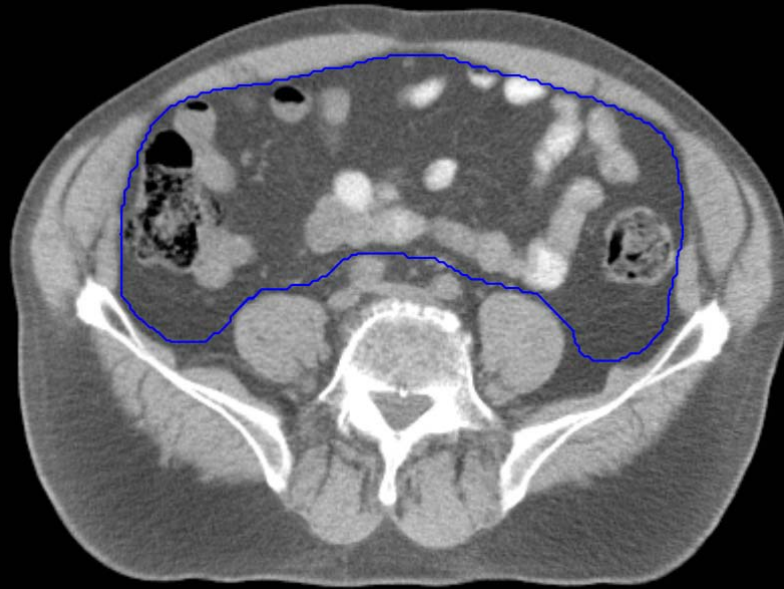


GI:

- Small Bowel
- AnoRectumSig
- Colon
- Mesorectum

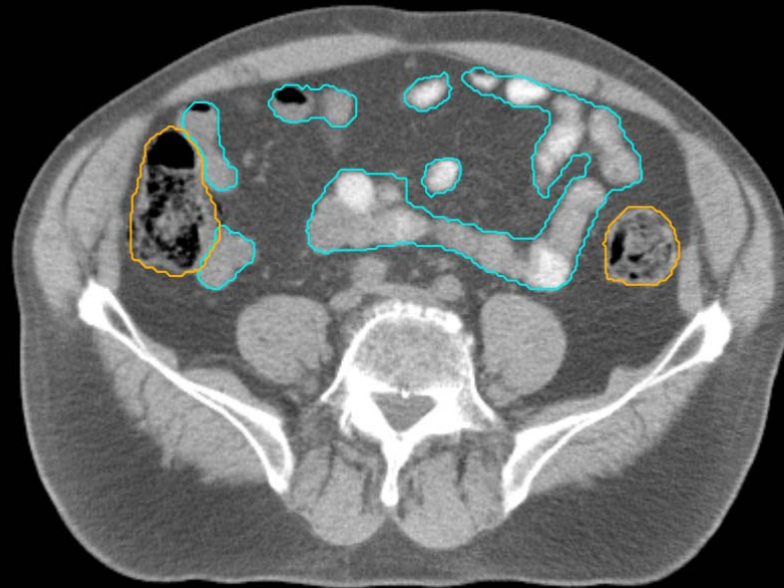GU:

- Rectum
- BowelBag



GU/GI:

- PenileBulb
- Bladder
- SeminalVesc
- Prostate
- Femur\_L
- Femur\_R

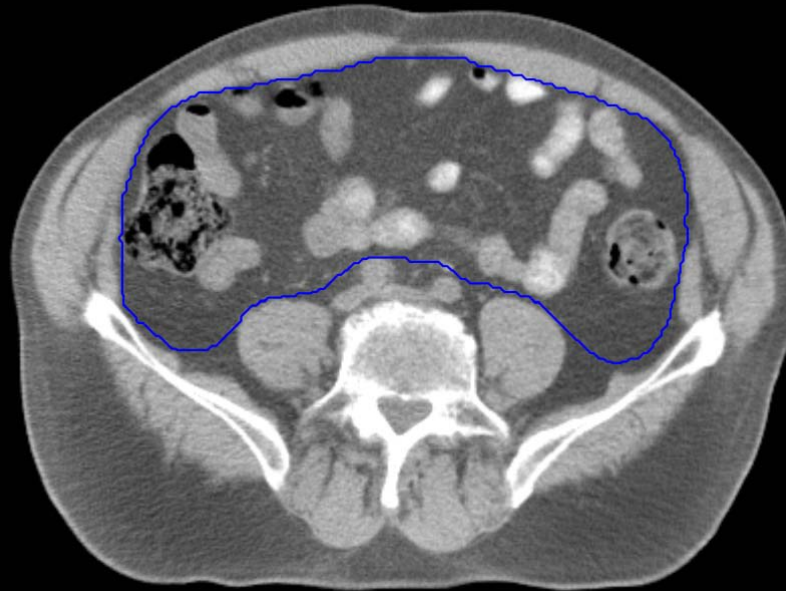

GI:

- Small Bowel
- AnoRectumSig
- Colon
- Mesorectum

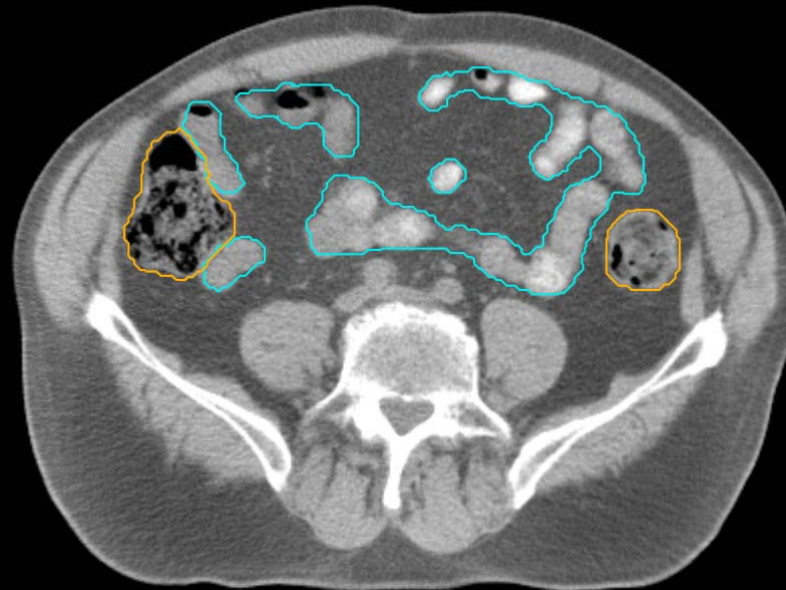
GU:

- Rectum
- BowelBag



GU/GI:

- PenileBulb
- Bladder
- SeminalVesc
- Prostate
- Femur\_L
- Femur\_R

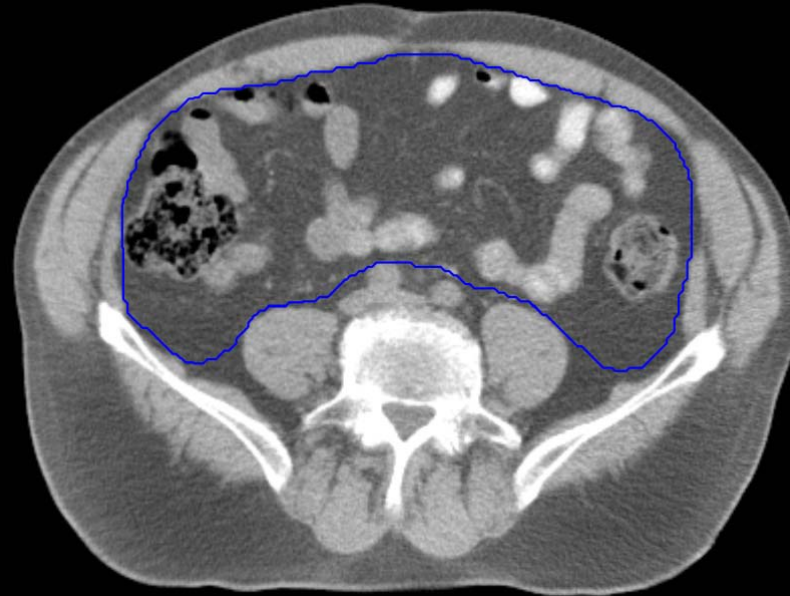

GI:

- Small Bowel
- AnoRectumSig
- Colon
- Mesorectum

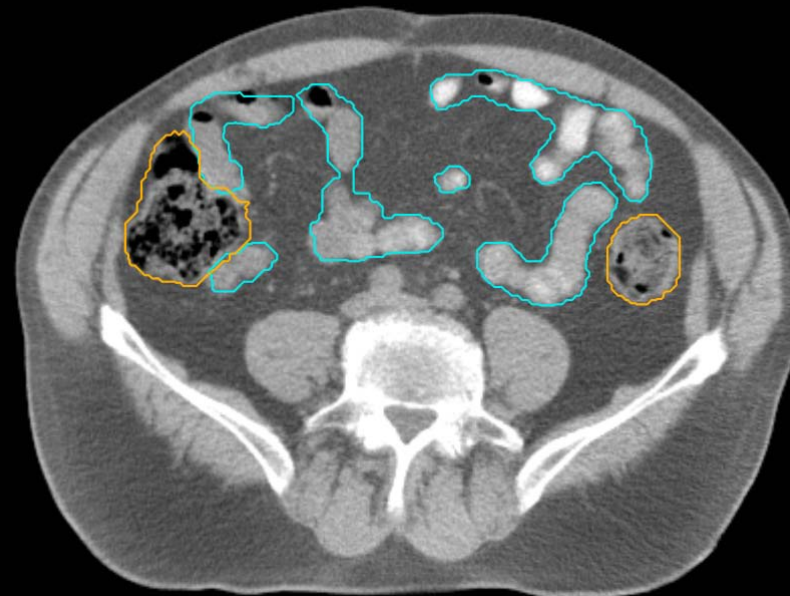
GU:

- Rectum
- BowelBag



GU/GI:

- PenileBulb
- Bladder
- SeminalVesc
- Prostate
- Femur\_L
- Femur\_R



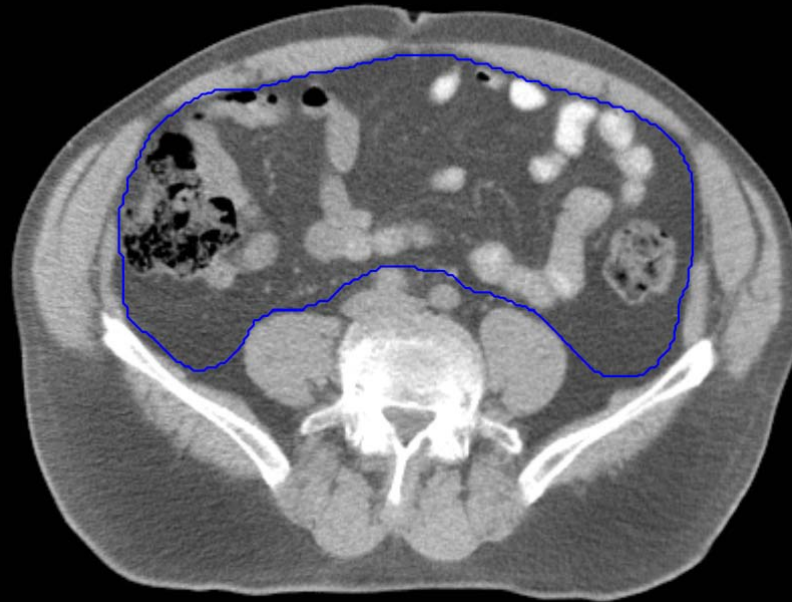GI:

- Small Bowel
- AnoRectumSig
- Colon
- Mesorectum



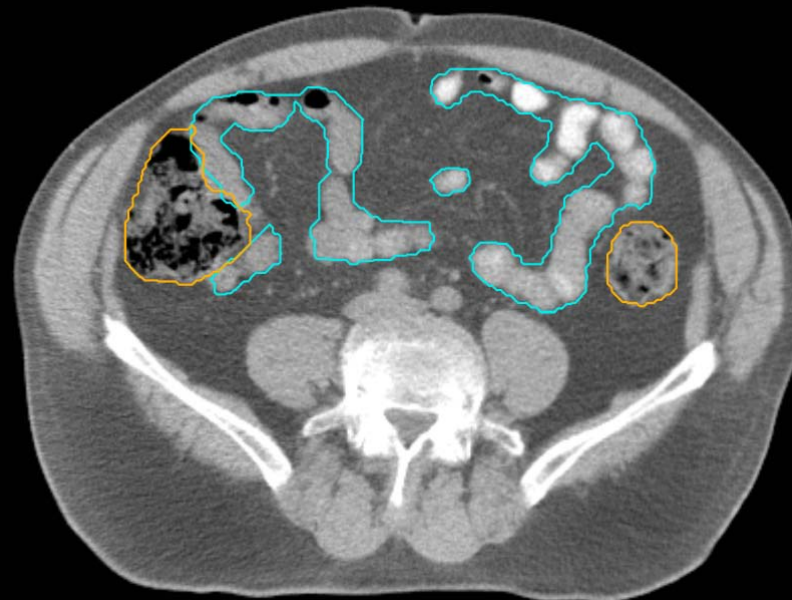GU:

- Rectum
- BowelBag



GU/GI:

- PenileBulb
- Bladder
- SeminalVesc
- Prostate
- Femur\_L
- Femur\_R

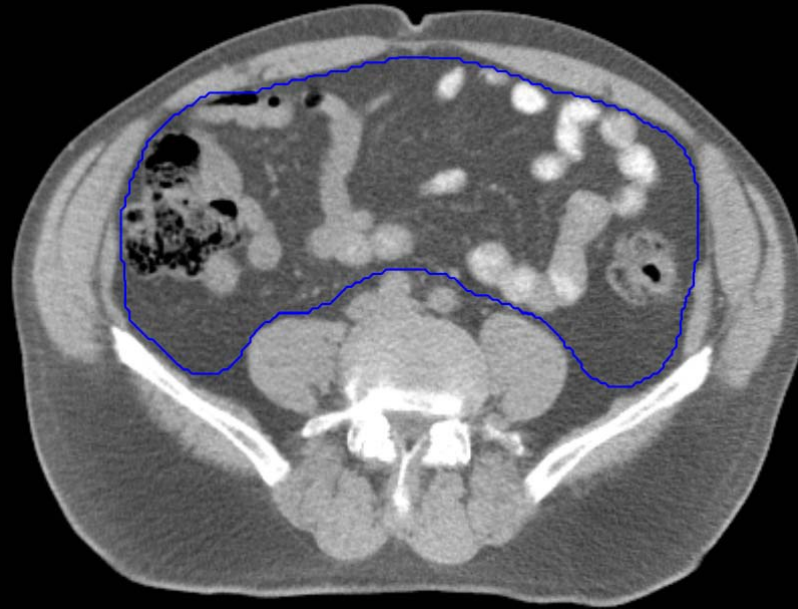

GI:

- Small Bowel
- AnoRectumSig
- Colon
- Mesorectum

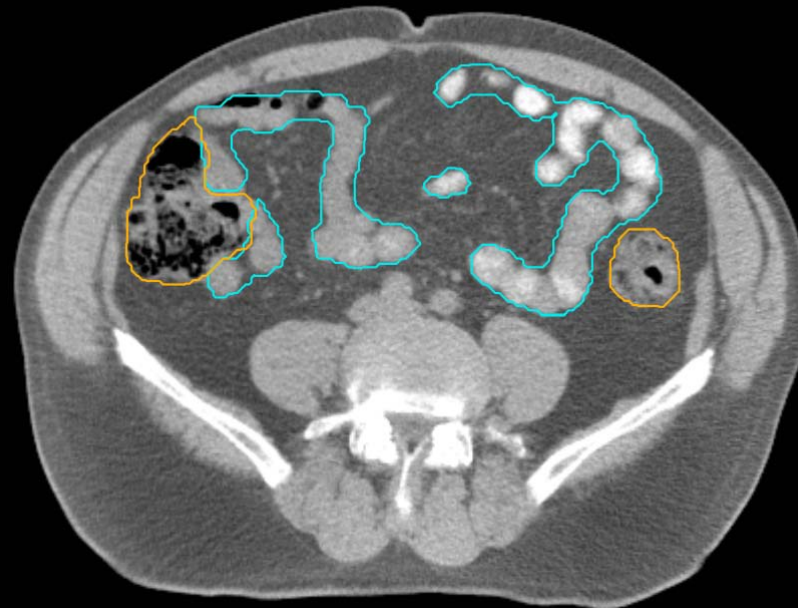GU:

- Rectum
- BowelBag



GU/GI:

- PenileBulb
- Bladder
- SeminalVesc
- Prostate
- Femur\_L
- Femur\_R

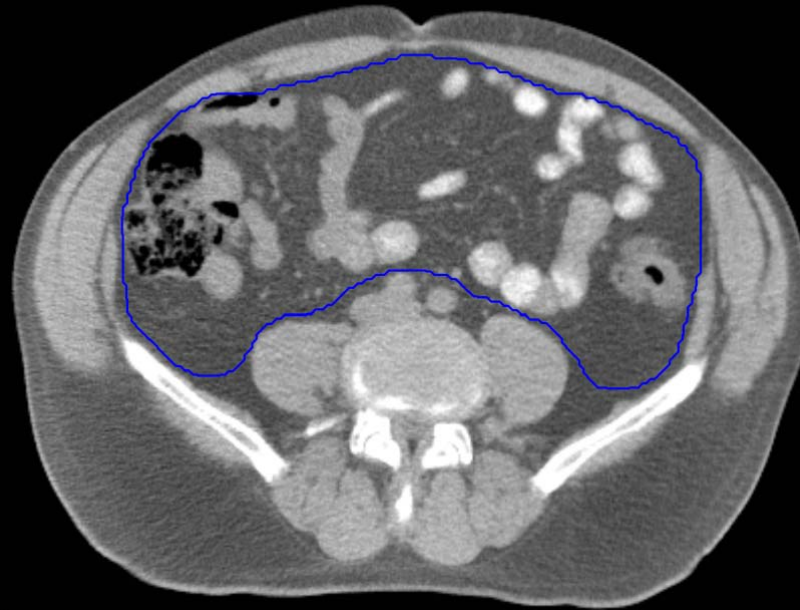

GI:

- Small Bowel
- AnoRectumSig
- Colon
- Mesorectum

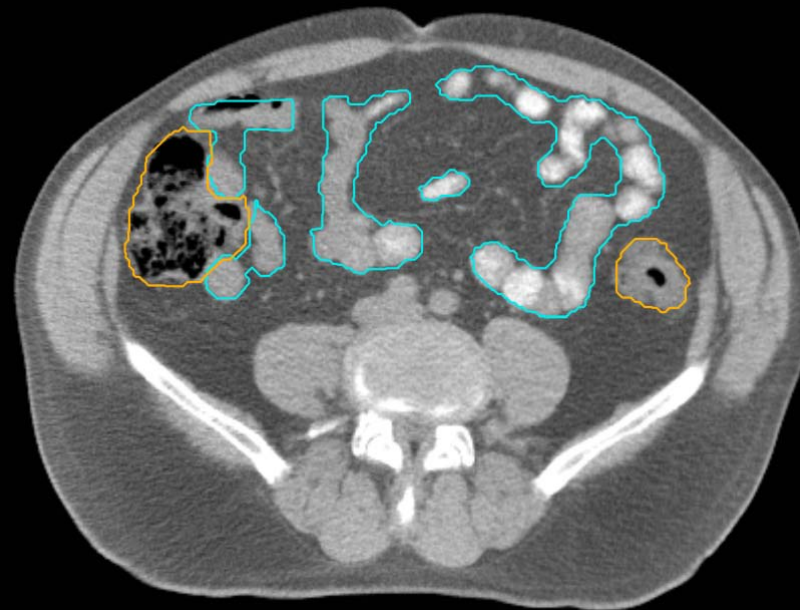GU:

- Rectum
- BowelBag



GU/GI:

- PenileBulb
- Bladder
- SeminalVesc
- Prostate
- Femur\_L
- Femur\_R

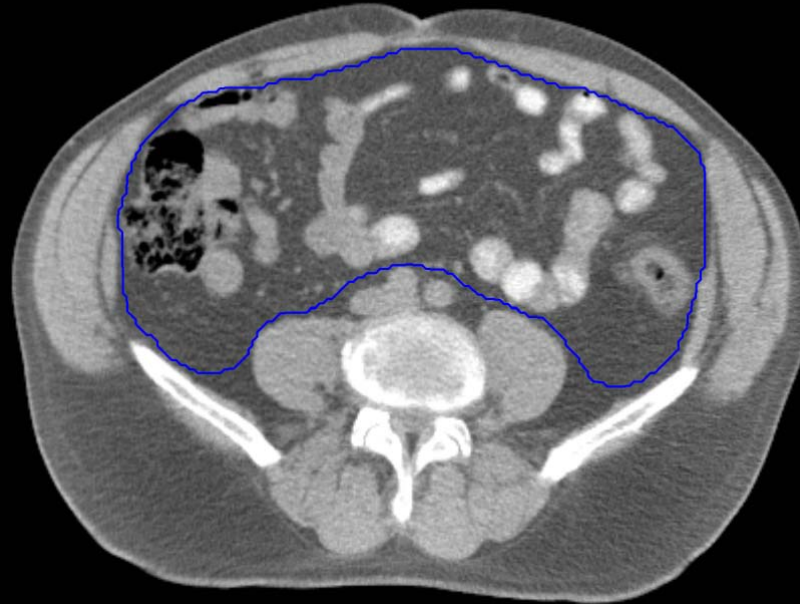

GI:

- Small Bowel
- AnoRectumSig
- Colon
- Mesorectum

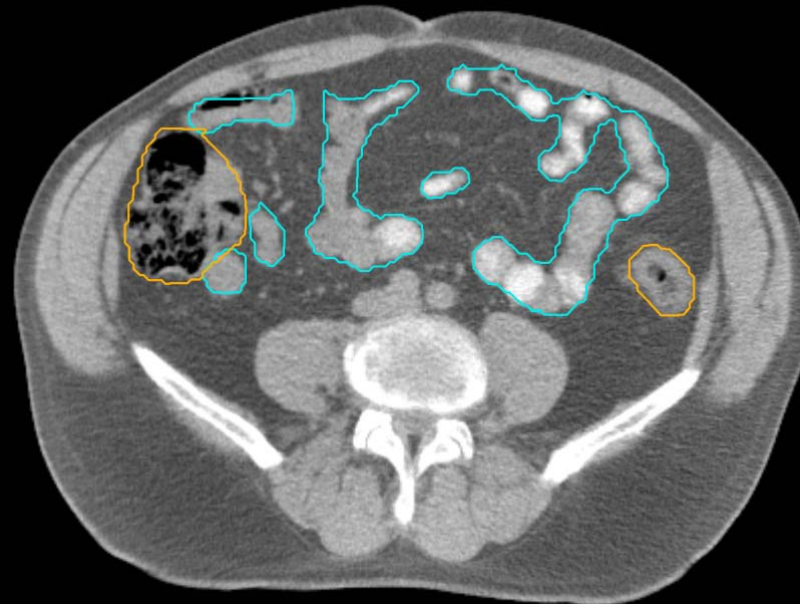GU:

- Rectum
- BowelBag



GU/GI:

- PenileBulb
- Bladder
- SeminalVesc
- Prostate
- Femur\_L
- Femur\_R

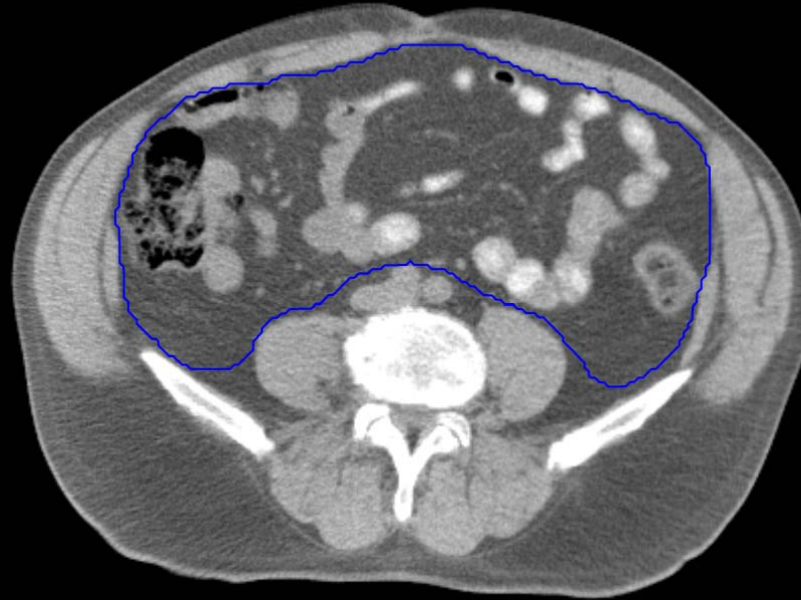

GI:

- Small Bowel
- AnoRectumSig
- Colon
- Mesorectum

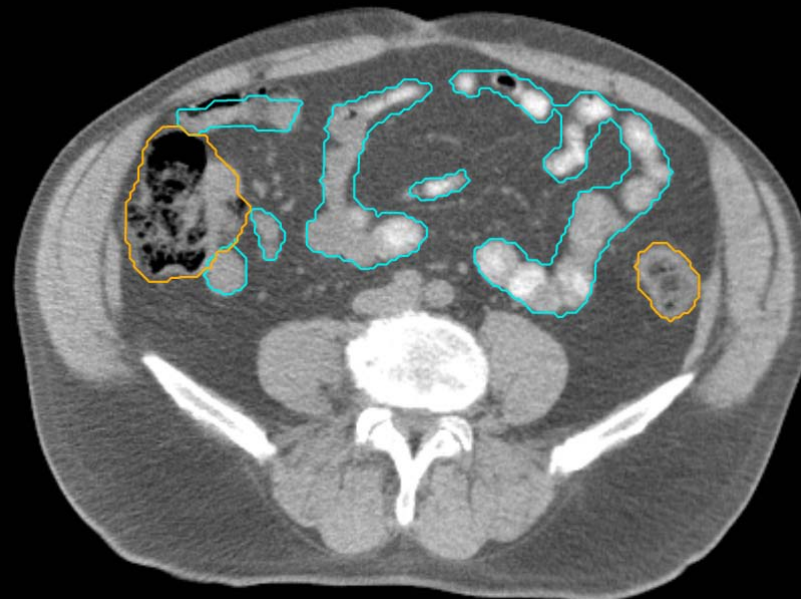
GU:

- Rectum
- BowelBag



GU/GI:

- PenileBulb
- Bladder
- SeminalVesc
- Prostate
- Femur\_L
- Femur\_R

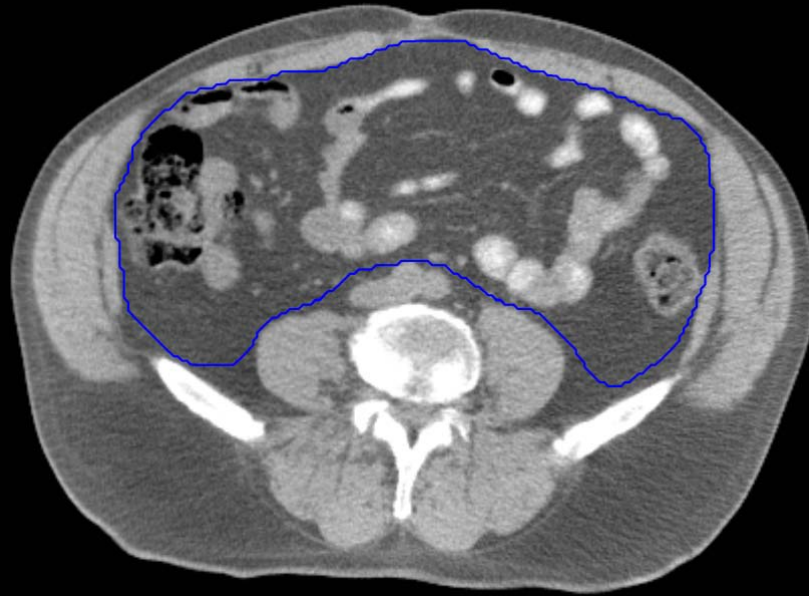

GI:

- Small Bowel
- AnoRectumSig
- Colon
- Mesorectum

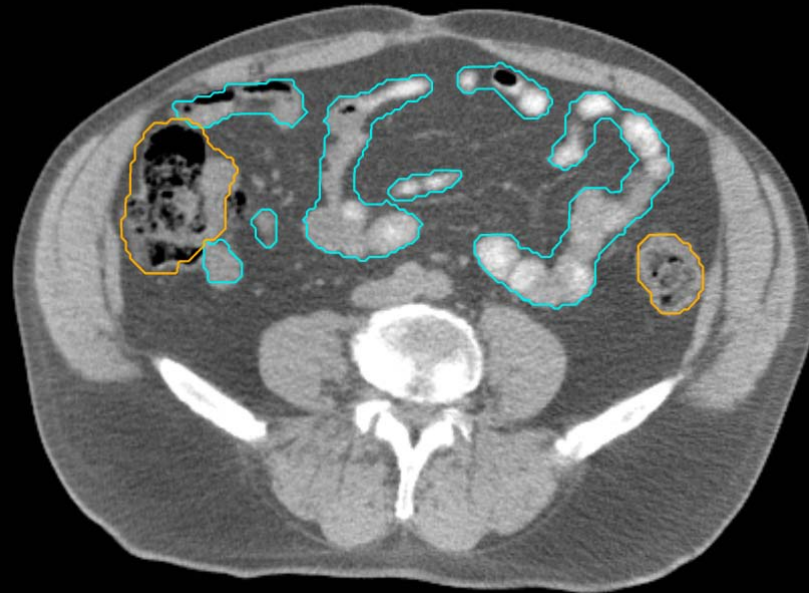
GU:

- Rectum
- BowelBag



GU/GI:

- PenileBulb
- Bladder
- SeminalVesc
- Prostate
- Femur\_L
- Femur\_R



GI:

- Small Bowel
- AnoRectumSig
- Colon
- Mesorectum