

# FEMALE PELVIS Normal Tissue RTOG Consensus Contouring Guidelines

# GYN

Organ	Standardized TPS Name	Tumor Category	Consensus Definition
anus + rectum	AnoRectum	GYN	Inferiorly from the anal verge as marked with a radiopaque marker at the time of simulation. Contouring ends superiorly before the rectum loses its round shape in the axial plane and connects anteriorly with the sigmoid. The AnoRectum is used with the Sigmoid and BowelBag.
sigmoid	Sigmoid	GYN	Bowel continuing where the AnoRectum contour ended. Stops prior to connecting to the ascending colon laterally. Contoured when a brachytherapy applicator rests in the uterus. Any sigmoid adjacent or above the uterus or a brachytherapy applicator should be contoured.
bowel bag	BowelBag	GYN	<p>* Inferiorly from the most inferior small or large bowel loop, or above the Rectum (GU) or AnoRectum (GYN), whichever is most inferior. If when following the bowel loop rule the Rectum or AnoRectum is present in that axial slice, it should be included as part of the bag; otherwise it should be excluded.</p> <p>Tips: Contour the abdominal contents excluding muscle and bones. Contour every other slice when the contour is not changing rapidly, and interpolate and edit as necessary. Finally, subtract any overlapping non-GI normal structures. If the TPS does not allow subtraction leave as is.</p>

\*Stop contouring the BowelBag, SmallBowel, and Colon 1 cm above PTV for most coplanar beam plans, but the choice will depend on the treatment technique. Stop these PTVs at distances much greater than 1 cm for non-coplanar beam plans depending on the beam angle and path. Tomotherapy plans will require stopping from 1 to 5 cm above the PTV, depending on the selected field size, which is often 2.5 cm.

Abbreviations: TPS = treatment planning software

# GYN/GI

Organ	Standardized TPS Name	Tumor Category	Consensus Definition
bladder	Bladder	GYN, GI	Inferiorly from its base, and superiorly to the dome
uterus + cervix	UteroCervix	GYN	The uterus and cervix as one structure. Tip: Fuse with MRI to help identify it.
ovaries + fallopian tubes	Adnexa_R Adnexa_L	GYN	Right and left ovary and fallopian tube. Tip: Fuse with MRI to help identify these. Refer to the article by Olson <i>et al.</i> PubMed ID: 1609137
proximal femurs	Femur_R Femur_L	GYN, GI	The proximal femur inferiorly from the lowest level of the ischial tuberosities (right or left) and superiorly to the top of the ball of the femur, including the trochanters.  Tips: Auto-contouring threshold parameters with bone can facilitate this process, but requires editing any auto-contouring artifacts.

# GI

Organ	Standardized TPS Name	Tumor Category	Consensus Definition
small bowel	SmallBowel	GI	* In order to distinguish from large bowel, the use of oral contrast is encouraged. After administration of contrast (e.g. 3 oz gastrograffin and 3 oz water/barium mixture) 30 minutes prior to scanning, the small bowel can be outlined as loops containing contrast.
colon	Colon	GI	* Large bowel continuing where the AnoRectumSig contour ended. Depending on the volume treated, this will include portions or all of the ascending, transverse, descending and sigmoid colon.

\*Stop contouring the BowelBag, SmallBowel, and Colon 1 cm above PTV for most coplanar beam plans, but the choice will depend on the treatment technique. Stop these PTVs at distances much greater than 1 cm for non-coplanar beam plans depending on the beam angle and path. Tomotherapy plans will require stopping from 1 to 5 cm above the PTV, depending on the selected field size, which is often 2.5 cm.

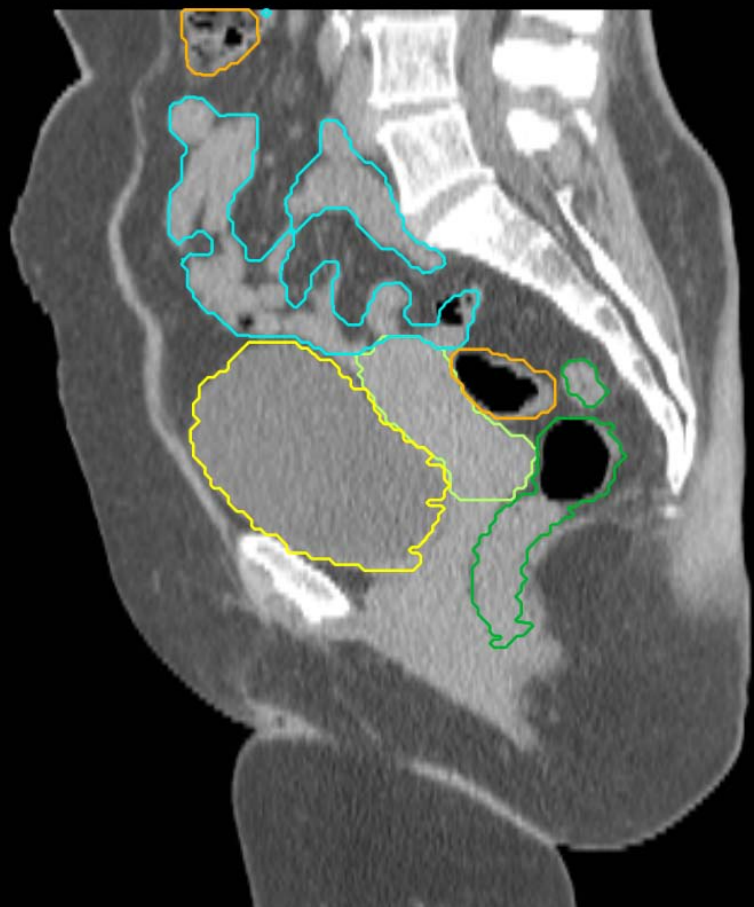# GI - target

Organ	Standardized TPS Name	Tumor Category	Consensus Definition
anus + rectum + rectosigmoid <b>(target)</b>	AnoRectumSig	GI	Target structure. Inferiorly from the anal verge as marked with a radiopaque marker at time of simulation. Contouring ends superiorly at the rectosigmoid flexure after the mesorectum disappears. The AnoRectumSig is used with the Small Bowel and Colon.
mesorectum <b>(target)</b>	Mesorectum	GI	Target structure for anal and rectal cancer. The rectum inferiorly below where the mesorectal fat disappears, and continuing superiorly and encompassing the mesorectal fat until the mesorectal fascia disappears. For these entities, the AnoRectoSig (anus + rectum + rectosigmoid), unlike the rest of the alimentary canal, is NOT an avoidance structure.

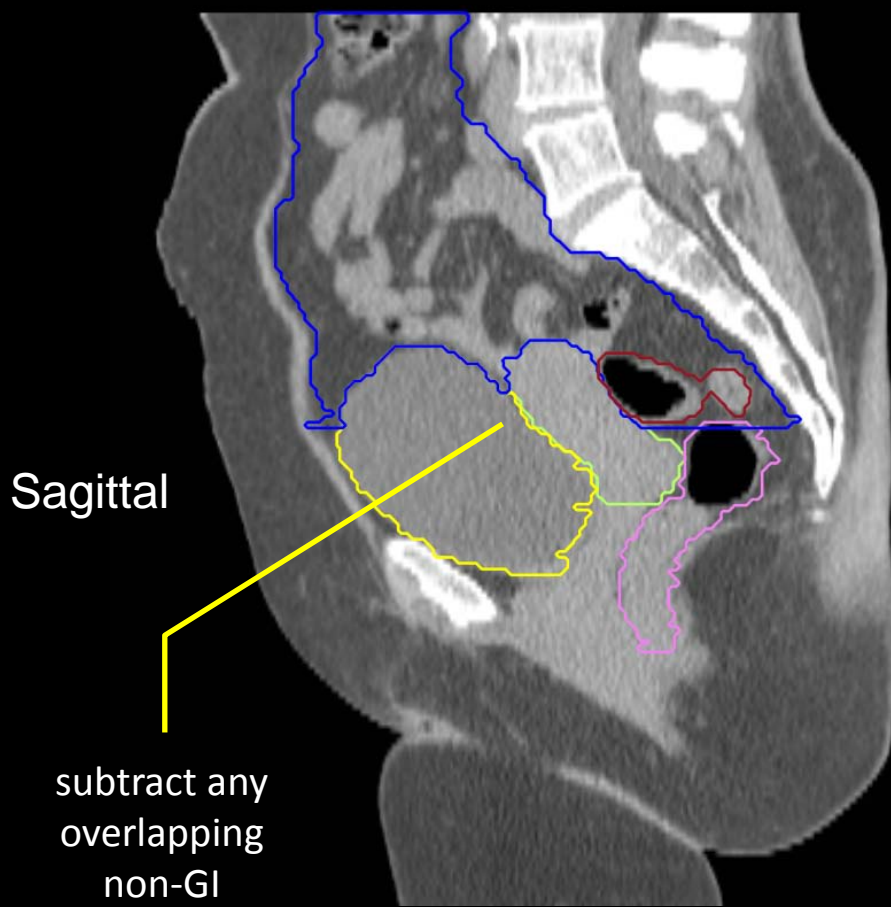
In cases where it is difficult to visualize the mesorectum, the anatomical borders of the mesorectum include: cranial, the level of the recto-sigmoid junction; caudal, the anorectal junction defined by where the levator muscles fuse with the external sphincter muscles (or where the mesorectal fat/space can no longer be seen tapering inferiorly); posterior, pre-sacral space; anterior, GU/GYN organs with an internal margin of 10 mm to the anterior mesorectal border on the axial slices of the bladder to account for bladder volume variation on this boundary; lateral-medial edge of the levator ani in the lower pelvis and pelvic brim in upper (excluding any non-target muscle).

Tip: Adjusting the windowing level may facilitate visualizing the mesorectum.

Contour BowelBag, Colon and SmallBowel the recommended cm above PTV, not necessarily this high



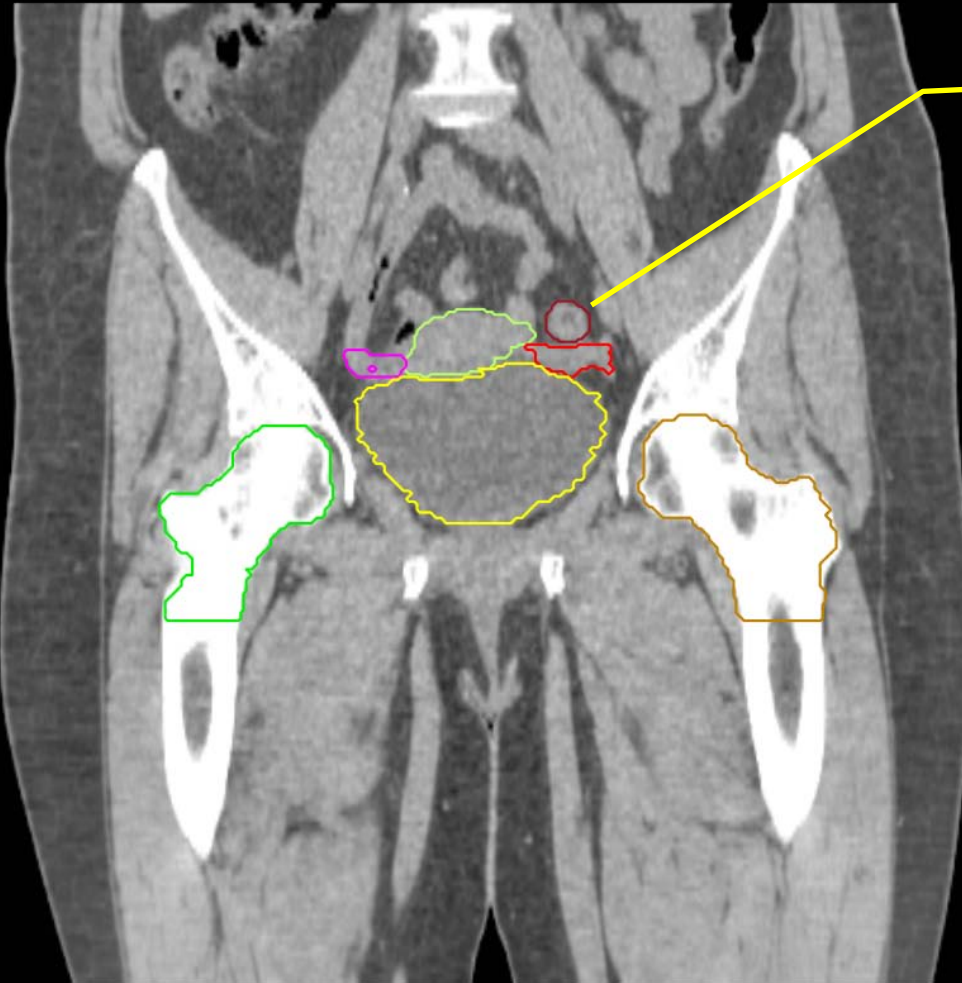
- Small Bowel
- AnoRectumSig
- Colon
- UteroCervix
- Bladder



Sagittal  
subtract any overlapping non-GI normal structures from BowelBag

- Sigmoid
- AnoRectum
- BowelBag
- UteroCervix
- Bladder

- Sigmoid
- UteroCervix
- Femur\_L
- Femur\_R
- Adnexa\_R
- Adnexa\_L
- Bladder



Any sigmoid adjacent or above the uterus or a brachytherapy applicator should be contoured.

Coronal

GYN:

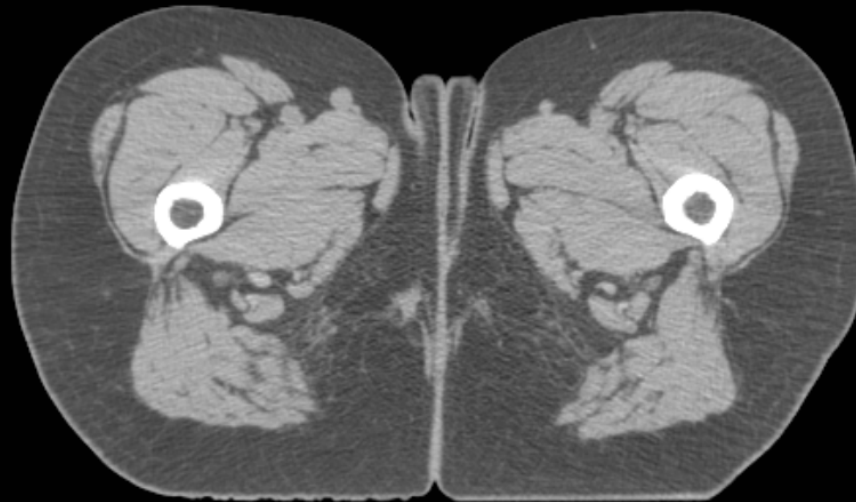
- Sigmoid
- AnoRectum
- BowelBag

GYN/GI:

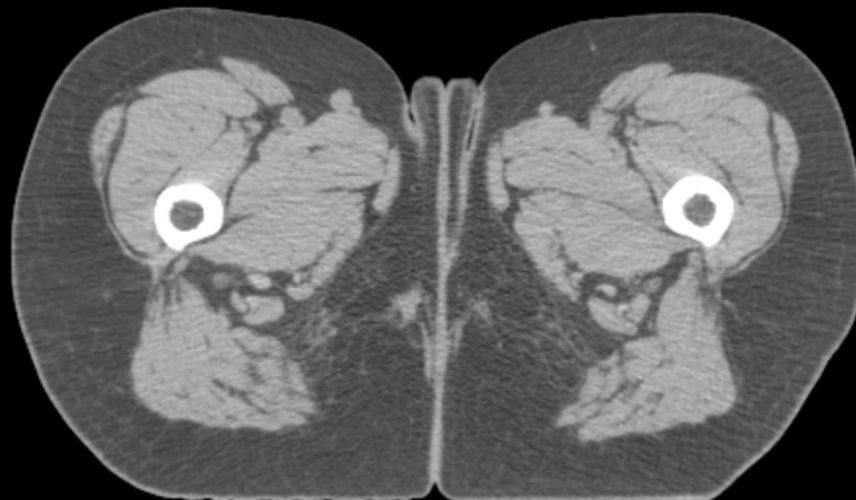
- UteroCervix
- Femur\_L
- Femur\_R
- Adnexa\_R
- Adnexa\_L
- Bladder

GI:

- Small Bowel
- AnoRectumSig
- Colon



Axial





GYN:

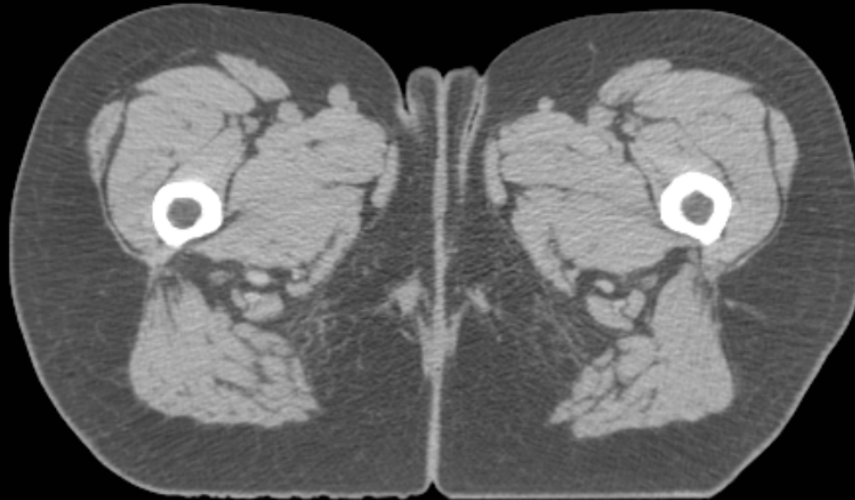
- Sigmoid
- AnoRectum
- BowelBag

GYN/GI:

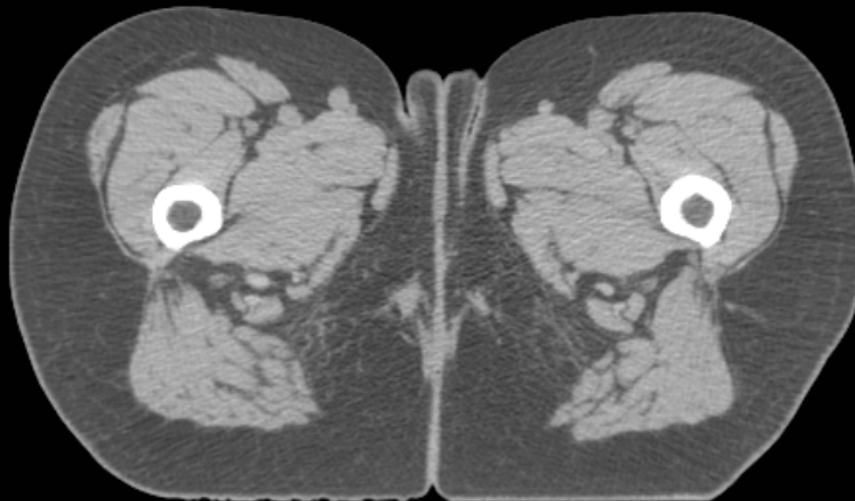
- UteroCervix
- Femur\_L
- Femur\_R
- Adnexa\_R
- Adnexa\_L
- Bladder

GI:

- Small Bowel
- AnoRectumSig
- Colon



It is an excellent habit to always use the standardized nomenclature, even if the patient is not in a protocol



GYN:

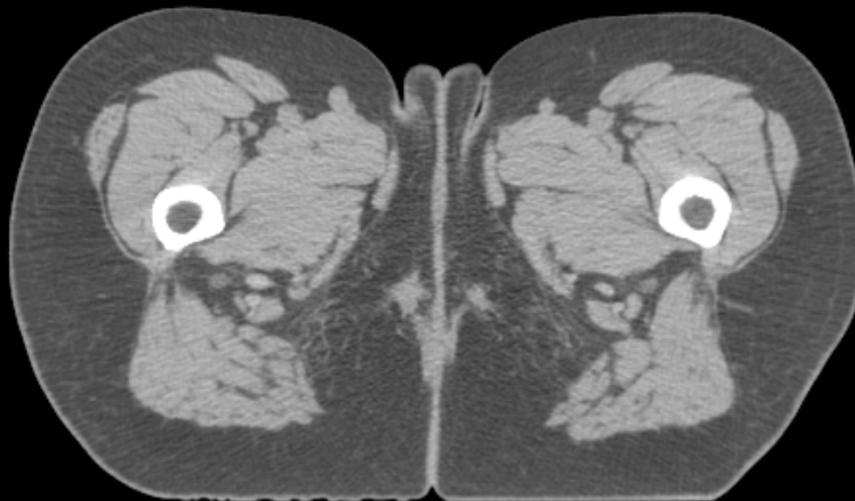
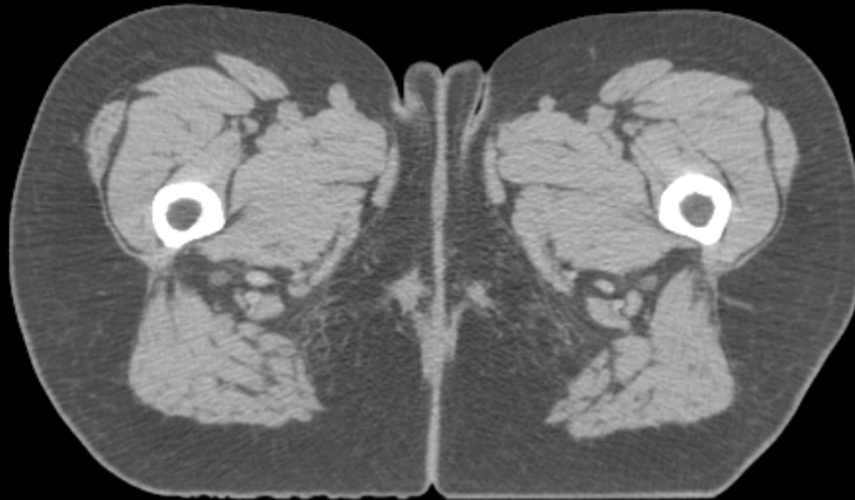
- Sigmoid
- AnoRectum
- BowelBag

GYN/GI:

- UteroCervix
- Femur\_L
- Femur\_R
- Adnexa\_R
- Adnexa\_L
- Bladder

GI:

- Small Bowel
- AnoRectumSig
- Colon



GYN:

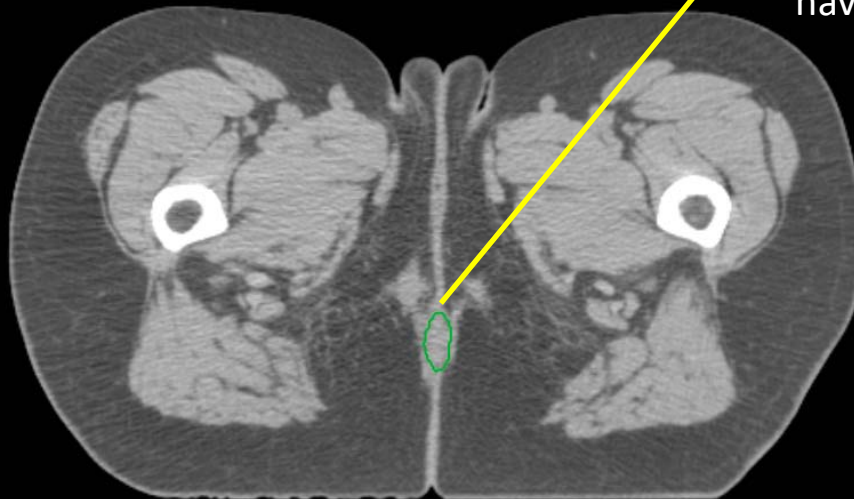
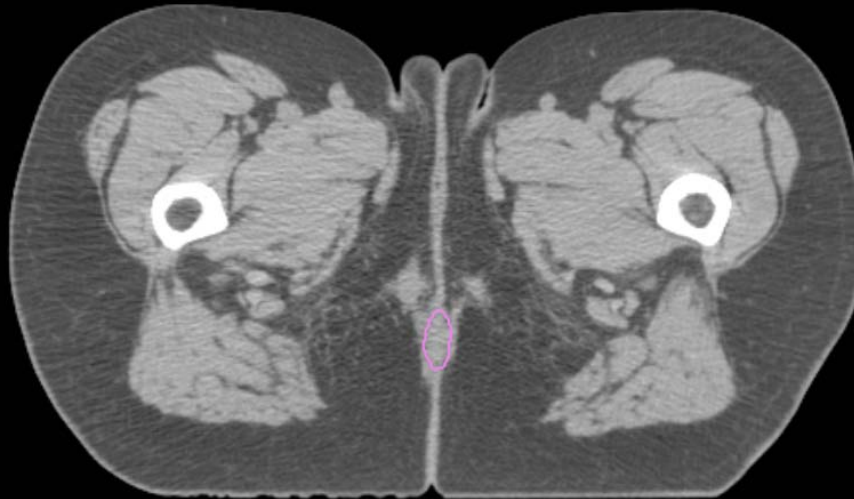
- Sigmoid
- AnoRectum
- BowelBag

GYN/GI:

- UteroCervix
- Femur\_L
- Femur\_R
- Adnexa\_R
- Adnexa\_L
- Bladder

GI:

- Small Bowel
- AnoRectumSig
- Colon



A radiopaque marker would have helped better identify the anal verge

GYN:

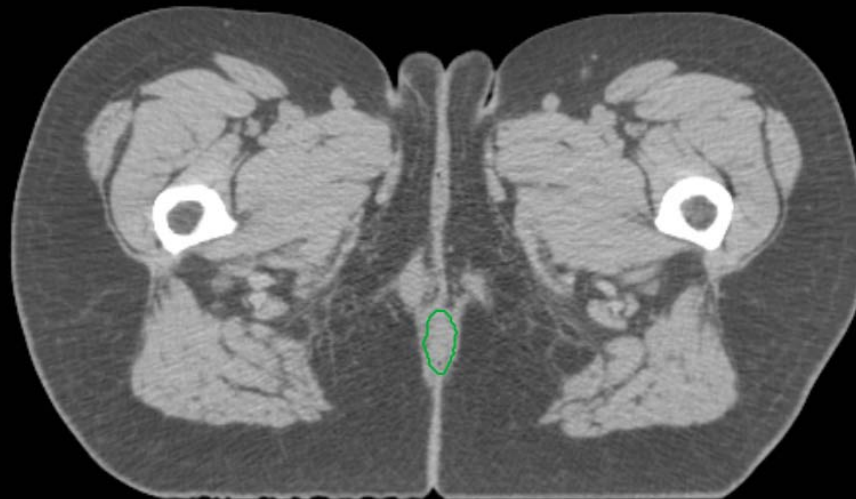
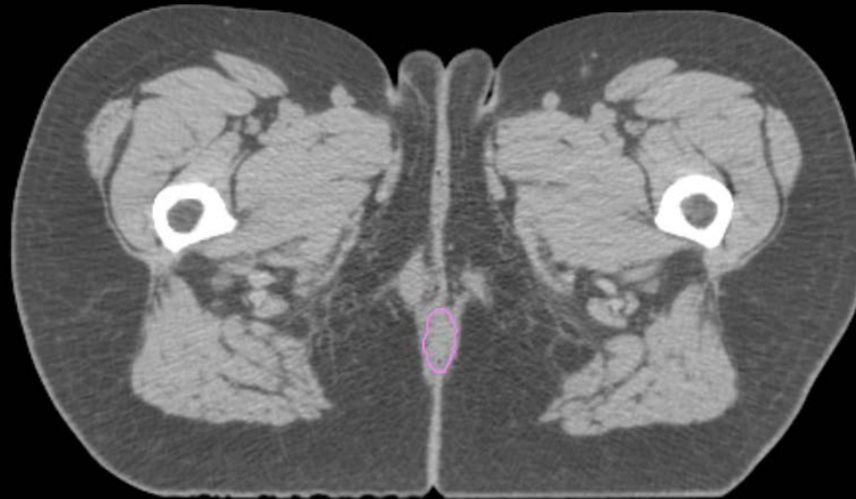
- Sigmoid
- AnoRectum
- BowelBag

GYN/GI:

- UteroCervix
- Femur\_L
- Femur\_R
- Adnexa\_R
- Adnexa\_L
- Bladder

GI:

- Small Bowel
- AnoRectumSig
- Colon



GYN:

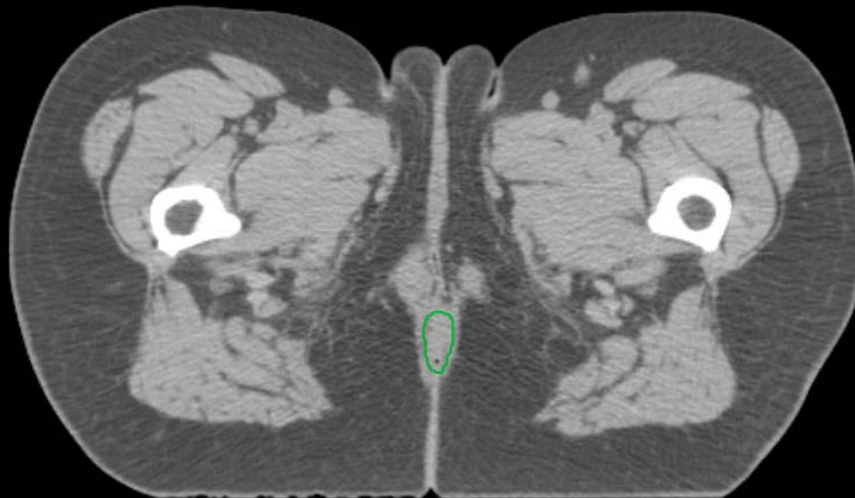
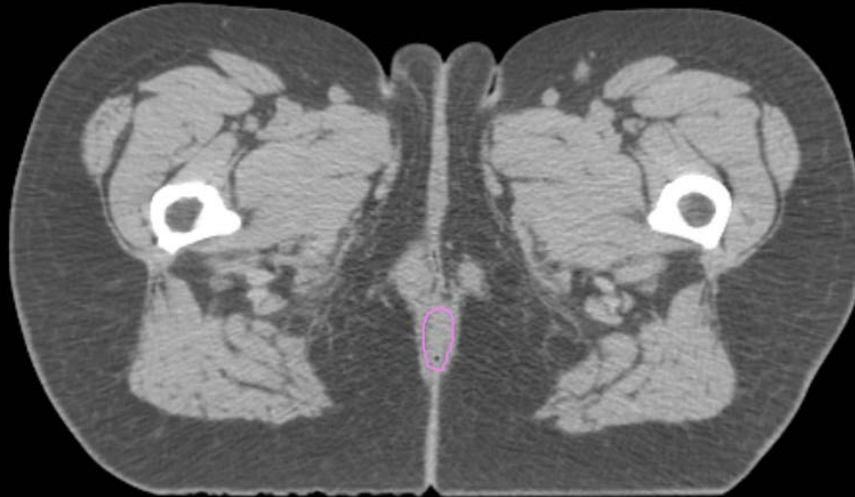
- Sigmoid
- AnoRectum
- BowelBag

GYN/GI:

- UteroCervix
- Femur\_L
- Femur\_R
- Adnexa\_R
- Adnexa\_L
- Bladder

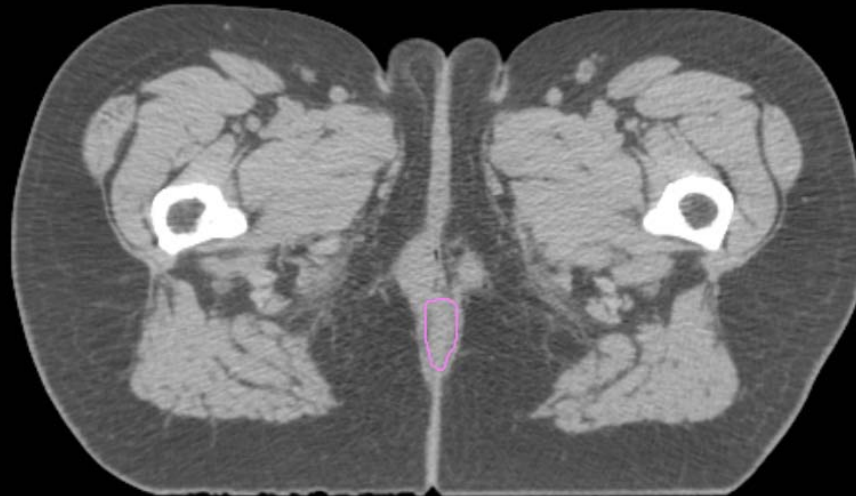
GI:

- Small Bowel
- AnoRectumSig
- Colon



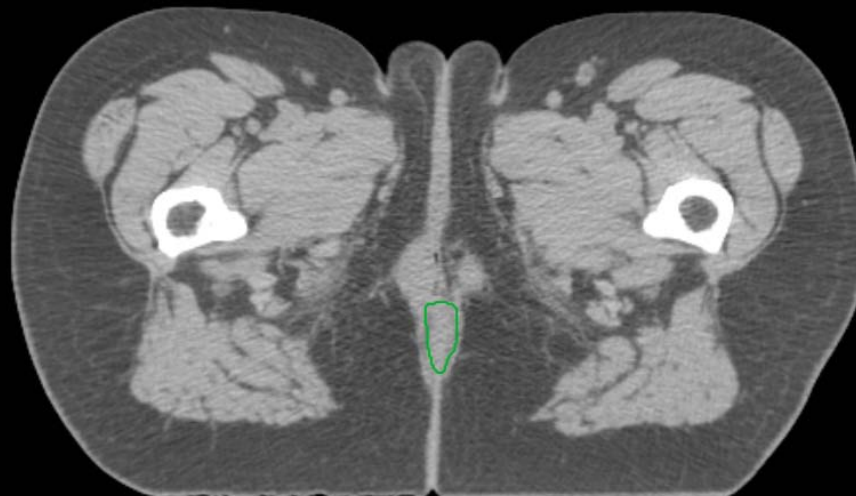
GYN:

- Sigmoid
- AnoRectum
- BowelBag



GYN/GI:

- UteroCervix
- Femur\_L
- Femur\_R
- Adnexa\_R
- Adnexa\_L
- Bladder



GI:

- Small Bowel
- AnoRectumSig
- Colon

GYN:

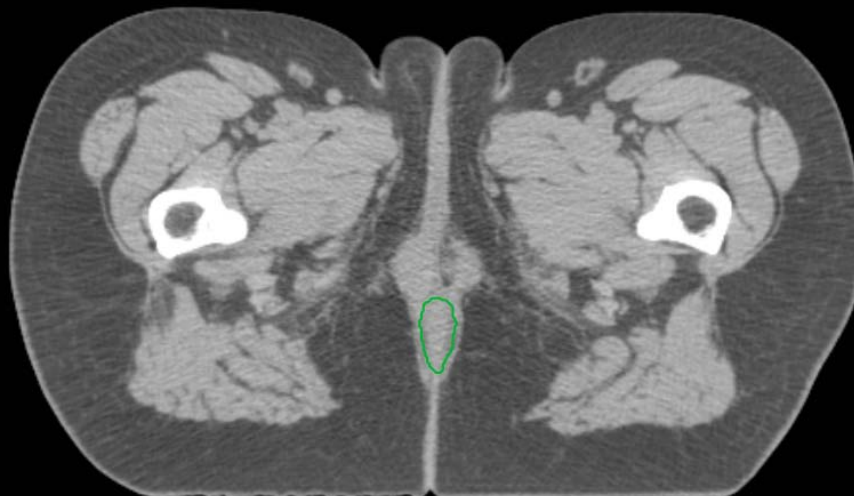
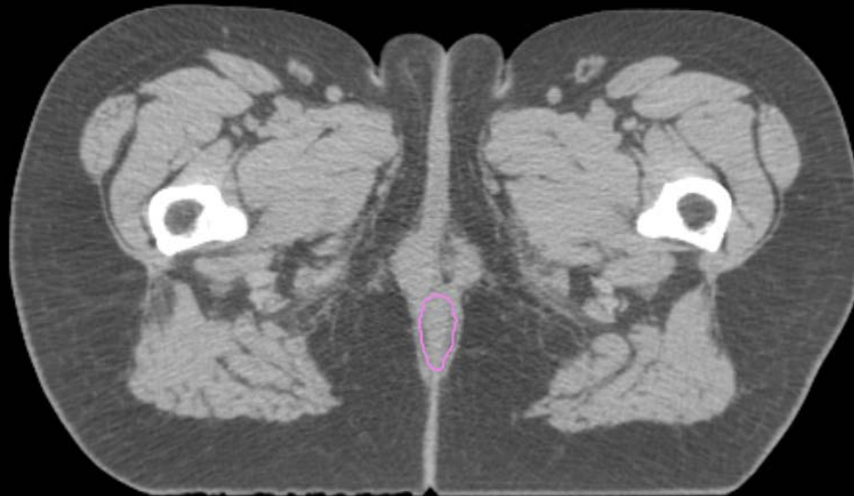
- Sigmoid
- AnoRectum
- BowelBag

GYN/GI:

- UteroCervix
- Femur\_L
- Femur\_R
- Adnexa\_R
- Adnexa\_L
- Bladder

GI:

- Small Bowel
- AnoRectumSig
- Colon



GYN:

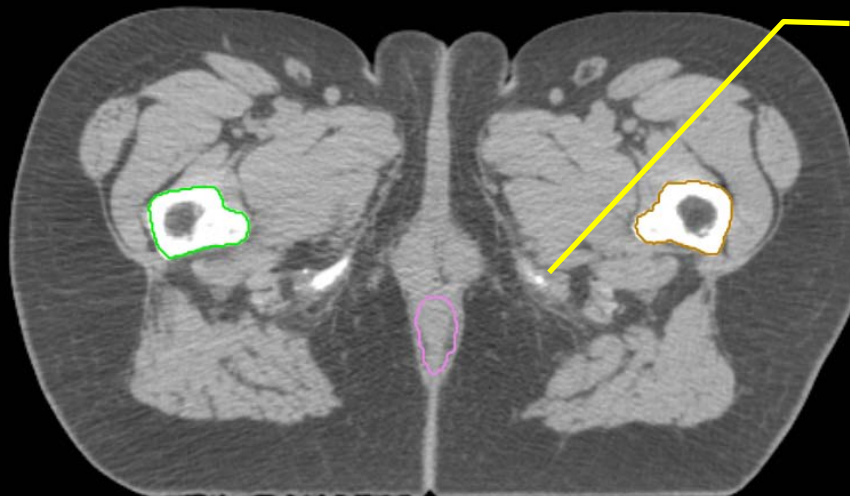
- Sigmoid
- AnoRectum
- BowelBag

GYN/GI:

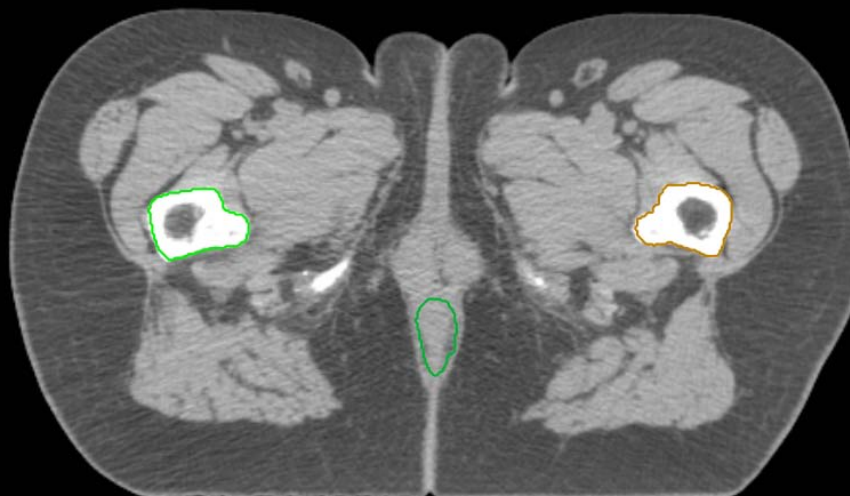
- UteroCervix
- Femur\_L
- Femur\_R
- Adnexa\_R
- Adnexa\_L
- Bladder

GI:

- Small Bowel
- AnoRectumSig
- Colon



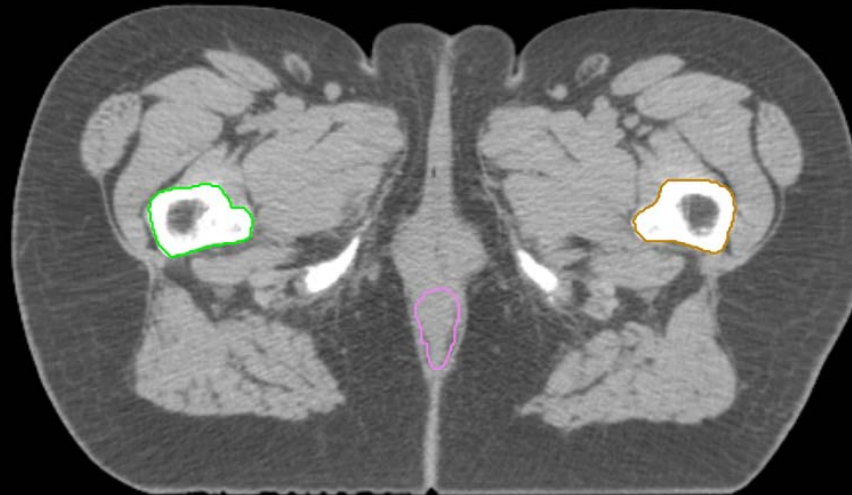
lowest level of ischial tuberosities, this is where Femur\_L and Femur\_R start





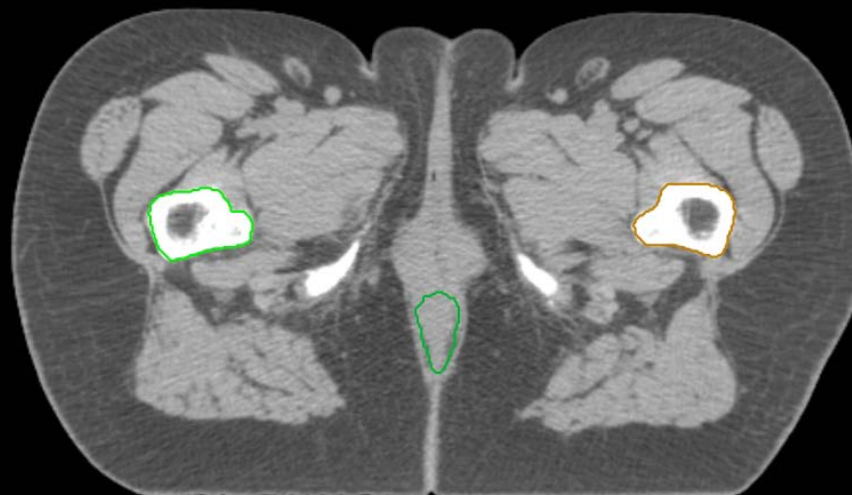
GYN:

- Sigmoid
- AnoRectum
- BowelBag



GYN/GI:

- UteroCervix
- Femur\_L
- Femur\_R
- Adnexa\_R
- Adnexa\_L
- Bladder



GI:

- Small Bowel
- AnoRectumSig
- Colon

GYN:

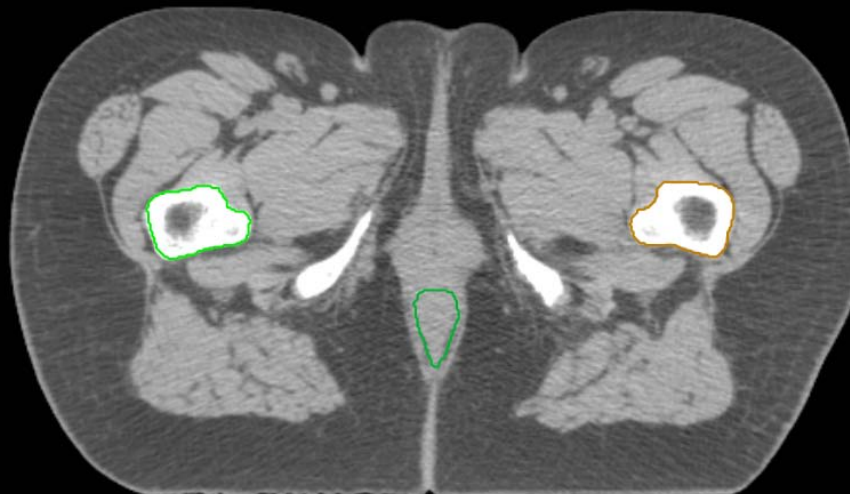
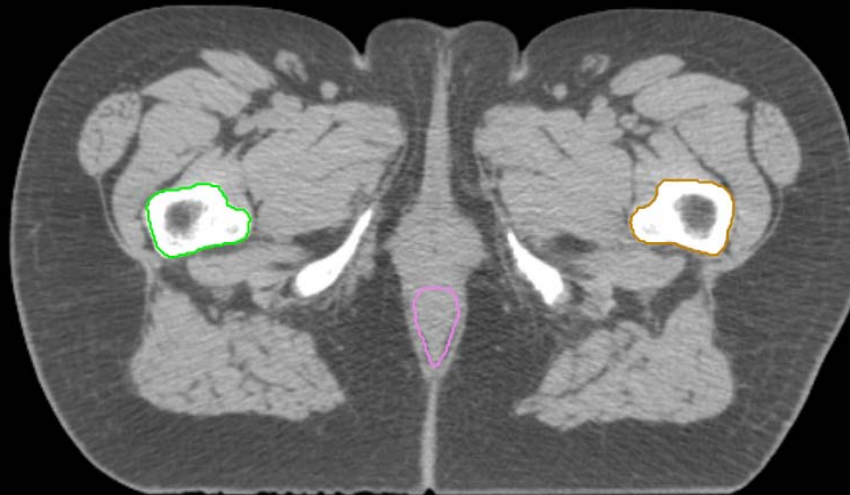
- Sigmoid
- AnoRectum
- BowelBag

GYN/GI:

- UteroCervix
- Femur\_L
- Femur\_R
- Adnexa\_R
- Adnexa\_L
- Bladder

GI:

- Small Bowel
- AnoRectumSig
- Colon



GYN:

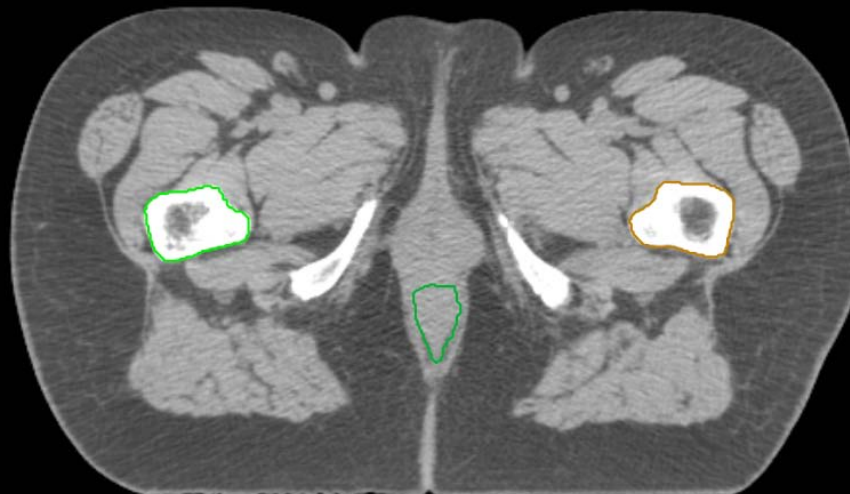
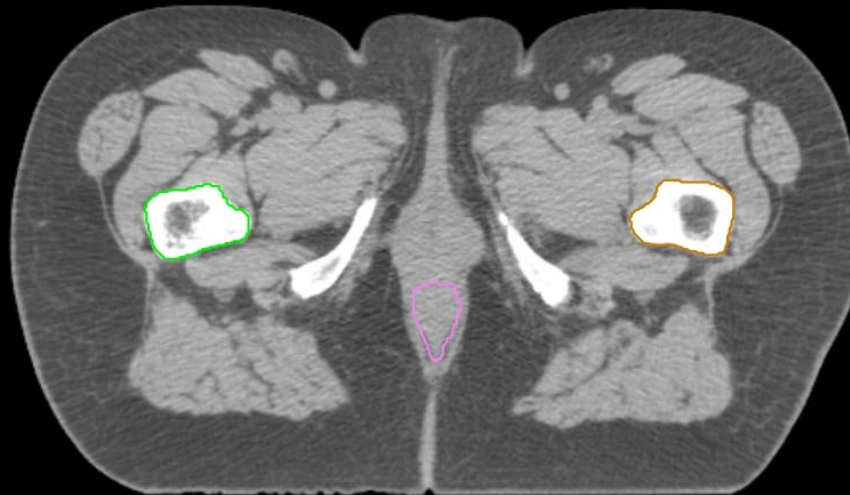
- Sigmoid
- AnoRectum
- BowelBag

GYN/GI:

- UteroCervix
- Femur\_L
- Femur\_R
- Adnexa\_R
- Adnexa\_L
- Bladder

GI:

- Small Bowel
- AnoRectumSig
- Colon



GYN:

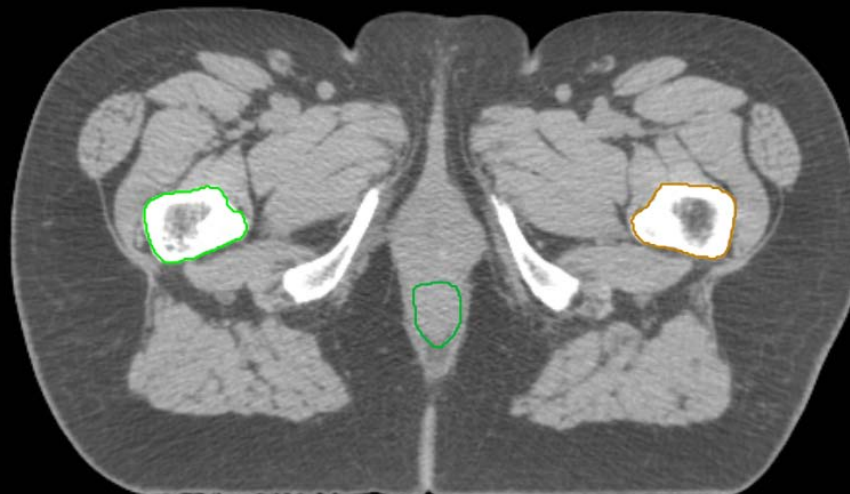
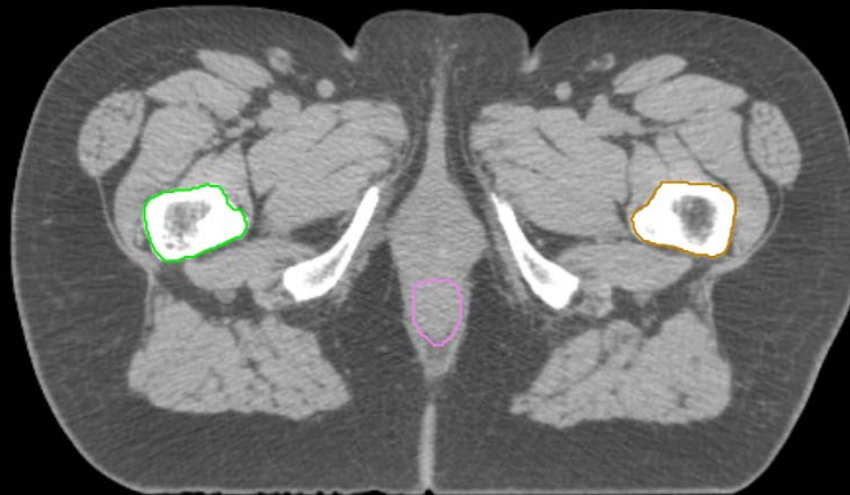
- Sigmoid
- AnoRectum
- BowelBag

GYN/GI:

- UteroCervix
- Femur\_L
- Femur\_R
- Adnexa\_R
- Adnexa\_L
- Bladder

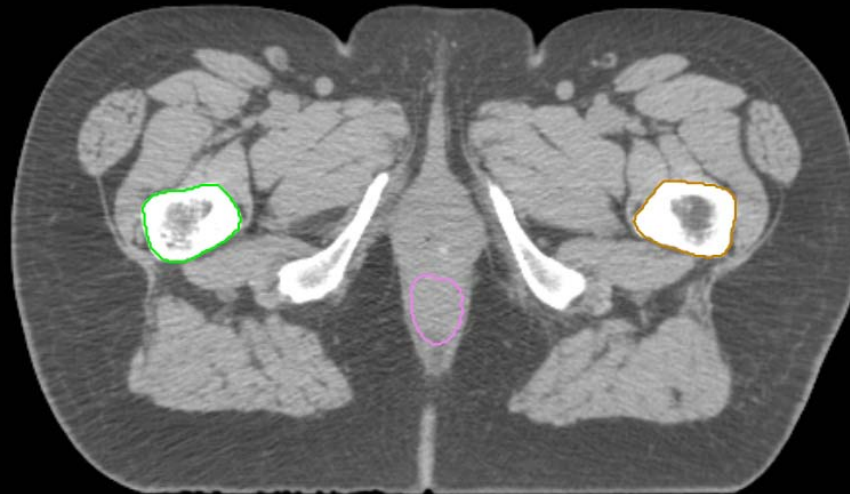
GI:

- Small Bowel
- AnoRectumSig
- Colon



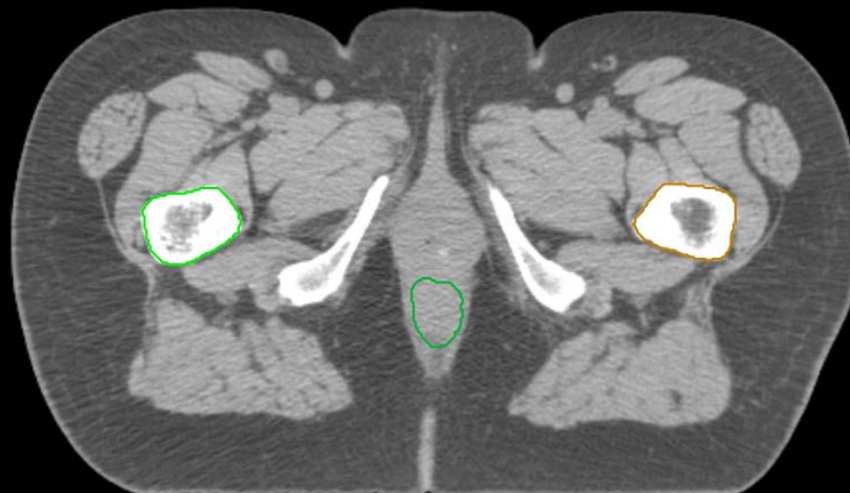
GYN:

- Sigmoid
- AnoRectum
- BowelBag



GYN/GI:

- UteroCervix
- Femur\_L
- Femur\_R
- Adnexa\_R
- Adnexa\_L
- Bladder

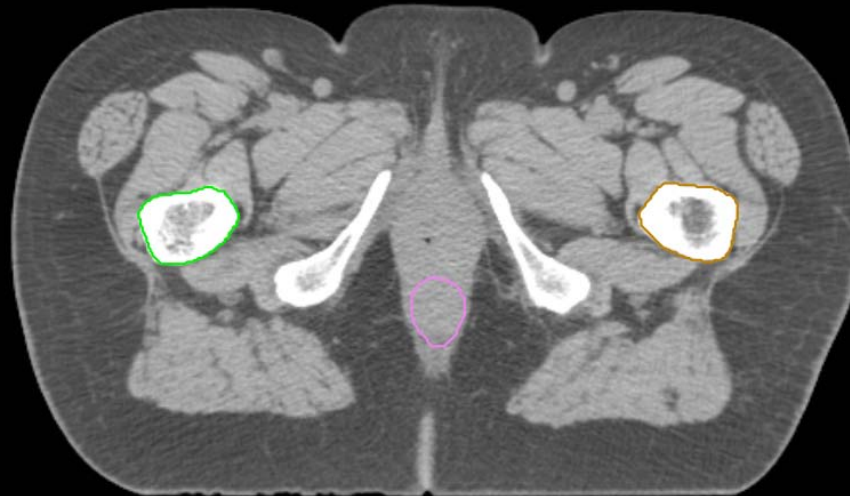


GI:

- Small Bowel
- AnoRectumSig
- Colon

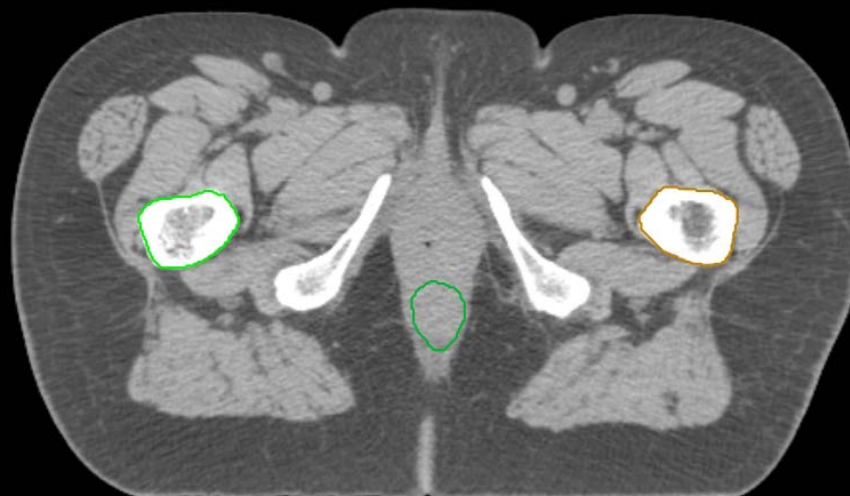
GYN:

- Sigmoid
- AnoRectum
- BowelBag



GYN/GI:

- UteroCervix
- Femur\_L
- Femur\_R
- Adnexa\_R
- Adnexa\_L
- Bladder



GI:

- Small Bowel
- AnoRectumSig
- Colon

GYN:

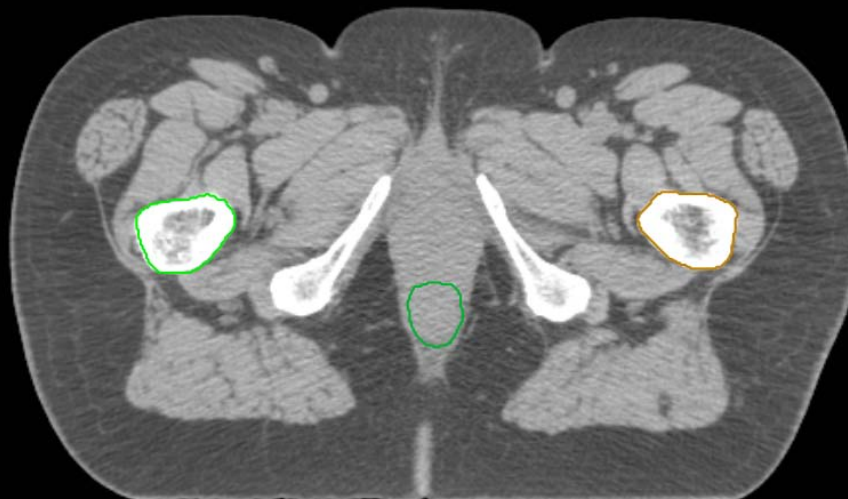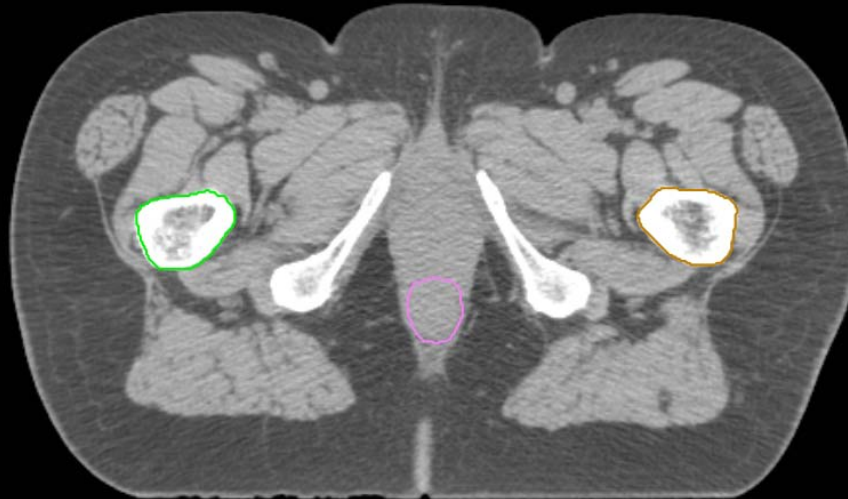
- Sigmoid
- AnoRectum
- BowelBag

GYN/GI:

- UteroCervix
- Femur\_L
- Femur\_R
- Adnexa\_R
- Adnexa\_L
- Bladder

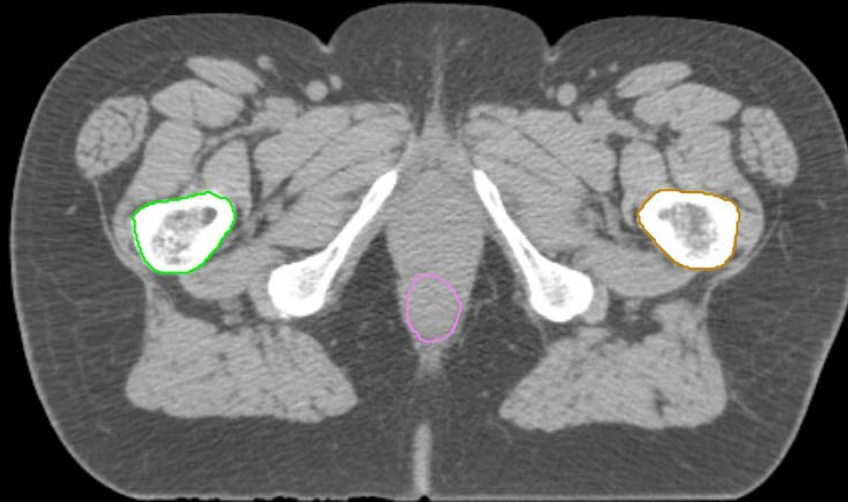
GI:

- Small Bowel
- AnoRectumSig
- Colon



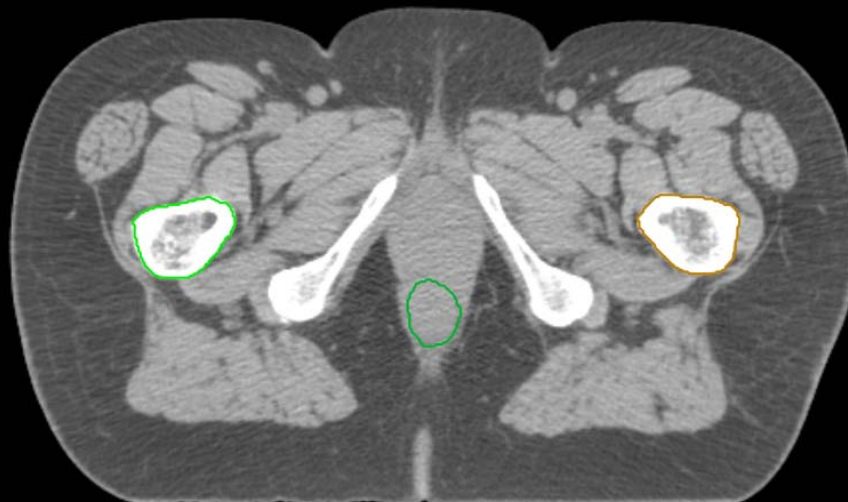
GYN:

- Sigmoid
- AnoRectum
- BowelBag



GYN/GI:

- UteroCervix
- Femur\_L
- Femur\_R
- Adnexa\_R
- Adnexa\_L
- Bladder



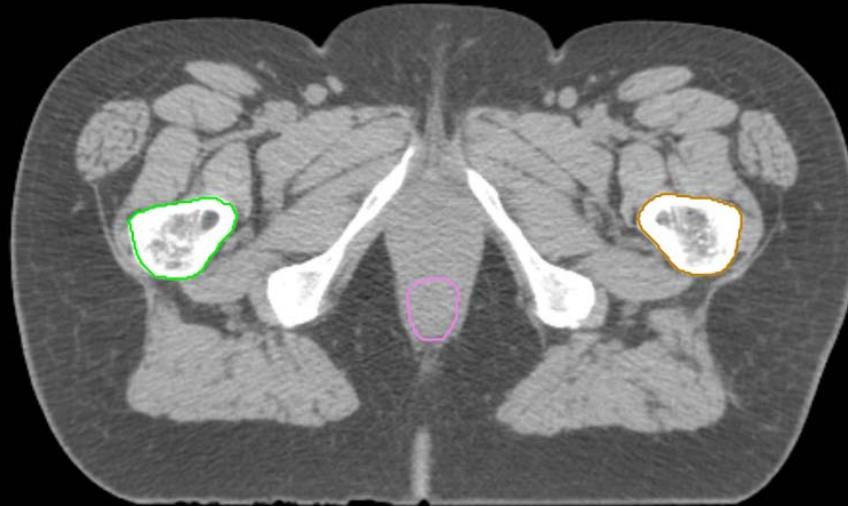
GI:

- Small Bowel
- AnoRectumSig
- Colon



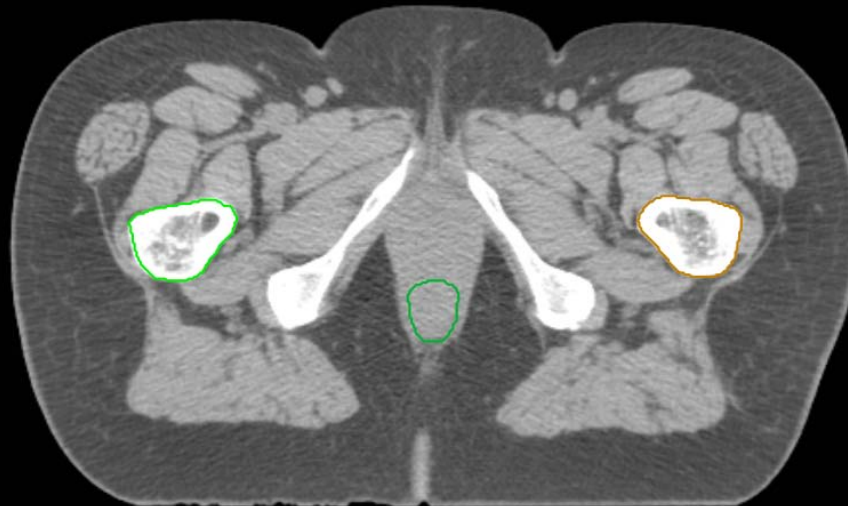
GYN:

- Sigmoid
- AnoRectum
- BowelBag



GYN/GI:

- UteroCervix
- Femur\_L
- Femur\_R
- Adnexa\_R
- Adnexa\_L
- Bladder

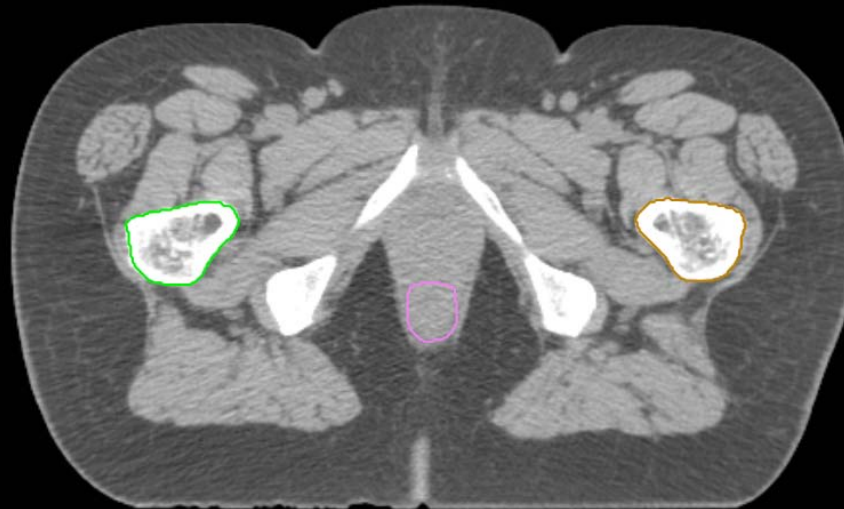

GI:

- Small Bowel
- AnoRectumSig
- Colon

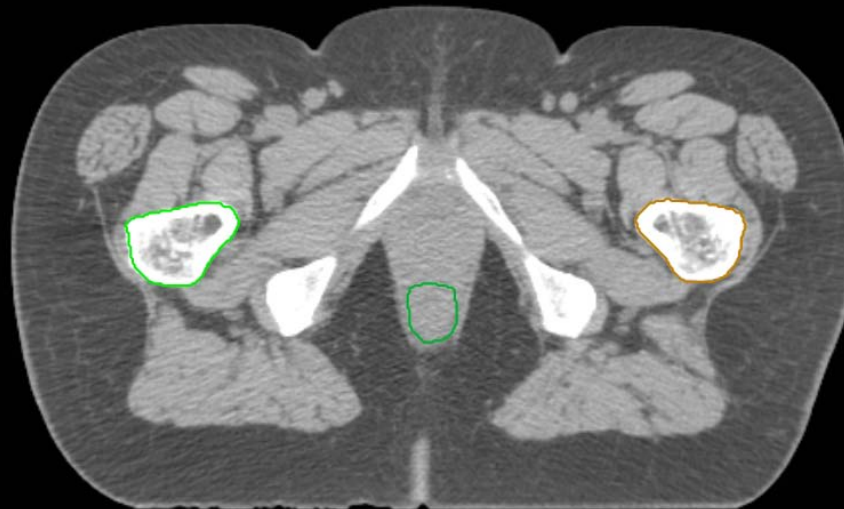GYN:

- Sigmoid
- AnoRectum
- BowelBag



GYN/GI:

- UteroCervix
- Femur\_L
- Femur\_R
- Adnexa\_R
- Adnexa\_L
- Bladder



GI:

- Small Bowel
- AnoRectumSig
- Colon

GYN:

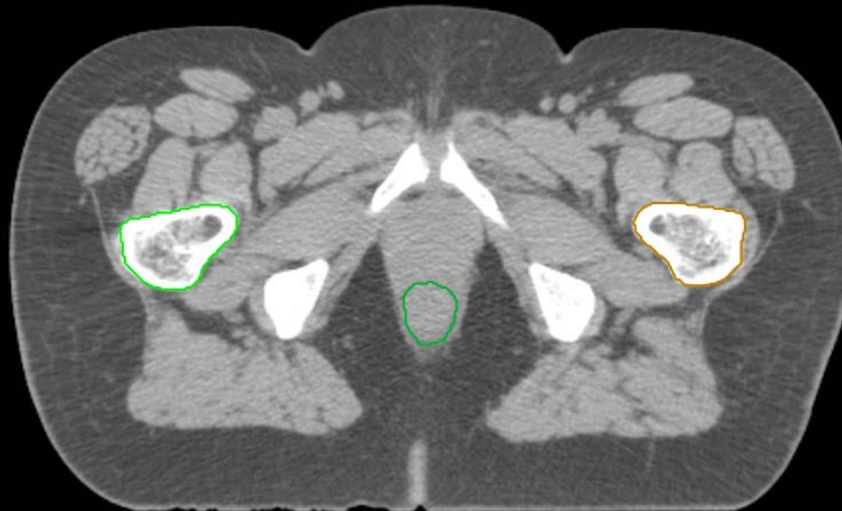
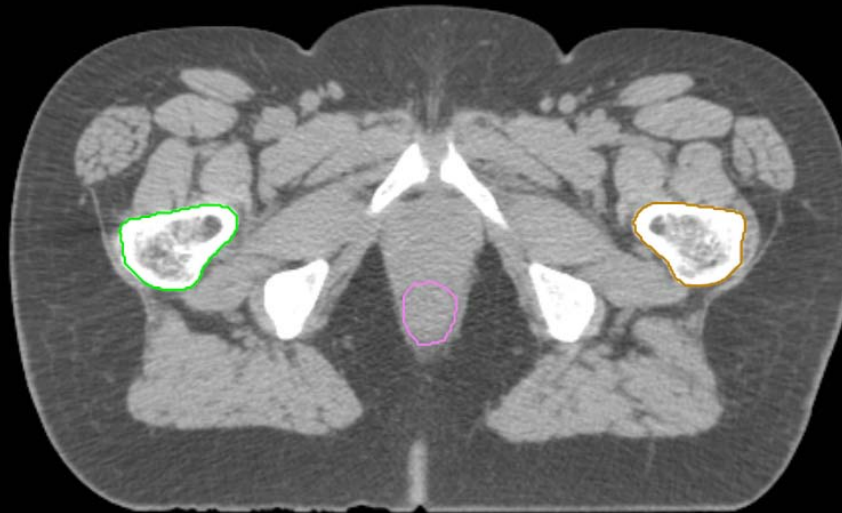
- Sigmoid
- AnoRectum
- BowelBag

GYN/GI:

- UteroCervix
- Femur\_L
- Femur\_R
- Adnexa\_R
- Adnexa\_L
- Bladder

GI:

- Small Bowel
- AnoRectumSig
- Colon



GYN:

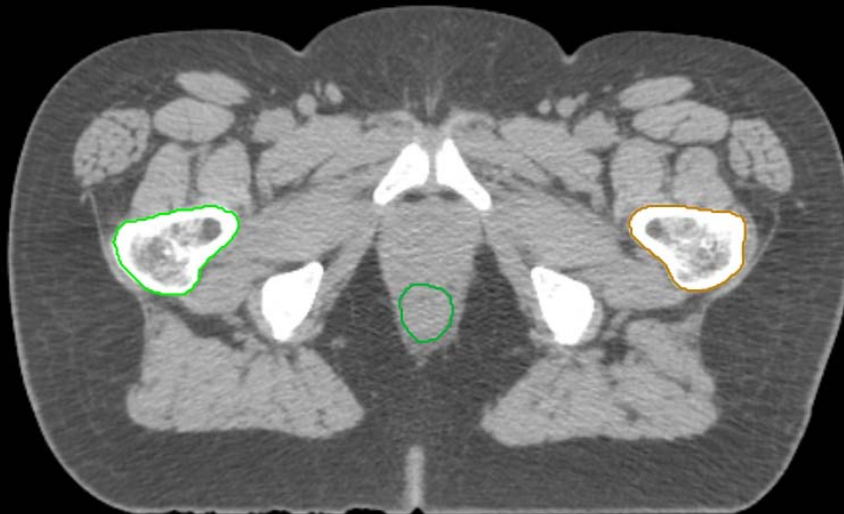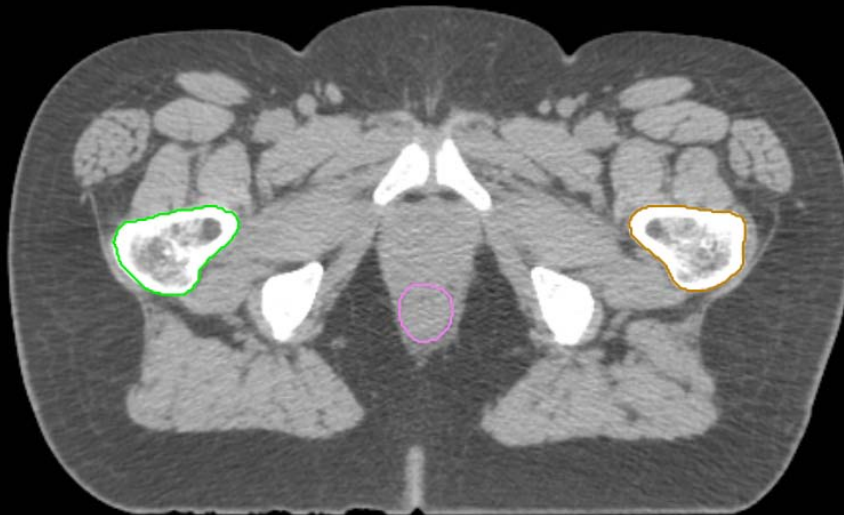
- Sigmoid
- AnoRectum
- BowelBag

GYN/GI:

- UteroCervix
- Femur\_L
- Femur\_R
- Adnexa\_R
- Adnexa\_L
- Bladder

GI:

- Small Bowel
- AnoRectumSig
- Colon



GYN:

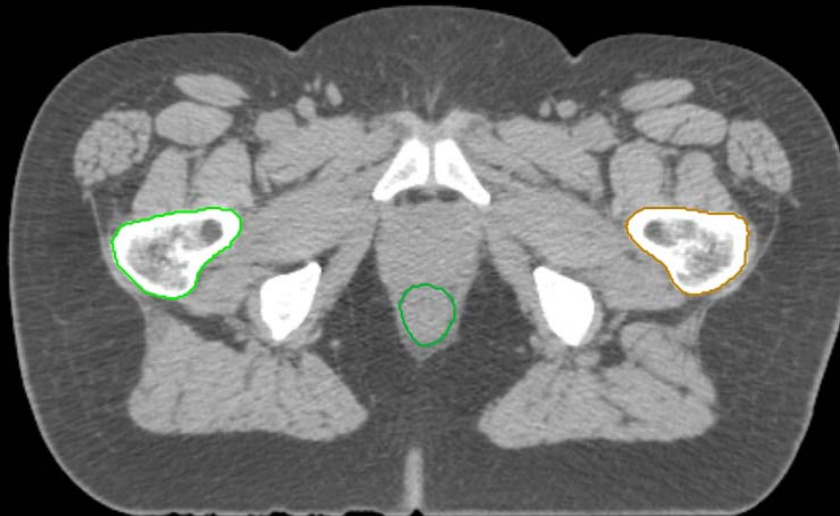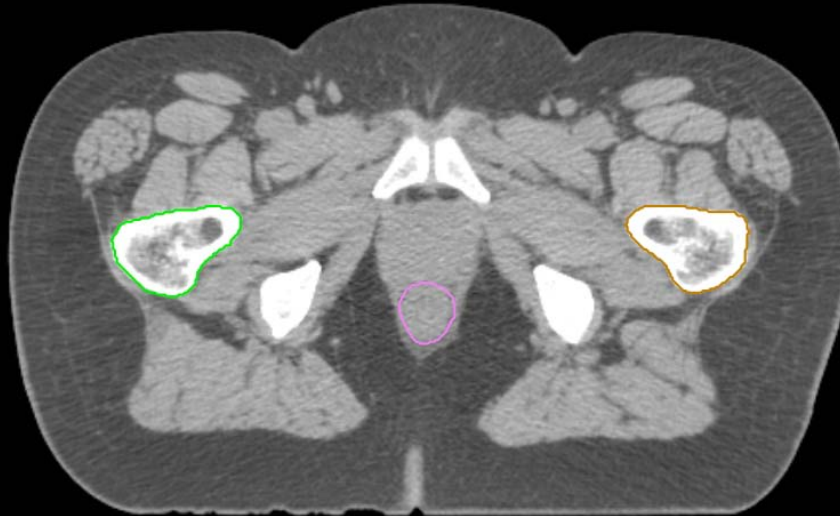
- Sigmoid
- AnoRectum
- BowelBag

GYN/GI:

- UteroCervix
- Femur\_L
- Femur\_R
- Adnexa\_R
- Adnexa\_L
- Bladder

GI:

- Small Bowel
- AnoRectumSig
- Colon



GYN:

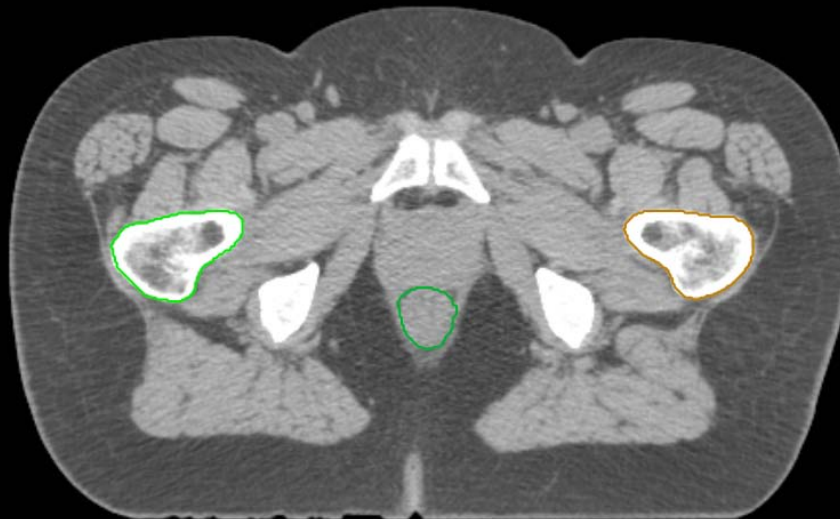
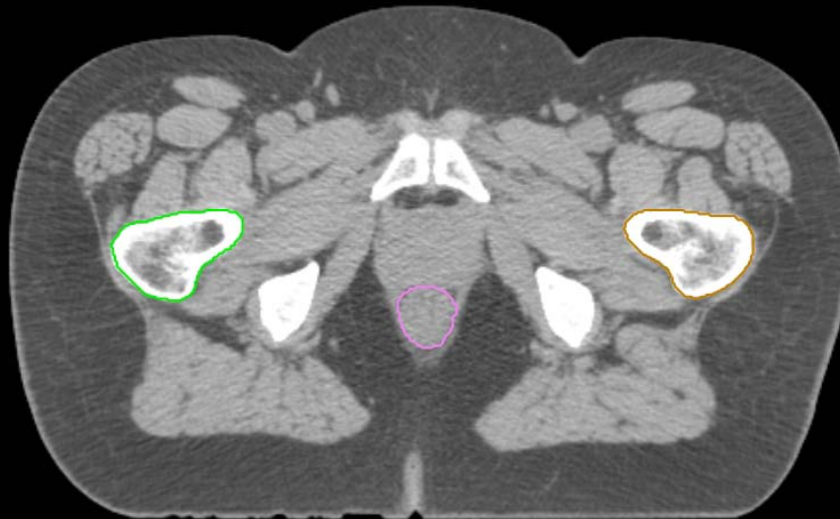
- Sigmoid
- AnoRectum
- BowelBag

GYN/GI:

- UteroCervix
- Femur\_L
- Femur\_R
- Adnexa\_R
- Adnexa\_L
- Bladder

GI:

- Small Bowel
- AnoRectumSig
- Colon



GYN:

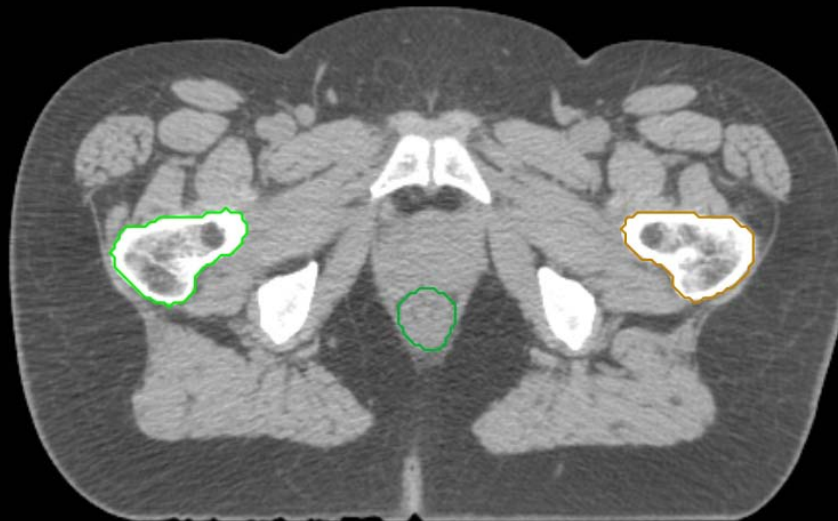
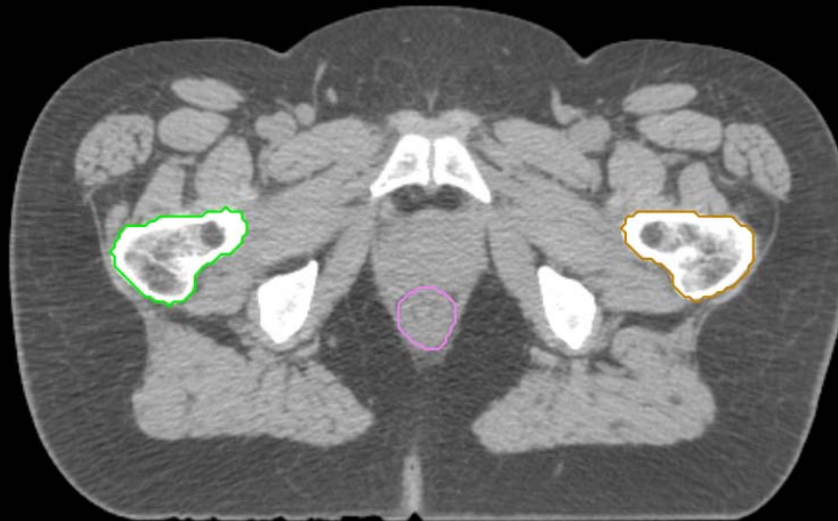- Sigmoid
- AnoRectum
- BowelBag

GYN/GI:

- UteroCervix
- Femur\_L
- Femur\_R
- Adnexa\_R
- Adnexa\_L
- Bladder

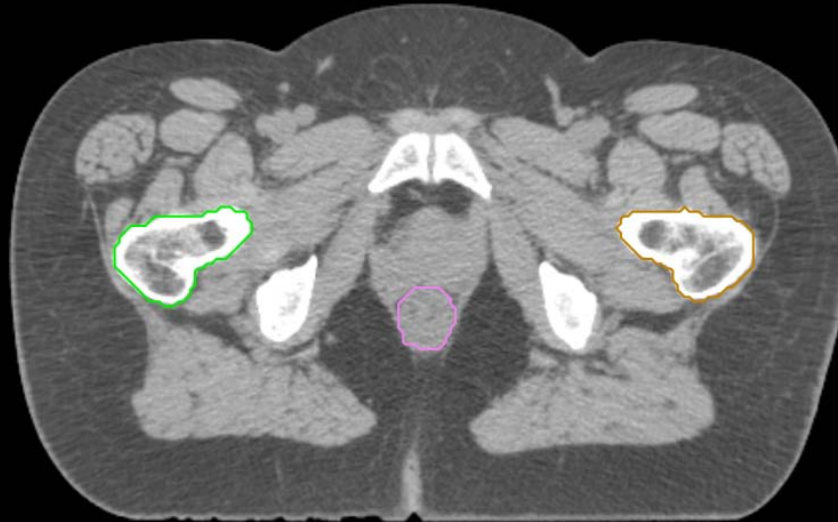
GI:

- Small Bowel
- AnoRectumSig
- Colon



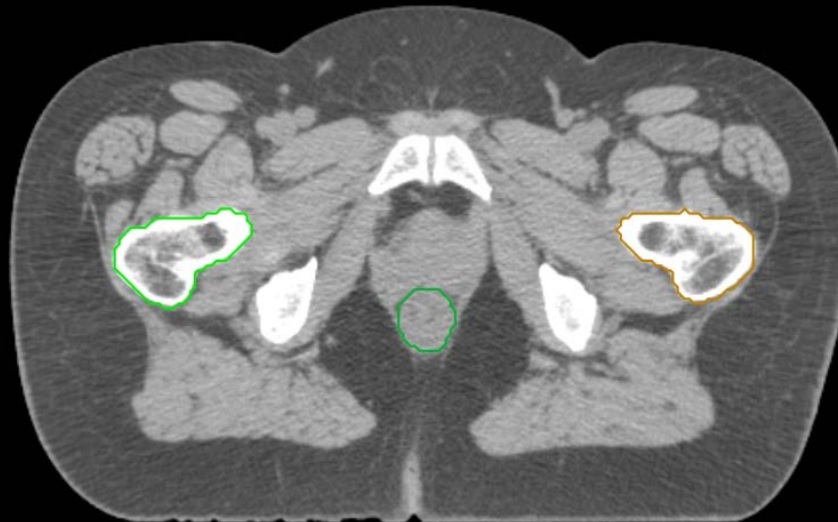
GYN:

- Sigmoid
- AnoRectum
- BowelBag



GYN/GI:

- UteroCervix
- Femur\_L
- Femur\_R
- Adnexa\_R
- Adnexa\_L
- Bladder



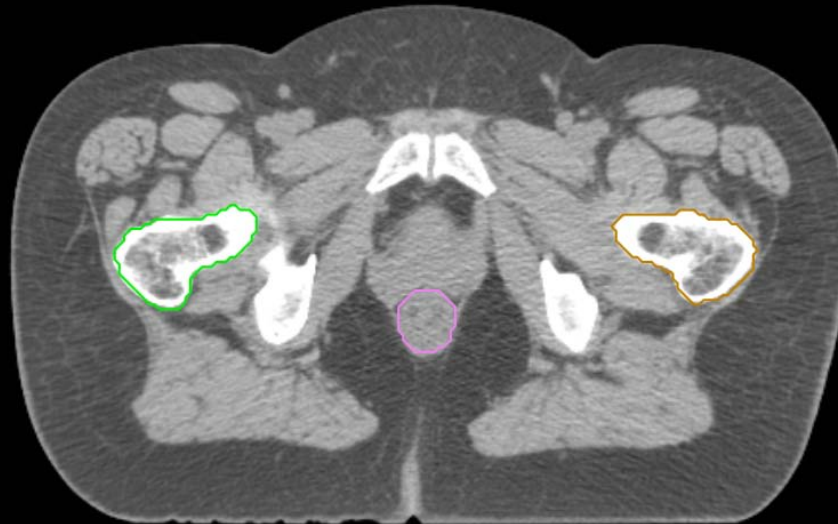
GI:

- Small Bowel
- AnoRectumSig
- Colon



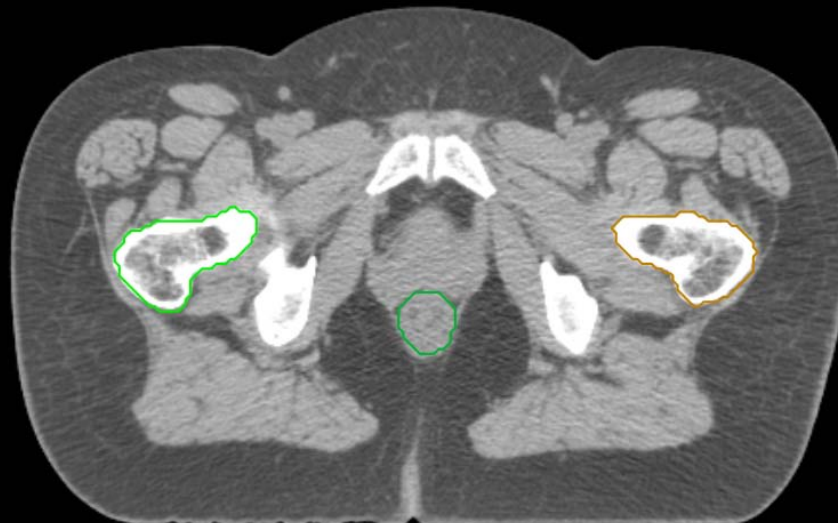GYN:

- Sigmoid
- AnoRectum
- BowelBag



GYN/GI:

- UteroCervix
- Femur\_L
- Femur\_R
- Adnexa\_R
- Adnexa\_L
- Bladder



GI:

- Small Bowel
- AnoRectumSig
- Colon

GYN:

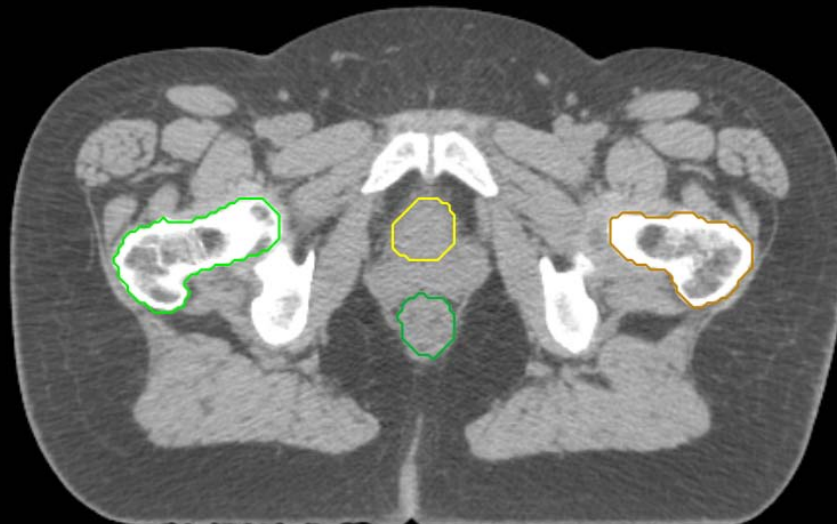
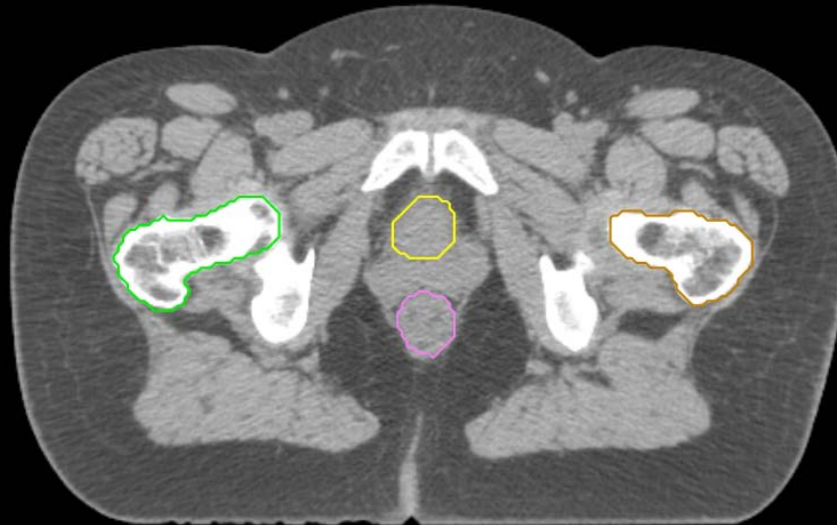
- Sigmoid
- AnoRectum
- BowelBag

GYN/GI:

- UteroCervix
- Femur\_L
- Femur\_R
- Adnexa\_R
- Adnexa\_L
- Bladder

GI:

- Small Bowel
- AnoRectumSig
- Colon



GYN:

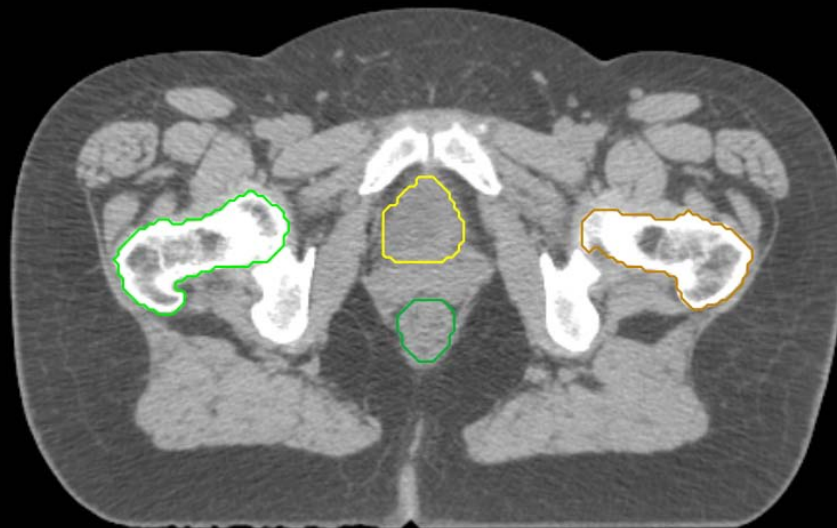
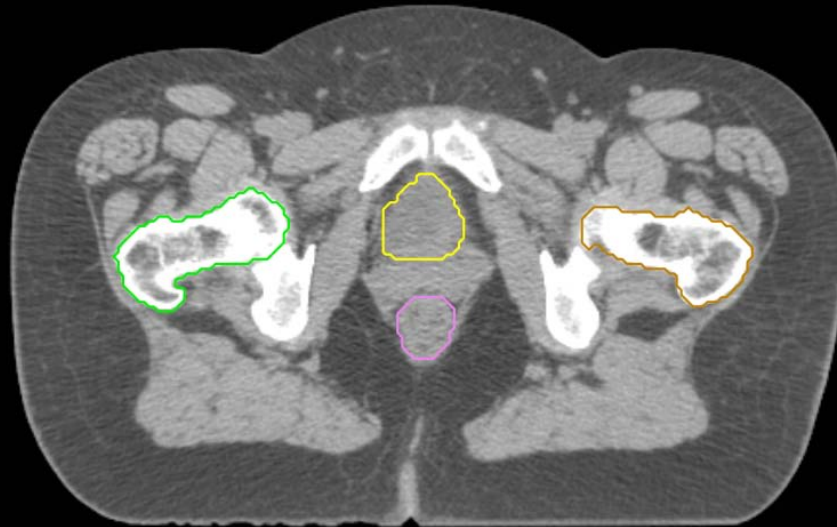- Sigmoid
- AnoRectum
- BowelBag

GYN/GI:

- UteroCervix
- Femur\_L
- Femur\_R
- Adnexa\_R
- Adnexa\_L
- Bladder

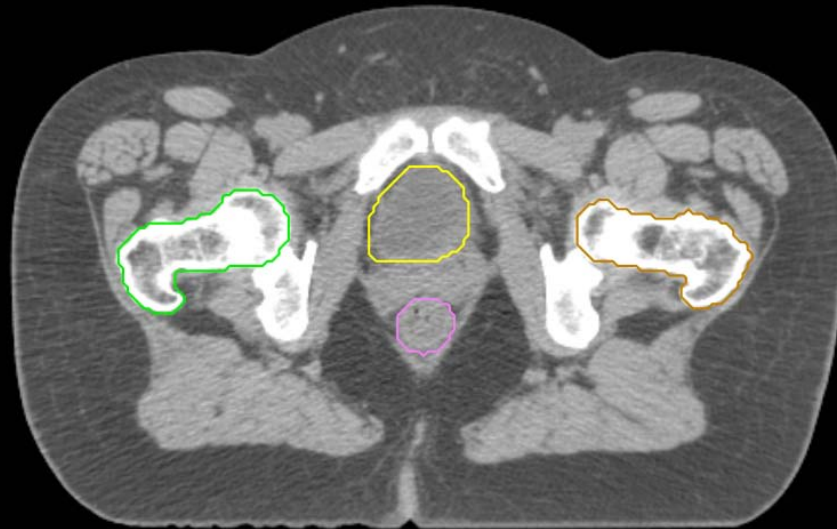GI:

- Small Bowel
- AnoRectumSig
- Colon



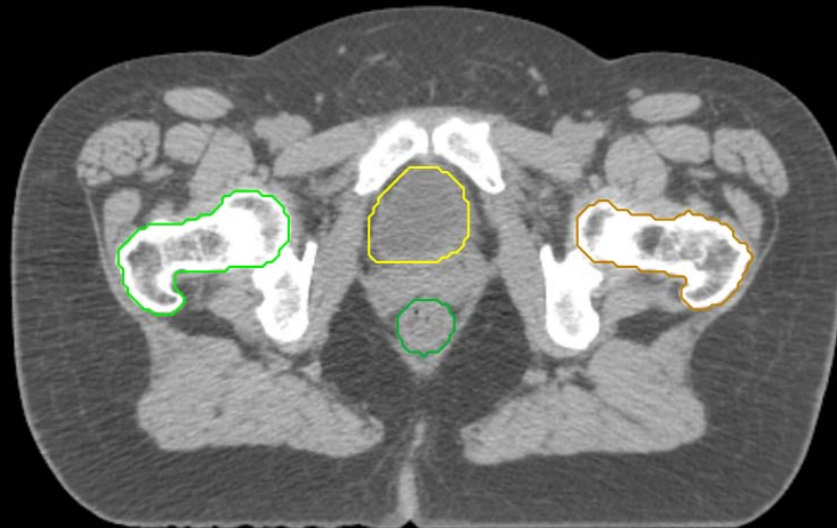
GYN:

- Sigmoid
- AnoRectum
- BowelBag



GYN/GI:

- UteroCervix
- Femur\_L
- Femur\_R
- Adnexa\_R
- Adnexa\_L
- Bladder



GI:

- Small Bowel
- AnoRectumSig
- Colon

GYN:

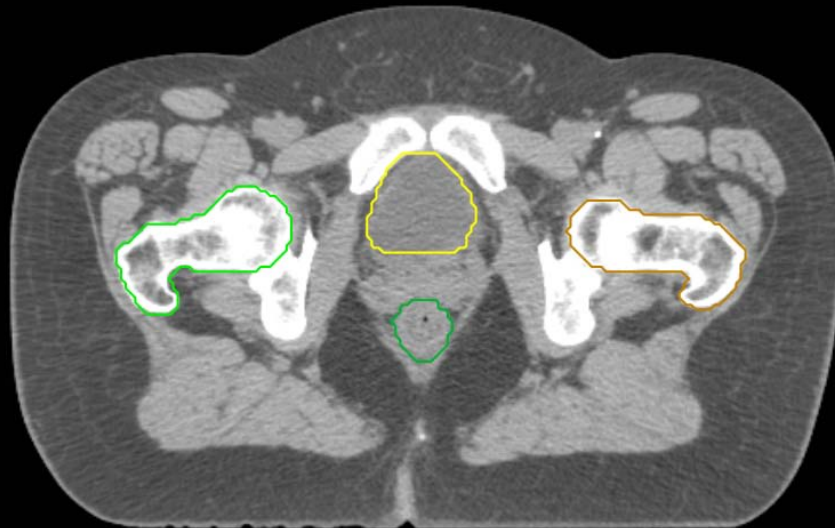
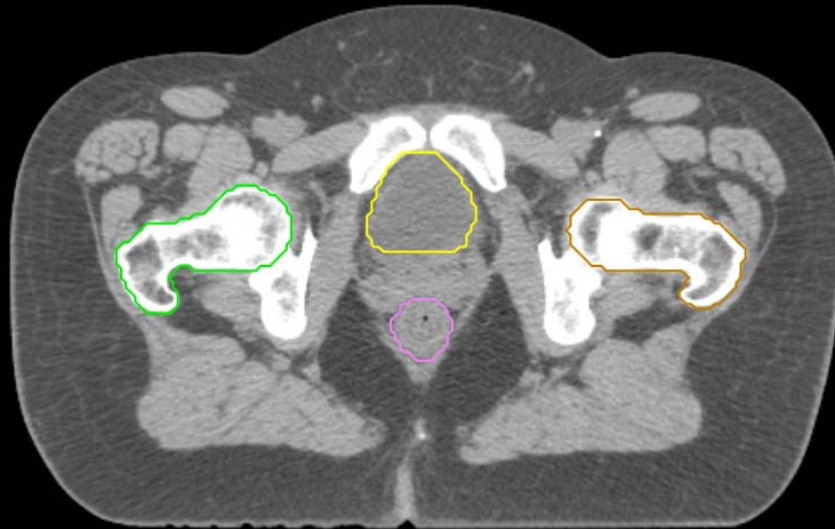
- Sigmoid
- AnoRectum
- BowelBag

GYN/GI:

- UteroCervix
- Femur\_L
- Femur\_R
- Adnexa\_R
- Adnexa\_L
- Bladder

GI:

- Small Bowel
- AnoRectumSig
- Colon



GYN:

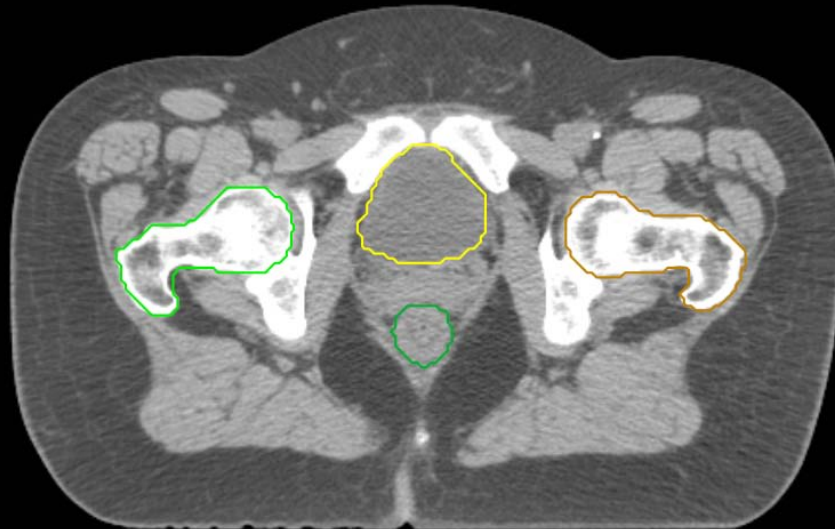
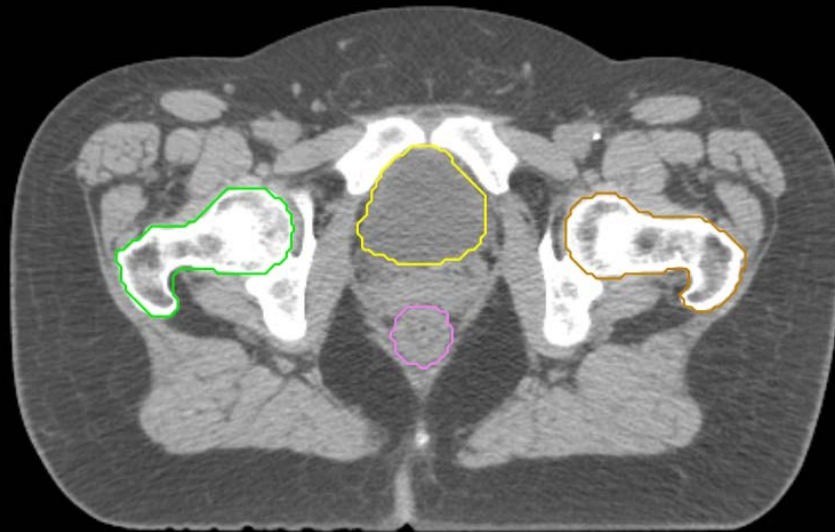
- Sigmoid
- AnoRectum
- BowelBag

GYN/GI:

- UteroCervix
- Femur\_L
- Femur\_R
- Adnexa\_R
- Adnexa\_L
- Bladder

GI:

- Small Bowel
- AnoRectumSig
- Colon



GYN:

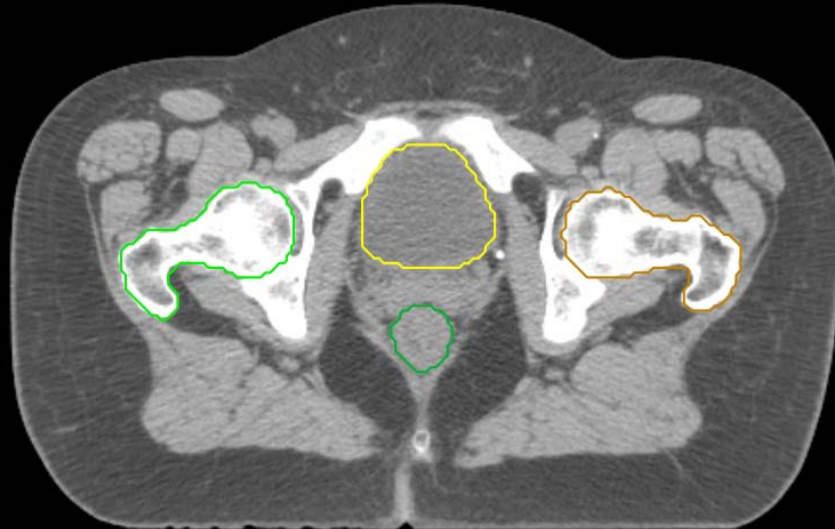
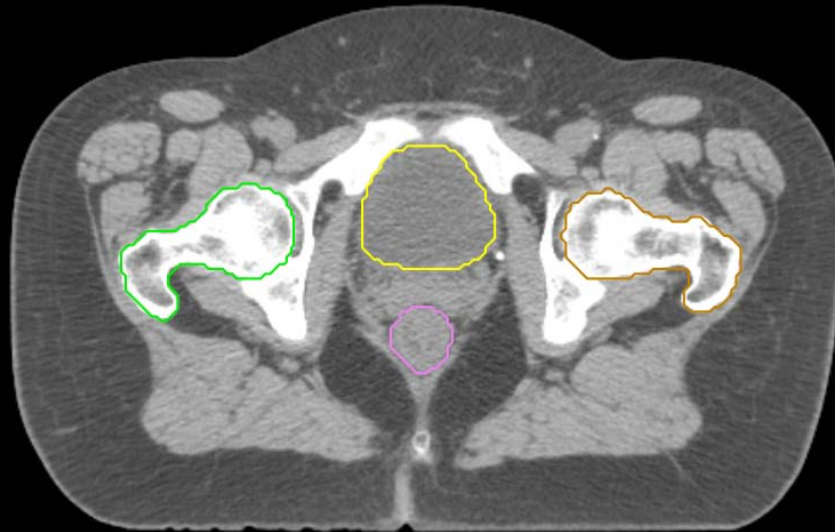
- Sigmoid
- AnoRectum
- BowelBag

GYN/GI:

- UteroCervix
- Femur\_L
- Femur\_R
- Adnexa\_R
- Adnexa\_L
- Bladder

GI:

- Small Bowel
- AnoRectumSig
- Colon



GYN:

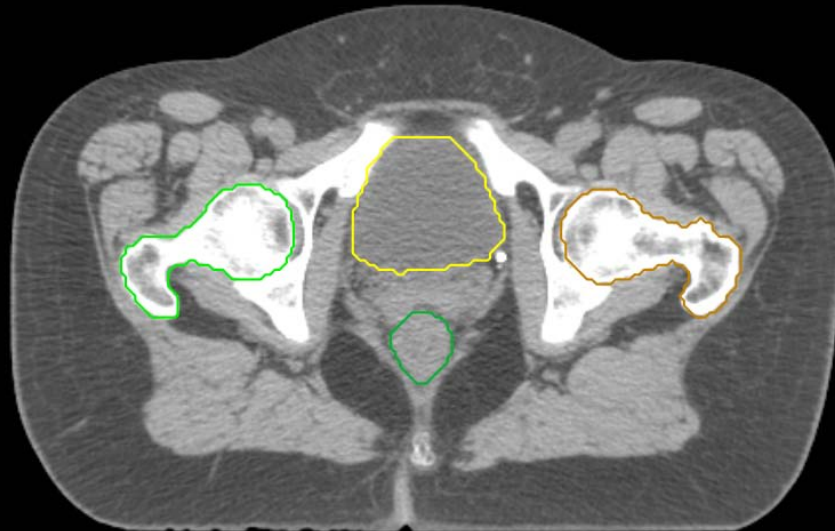
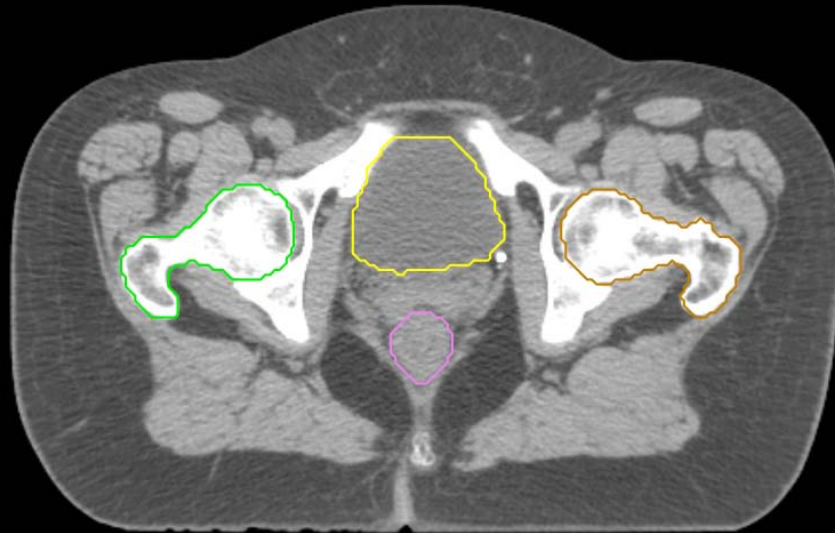
- Sigmoid
- AnoRectum
- BowelBag

GYN/GI:

- UteroCervix
- Femur\_L
- Femur\_R
- Adnexa\_R
- Adnexa\_L
- Bladder

GI:

- Small Bowel
- AnoRectumSig
- Colon





GYN:

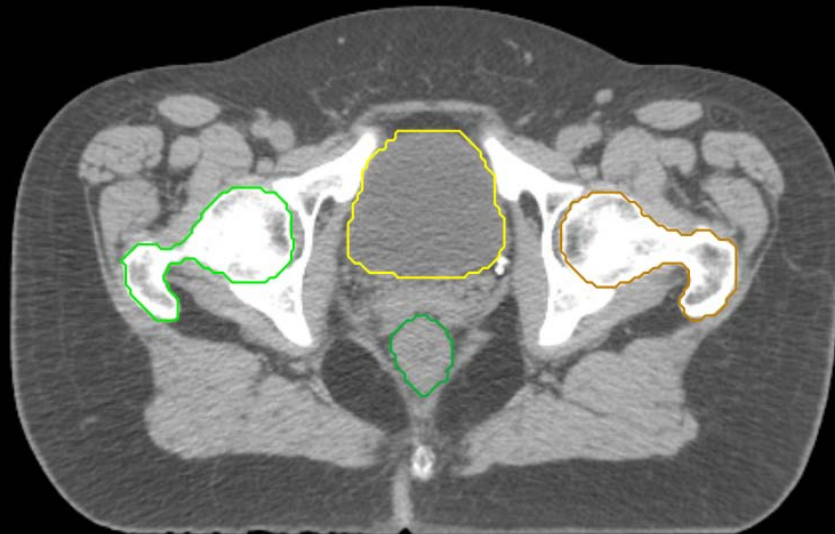
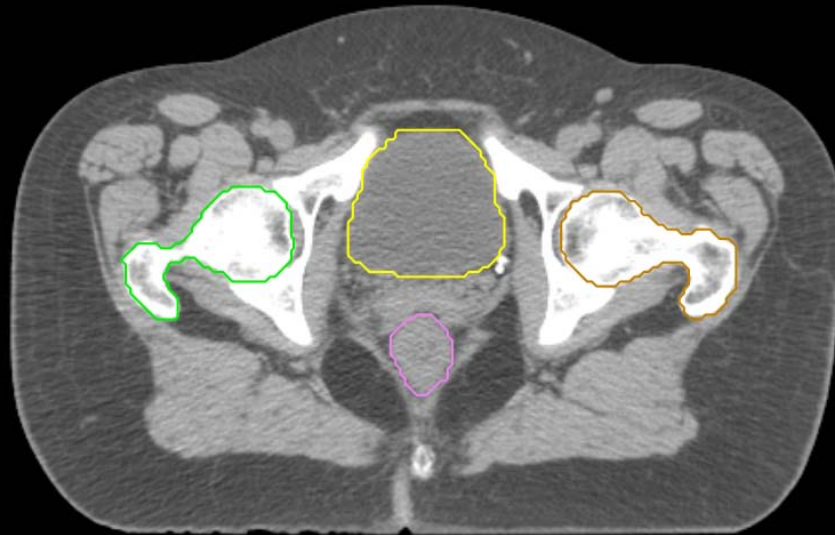
- Sigmoid
- AnoRectum
- BowelBag

GYN/GI:

- UteroCervix
- Femur\_L
- Femur\_R
- Adnexa\_R
- Adnexa\_L
- Bladder

GI:

- Small Bowel
- AnoRectumSig
- Colon



GYN:

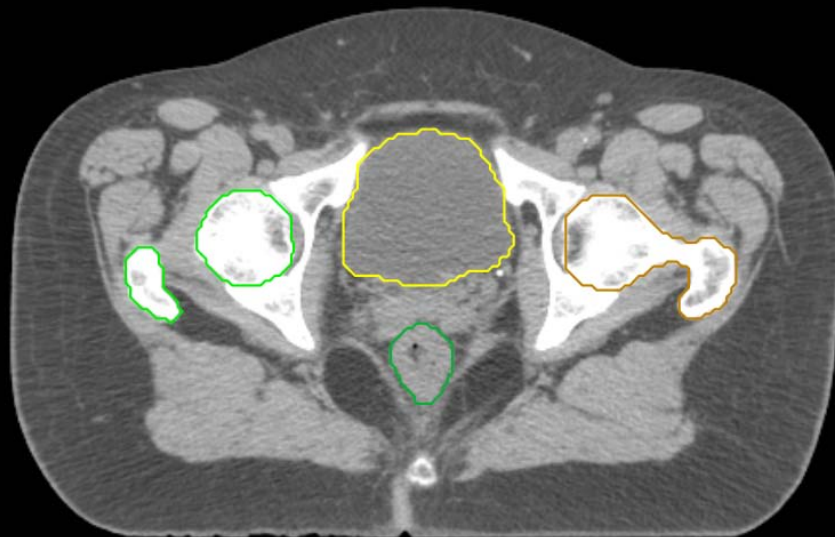
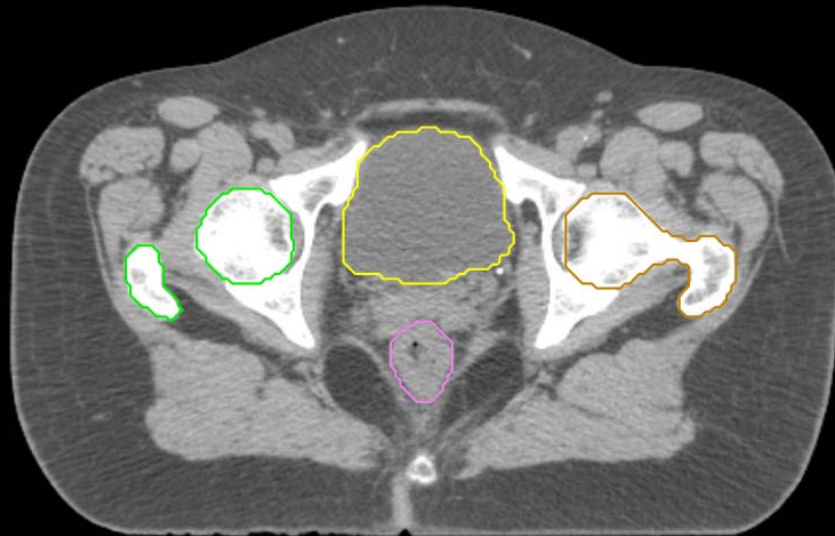
- Sigmoid
- AnoRectum
- BowelBag

GYN/GI:

- UteroCervix
- Femur\_L
- Femur\_R
- Adnexa\_R
- Adnexa\_L
- Bladder

GI:

- Small Bowel
- AnoRectumSig
- Colon



GYN:

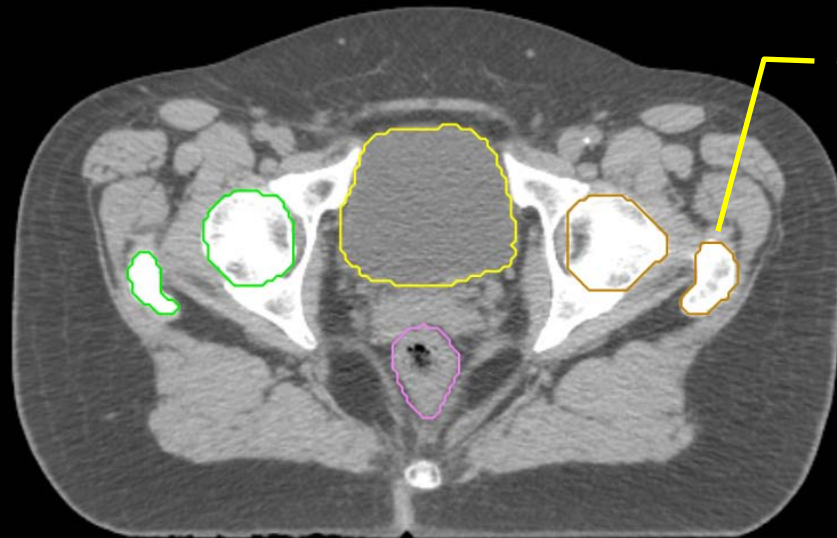
- Sigmoid
- AnoRectum
- BowelBag

GYN/GI:

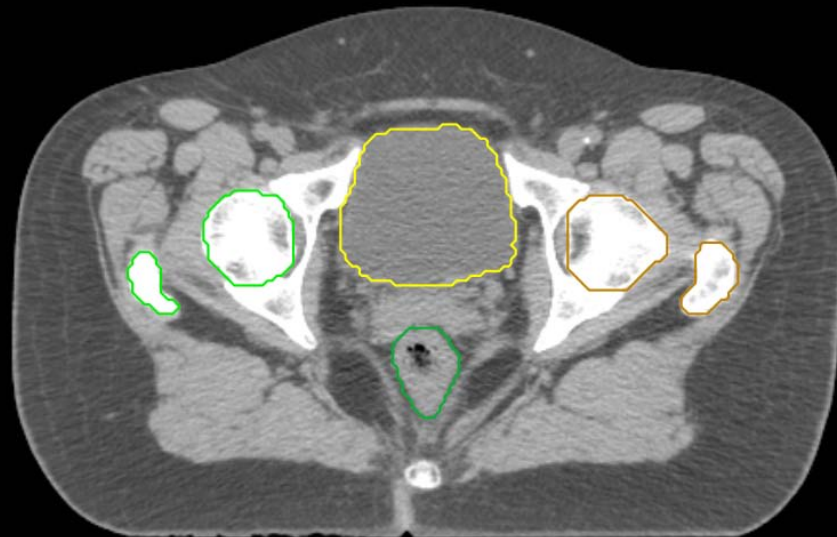
- UteroCervix
- Femur\_L
- Femur\_R
- Adnexa\_R
- Adnexa\_L
- Bladder

GI:

- Small Bowel
- AnoRectumSig
- Colon



this is also part of Femur\_L



GYN:

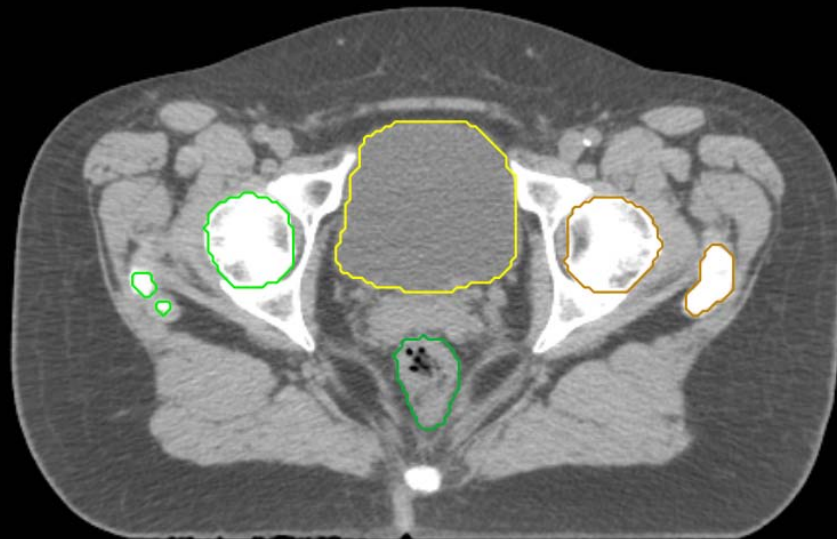
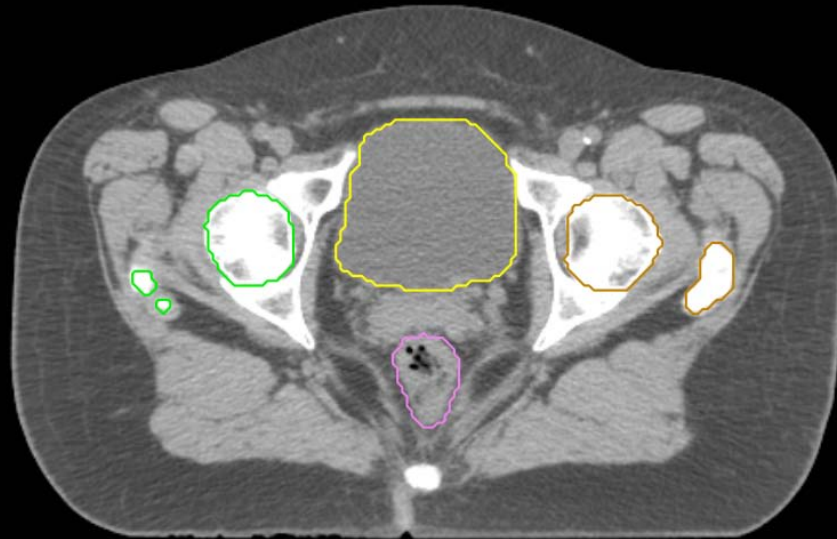
- Sigmoid
- AnoRectum
- BowelBag

GYN/GI:

- UteroCervix
- Femur\_L
- Femur\_R
- Adnexa\_R
- Adnexa\_L
- Bladder

GI:

- Small Bowel
- AnoRectumSig
- Colon



GYN:

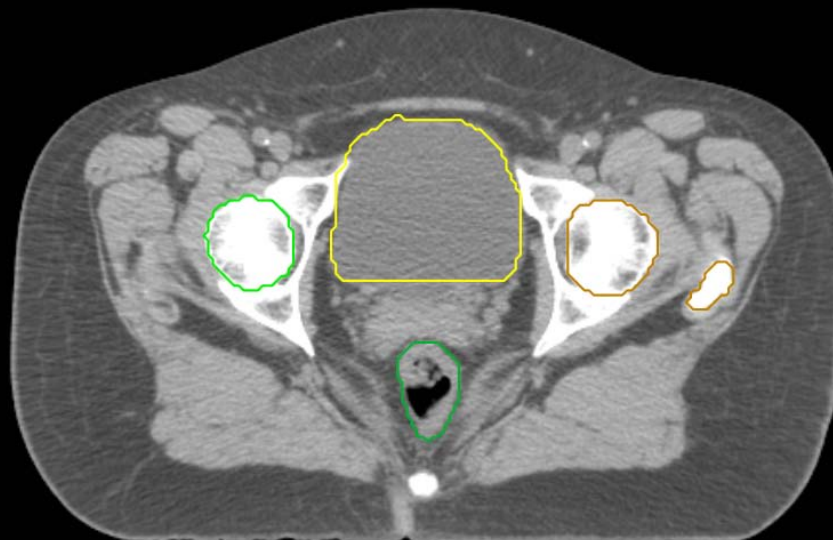
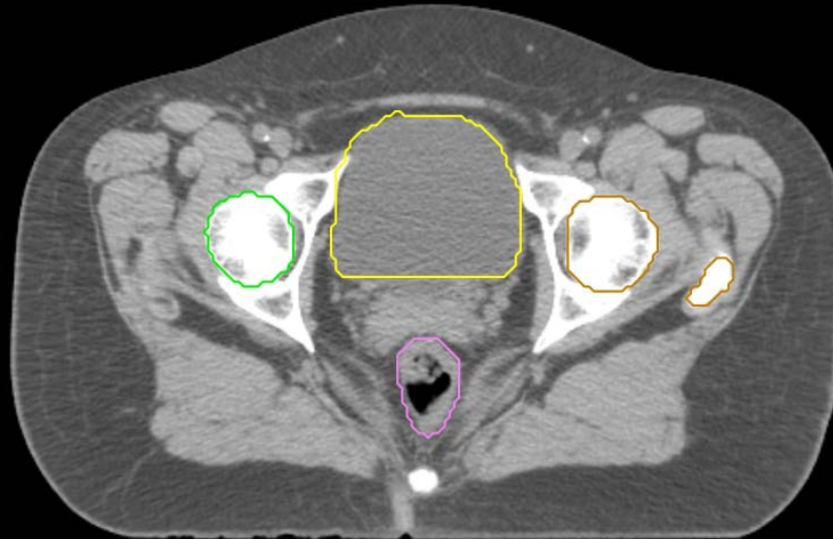
- Sigmoid
- AnoRectum
- BowelBag

GYN/GI:

- UteroCervix
- Femur\_L
- Femur\_R
- Adnexa\_R
- Adnexa\_L
- Bladder

GI:

- Small Bowel
- AnoRectumSig
- Colon



GYN:

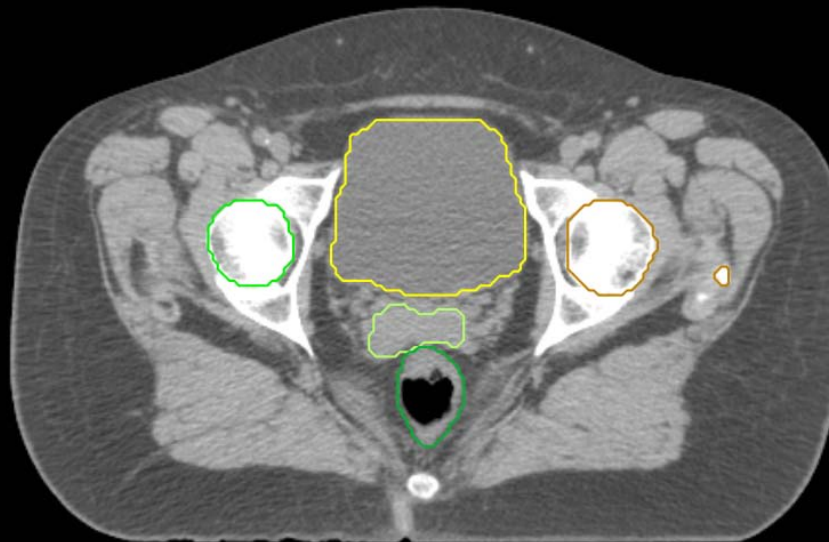
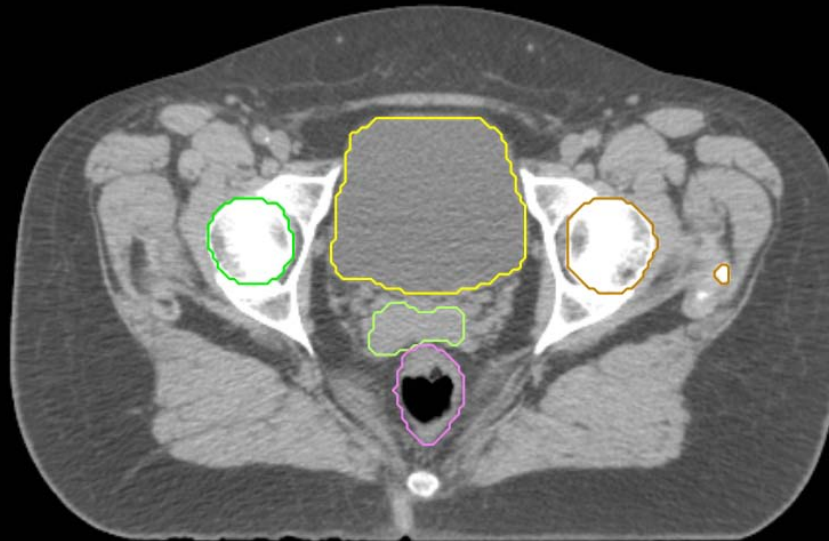
- Sigmoid
- AnoRectum
- BowelBag

GYN/GI:

- UteroCervix
- Femur\_L
- Femur\_R
- Adnexa\_R
- Adnexa\_L
- Bladder

GI:

- Small Bowel
- AnoRectumSig
- Colon



GYN:

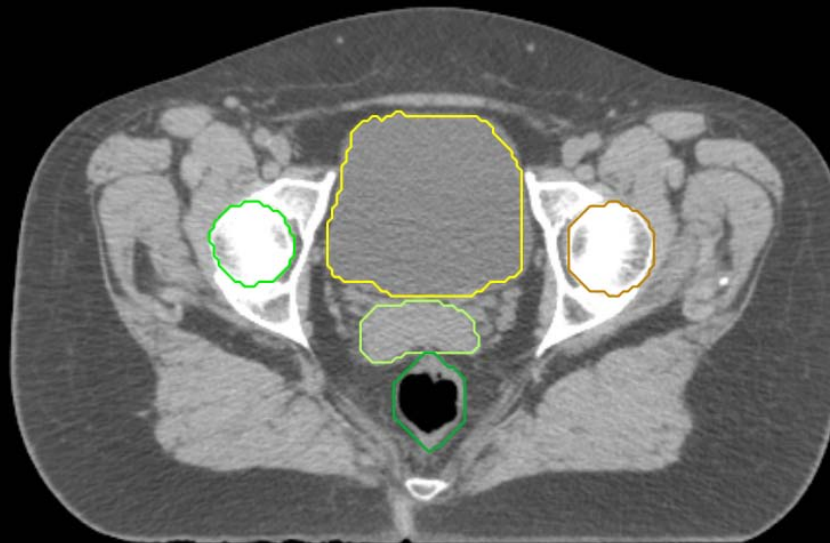
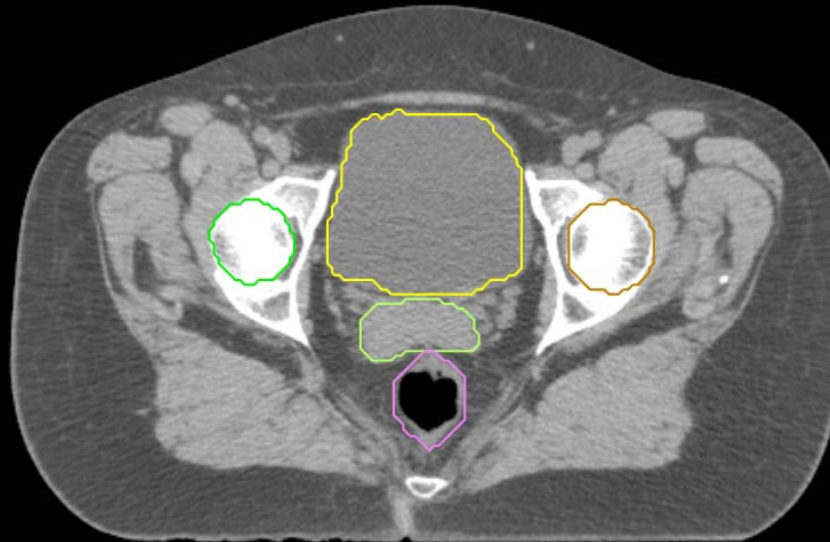
- Sigmoid
- AnoRectum
- BowelBag

GYN/GI:

- UteroCervix
- Femur\_L
- Femur\_R
- Adnexa\_R
- Adnexa\_L
- Bladder

GI:

- Small Bowel
- AnoRectumSig
- Colon



GYN:

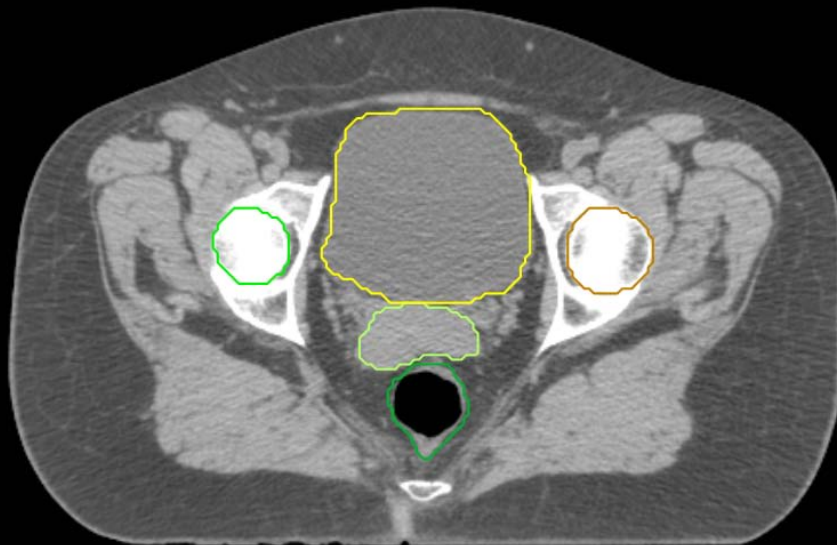
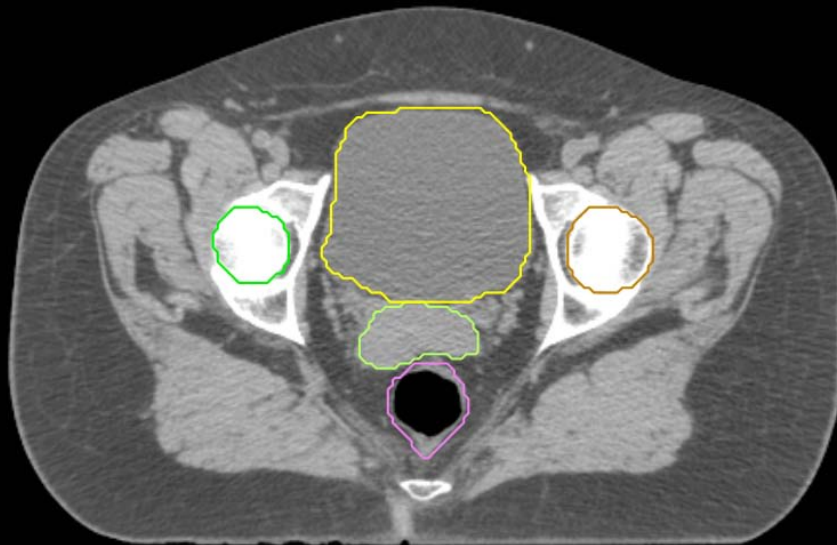
- Sigmoid
- AnoRectum
- BowelBag

GYN/GI:

- UteroCervix
- Femur\_L
- Femur\_R
- Adnexa\_R
- Adnexa\_L
- Bladder

GI:

- Small Bowel
- AnoRectumSig
- Colon





GYN:

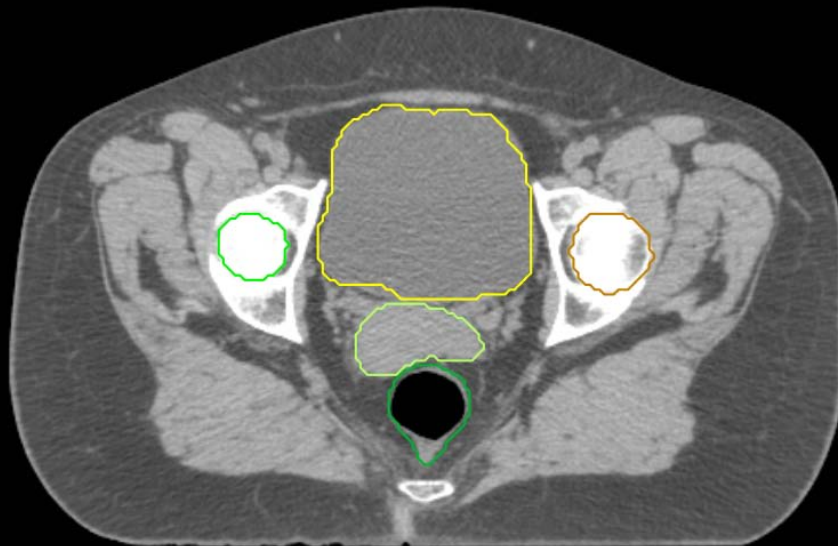
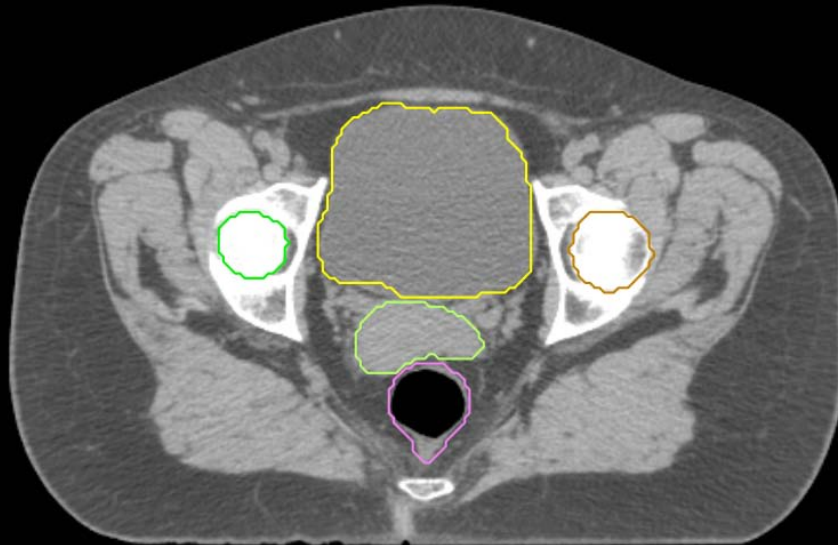
- Sigmoid
- AnoRectum
- BowelBag

GYN/GI:

- UteroCervix
- Femur\_L
- Femur\_R
- Adnexa\_R
- Adnexa\_L
- Bladder

GI:

- Small Bowel
- AnoRectumSig
- Colon



GYN:

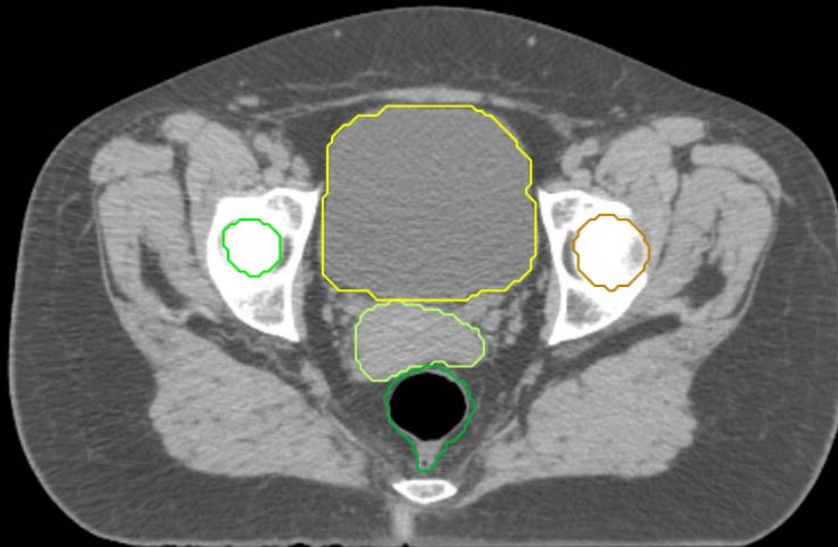
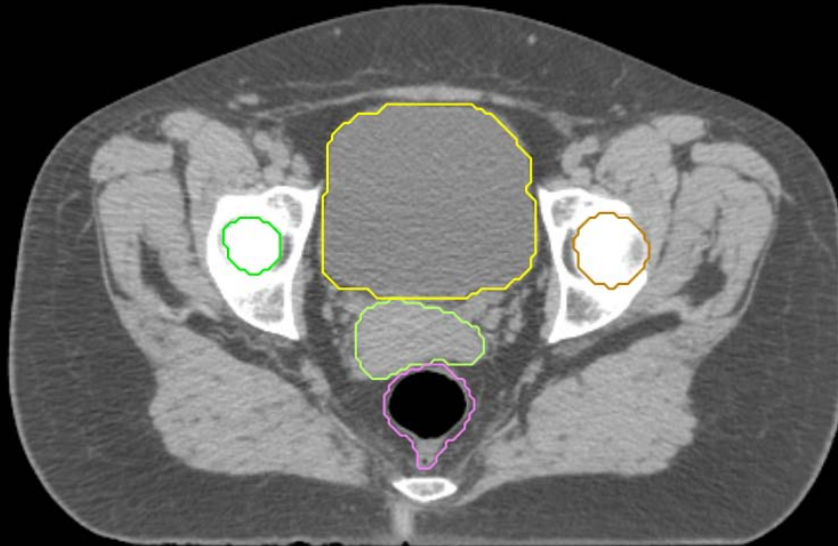
- Sigmoid
- AnoRectum
- BowelBag

GYN/GI:

- UteroCervix
- Femur\_L
- Femur\_R
- Adnexa\_R
- Adnexa\_L
- Bladder

GI:

- Small Bowel
- AnoRectumSig
- Colon



GYN:

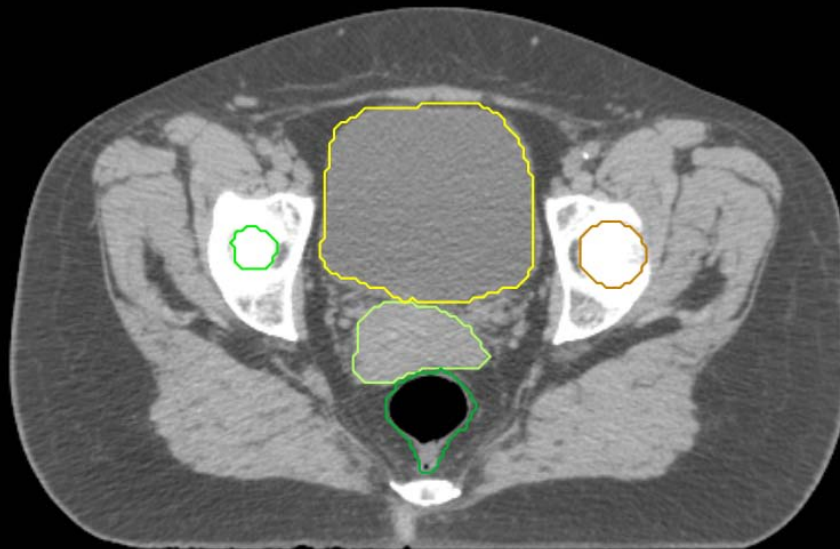
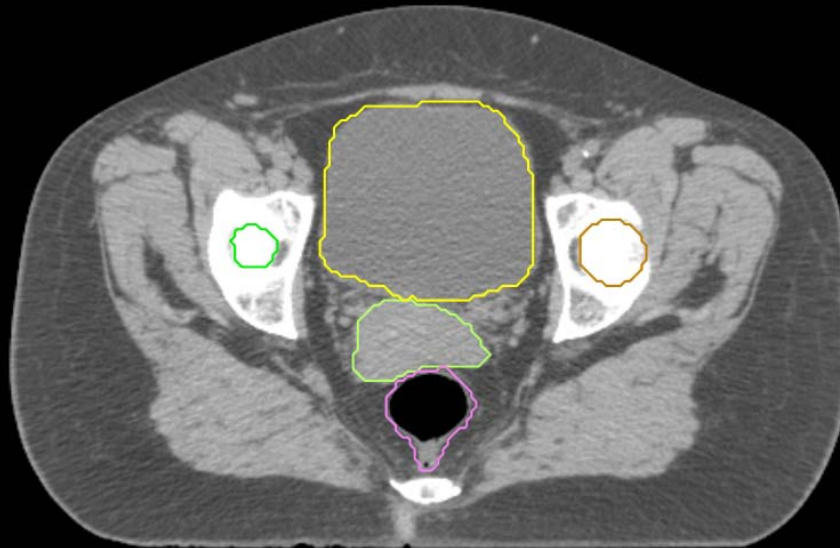
- Sigmoid
- AnoRectum
- BowelBag

GYN/GI:

- UteroCervix
- Femur\_L
- Femur\_R
- Adnexa\_R
- Adnexa\_L
- Bladder

GI:

- Small Bowel
- AnoRectumSig
- Colon



GYN:

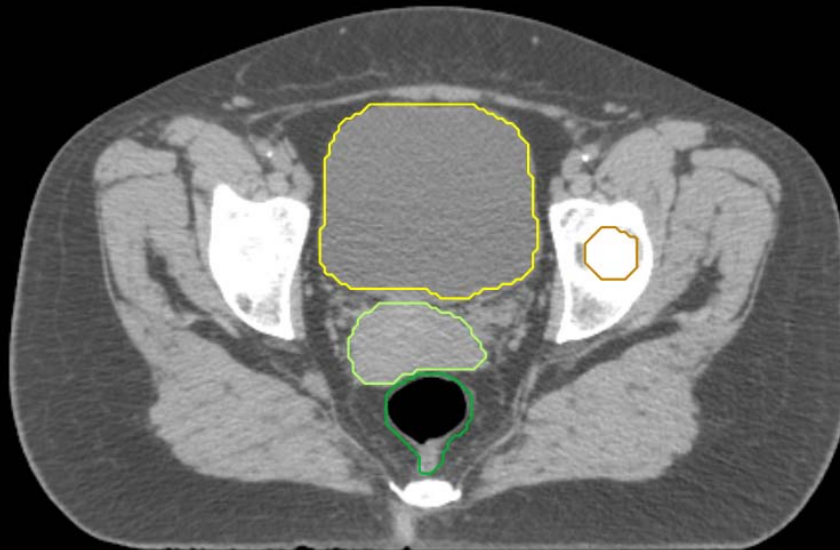
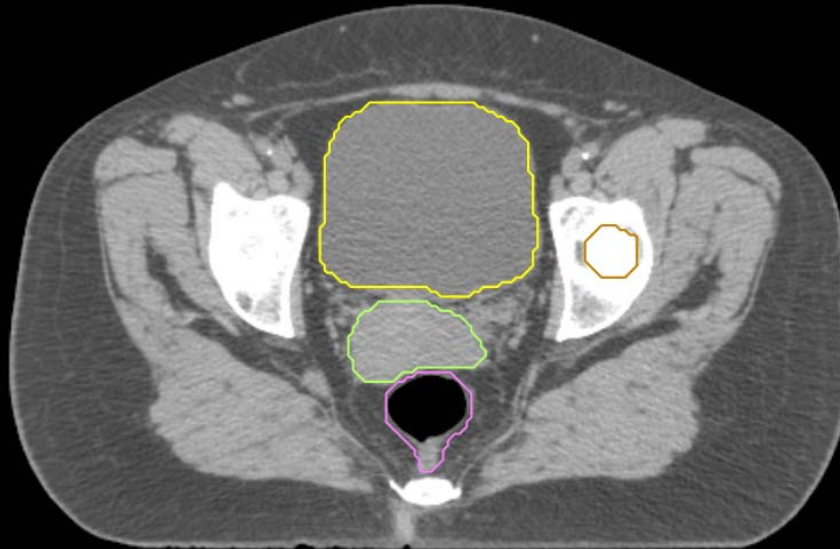
- Sigmoid
- AnoRectum
- BowelBag

GYN/GI:

- UteroCervix
- Femur\_L
- Femur\_R
- Adnexa\_R
- Adnexa\_L
- Bladder

GI:

- Small Bowel
- AnoRectumSig
- Colon



GYN:

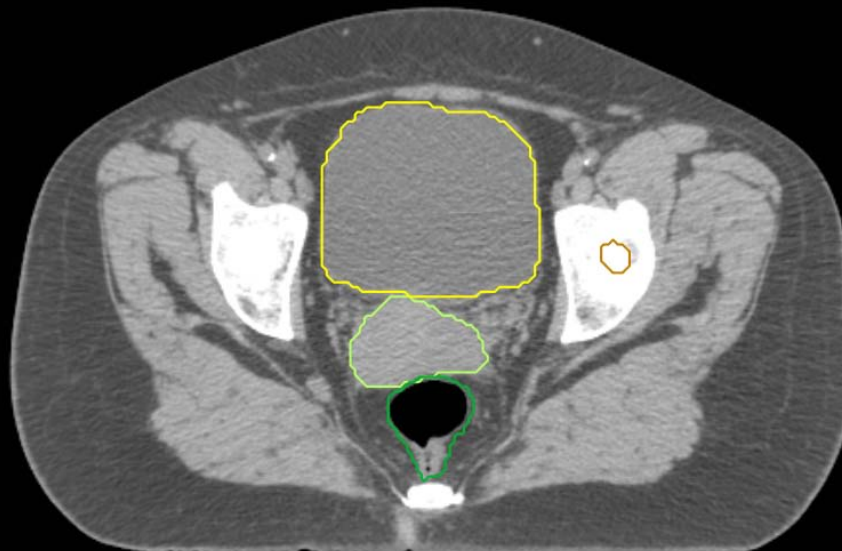
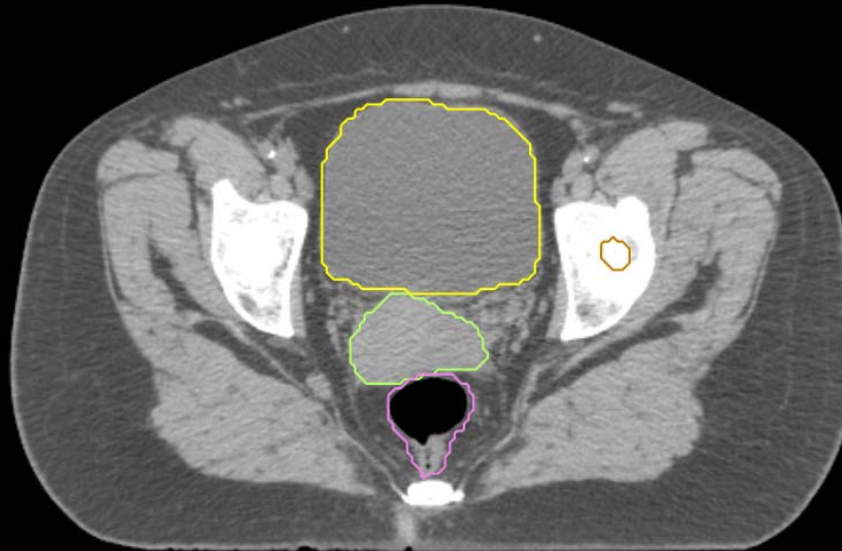
- Sigmoid
- AnoRectum
- BowelBag

GYN/GI:

- UteroCervix
- Femur\_L
- Femur\_R
- Adnexa\_R
- Adnexa\_L
- Bladder

GI:

- Small Bowel
- AnoRectumSig
- Colon



GYN:

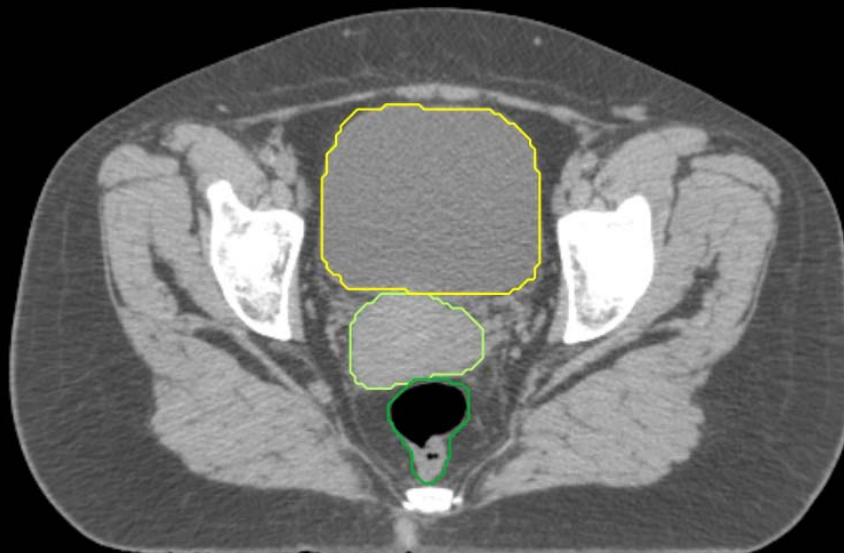
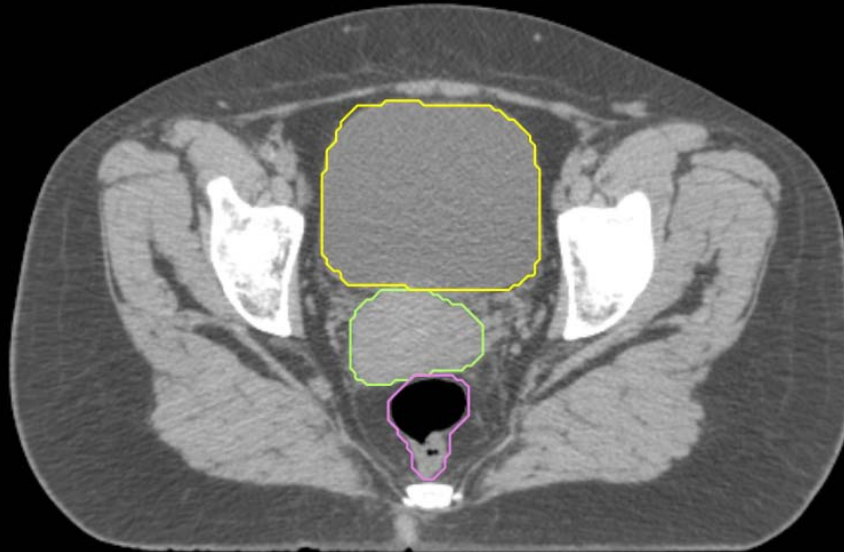
- Sigmoid
- AnoRectum
- BowelBag

GYN/GI:

- UteroCervix
- Femur\_L
- Femur\_R
- Adnexa\_R
- Adnexa\_L
- Bladder

GI:

- Small Bowel
- AnoRectumSig
- Colon



GYN:

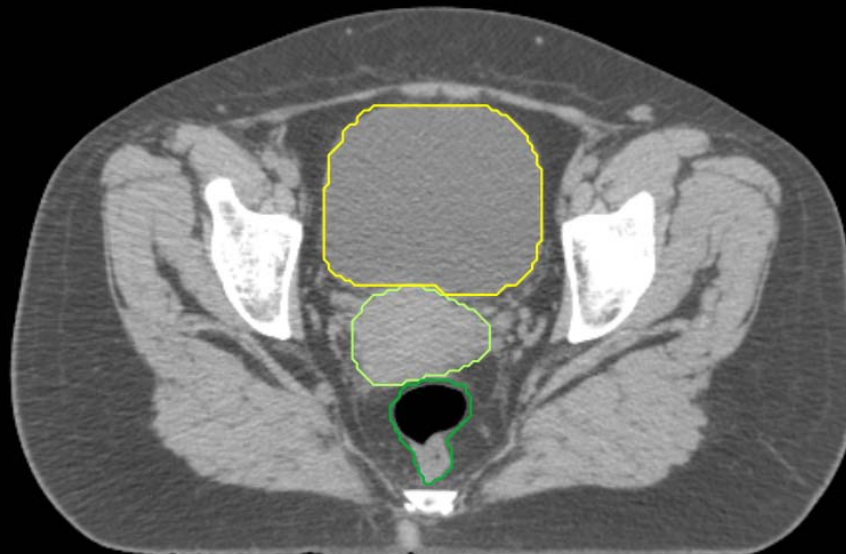
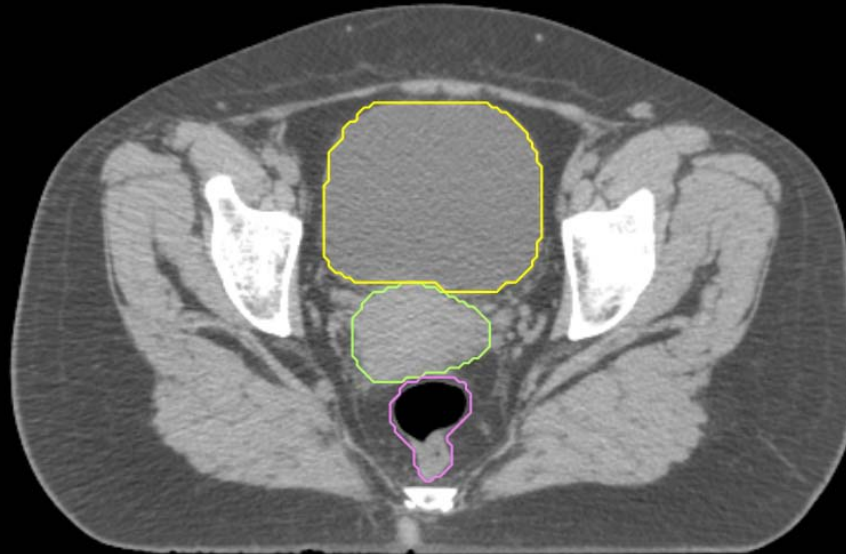
- Sigmoid
- AnoRectum
- BowelBag

GYN/GI:

- UteroCervix
- Femur\_L
- Femur\_R
- Adnexa\_R
- Adnexa\_L
- Bladder

GI:

- Small Bowel
- AnoRectumSig
- Colon



GYN:

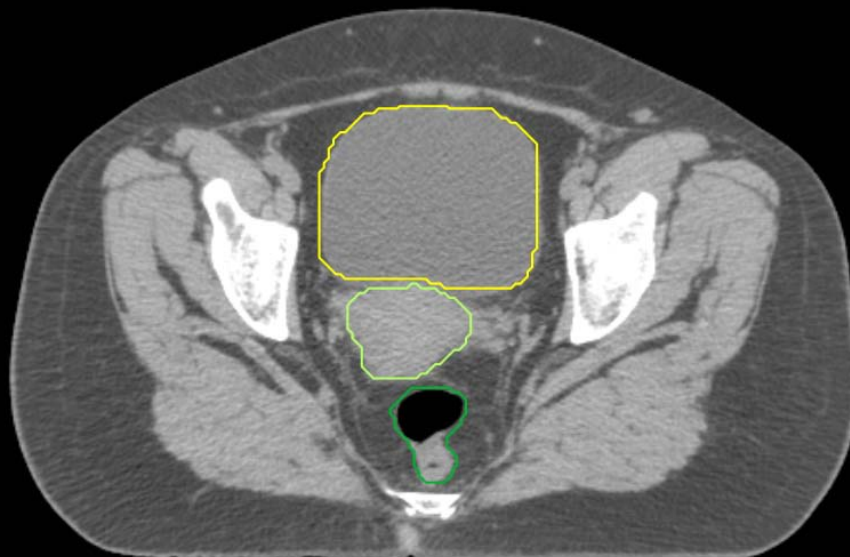
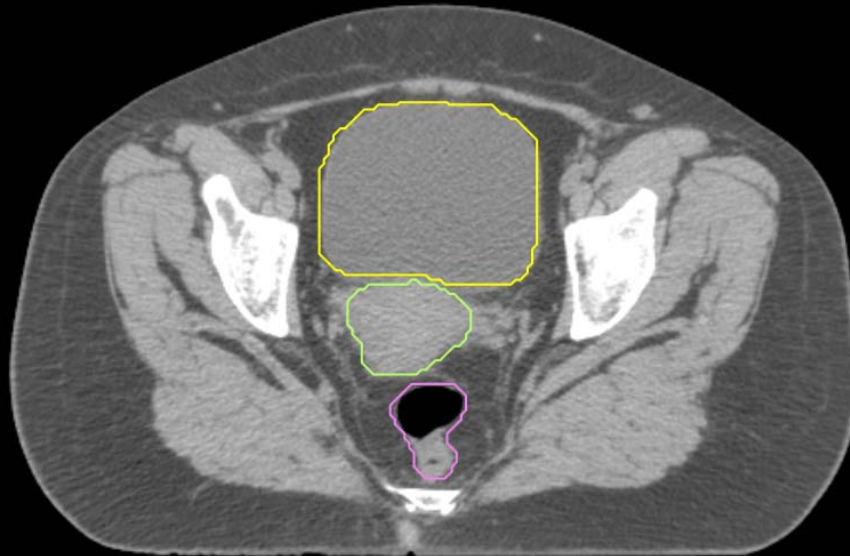
- Sigmoid
- AnoRectum
- BowelBag

GYN/GI:

- UteroCervix
- Femur\_L
- Femur\_R
- Adnexa\_R
- Adnexa\_L
- Bladder

GI:

- Small Bowel
- AnoRectumSig
- Colon





GYN:

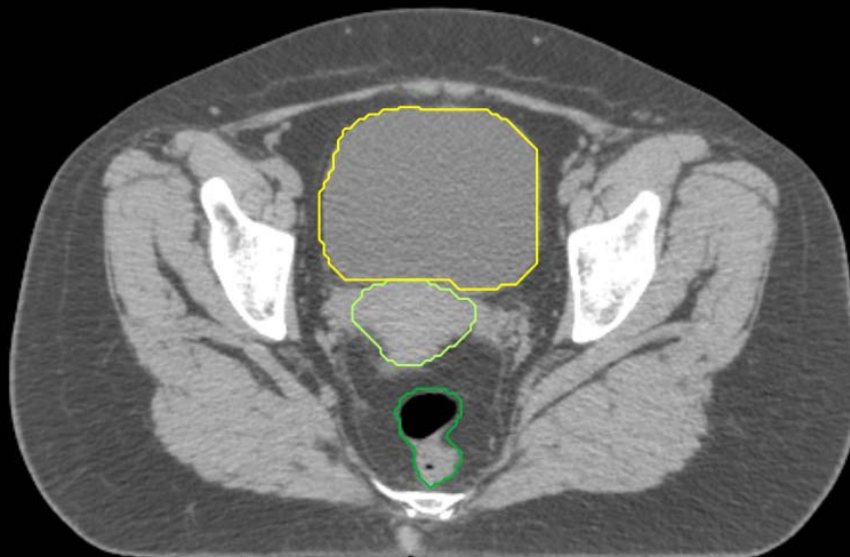
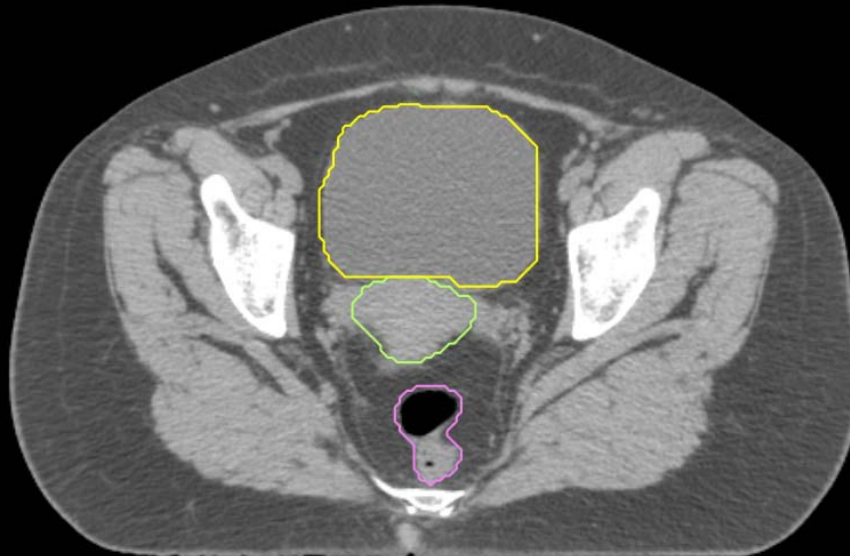
- Sigmoid
- AnoRectum
- BowelBag

GYN/GI:

- UteroCervix
- Femur\_L
- Femur\_R
- Adnexa\_R
- Adnexa\_L
- Bladder

GI:

- Small Bowel
- AnoRectumSig
- Colon



GYN:

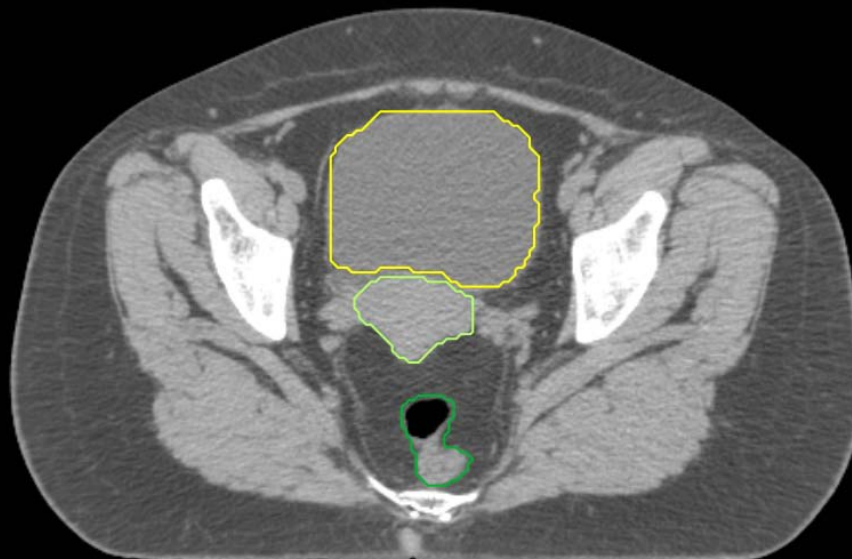
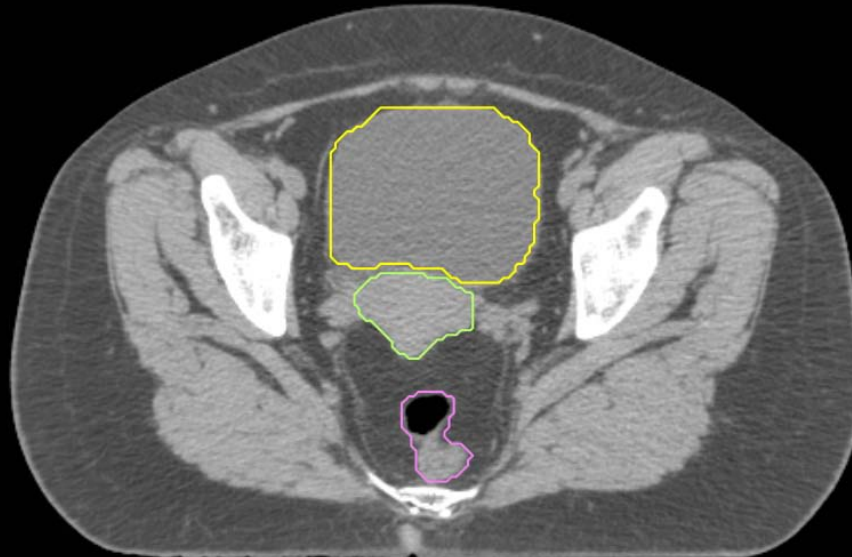
- Sigmoid
- AnoRectum
- BowelBag

GYN/GI:

- UteroCervix
- Femur\_L
- Femur\_R
- Adnexa\_R
- Adnexa\_L
- Bladder

GI:

- Small Bowel
- AnoRectumSig
- Colon



GYN:

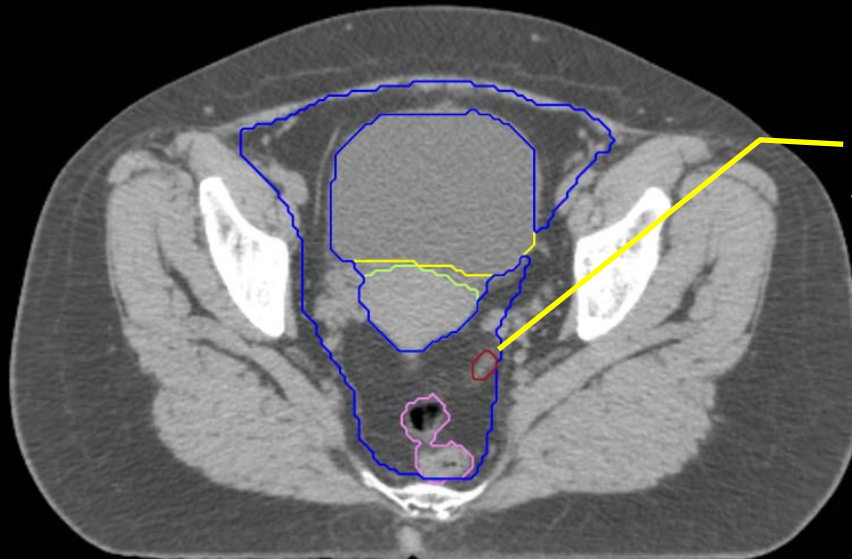
- Sigmoid
- AnoRectum
- BowelBag

GYN/GI:

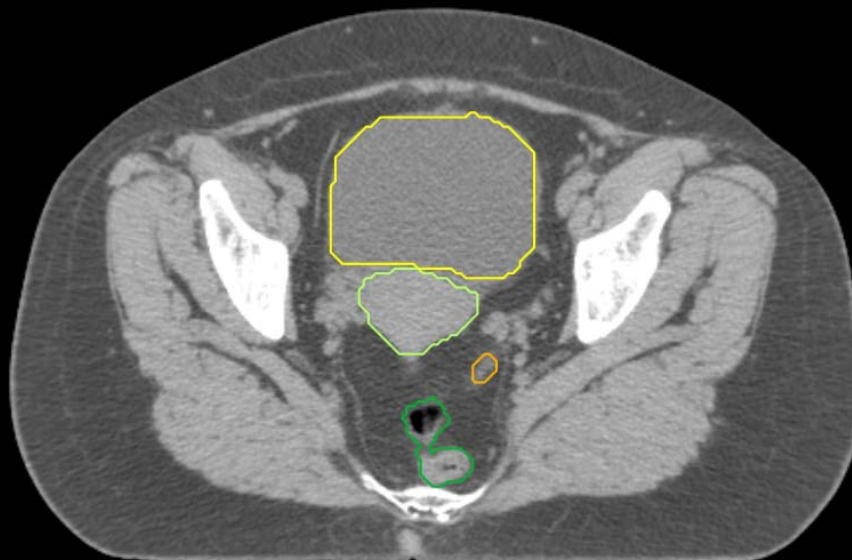- UteroCervix
- Femur\_L
- Femur\_R
- Adnexa\_R
- Adnexa\_L
- Bladder

GI:

- Small Bowel
- AnoRectumSig
- Colon



BowelBag starts Inferiorly from the most inferior small or large bowel loop, or above the Rectum (GU) or AnoRectum (GYN), whichever is most inferior. In this case the large bowel (see Colon below) is most inferior.



GYN:

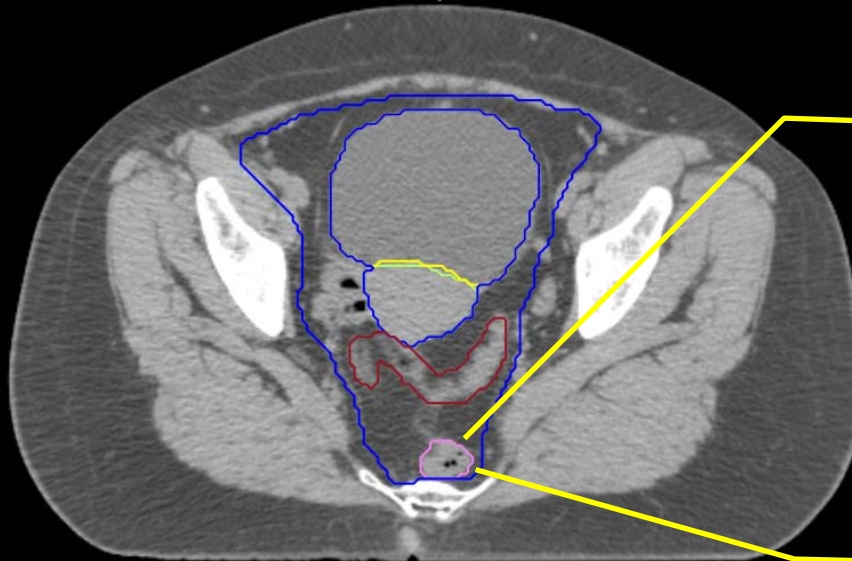
- Sigmoid
- AnoRectum
- BowelBag

GYN/GI:

- UteroCervix
- Femur\_L
- Femur\_R
- Adnexa\_R
- Adnexa\_L
- Bladder

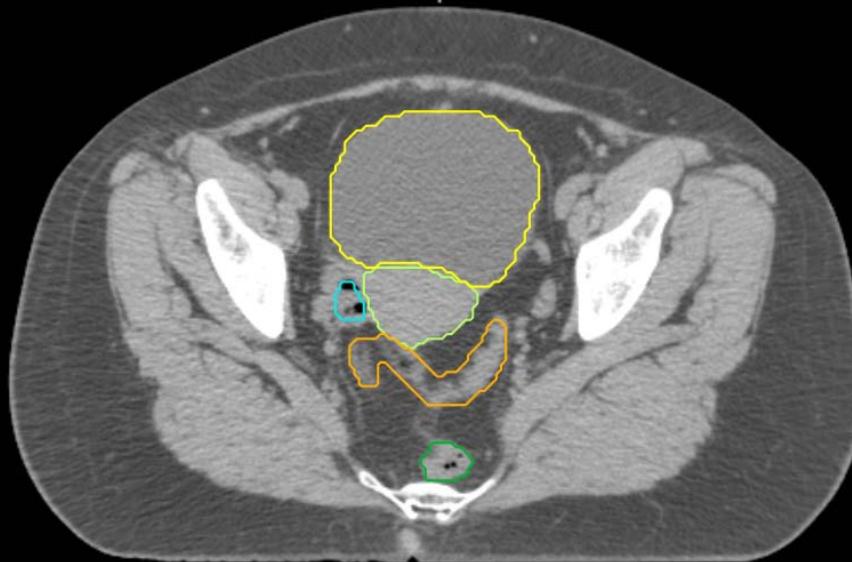
GI:

- Small Bowel
- AnoRectumSig
- Colon



If the AnoRectum (GYN) or Rectum (GU) is present in a BowelBag axial slice, it should be included as part of the bag; otherwise it should be excluded.

AnoRectum stops here since this is the last cut it has a round shape



GYN:

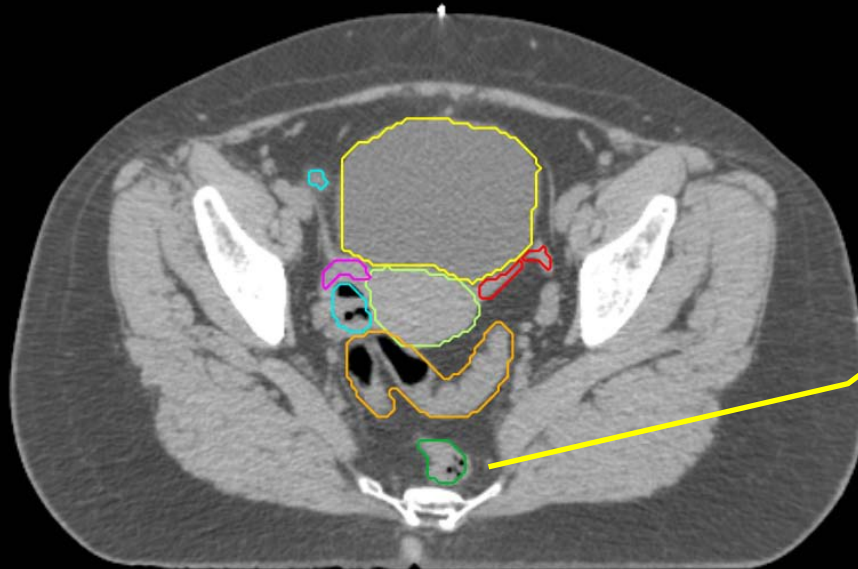
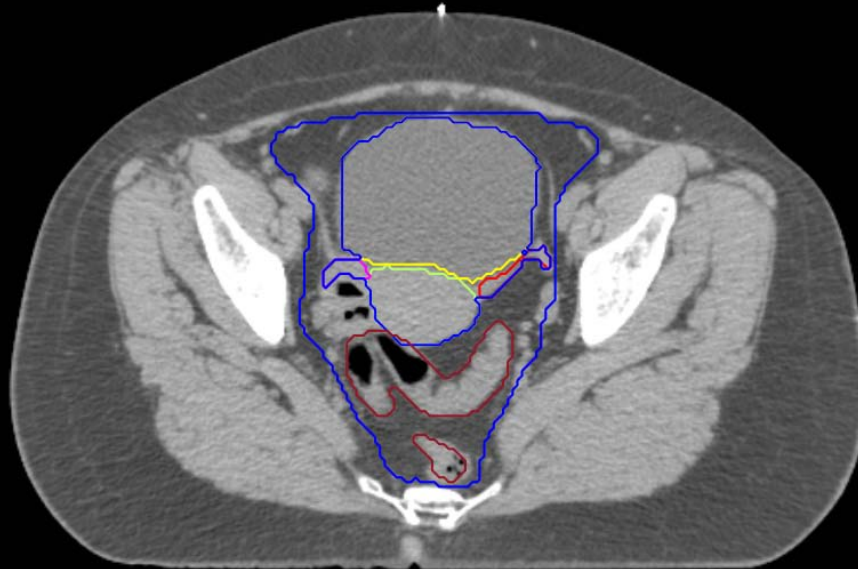- Sigmoid
- AnoRectum
- BowelBag

GYN/GI:

- UteroCervix
- Femur\_L
- Femur\_R
- Adnexa\_R
- Adnexa\_L
- Bladder

GI:

- Small Bowel
- AnoRectumSig
- Colon



GYN:

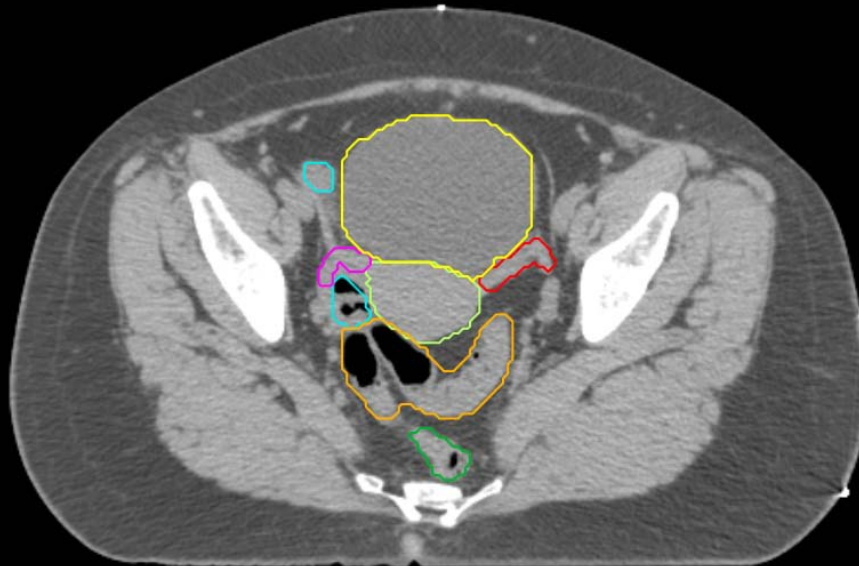
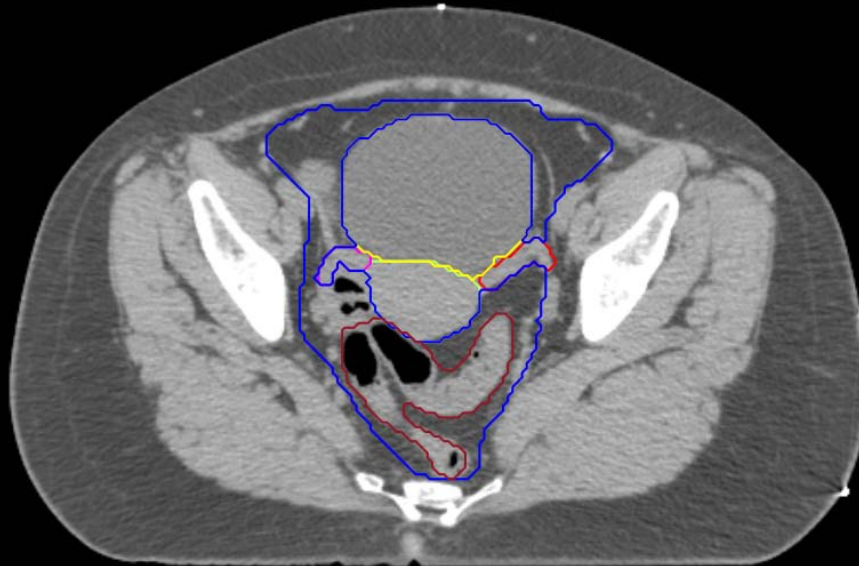
- Sigmoid
- AnoRectum
- BowelBag

GYN/GI:

- UteroCervix
- Femur\_L
- Femur\_R
- Adnexa\_R
- Adnexa\_L
- Bladder

GI:

- Small Bowel
- AnoRectumSig
- Colon



GYN:

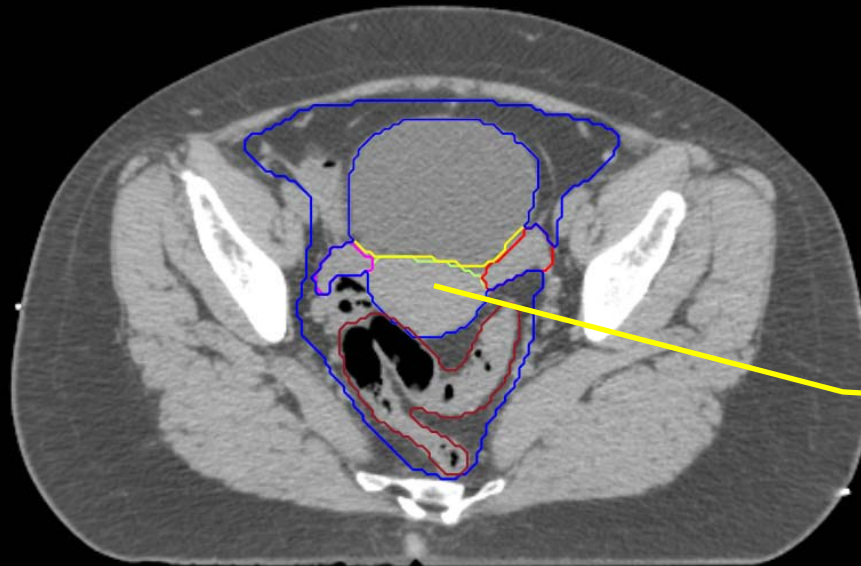
- Sigmoid
- AnoRectum
- BowelBag

GYN/GI:

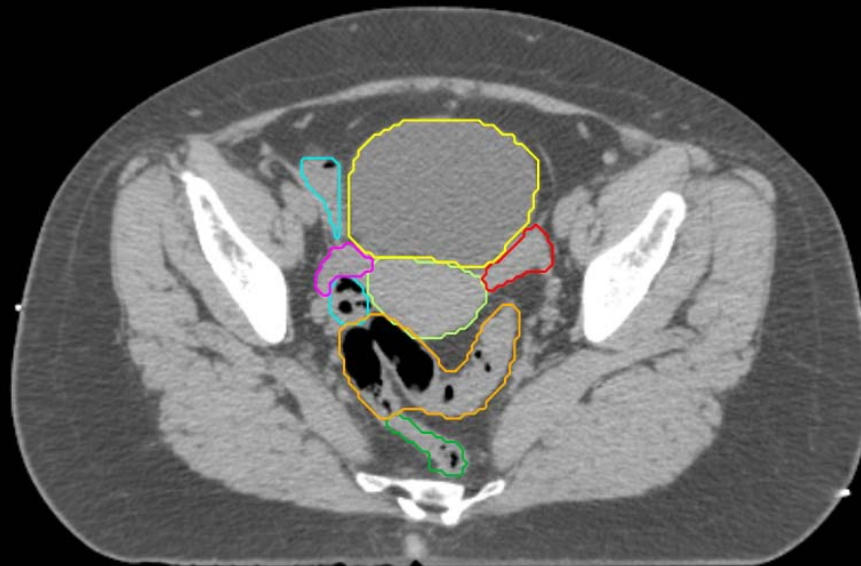
- UteroCervix
- Femur\_L
- Femur\_R
- Adnexa\_R
- Adnexa\_L
- Bladder

GI:

- Small Bowel
- AnoRectumSig
- Colon



UteroCervix, Bladder, Adnexa\_R, and Adnexa\_L excluded from BowelBag



GYN:

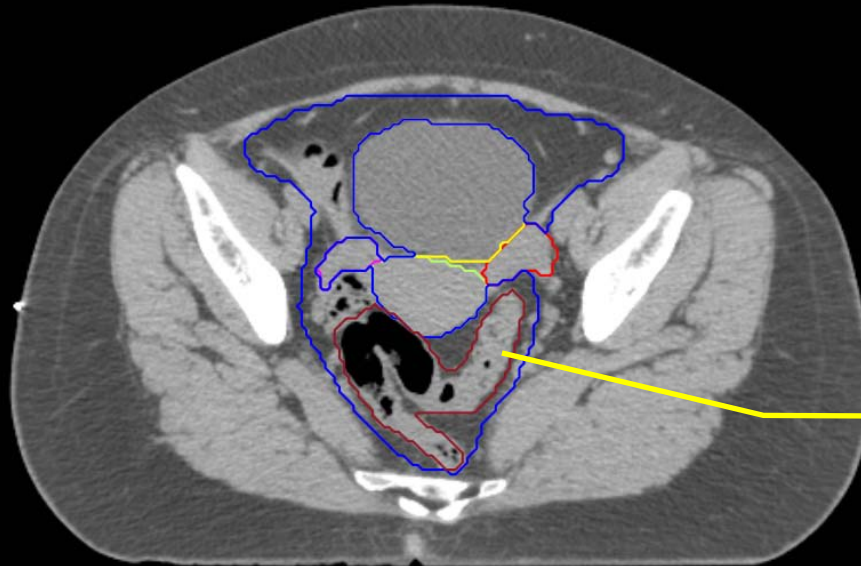
- Sigmoid
- AnoRectum
- BowelBag

GYN/GI:

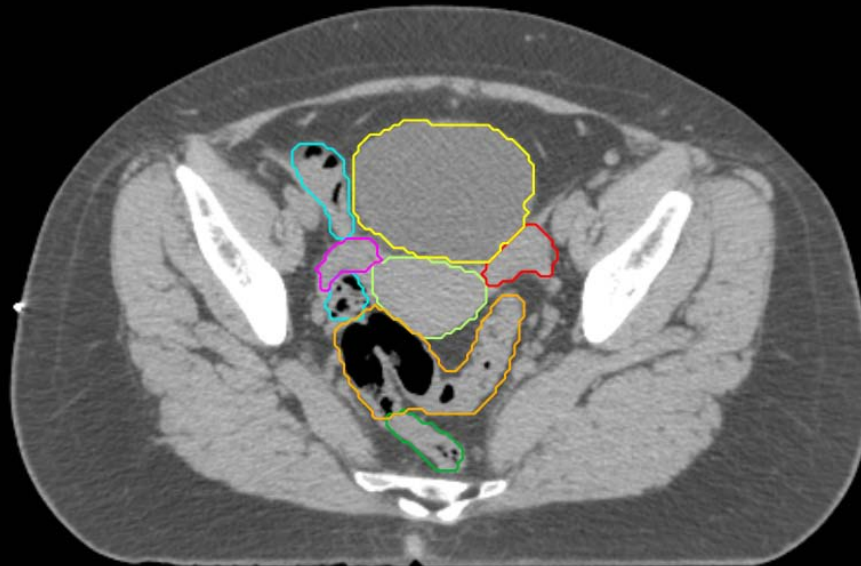
- UteroCervix
- Femur\_L
- Femur\_R
- Adnexa\_R
- Adnexa\_L
- Bladder

GI:

- Small Bowel
- AnoRectumSig
- Colon



Any Sigmoid adjacent or above the uterus or a brachytherapy applicator should be contoured





GYN:

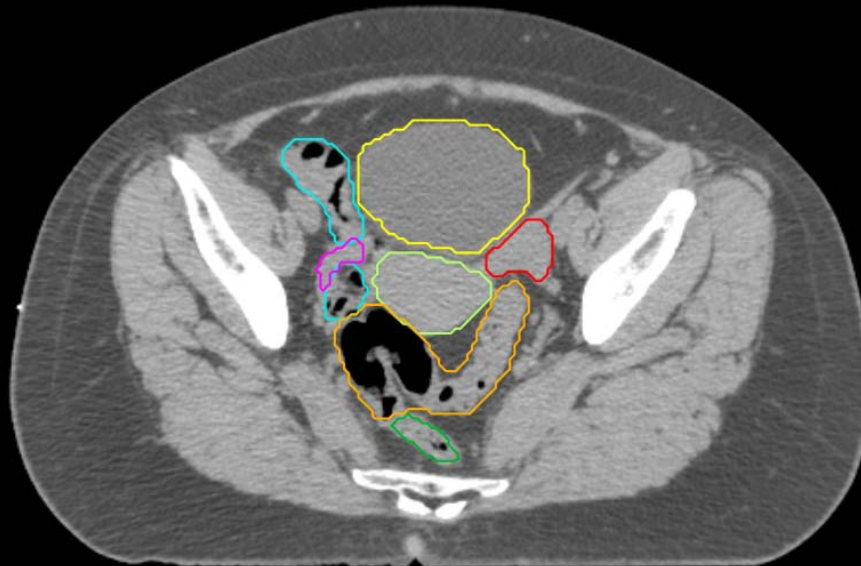
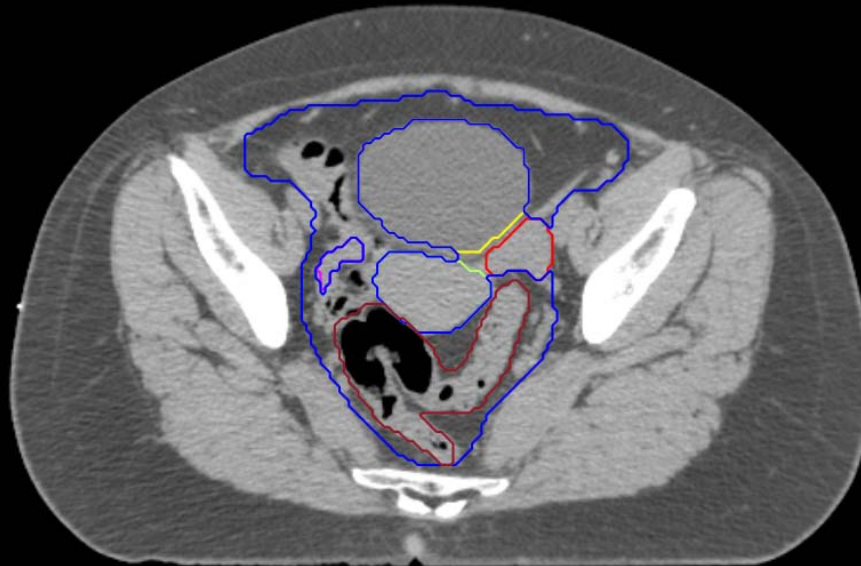- Sigmoid
- AnoRectum
- BowelBag

GYN/GI:

- UteroCervix
- Femur\_L
- Femur\_R
- Adnexa\_R
- Adnexa\_L
- Bladder

GI:

- Small Bowel
- AnoRectumSig
- Colon



GYN:

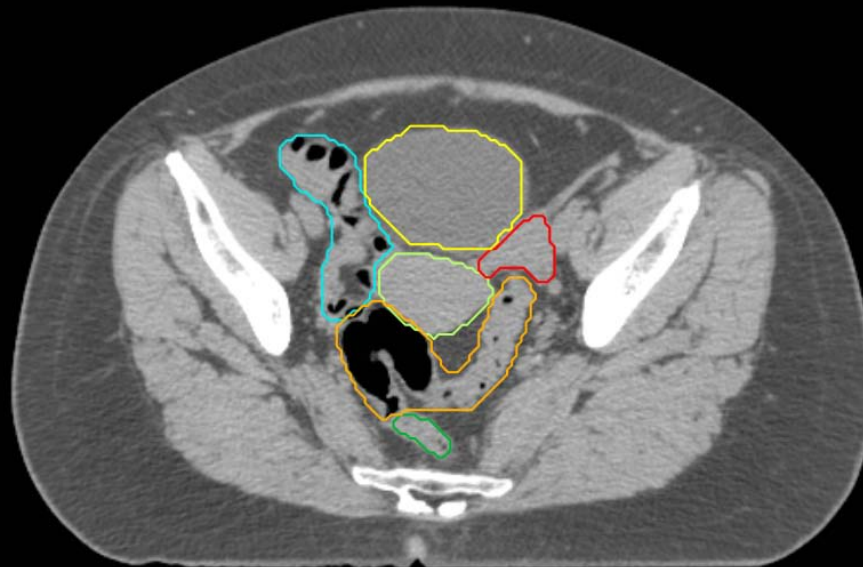
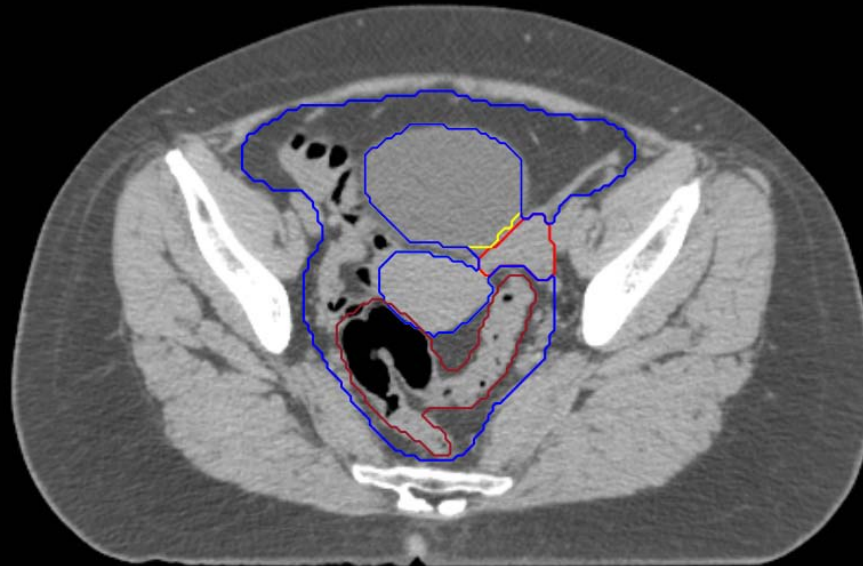
- Sigmoid
- AnoRectum
- BowelBag

GYN/GI:

- UteroCervix
- Femur\_L
- Femur\_R
- Adnexa\_R
- Adnexa\_L
- Bladder

GI:

- Small Bowel
- AnoRectumSig
- Colon



GYN:

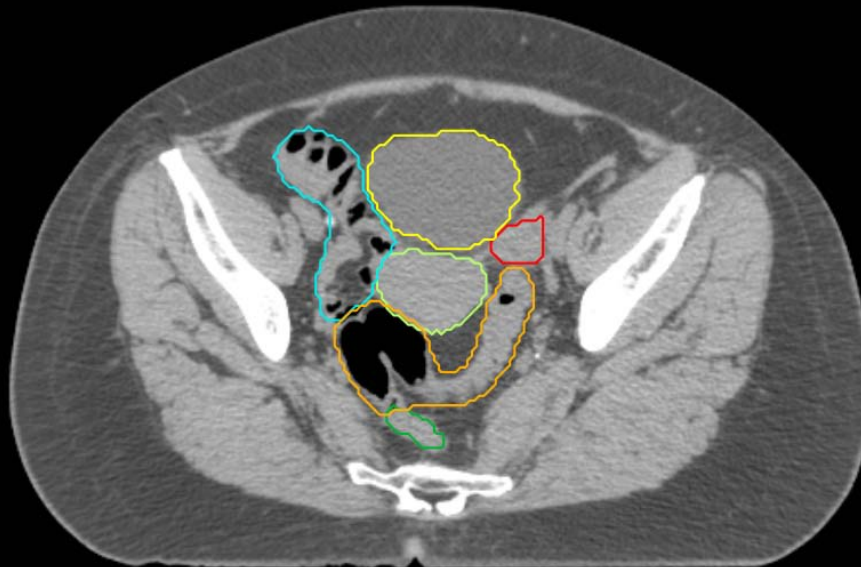
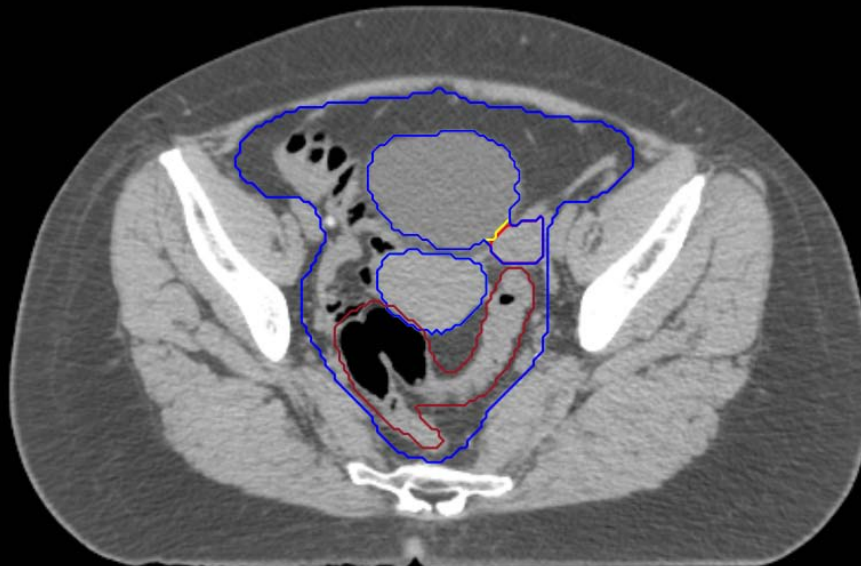- Sigmoid
- AnoRectum
- BowelBag

GYN/GI:

- UteroCervix
- Femur\_L
- Femur\_R
- Adnexa\_R
- Adnexa\_L
- Bladder

GI:

- Small Bowel
- AnoRectumSig
- Colon



GYN:

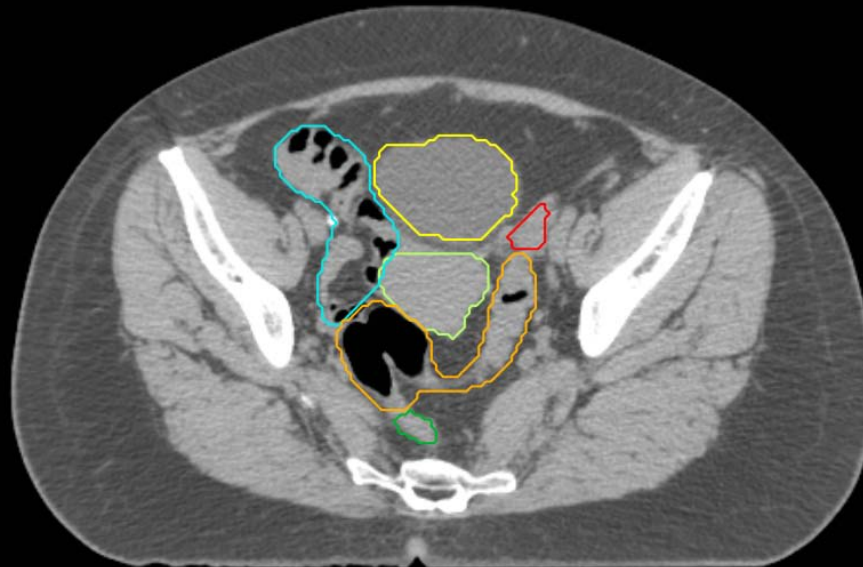
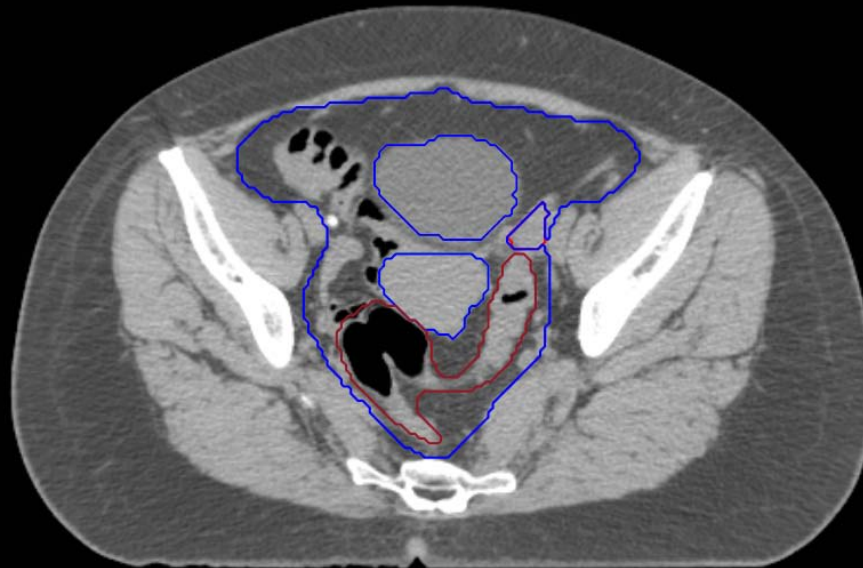
- Sigmoid
- AnoRectum
- BowelBag

GYN/GI:

- UteroCervix
- Femur\_L
- Femur\_R
- Adnexa\_R
- Adnexa\_L
- Bladder

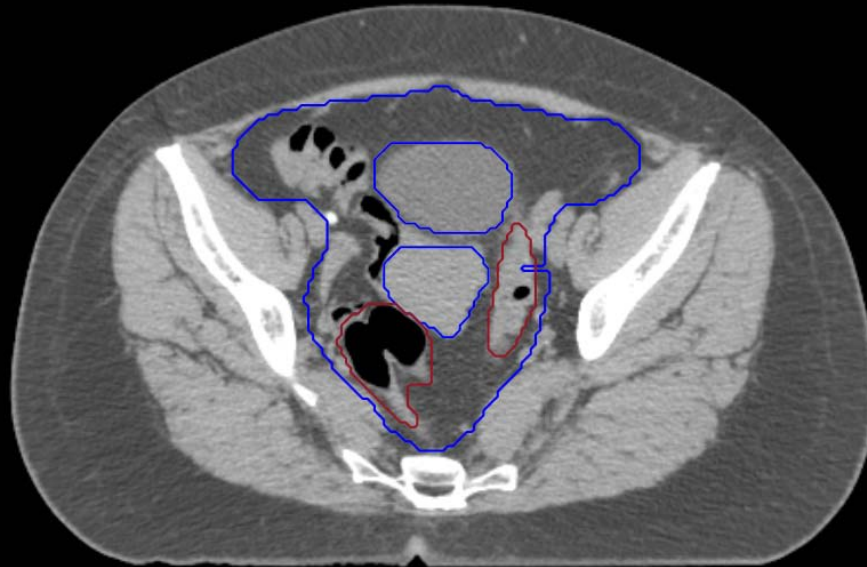
GI:

- Small Bowel
- AnoRectumSig
- Colon



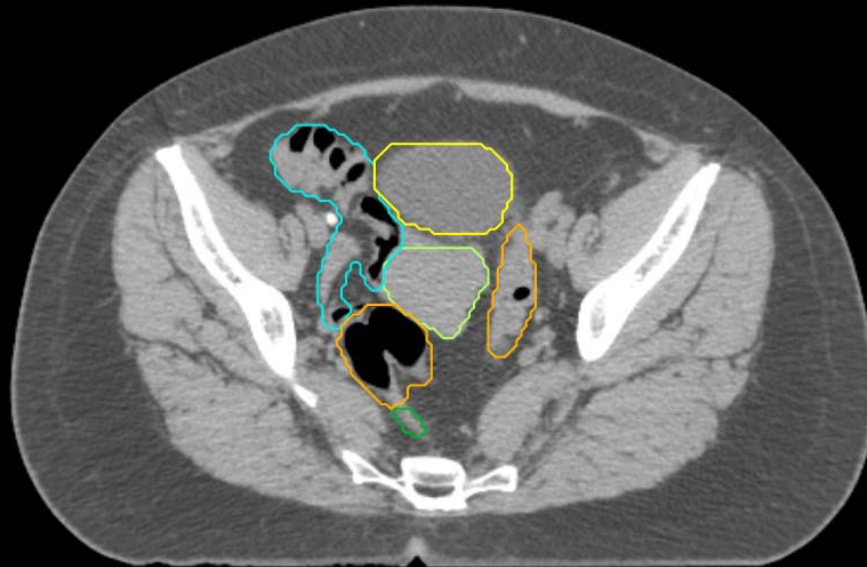
GYN:

- Sigmoid
- AnoRectum
- BowelBag



GYN/GI:

- UteroCervix
- Femur\_L
- Femur\_R
- Adnexa\_R
- Adnexa\_L
- Bladder

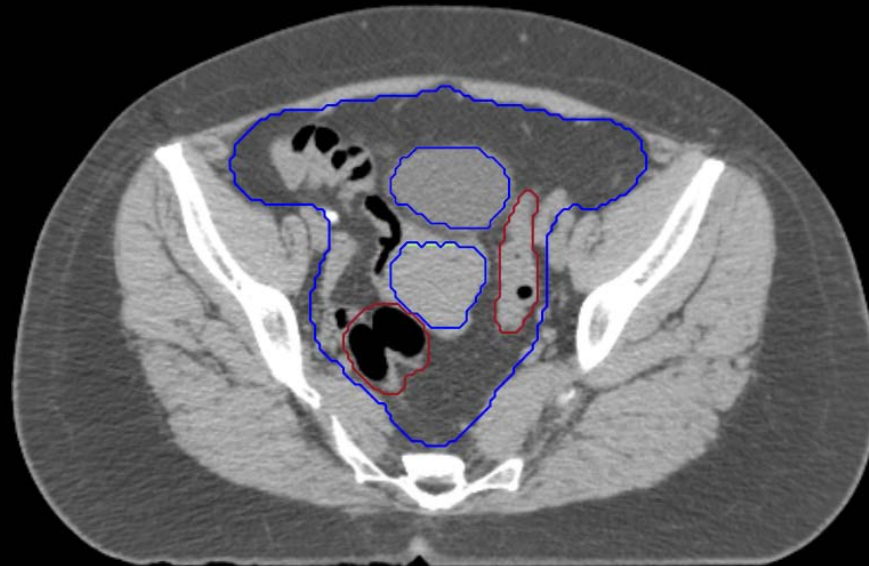


GI:

- Small Bowel
- AnoRectumSig
- Colon

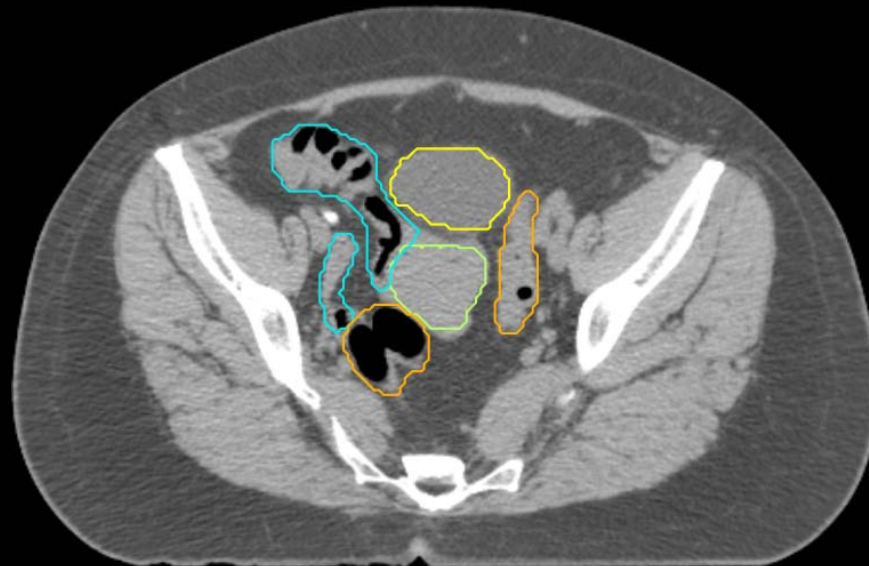GYN:

- Sigmoid
- AnoRectum
- BowelBag



GYN/GI:

- UteroCervix
- Femur\_L
- Femur\_R
- Adnexa\_R
- Adnexa\_L
- Bladder

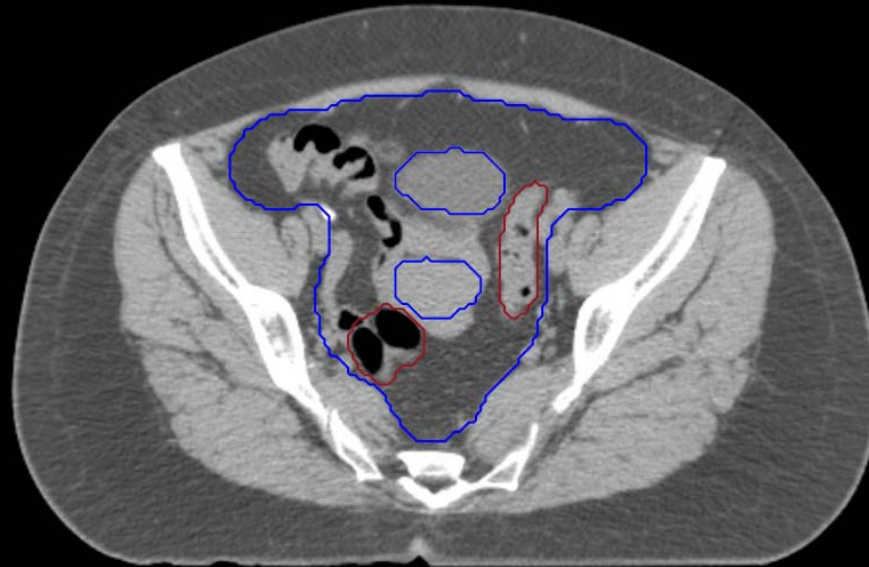


GI:

- Small Bowel
- AnoRectumSig
- Colon

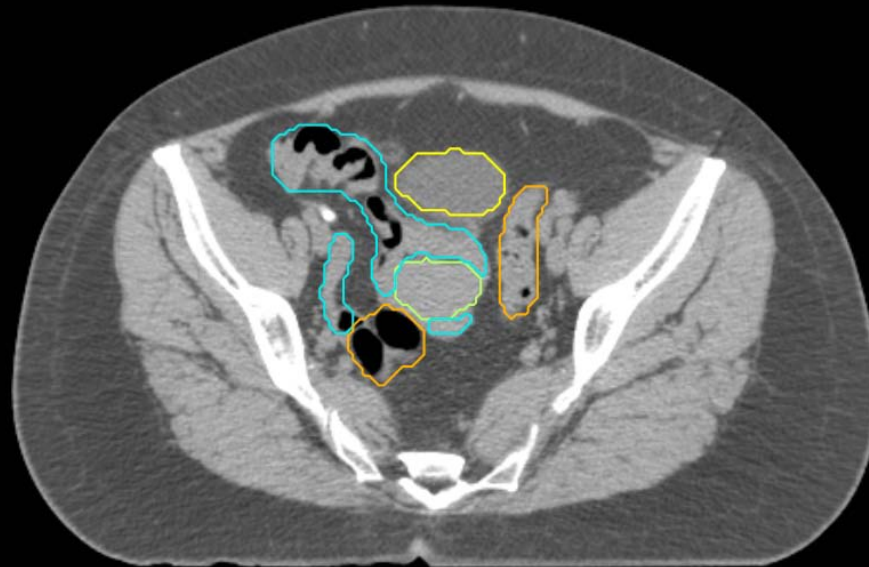GYN:

- Sigmoid
- AnoRectum
- BowelBag



GYN/GI:

- UteroCervix
- Femur\_L
- Femur\_R
- Adnexa\_R
- Adnexa\_L
- Bladder

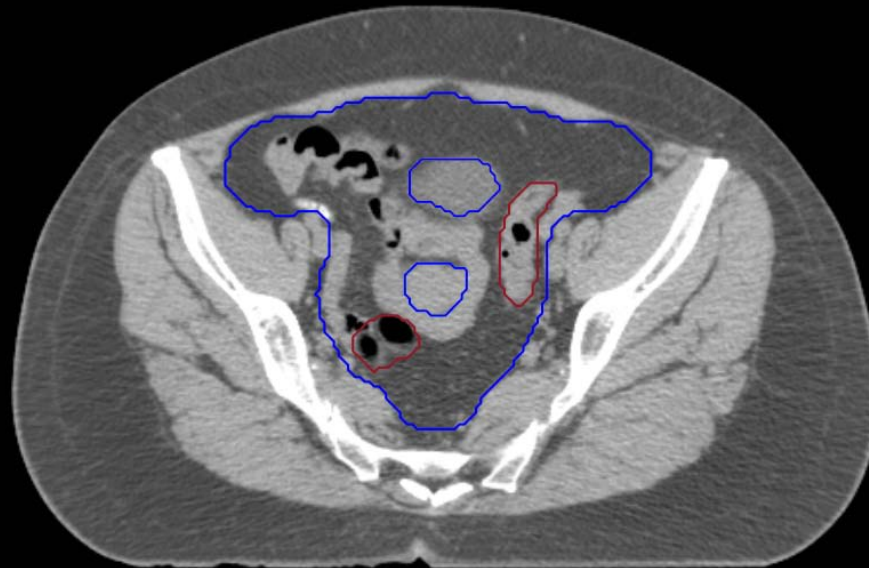


GI:

- Small Bowel
- AnoRectumSig
- Colon

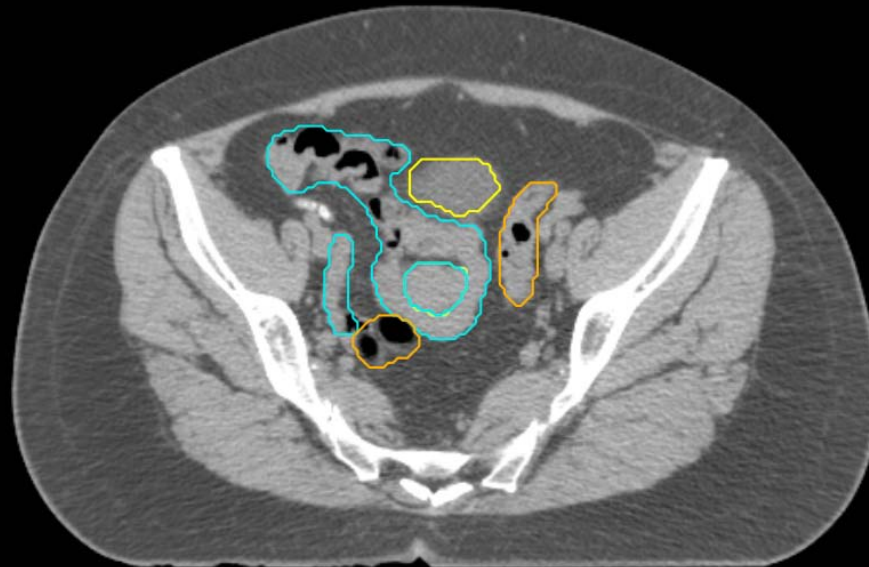
GYN:

- Sigmoid
- AnoRectum
- BowelBag



GYN/GI:

- UteroCervix
- Femur\_L
- Femur\_R
- Adnexa\_R
- Adnexa\_L
- Bladder



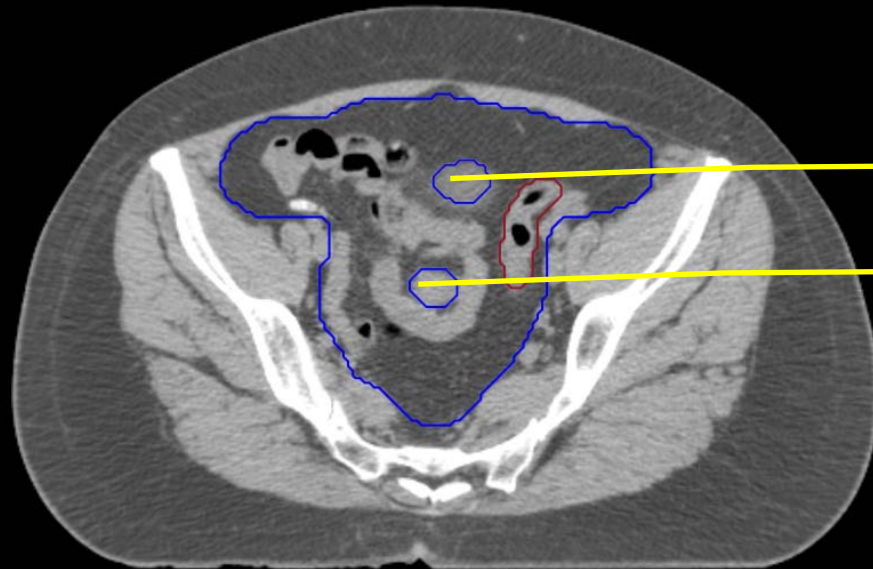
GI:

- Small Bowel
- AnoRectumSig
- Colon



GYN:

- Sigmoid
- AnoRectum
- BowelBag

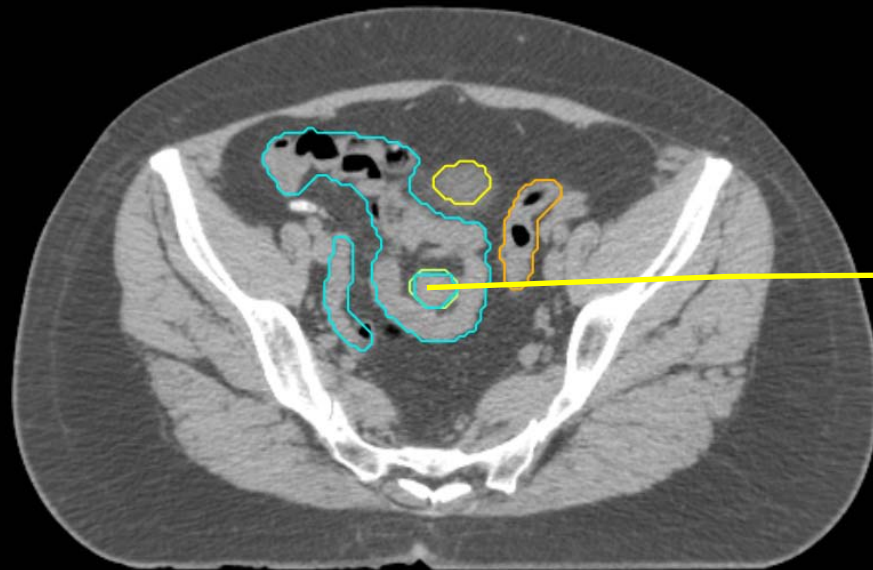


Bladder

UteroCervix

GYN/GI:

- UteroCervix
- Femur\_L
- Femur\_R
- Adnexa\_R
- Adnexa\_L
- Bladder



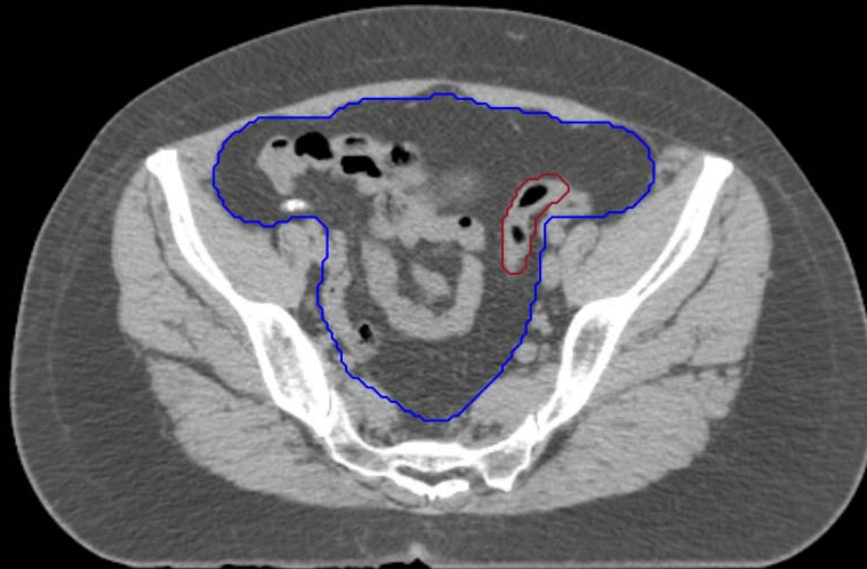UteroCervix

GI:

- Small Bowel
- AnoRectumSig
- Colon

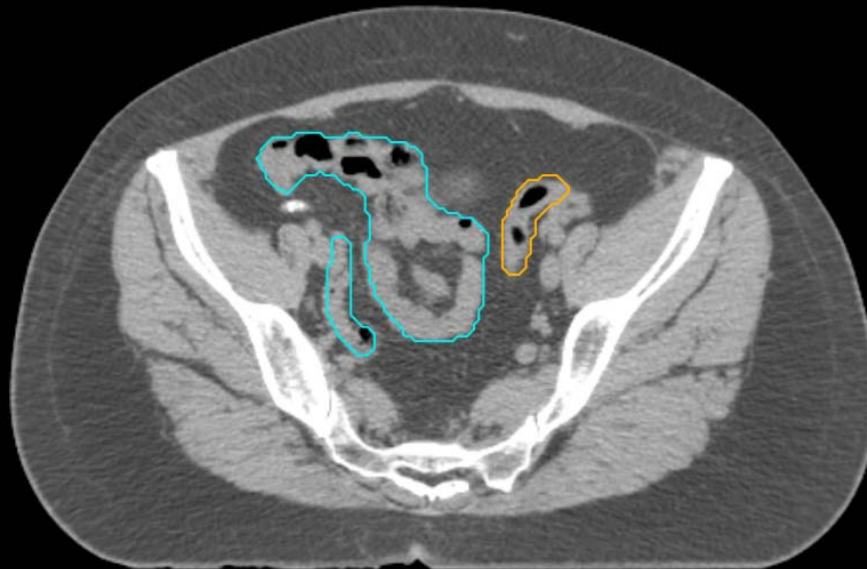
GYN:

- Sigmoid
- AnoRectum
- BowelBag



GYN/GI:

- UteroCervix
- Femur\_L
- Femur\_R
- Adnexa\_R
- Adnexa\_L
- Bladder

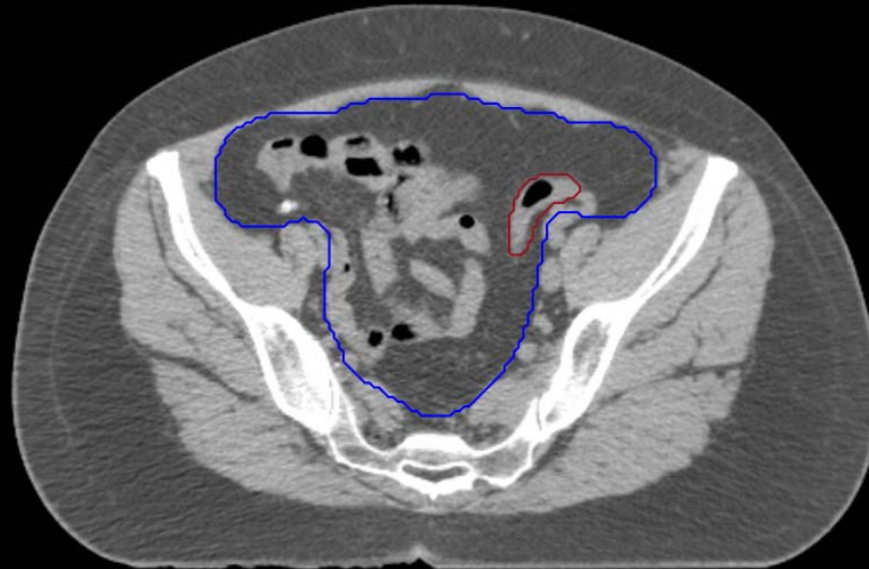

GI:

- Small Bowel
- AnoRectumSig
- Colon

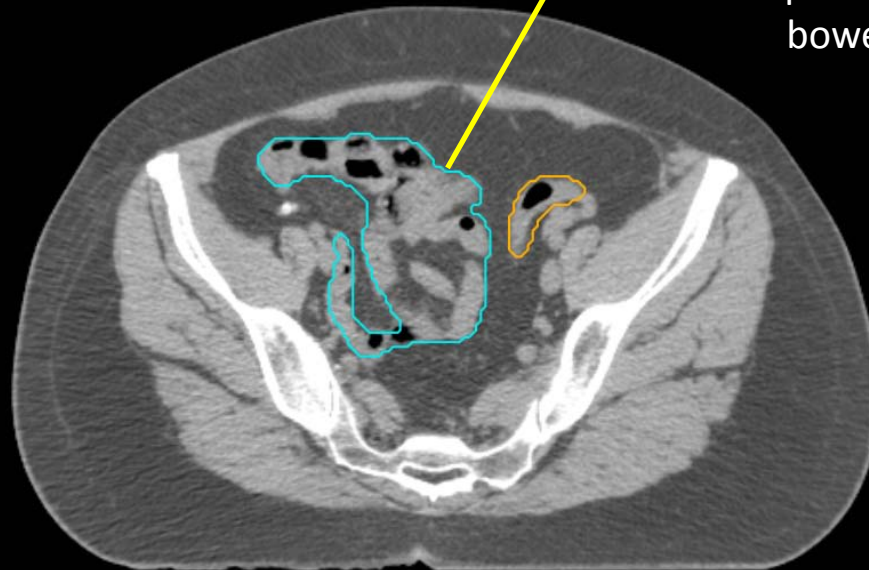
GYN:

- Sigmoid
- AnoRectum
- BowelBag



GYN/GI:

- UteroCervix
- Femur\_L
- Femur\_R
- Adnexa\_R
- Adnexa\_L
- Bladder



GI:

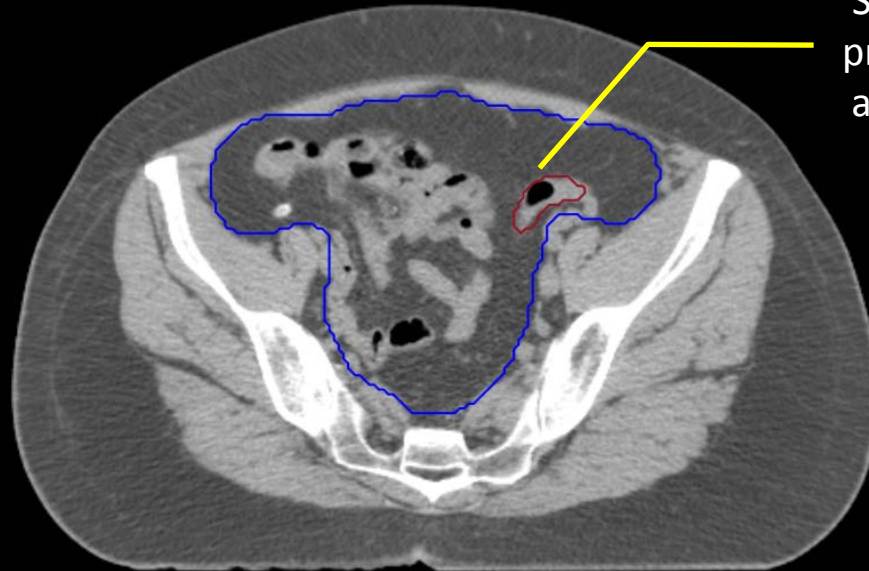
- Small Bowel
- AnoRectumSig
- Colon

oral contrast would have helped distinguish the small bowel from the colon

GYN:

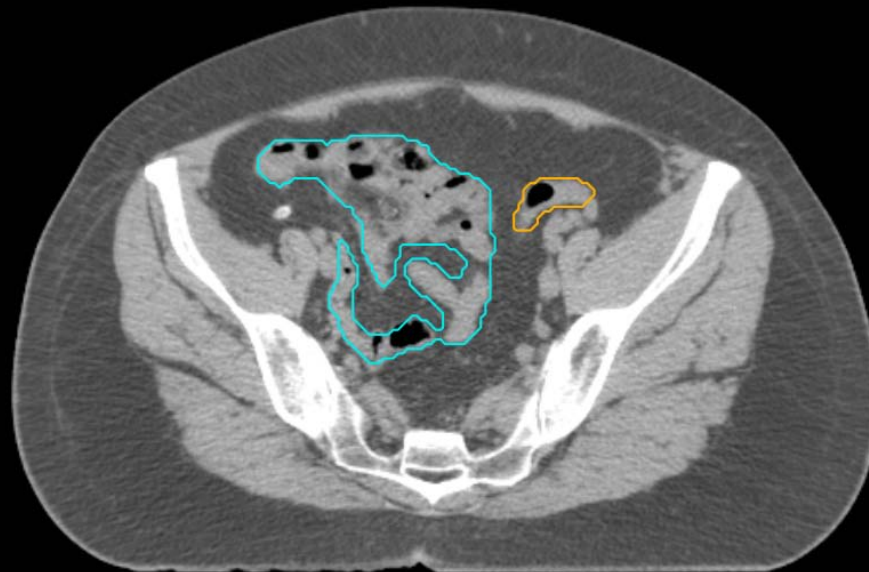
- Sigmoid
- AnoRectum
- BowelBag

Stop contouring Sigmoid prior to connecting to the ascending colon laterally



GYN/GI:

- UteroCervix
- Femur\_L
- Femur\_R
- Adnexa\_R
- Adnexa\_L
- Bladder

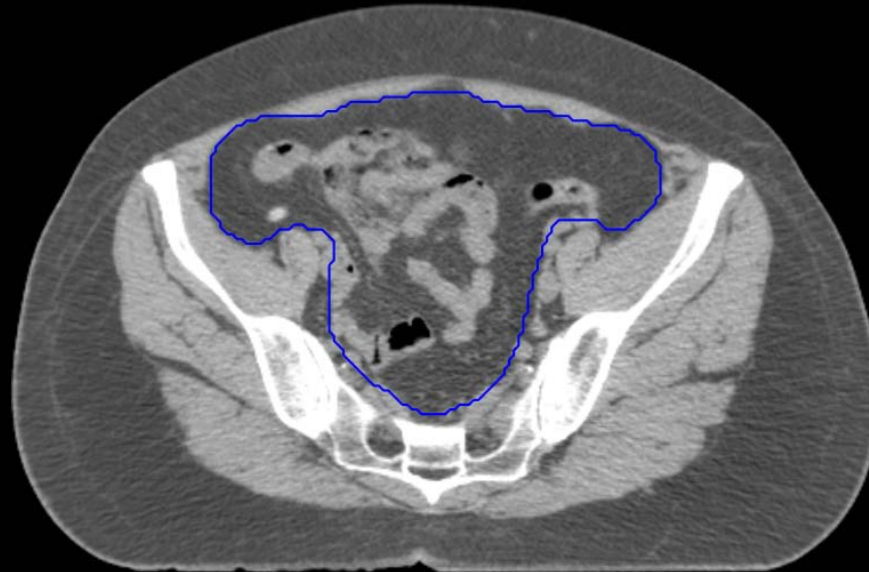

GI:

- Small Bowel
- AnoRectumSig
- Colon

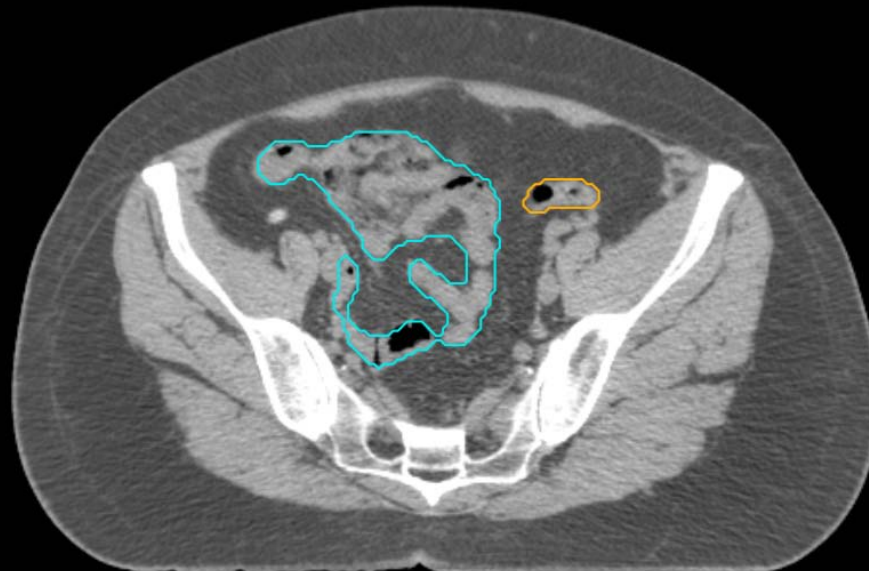
GYN:

- Sigmoid
- AnoRectum
- BowelBag



GYN/GI:

- UteroCervix
- Femur\_L
- Femur\_R
- Adnexa\_R
- Adnexa\_L
- Bladder

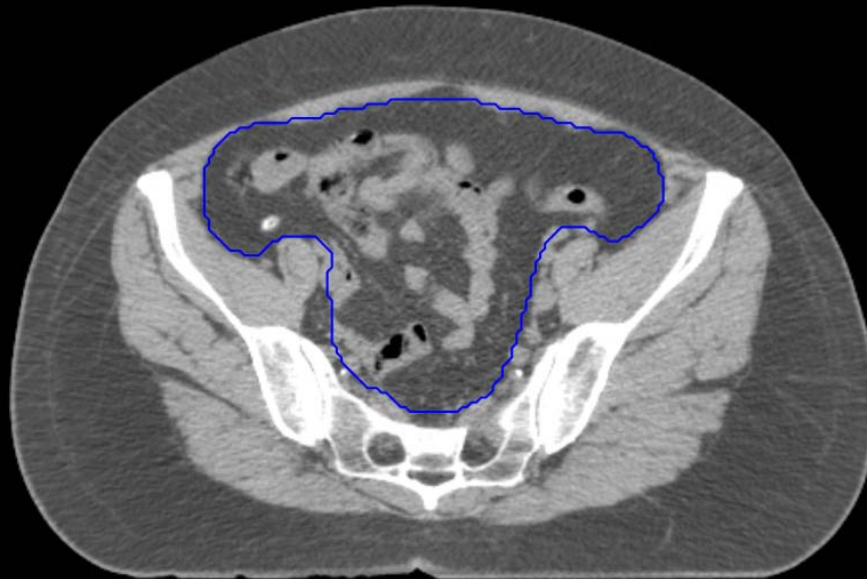

GI:

- Small Bowel
- AnoRectumSig
- Colon

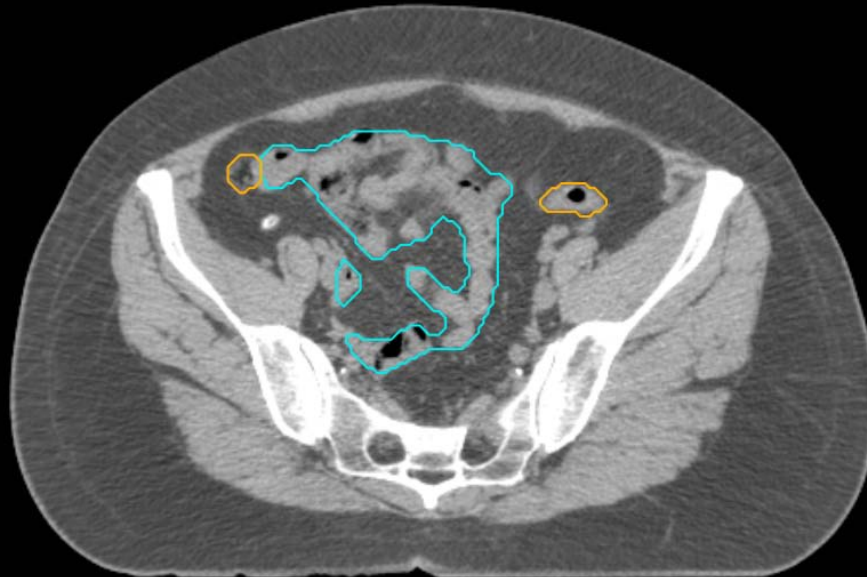
GYN:

- Sigmoid
- AnoRectum
- BowelBag



GYN/GI:

- UteroCervix
- Femur\_L
- Femur\_R
- Adnexa\_R
- Adnexa\_L
- Bladder

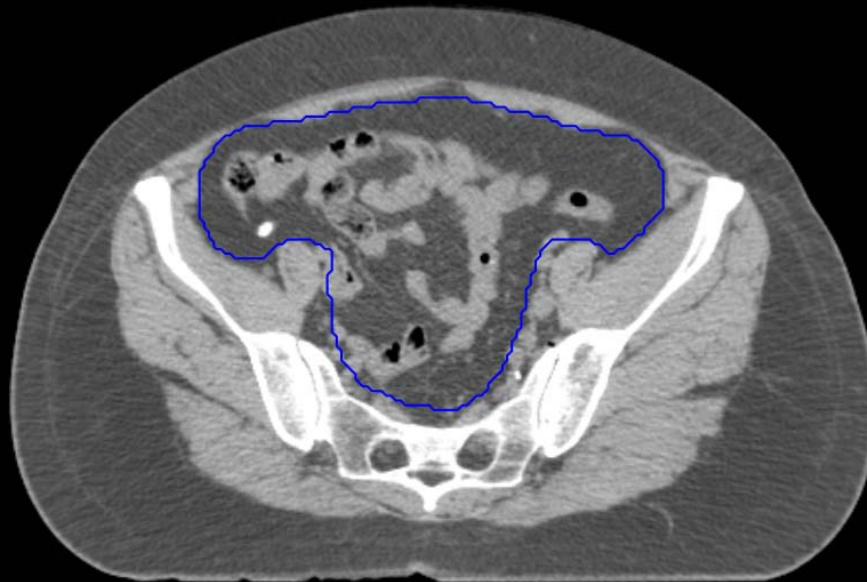


GI:

- Small Bowel
- AnoRectumSig
- Colon

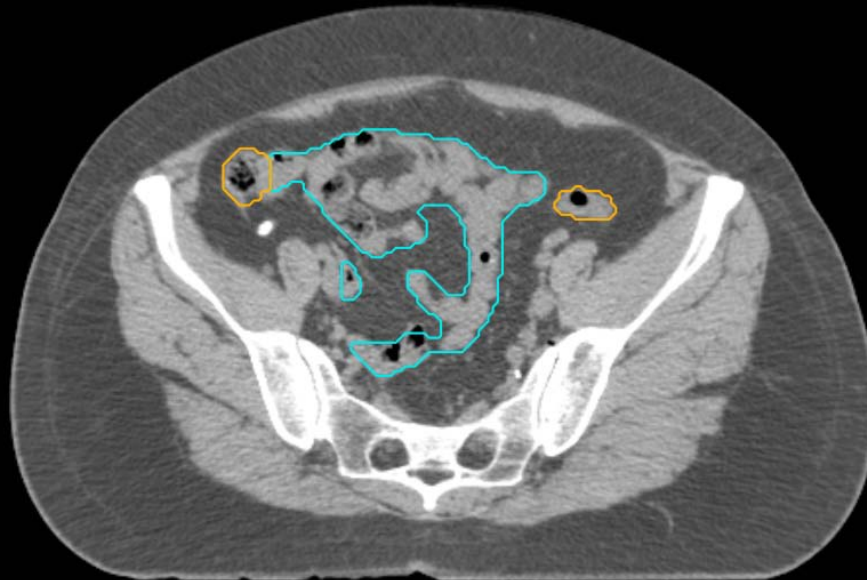
GYN:

- Sigmoid
- AnoRectum
- BowelBag



GYN/GI:

- UteroCervix
- Femur\_L
- Femur\_R
- Adnexa\_R
- Adnexa\_L
- Bladder



GI:

- Small Bowel
- AnoRectumSig
- Colon

GYN:

- Sigmoid
- AnoRectum
- BowelBag

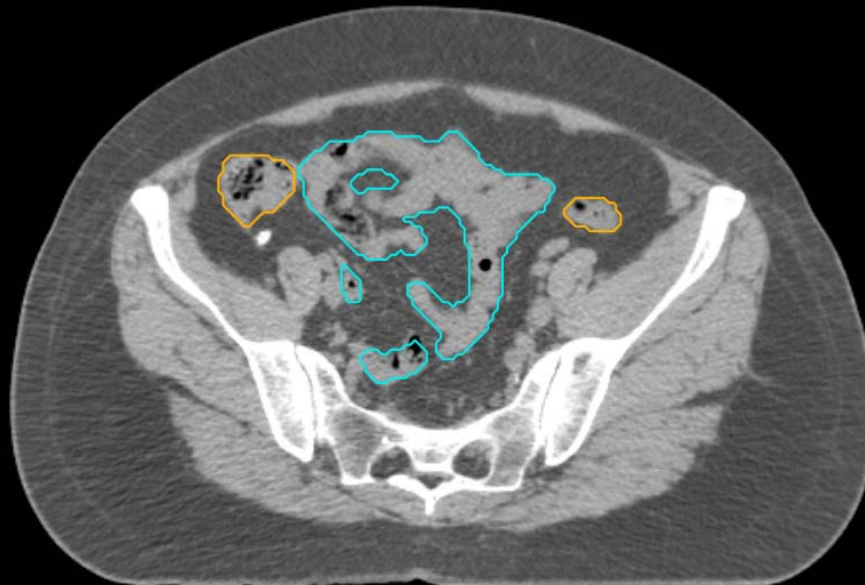
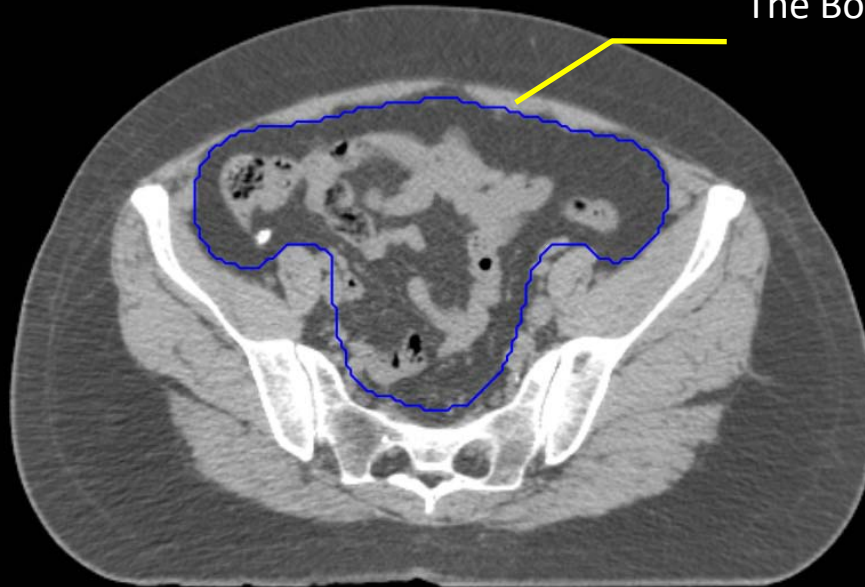
GYN/GI:

- UteroCervix
- Femur\_L
- Femur\_R
- Adnexa\_R
- Adnexa\_L
- Bladder

GI:

- Small Bowel
- AnoRectumSig
- Colon

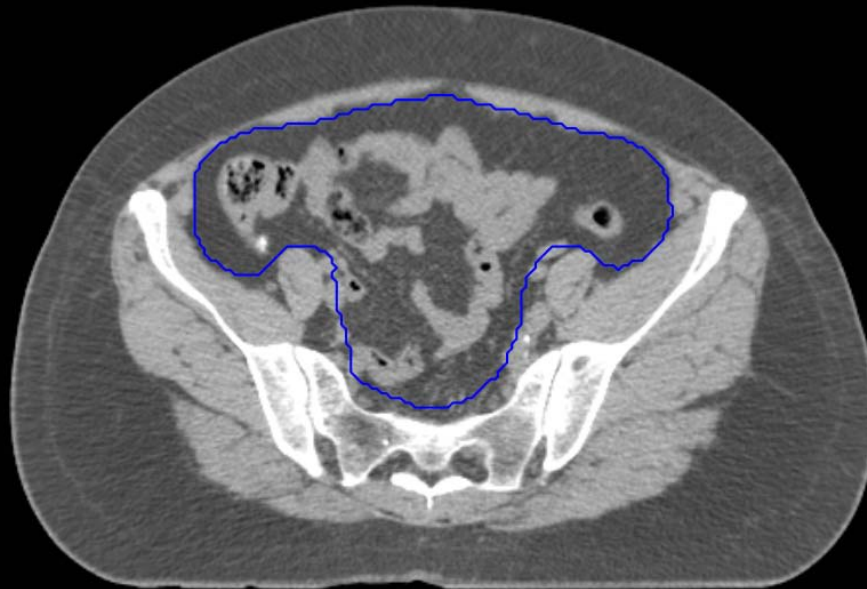
The BowelBag is bounded by the muscles and bone.





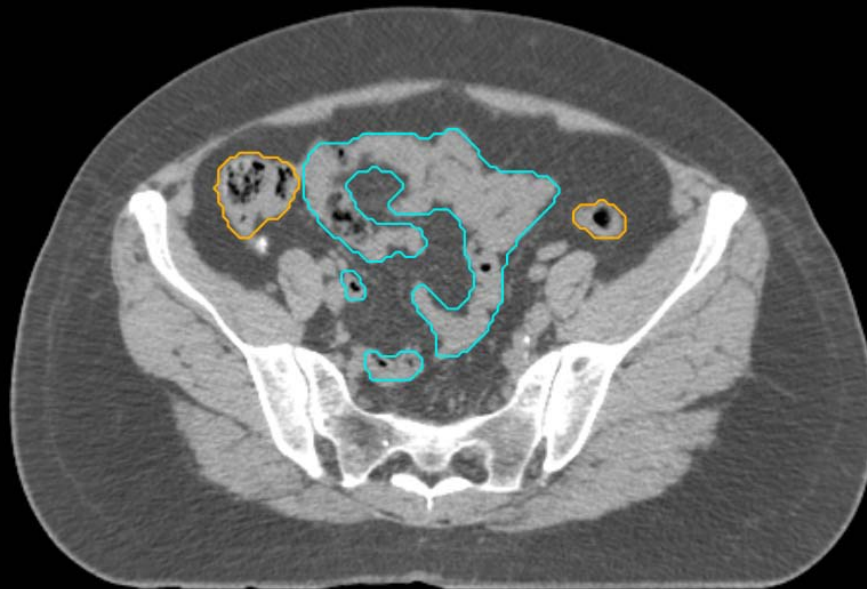GYN:

- Sigmoid
- AnoRectum
- BowelBag



GYN/GI:

- UteroCervix
- Femur\_L
- Femur\_R
- Adnexa\_R
- Adnexa\_L
- Bladder



GI:

- Small Bowel
- AnoRectumSig
- Colon

GYN:

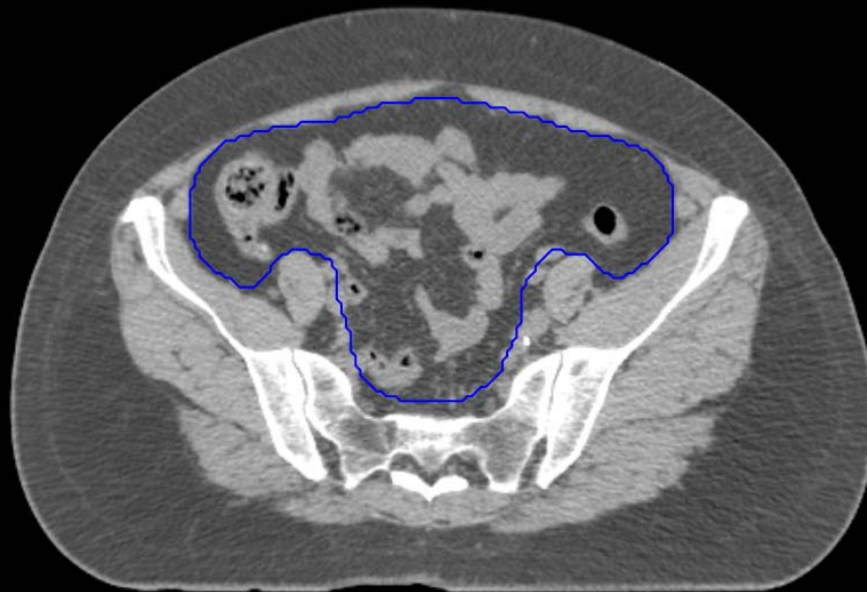- Sigmoid
- AnoRectum
- BowelBag

GYN/GI:

- UteroCervix
- Femur\_L
- Femur\_R
- Adnexa\_R
- Adnexa\_L
- Bladder

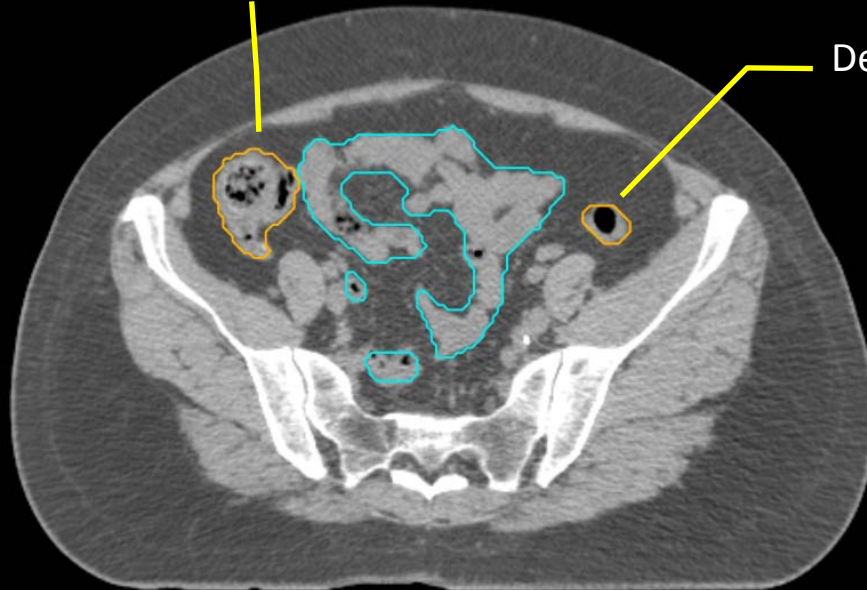
GI:

- Small Bowel
- AnoRectumSig
- Colon



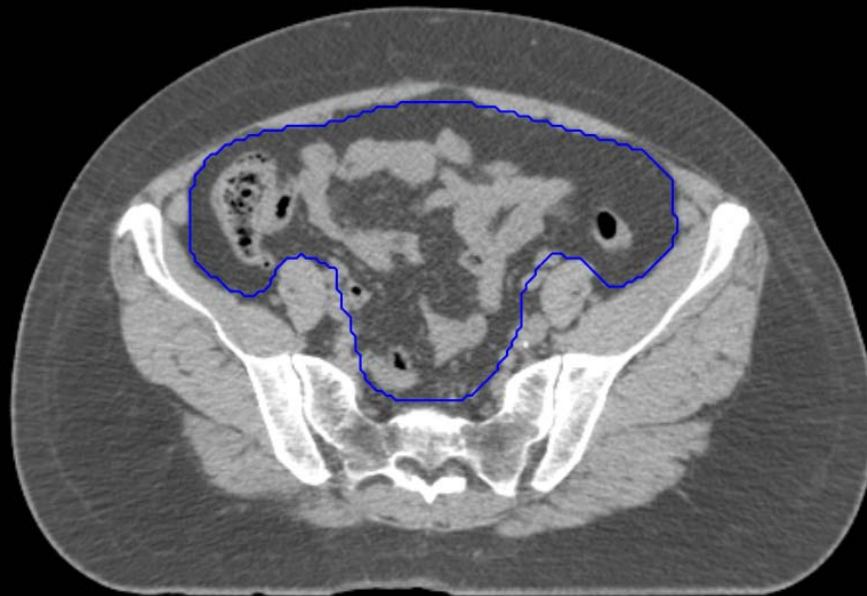Ascending Colon

Descending Colon



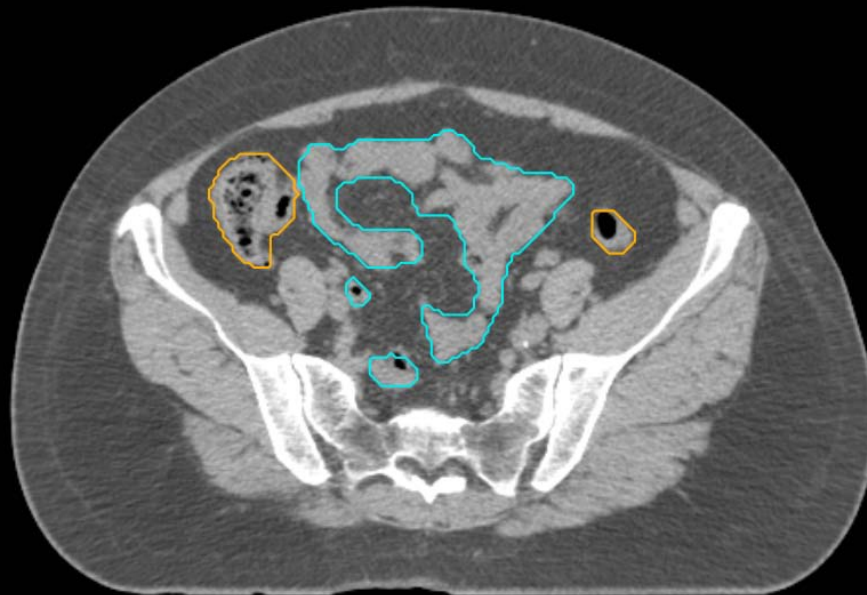
GYN:

- Sigmoid
- AnoRectum
- BowelBag



GYN/GI:

- UteroCervix
- Femur\_L
- Femur\_R
- Adnexa\_R
- Adnexa\_L
- Bladder

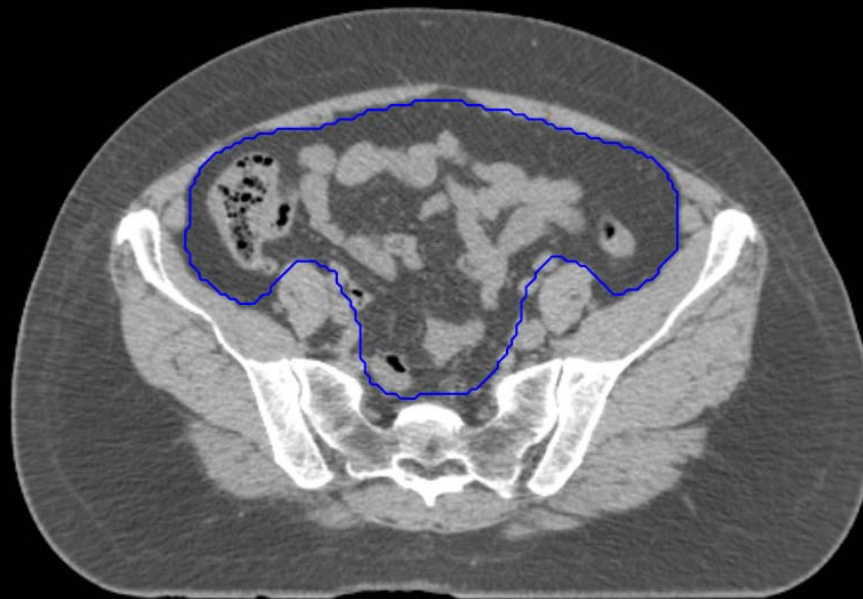


GI:

- Small Bowel
- AnoRectumSig
- Colon

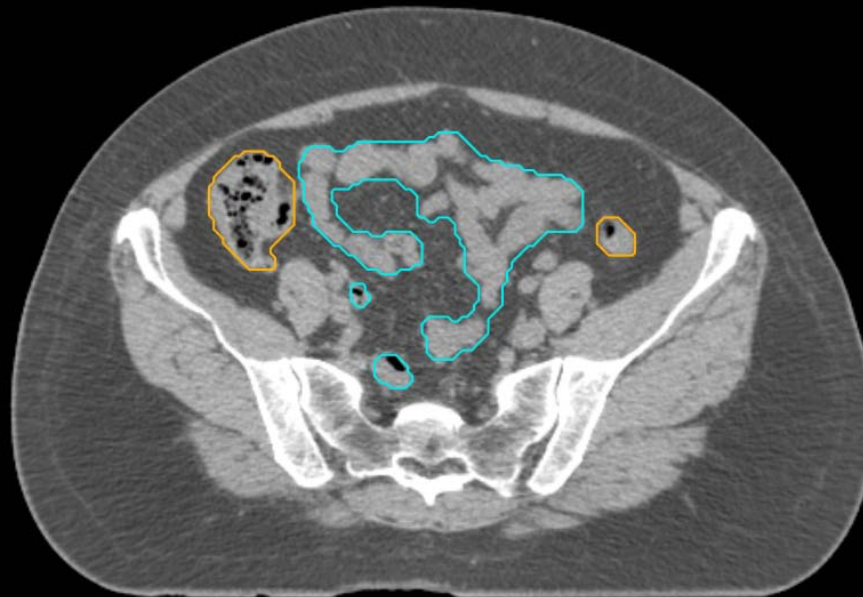
GYN:

- Sigmoid
- AnoRectum
- BowelBag



GYN/GI:

- UteroCervix
- Femur\_L
- Femur\_R
- Adnexa\_R
- Adnexa\_L
- Bladder

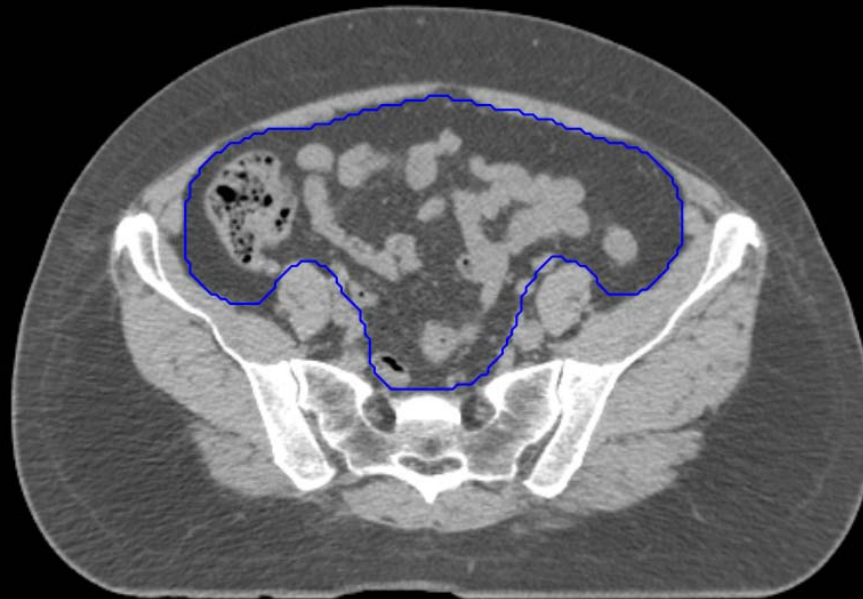

GI:

- Small Bowel
- AnoRectumSig
- Colon

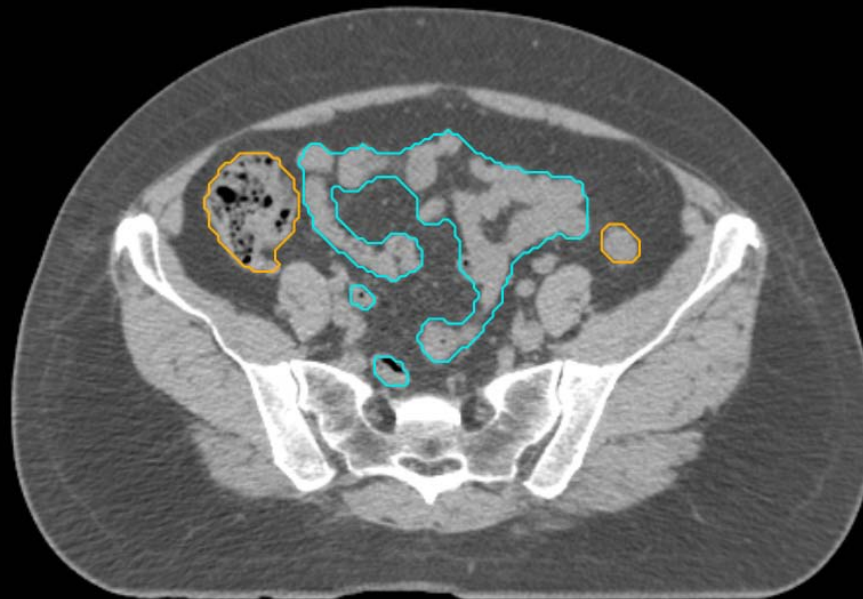
GYN:

- Sigmoid
- AnoRectum
- BowelBag



GYN/GI:

- UteroCervix
- Femur\_L
- Femur\_R
- Adnexa\_R
- Adnexa\_L
- Bladder

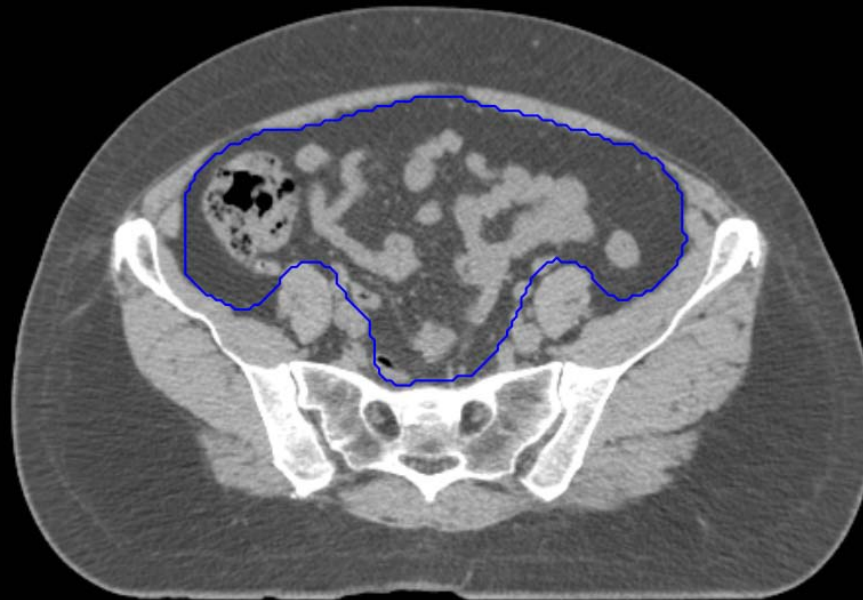

GI:

- Small Bowel
- AnoRectumSig
- Colon

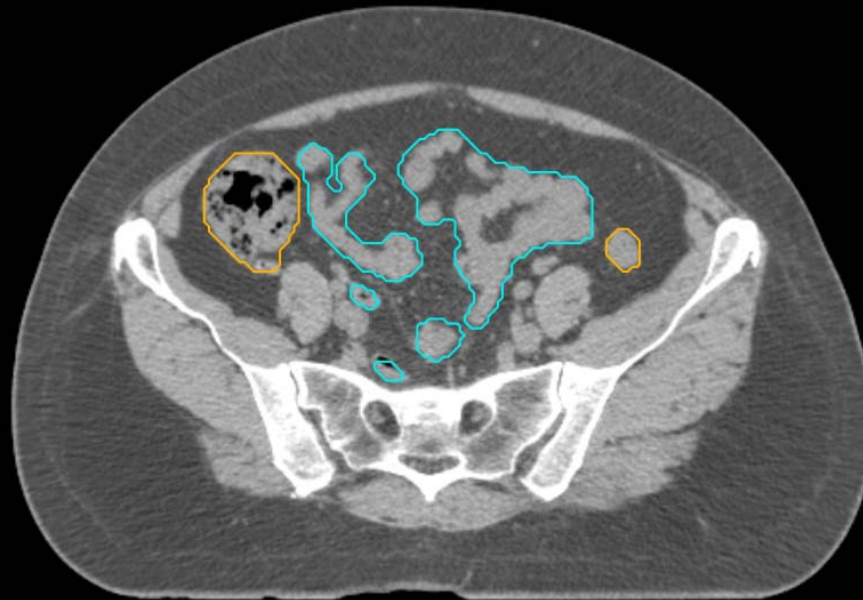
GYN:

- Sigmoid
- AnoRectum
- BowelBag



GYN/GI:

- UteroCervix
- Femur\_L
- Femur\_R
- Adnexa\_R
- Adnexa\_L
- Bladder

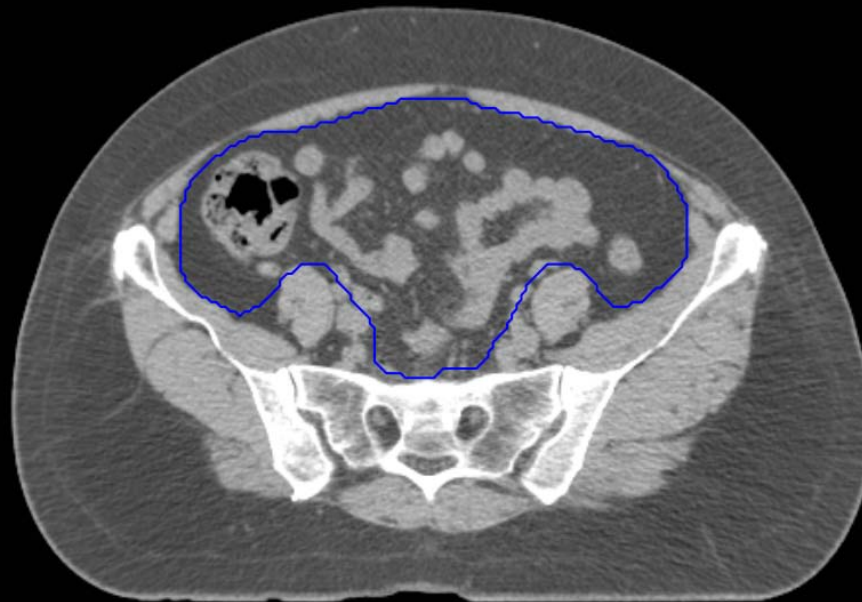


GI:

- Small Bowel
- AnoRectumSig
- Colon

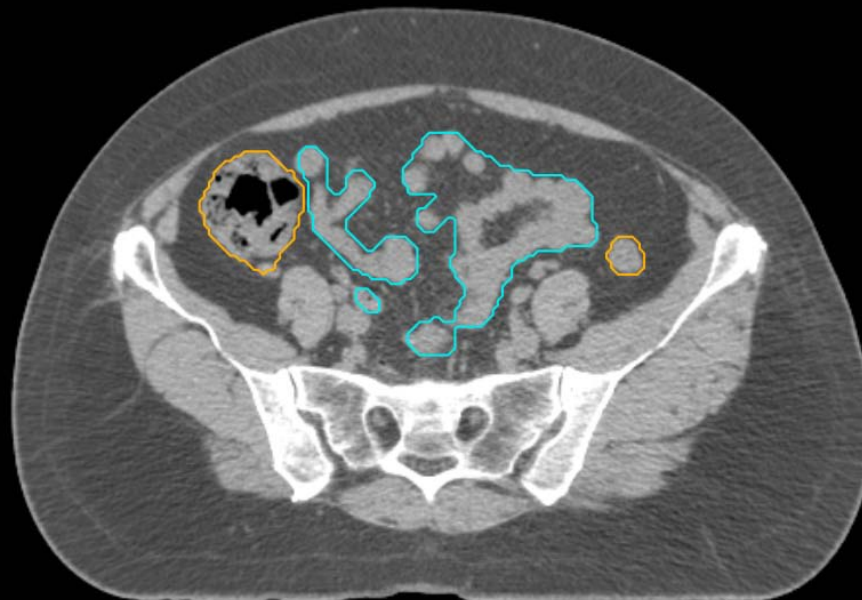
GYN:

- Sigmoid
- AnoRectum
- BowelBag



GYN/GI:

- UteroCervix
- Femur\_L
- Femur\_R
- Adnexa\_R
- Adnexa\_L
- Bladder

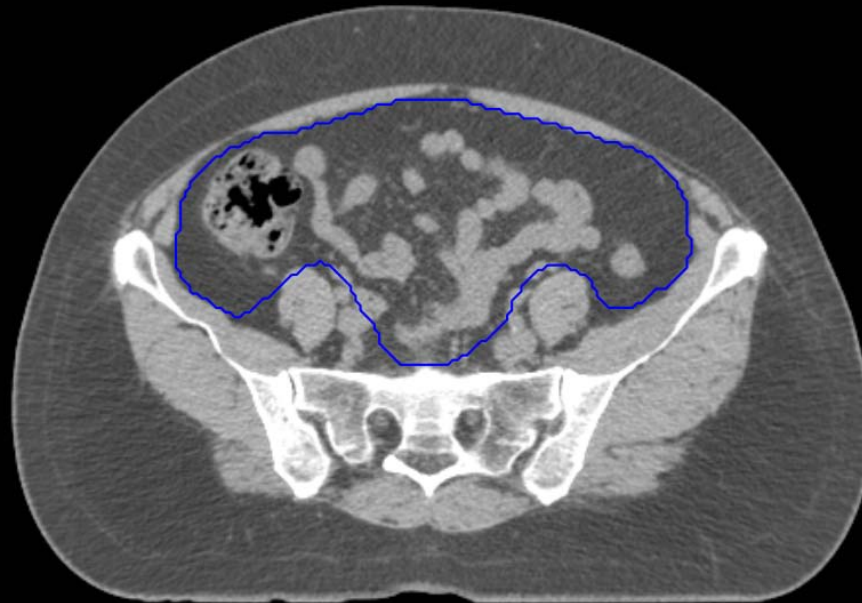


GI:

- Small Bowel
- AnoRectumSig
- Colon

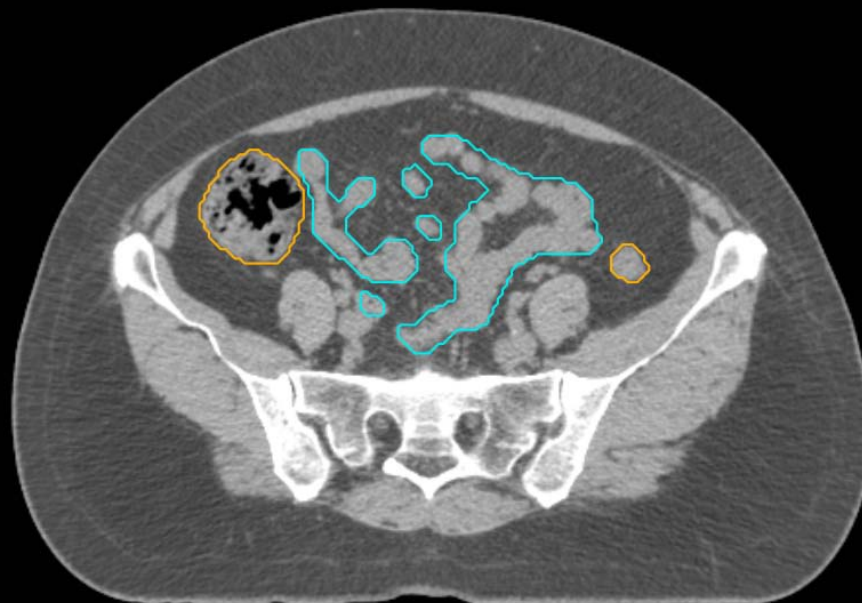
GYN:

- Sigmoid
- AnoRectum
- BowelBag



GYN/GI:

- UteroCervix
- Femur\_L
- Femur\_R
- Adnexa\_R
- Adnexa\_L
- Bladder



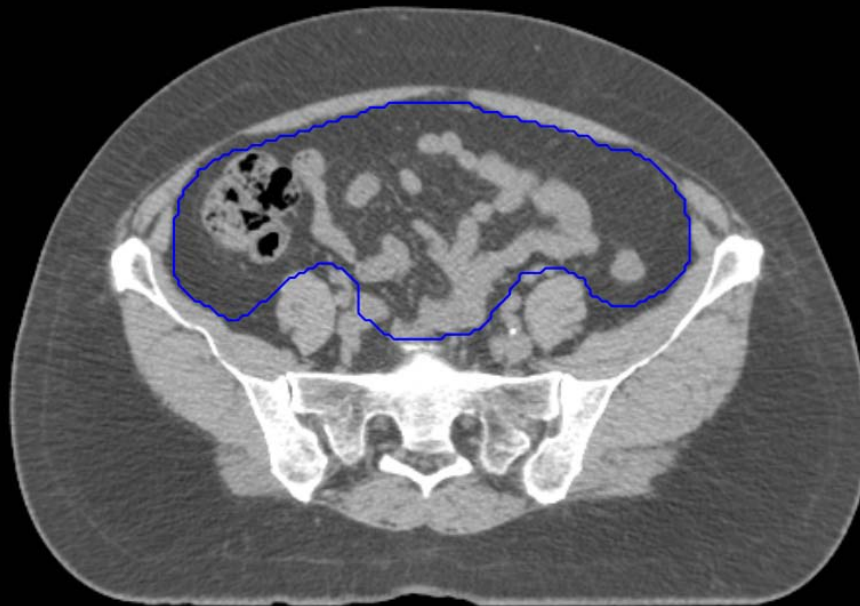
GI:

- Small Bowel
- AnoRectumSig
- Colon



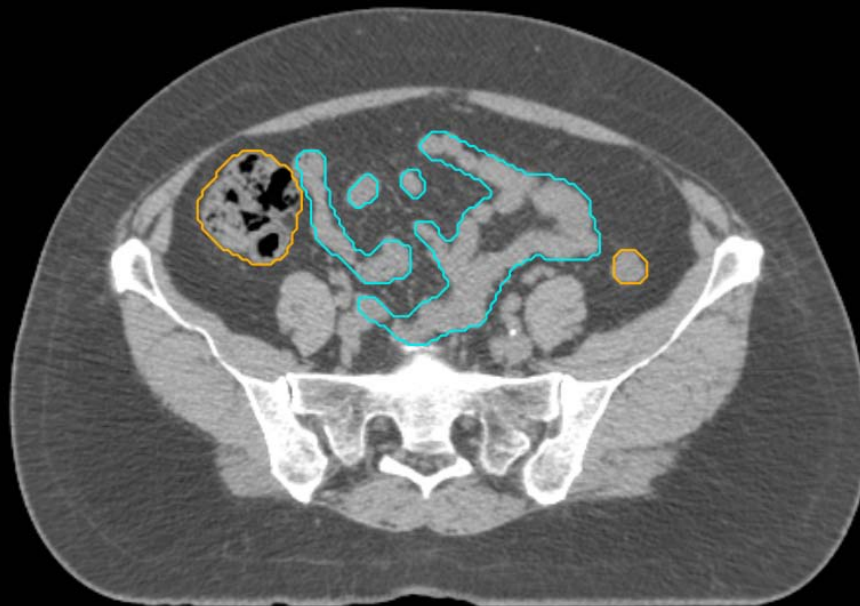
GYN:

- Sigmoid
- AnoRectum
- BowelBag



GYN/GI:

- UteroCervix
- Femur\_L
- Femur\_R
- Adnexa\_R
- Adnexa\_L
- Bladder

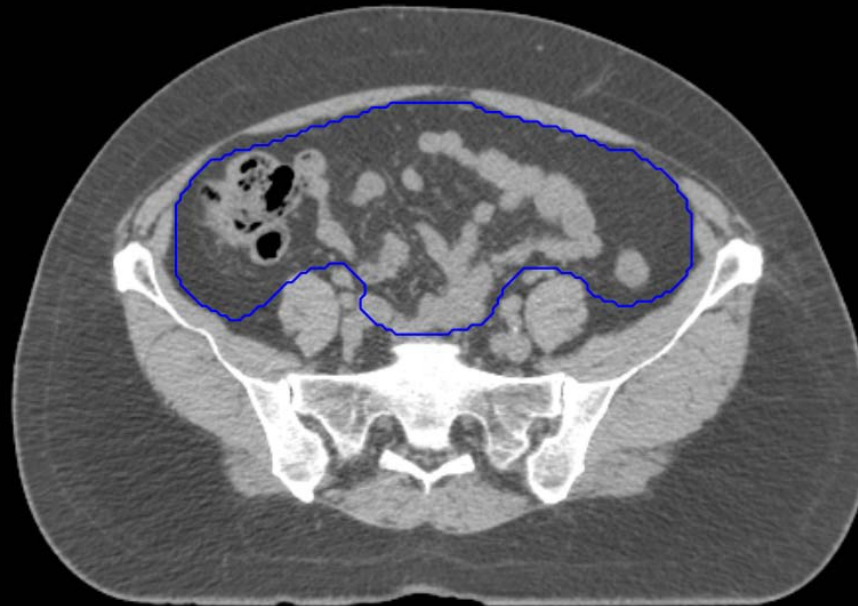

GI:

- Small Bowel
- AnoRectumSig
- Colon

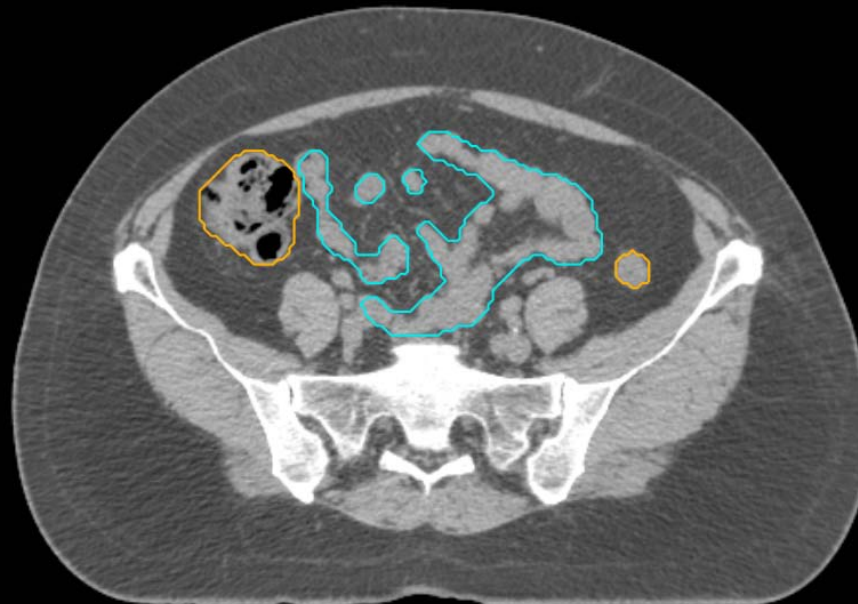GYN:

- Sigmoid
- AnoRectum
- BowelBag



GYN/GI:

- UteroCervix
- Femur\_L
- Femur\_R
- Adnexa\_R
- Adnexa\_L
- Bladder

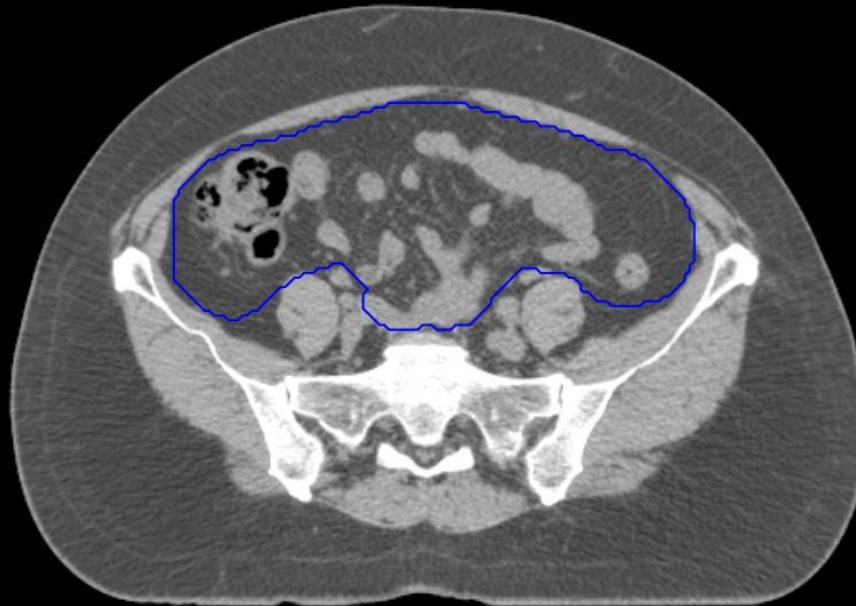


GI:

- Small Bowel
- AnoRectumSig
- Colon

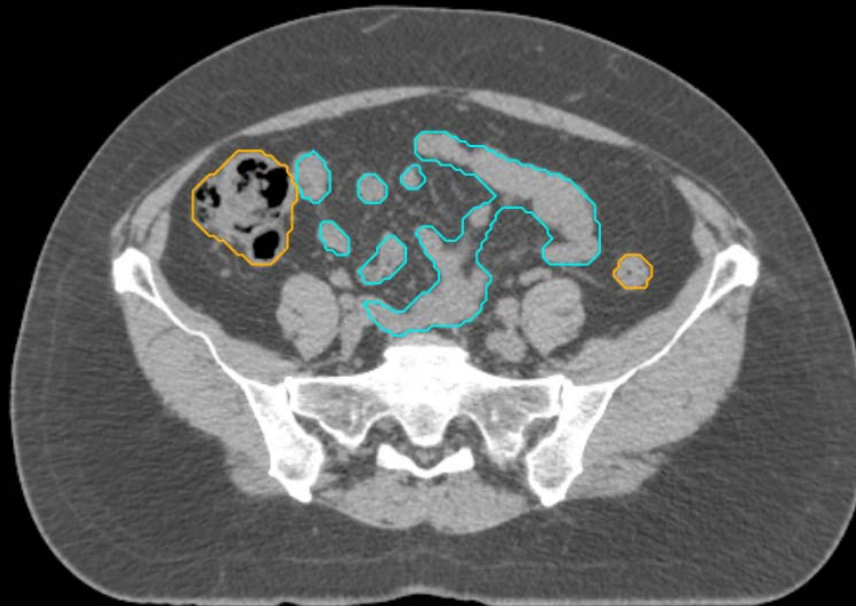
GYN:

- Sigmoid
- AnoRectum
- BowelBag



GYN/GI:

- UteroCervix
- Femur\_L
- Femur\_R
- Adnexa\_R
- Adnexa\_L
- Bladder

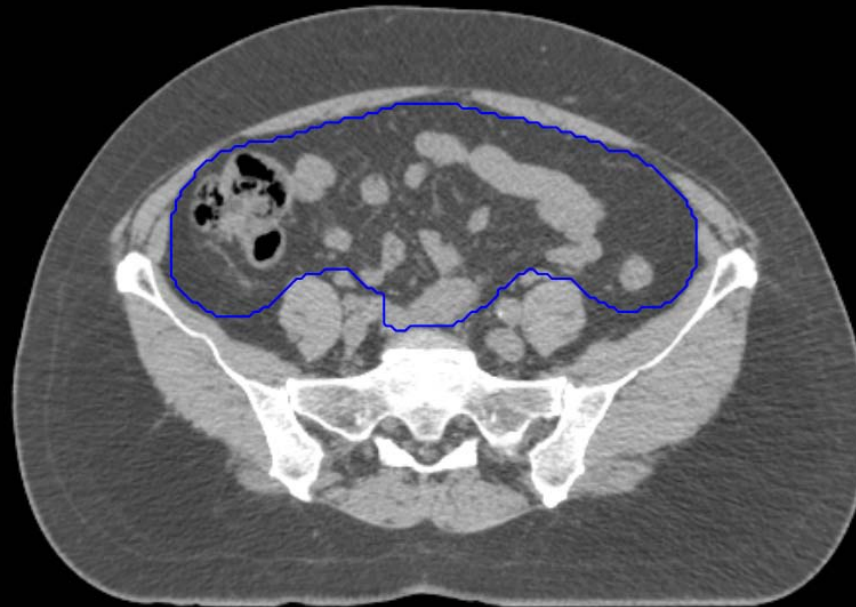


GI:

- Small Bowel
- AnoRectumSig
- Colon

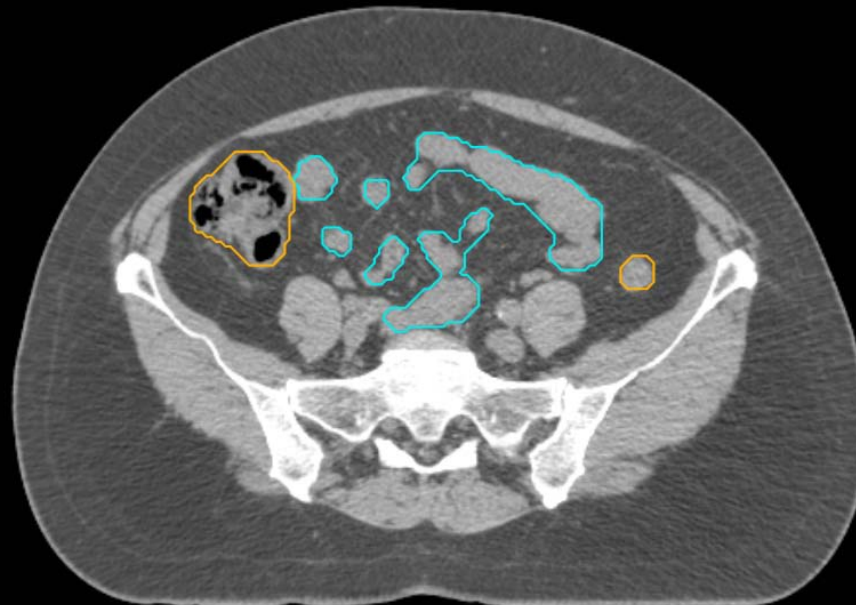
GYN:

- Sigmoid
- AnoRectum
- BowelBag



GYN/GI:

- UteroCervix
- Femur\_L
- Femur\_R
- Adnexa\_R
- Adnexa\_L
- Bladder

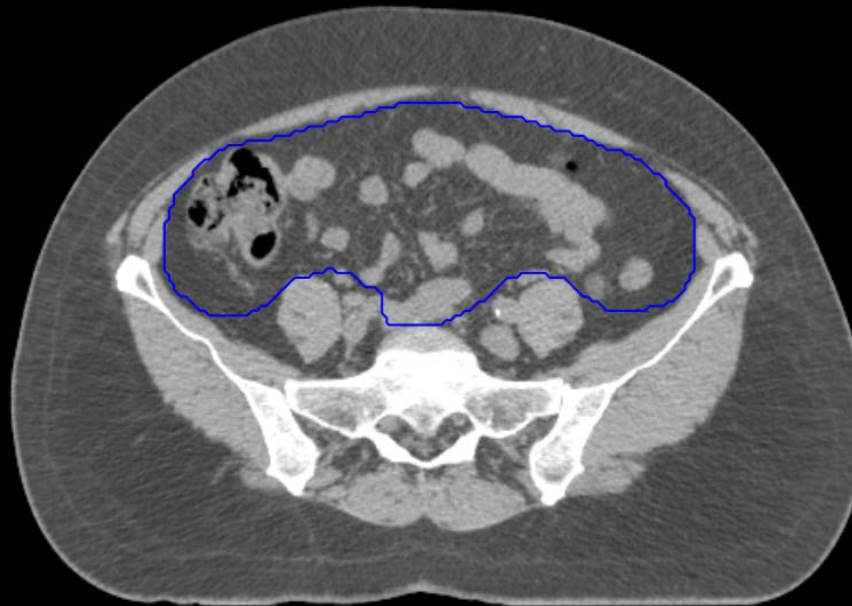


GI:

- Small Bowel
- AnoRectumSig
- Colon

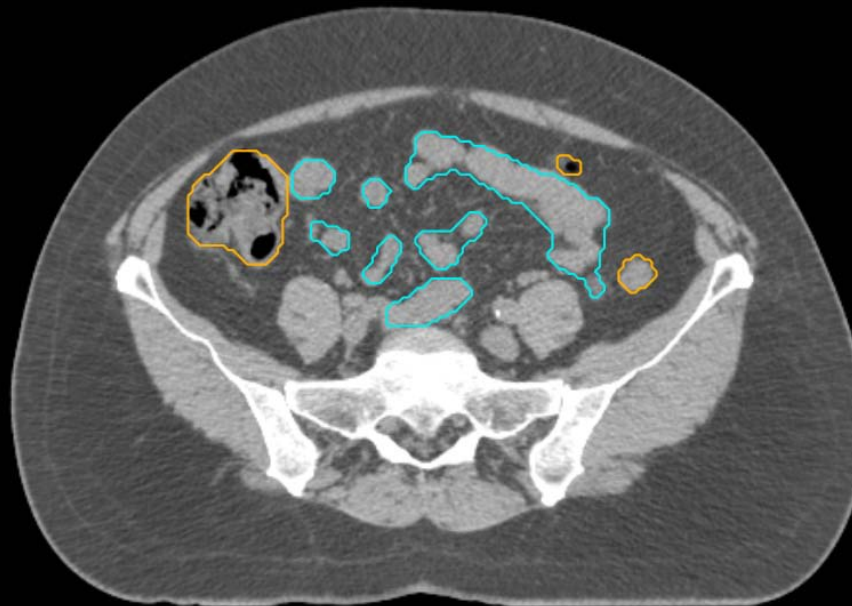
GYN:

- Sigmoid
- AnoRectum
- BowelBag



GYN/GI:

- UteroCervix
- Femur\_L
- Femur\_R
- Adnexa\_R
- Adnexa\_L
- Bladder

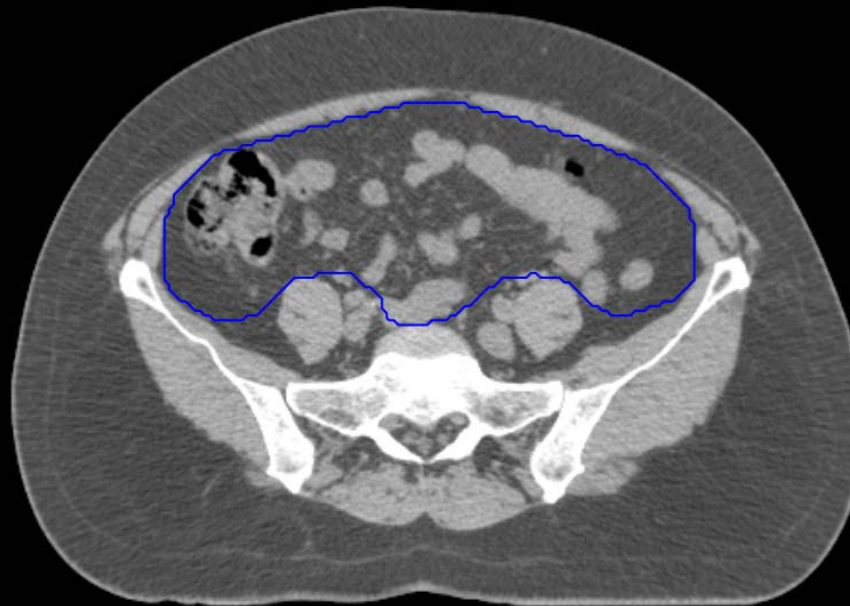

GI:

- Small Bowel
- AnoRectumSig
- Colon

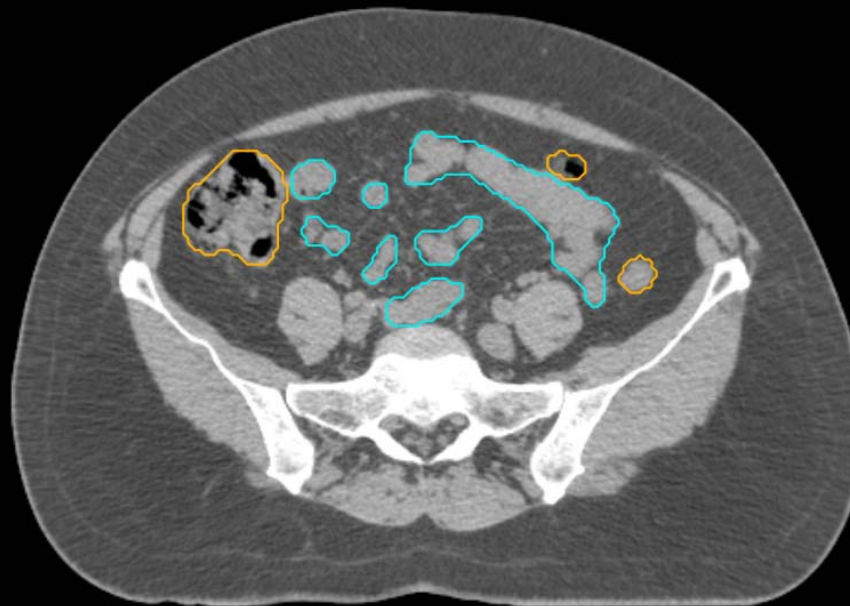
GYN:

- Sigmoid
- AnoRectum
- BowelBag



GYN/GI:

- UteroCervix
- Femur\_L
- Femur\_R
- Adnexa\_R
- Adnexa\_L
- Bladder



GI:

- Small Bowel
- AnoRectumSig
- Colon

GYN:

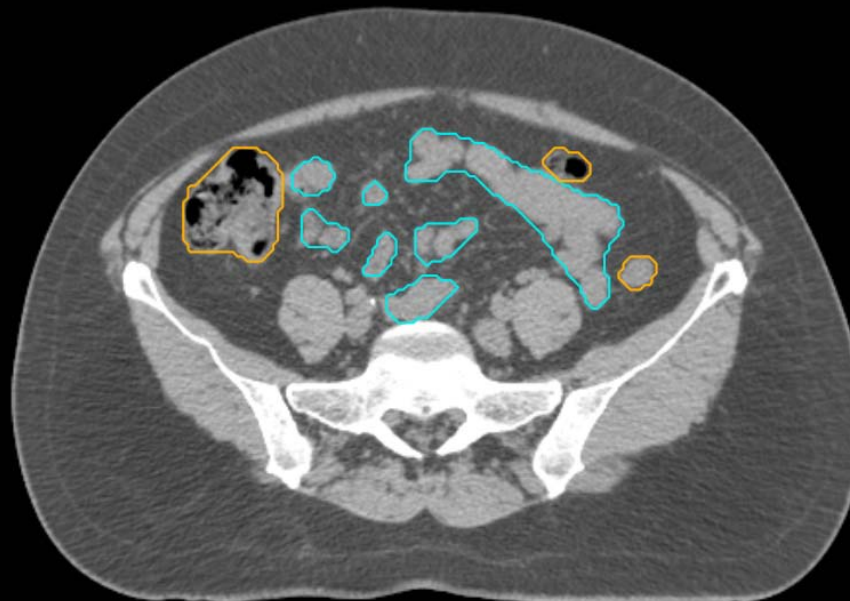
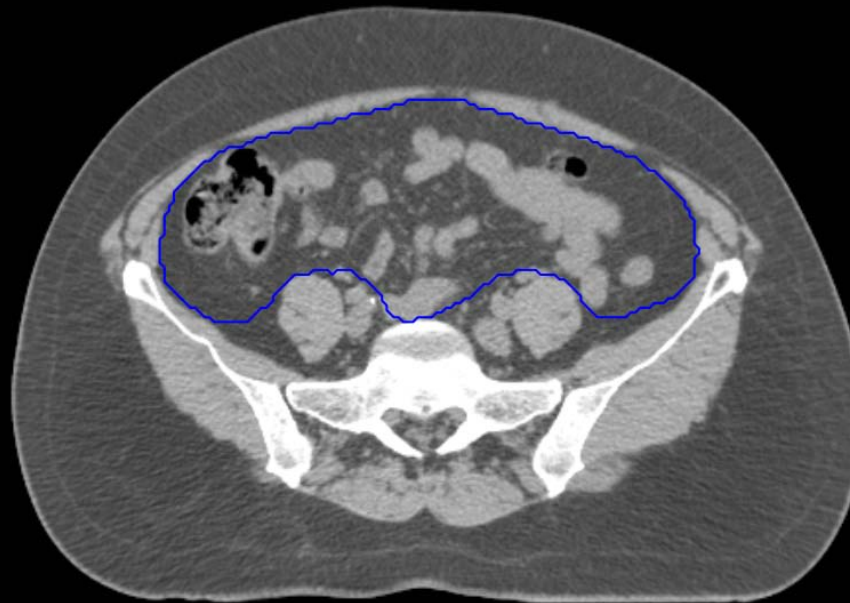
- Sigmoid
- AnoRectum
- BowelBag

GYN/GI:

- UteroCervix
- Femur\_L
- Femur\_R
- Adnexa\_R
- Adnexa\_L
- Bladder

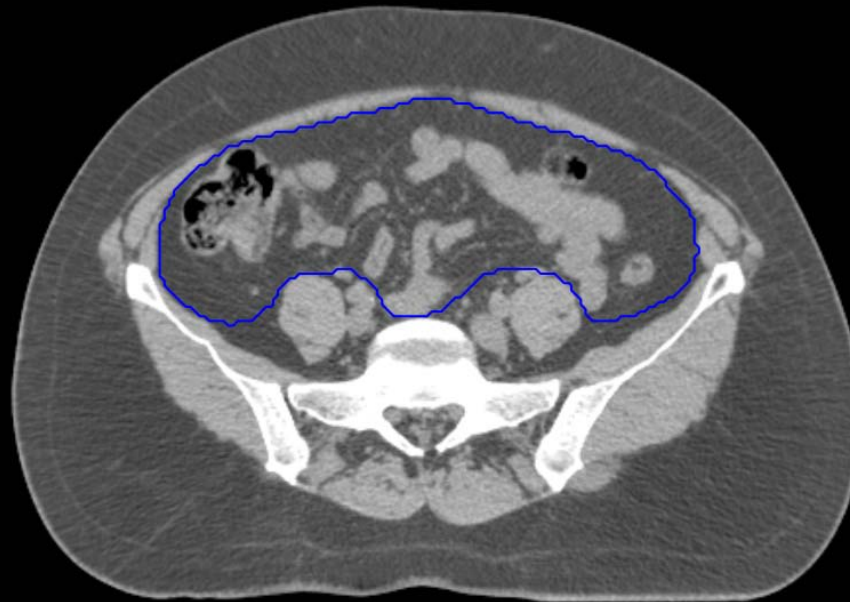
GI:

- Small Bowel
- AnoRectumSig
- Colon



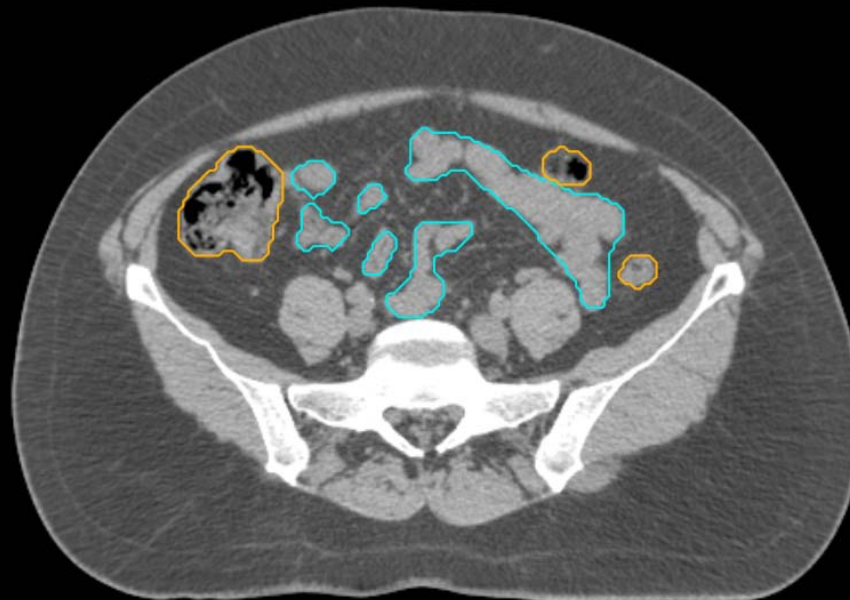GYN:

- Sigmoid
- AnoRectum
- BowelBag



GYN/GI:

- UteroCervix
- Femur\_L
- Femur\_R
- Adnexa\_R
- Adnexa\_L
- Bladder



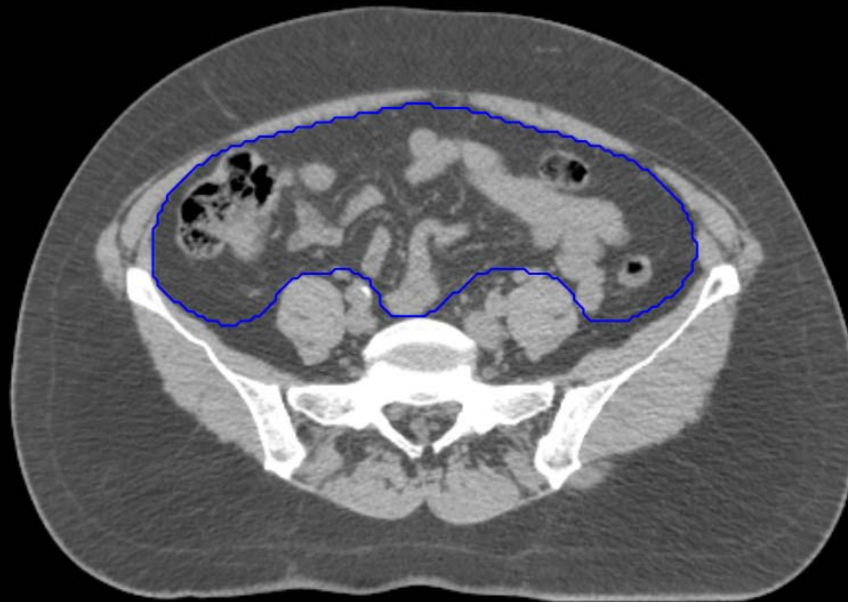
GI:

- Small Bowel
- AnoRectumSig
- Colon



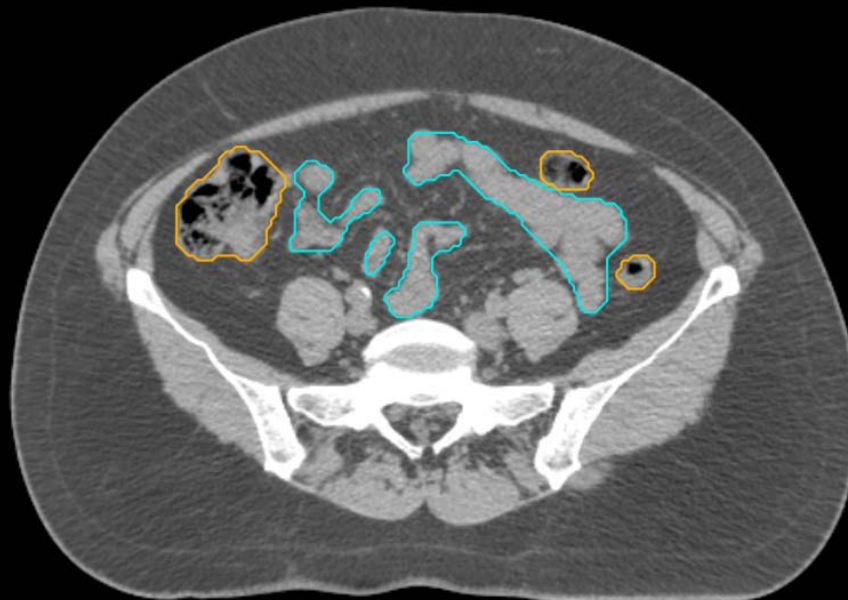
GYN:

- Sigmoid
- AnoRectum
- BowelBag



GYN/GI:

- UteroCervix
- Femur\_L
- Femur\_R
- Adnexa\_R
- Adnexa\_L
- Bladder

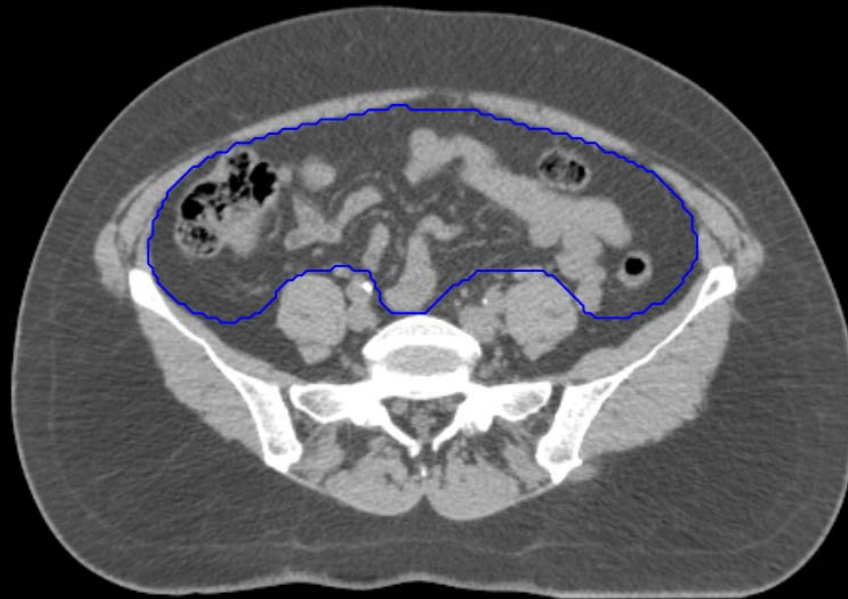


GI:

- Small Bowel
- AnoRectumSig
- Colon

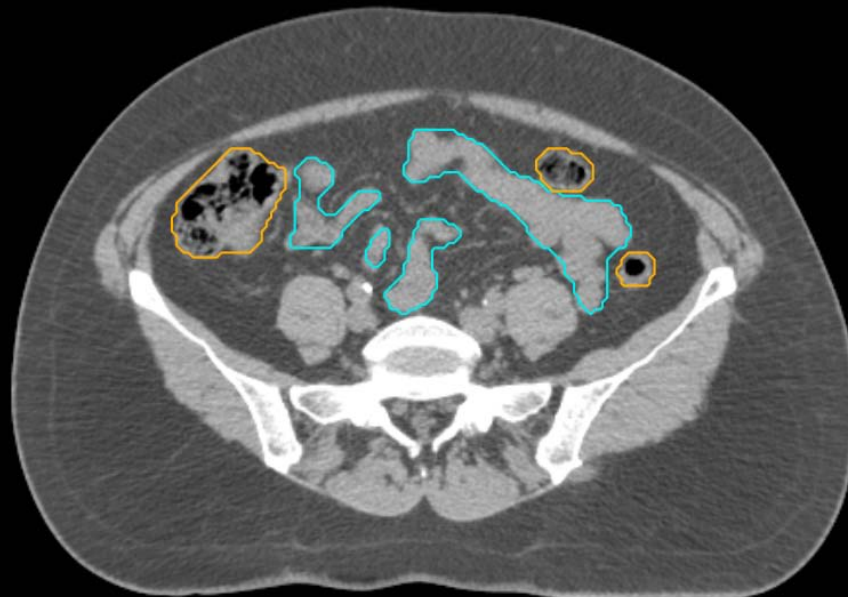
GYN:

- Sigmoid
- AnoRectum
- BowelBag



GYN/GI:

- UteroCervix
- Femur\_L
- Femur\_R
- Adnexa\_R
- Adnexa\_L
- Bladder

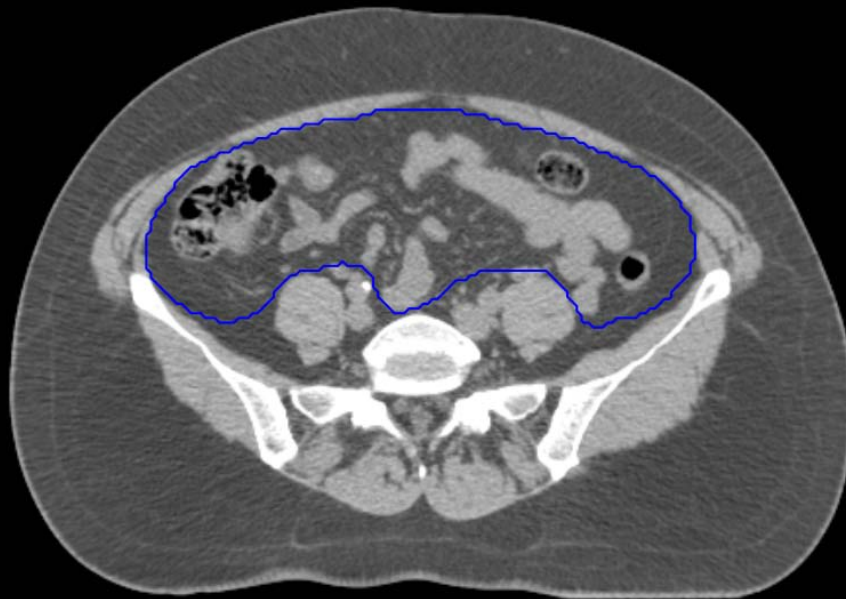


GI:

- Small Bowel
- AnoRectumSig
- Colon

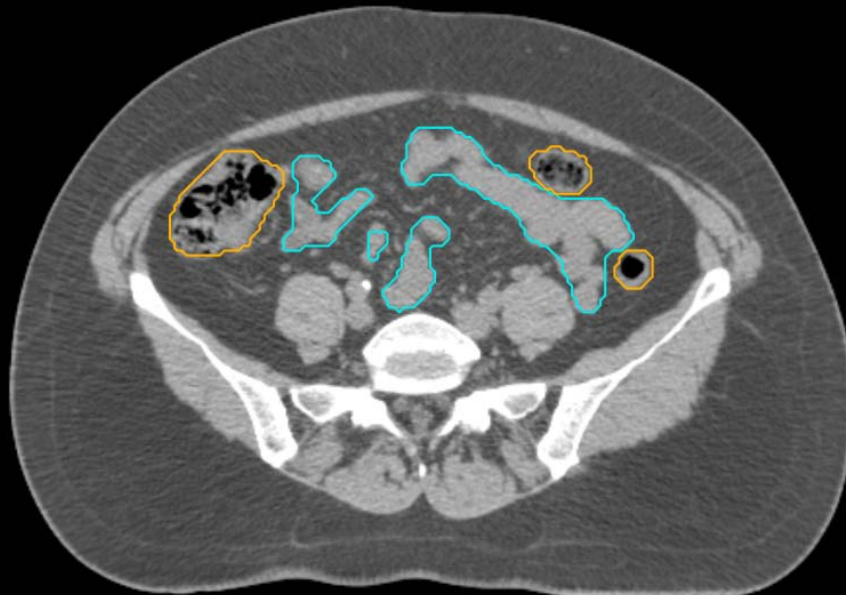
GYN:

- Sigmoid
- AnoRectum
- BowelBag



GYN/GI:

- UteroCervix
- Femur\_L
- Femur\_R
- Adnexa\_R
- Adnexa\_L
- Bladder

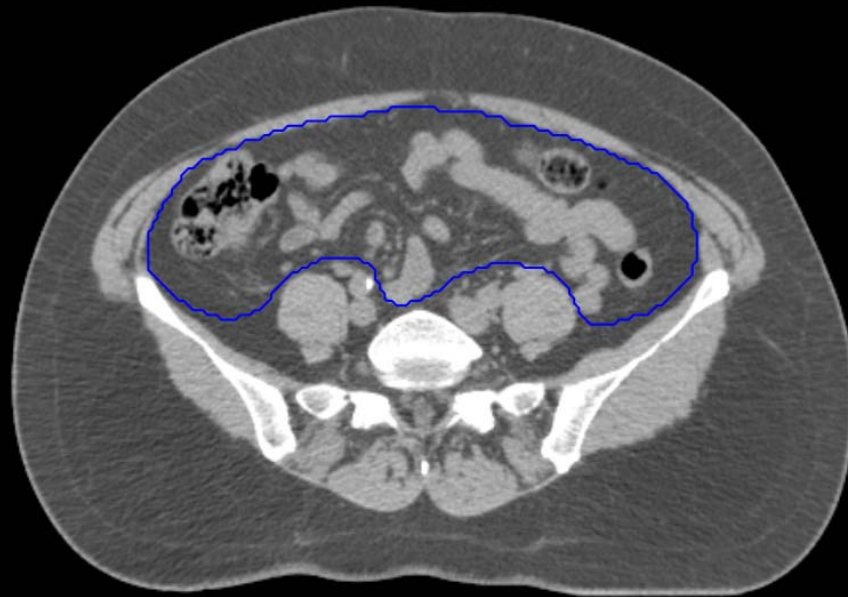


GI:

- Small Bowel
- AnoRectumSig
- Colon

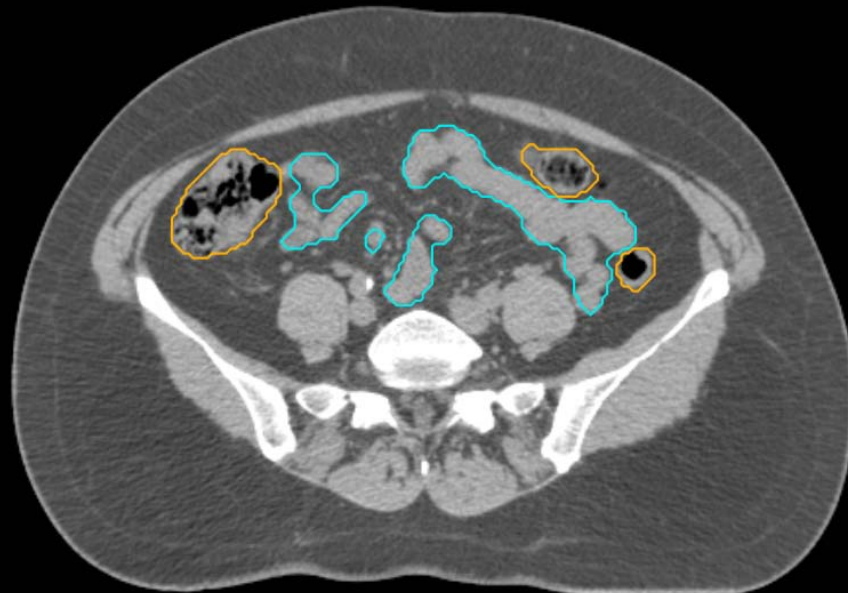
GYN:

- Sigmoid
- AnoRectum
- BowelBag



GYN/GI:

- UteroCervix
- Femur\_L
- Femur\_R
- Adnexa\_R
- Adnexa\_L
- Bladder

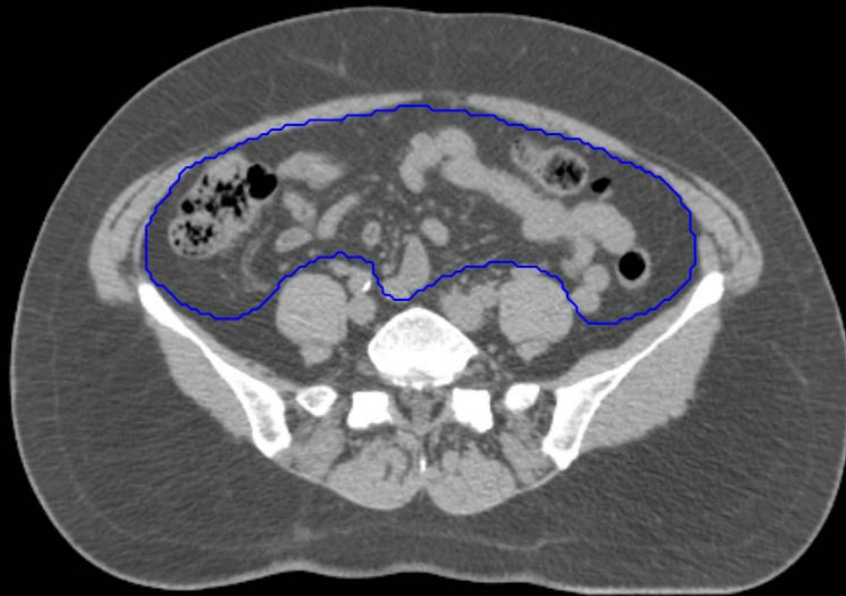

GI:

- Small Bowel
- AnoRectumSig
- Colon

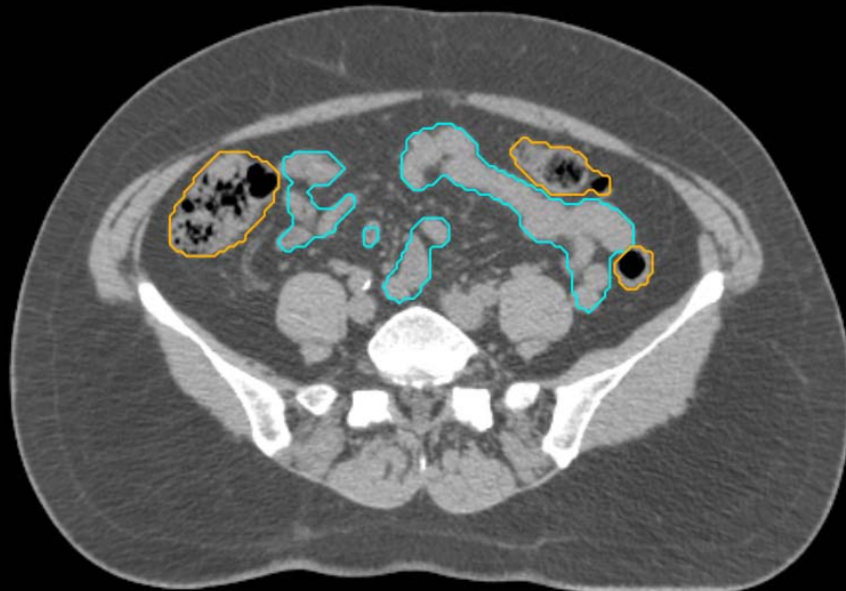
GYN:

- Sigmoid
- AnoRectum
- BowelBag



GYN/GI:

- UteroCervix
- Femur\_L
- Femur\_R
- Adnexa\_R
- Adnexa\_L
- Bladder



GI:

- Small Bowel
- AnoRectumSig
- Colon

GYN:

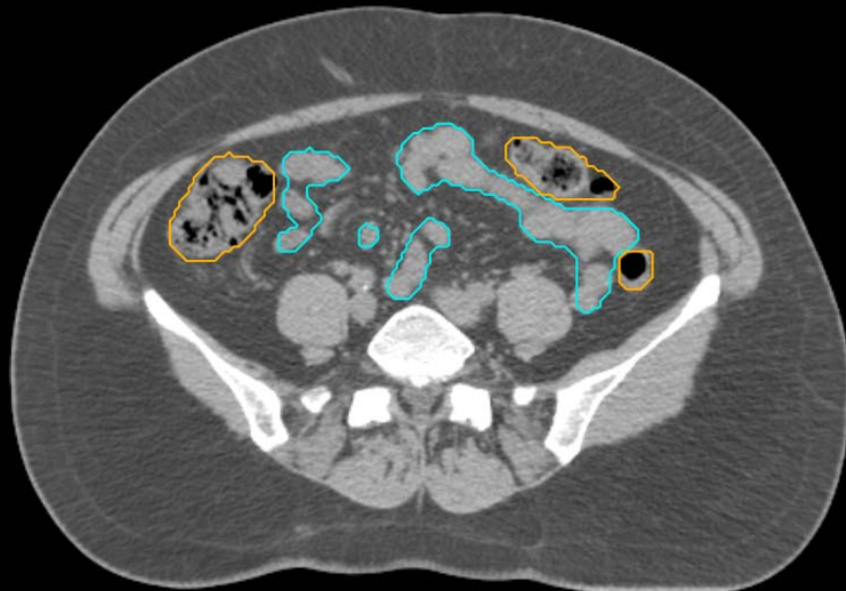
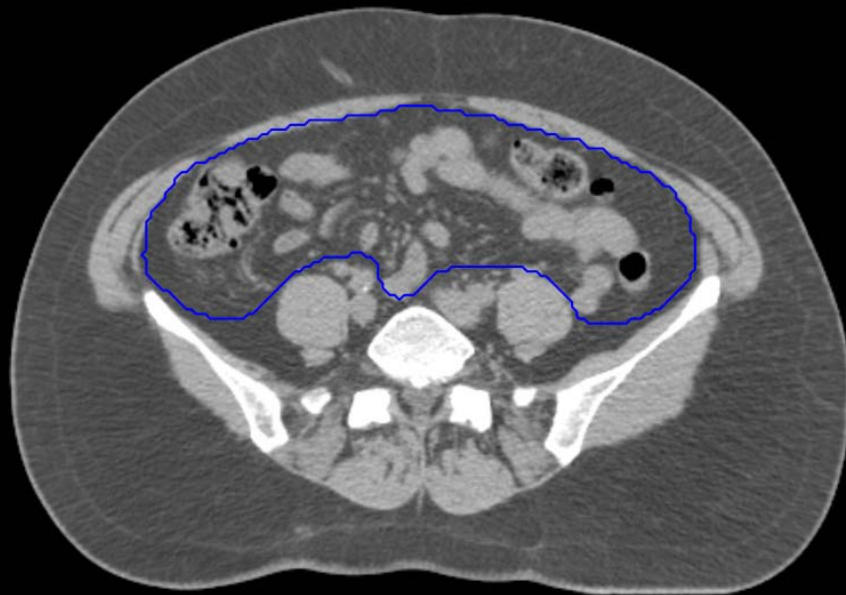
- Sigmoid
- AnoRectum
- BowelBag

GYN/GI:

- UteroCervix
- Femur\_L
- Femur\_R
- Adnexa\_R
- Adnexa\_L
- Bladder

GI:

- Small Bowel
- AnoRectumSig
- Colon



GYN:

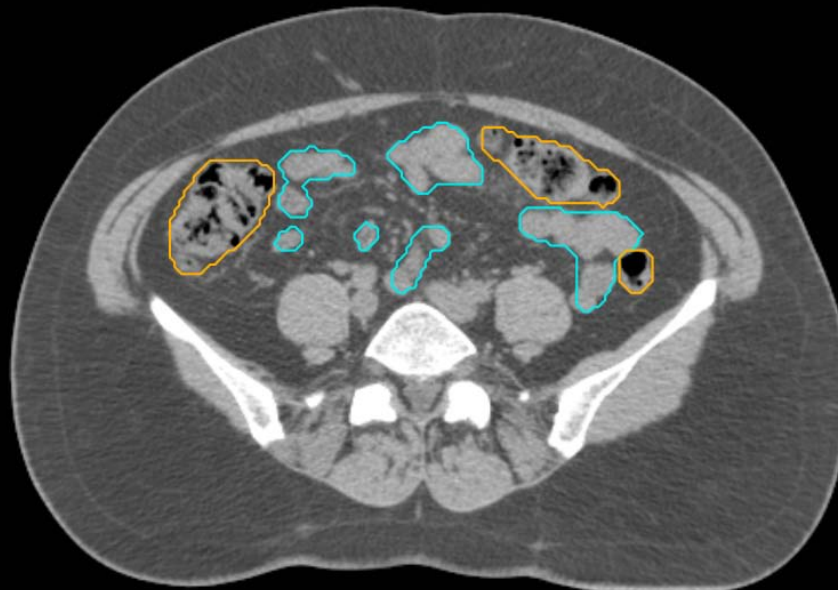
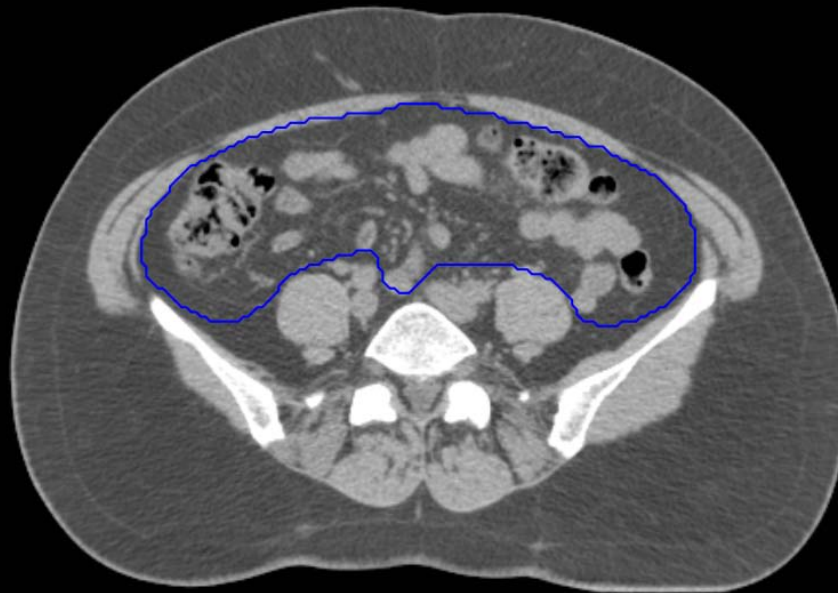
- Sigmoid
- AnoRectum
- BowelBag

GYN/GI:

- UteroCervix
- Femur\_L
- Femur\_R
- Adnexa\_R
- Adnexa\_L
- Bladder

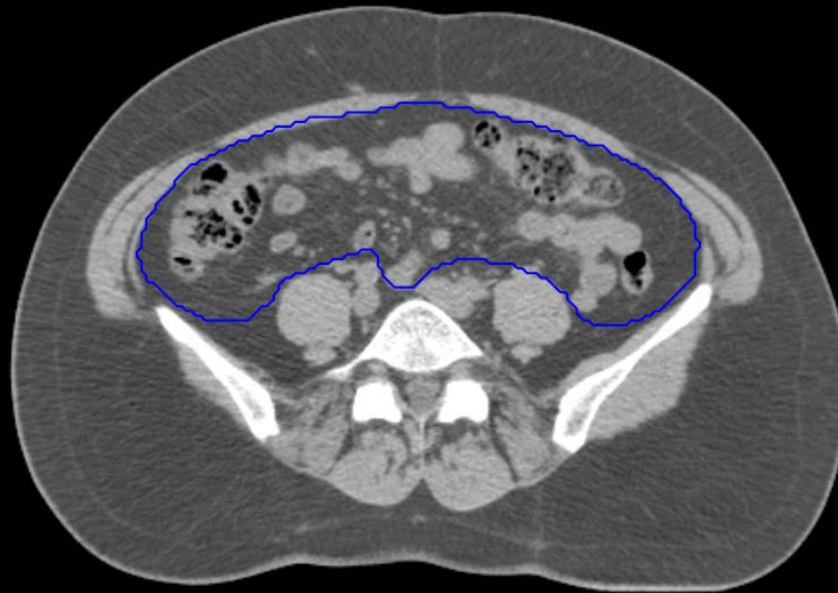
GI:

- Small Bowel
- AnoRectumSig
- Colon



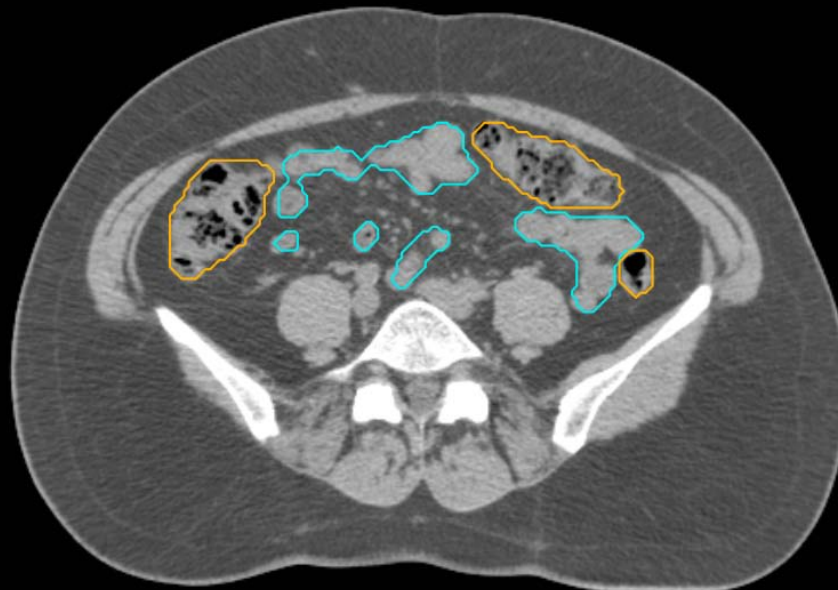
GYN:

- Sigmoid
- AnoRectum
- BowelBag



GYN/GI:

- UteroCervix
- Femur\_L
- Femur\_R
- Adnexa\_R
- Adnexa\_L
- Bladder



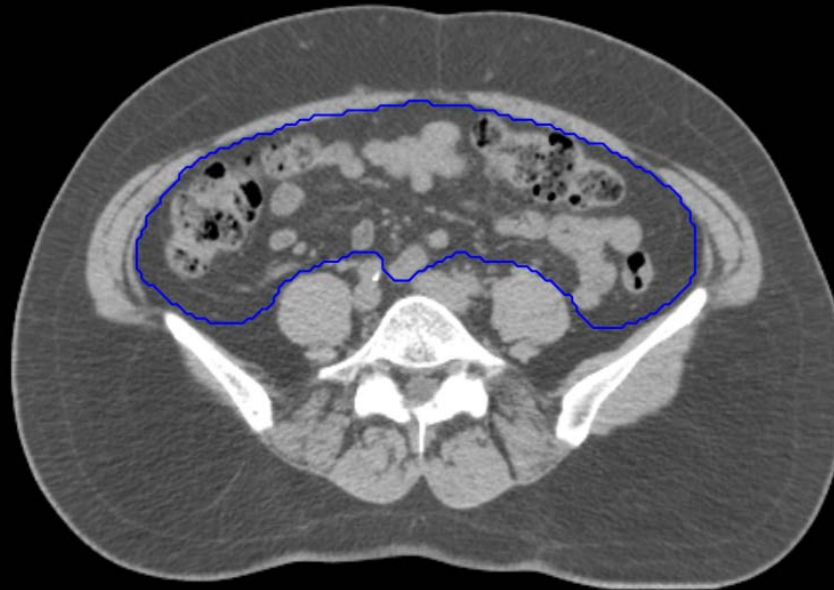GI:

- Small Bowel
- AnoRectumSig
- Colon



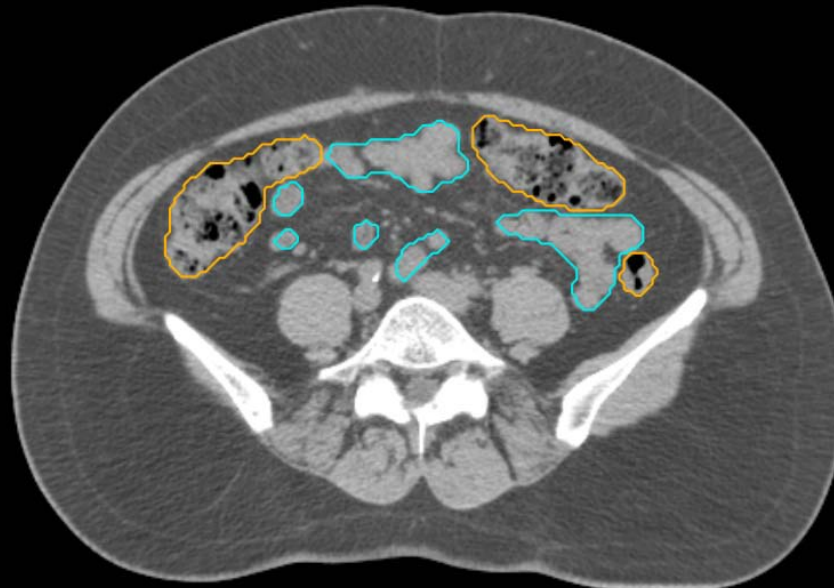GYN:

- Sigmoid
- AnoRectum
- BowelBag



GYN/GI:

- UteroCervix
- Femur\_L
- Femur\_R
- Adnexa\_R
- Adnexa\_L
- Bladder

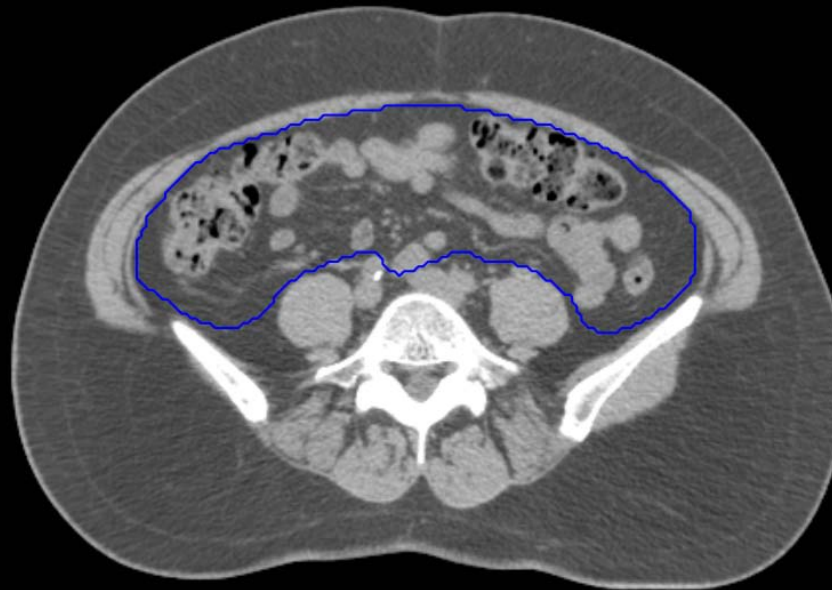


GI:

- Small Bowel
- AnoRectumSig
- Colon

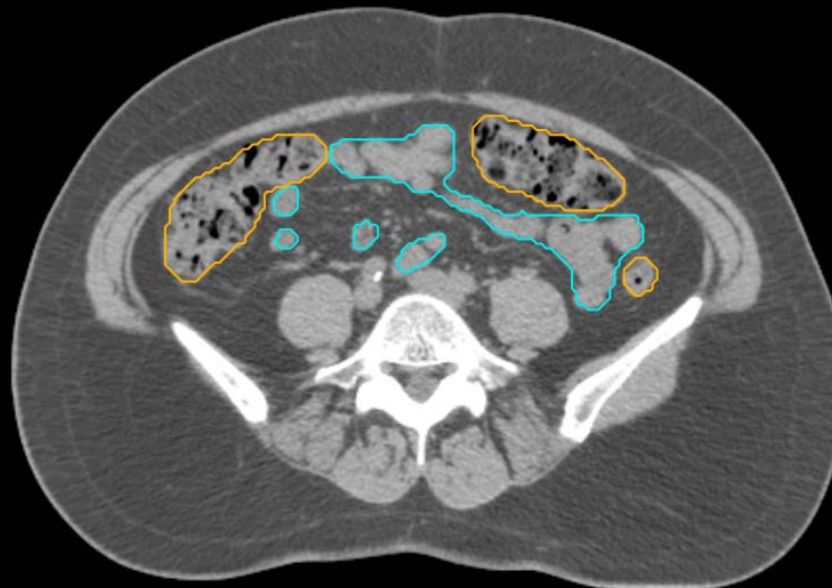GYN:

- Sigmoid
- AnoRectum
- BowelBag



GYN/GI:

- UteroCervix
- Femur\_L
- Femur\_R
- Adnexa\_R
- Adnexa\_L
- Bladder

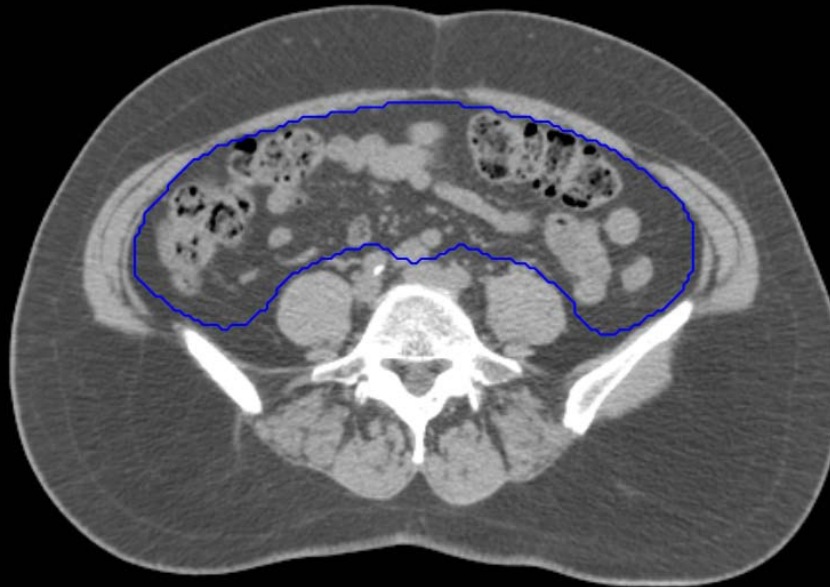


GI:

- Small Bowel
- AnoRectumSig
- Colon

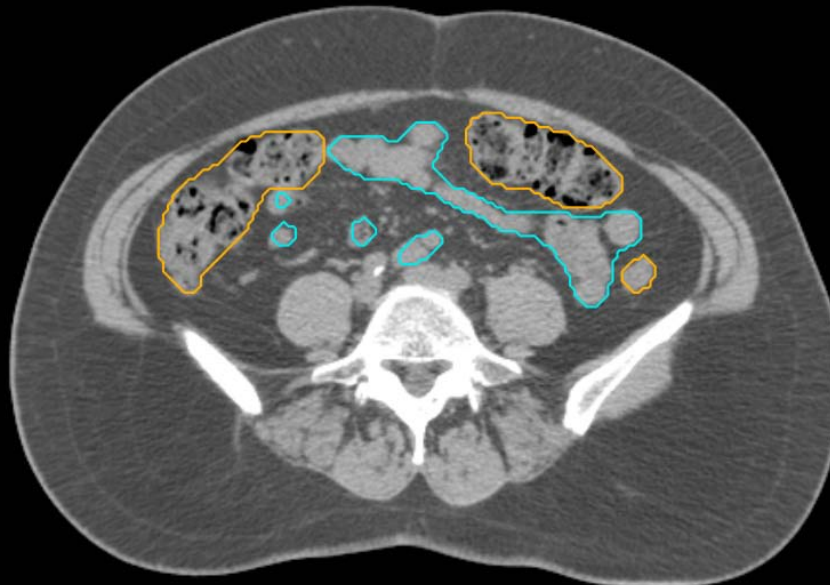GYN:

- Sigmoid
- AnoRectum
- BowelBag



GYN/GI:

- UteroCervix
- Femur\_L
- Femur\_R
- Adnexa\_R
- Adnexa\_L
- Bladder



GI:

- Small Bowel
- AnoRectumSig
- Colon

GYN:

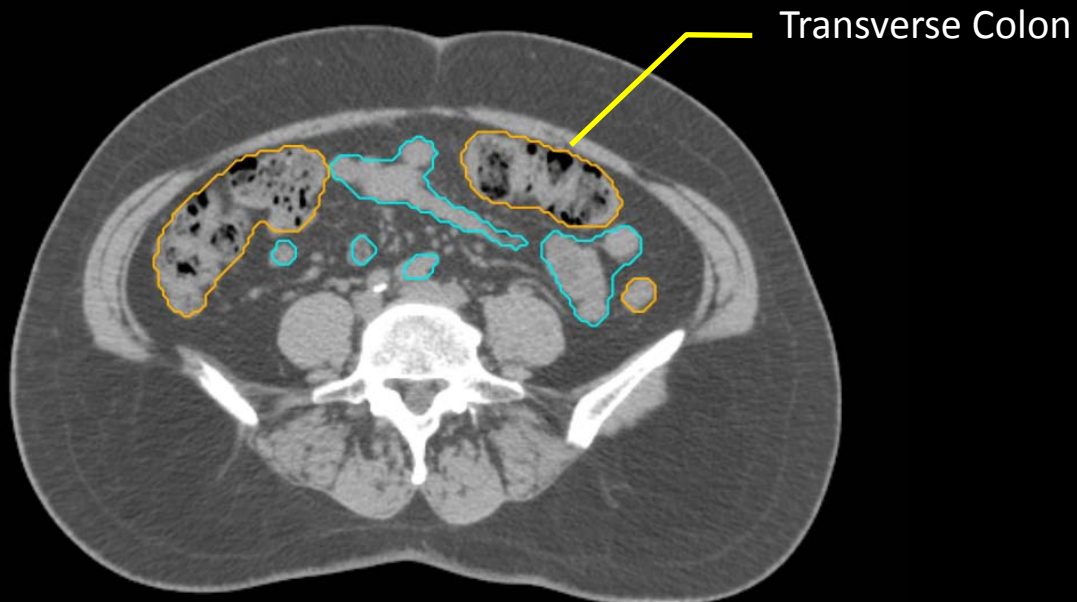
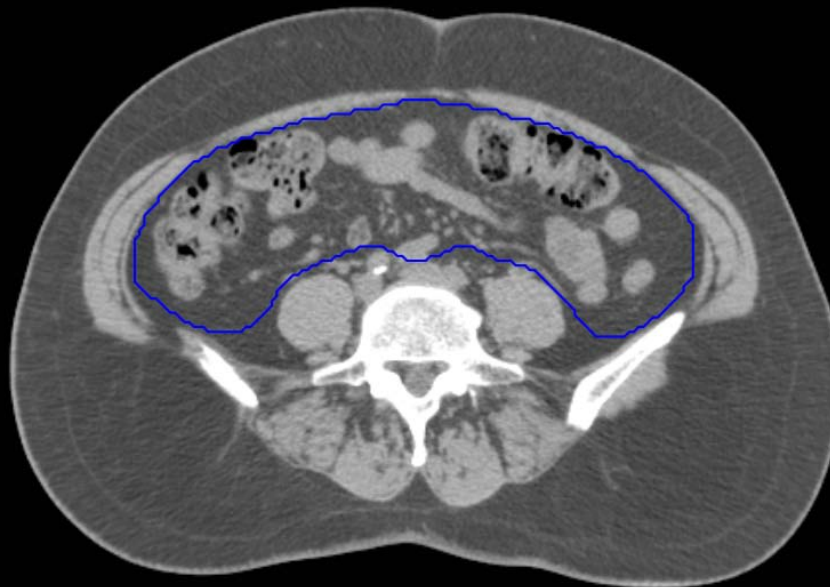- Sigmoid
- AnoRectum
- BowelBag

GYN/GI:

- UteroCervix
- Femur\_L
- Femur\_R
- Adnexa\_R
- Adnexa\_L
- Bladder

GI:

- Small Bowel
- AnoRectumSig
- Colon



GYN:

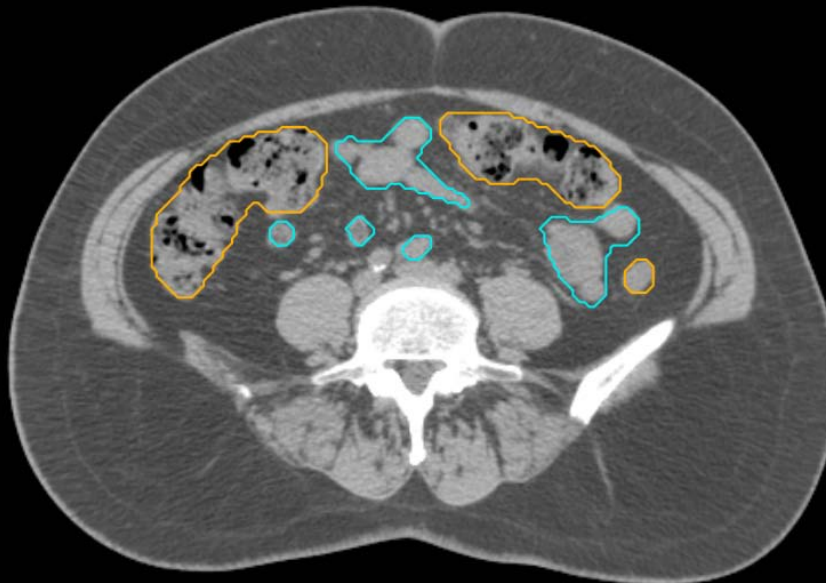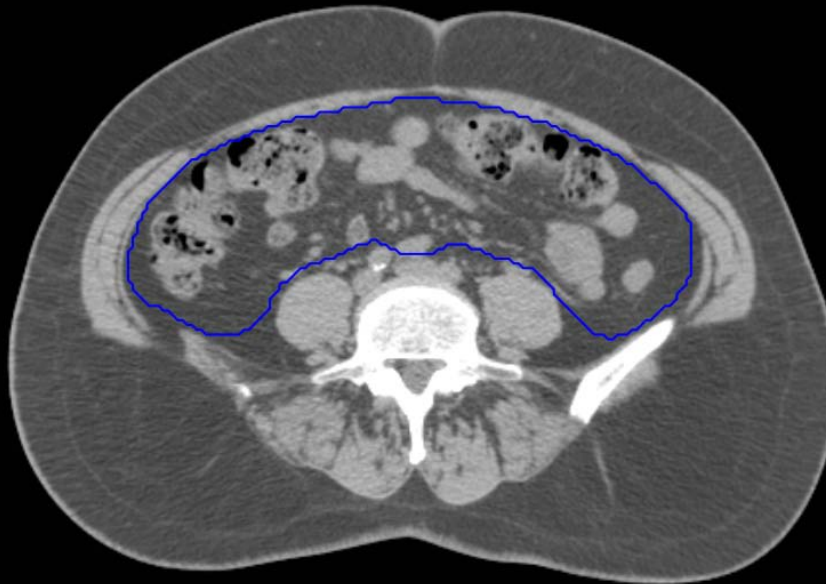- Sigmoid
- AnoRectum
- BowelBag

GYN/GI:

- UteroCervix
- Femur\_L
- Femur\_R
- Adnexa\_R
- Adnexa\_L
- Bladder

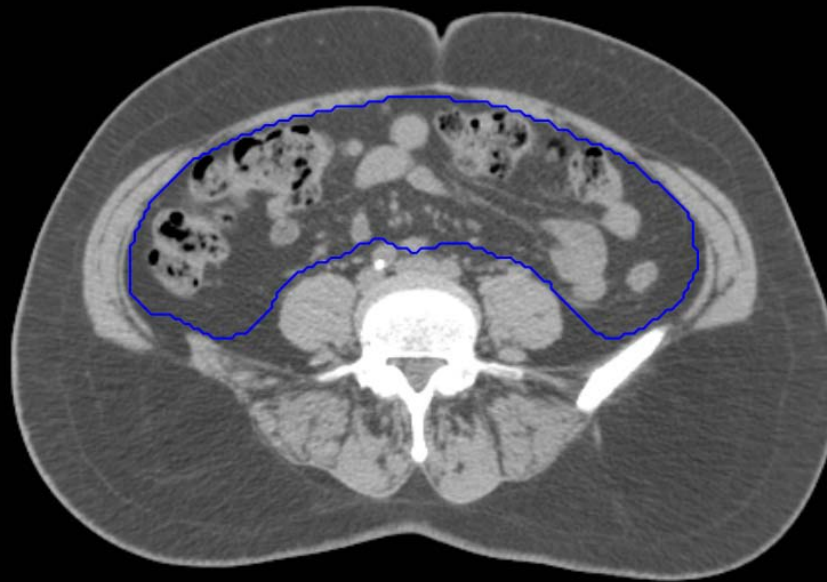GI:

- Small Bowel
- AnoRectumSig
- Colon



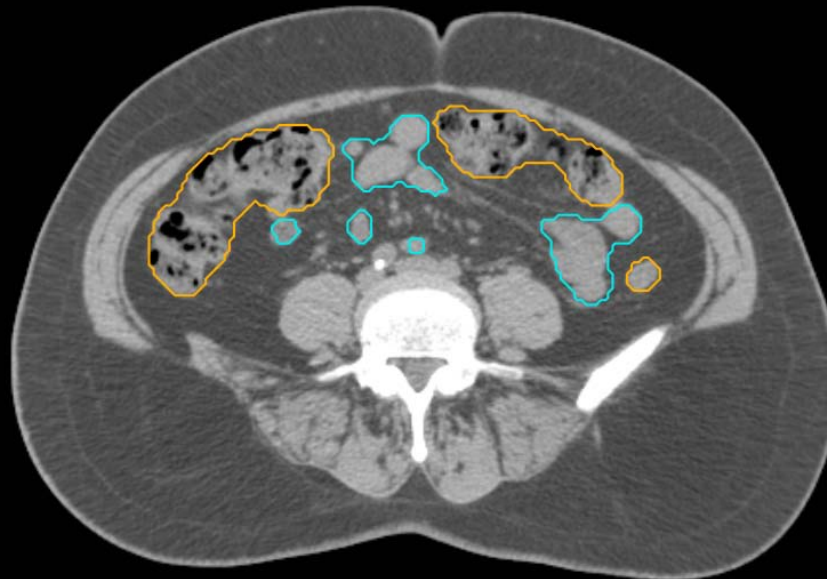GYN:

- Sigmoid
- AnoRectum
- BowelBag



GYN/GI:

- UteroCervix
- Femur\_L
- Femur\_R
- Adnexa\_R
- Adnexa\_L
- Bladder

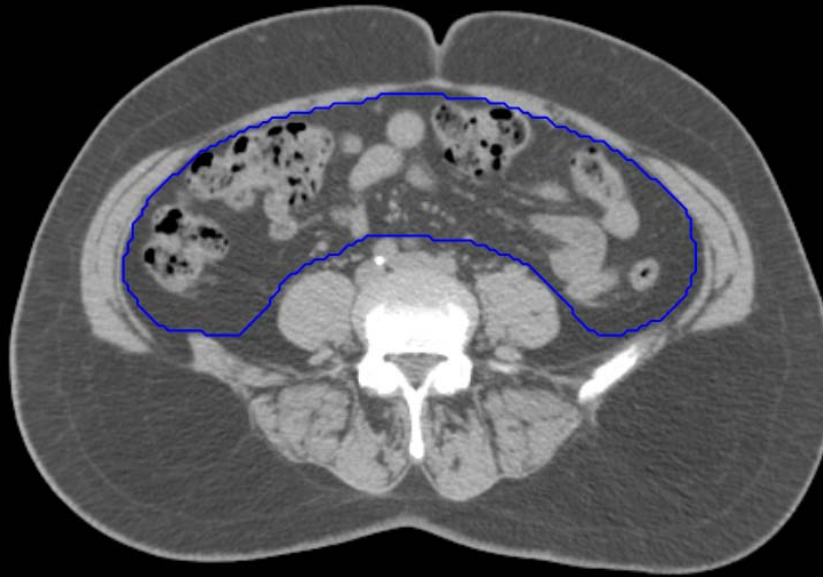

GI:

- Small Bowel
- AnoRectumSig
- Colon

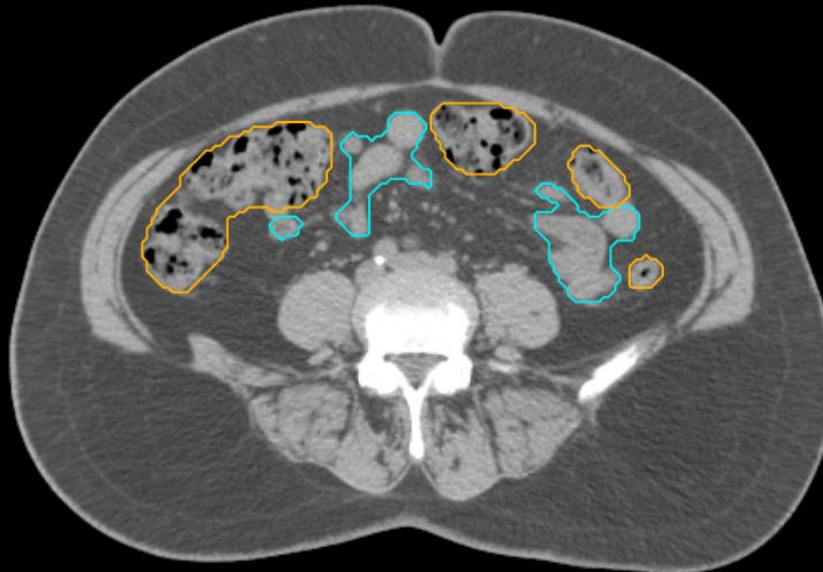GYN:

- Sigmoid
- AnoRectum
- BowelBag



GYN/GI:

- UteroCervix
- Femur\_L
- Femur\_R
- Adnexa\_R
- Adnexa\_L
- Bladder



GI:

- Small Bowel
- AnoRectumSig
- Colon

GYN:

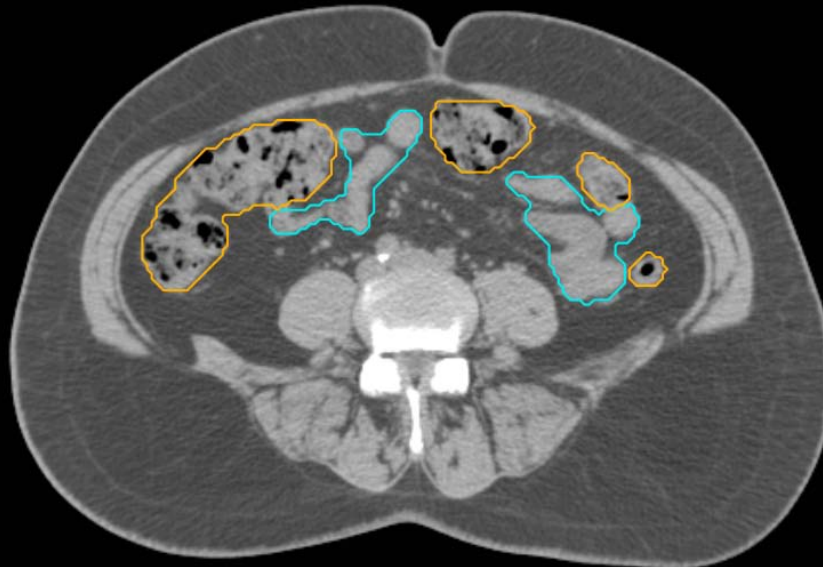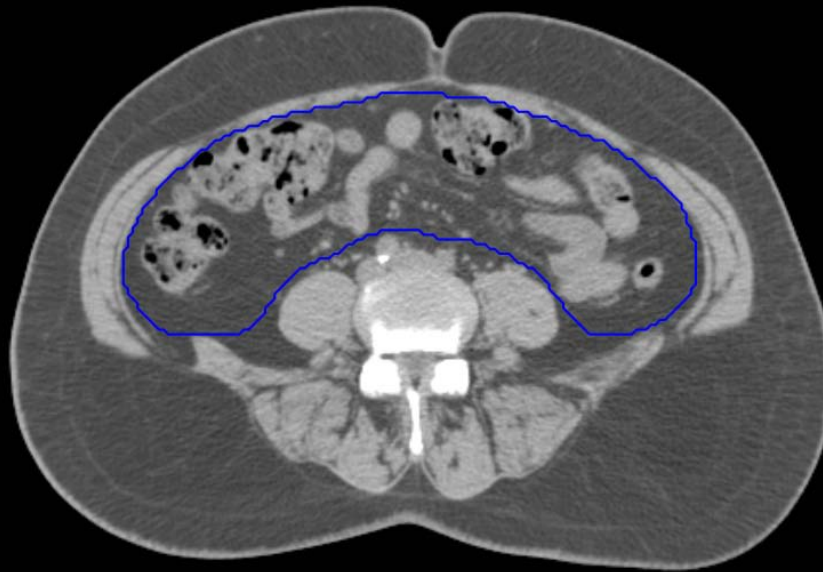
- Sigmoid
- AnoRectum
- BowelBag

GYN/GI:

- UteroCervix
- Femur\_L
- Femur\_R
- Adnexa\_R
- Adnexa\_L
- Bladder

GI:

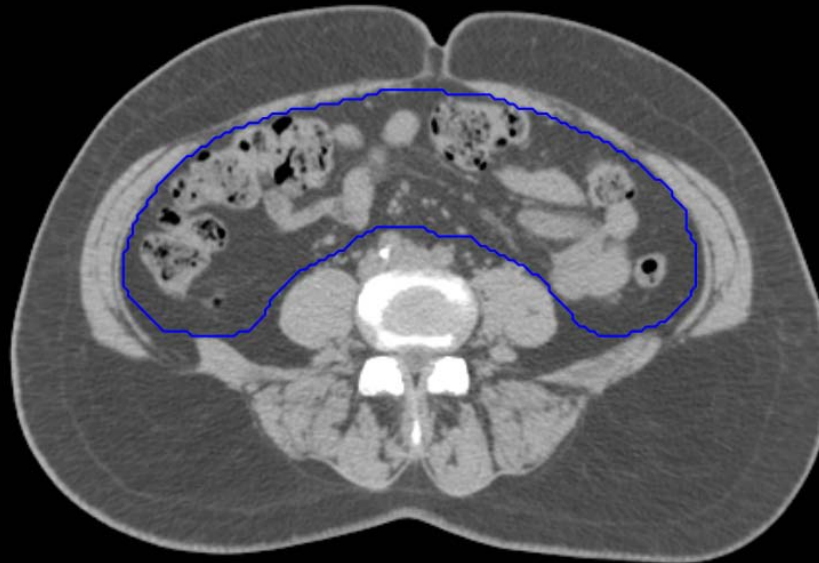
- Small Bowel
- AnoRectumSig
- Colon





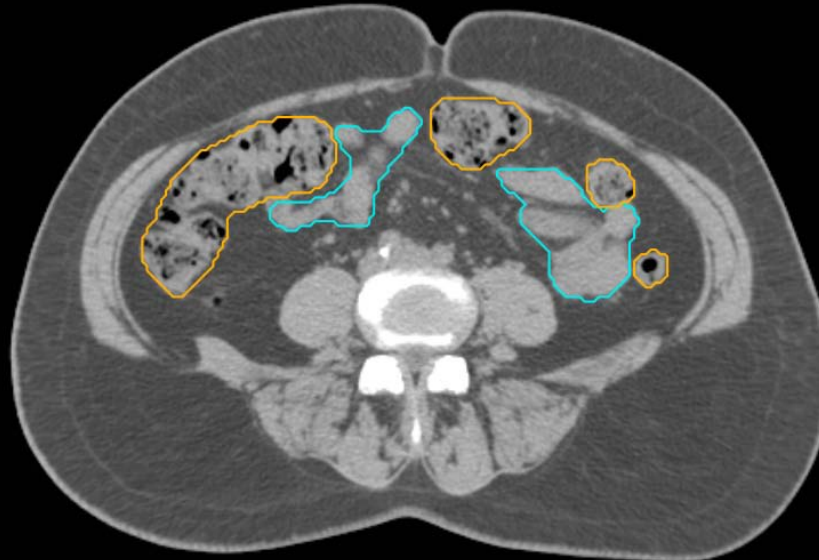
GYN:

- Sigmoid
- AnoRectum
- BowelBag



GYN/GI:

- UteroCervix
- Femur\_L
- Femur\_R
- Adnexa\_R
- Adnexa\_L
- Bladder

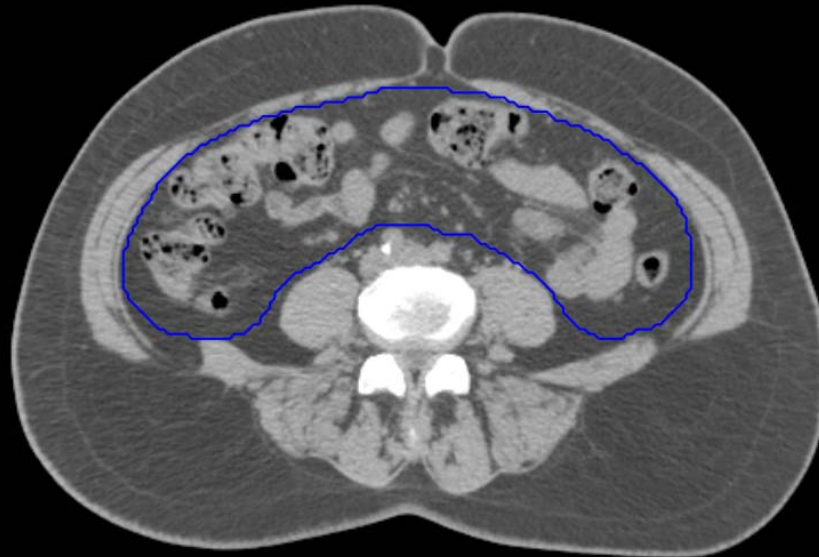


GI:

- Small Bowel
- AnoRectumSig
- Colon

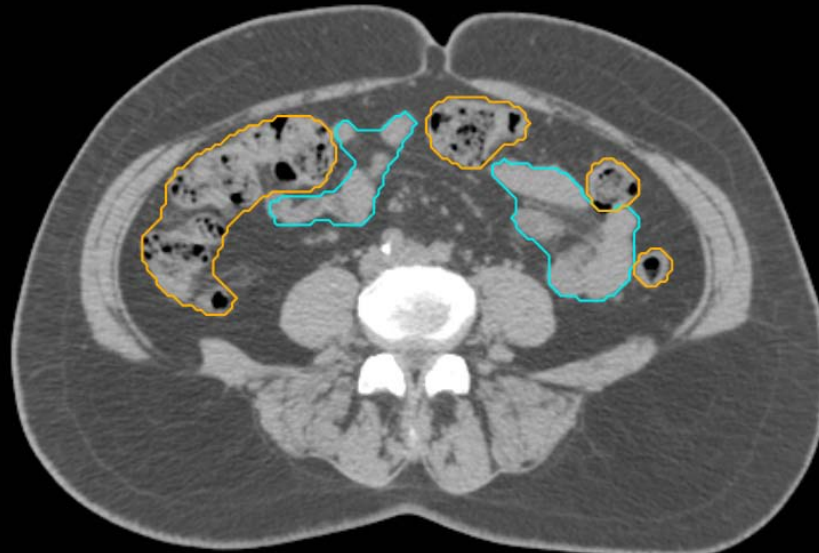
GYN:

- Sigmoid
- AnoRectum
- BowelBag



GYN/GI:

- UteroCervix
- Femur\_L
- Femur\_R
- Adnexa\_R
- Adnexa\_L
- Bladder

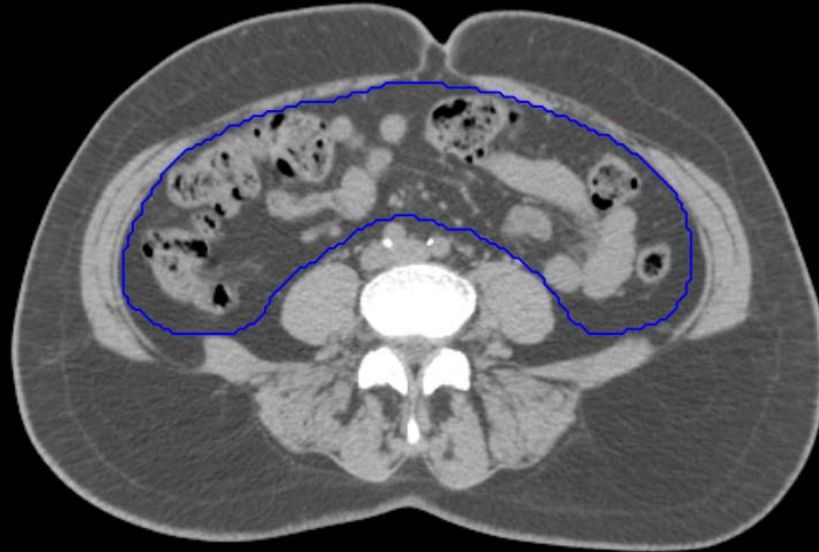


GI:

- Small Bowel
- AnoRectumSig
- Colon

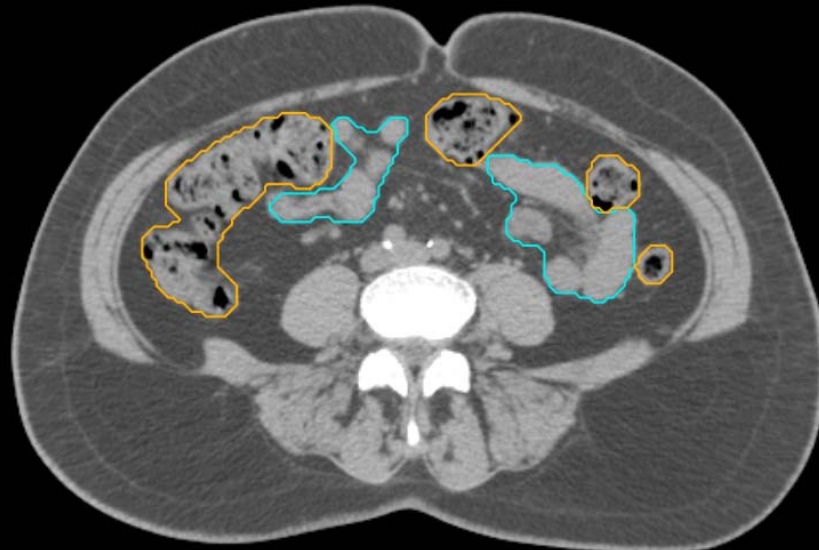GYN:

- Sigmoid
- AnoRectum
- BowelBag



GYN/GI:

- UteroCervix
- Femur\_L
- Femur\_R
- Adnexa\_R
- Adnexa\_L
- Bladder

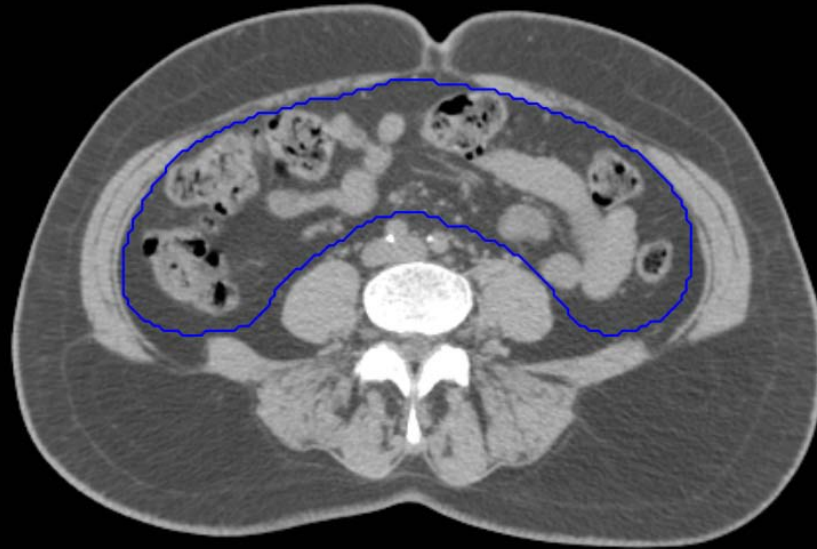

GI:

- Small Bowel
- AnoRectumSig
- Colon

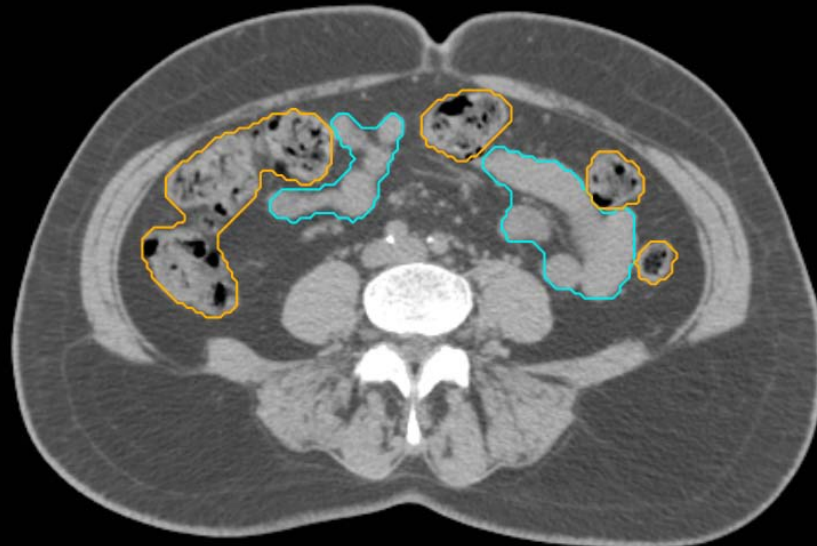
GYN:

- Sigmoid
- AnoRectum
- BowelBag



GYN/GI:

- UteroCervix
- Femur\_L
- Femur\_R
- Adnexa\_R
- Adnexa\_L
- Bladder

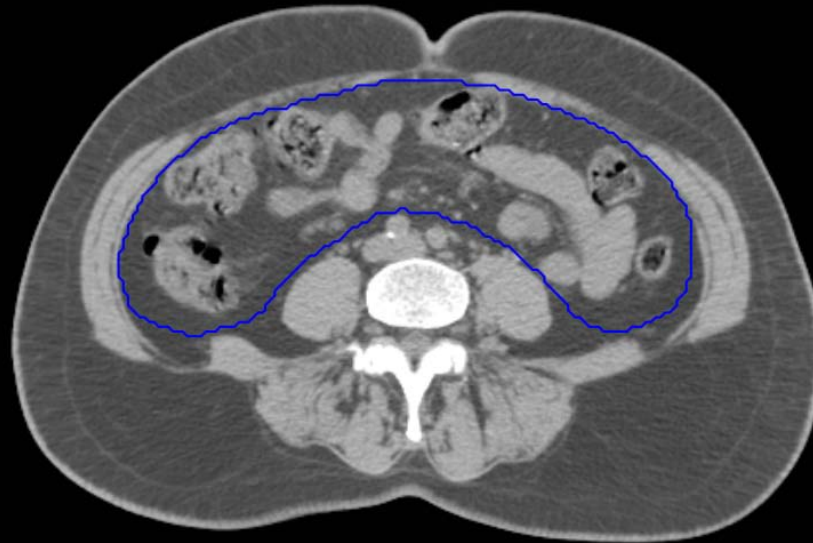

GI:

- Small Bowel
- AnoRectumSig
- Colon

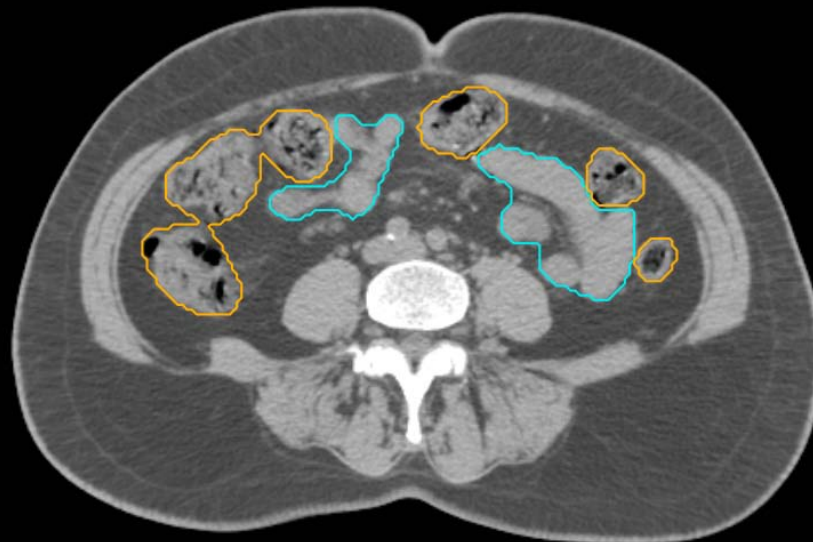GYN:

- Sigmoid
- AnoRectum
- BowelBag



GYN/GI:

- UteroCervix
- Femur\_L
- Femur\_R
- Adnexa\_R
- Adnexa\_L
- Bladder

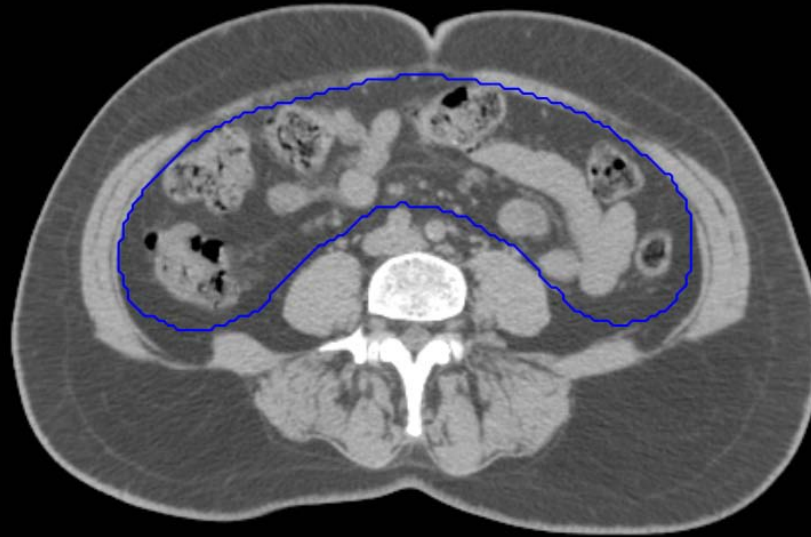


GI:

- Small Bowel
- AnoRectumSig
- Colon

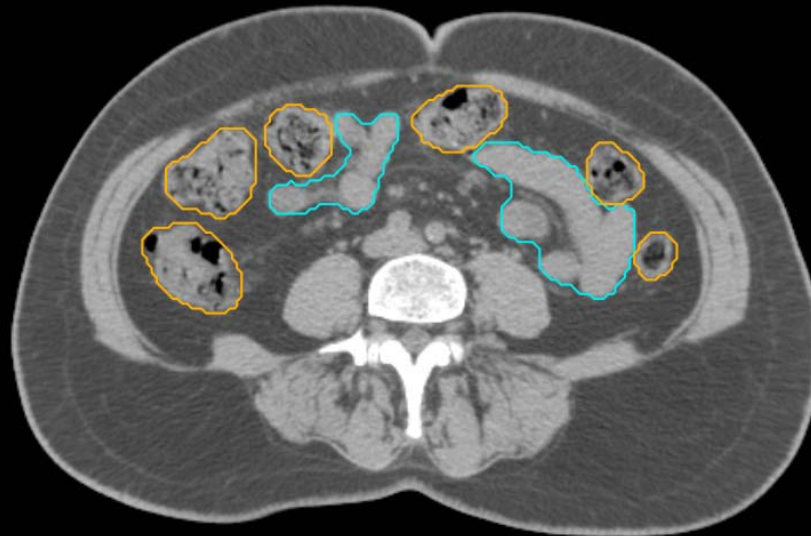
GYN:

- Sigmoid
- AnoRectum
- BowelBag



GYN/GI:

- UteroCervix
- Femur\_L
- Femur\_R
- Adnexa\_R
- Adnexa\_L
- Bladder

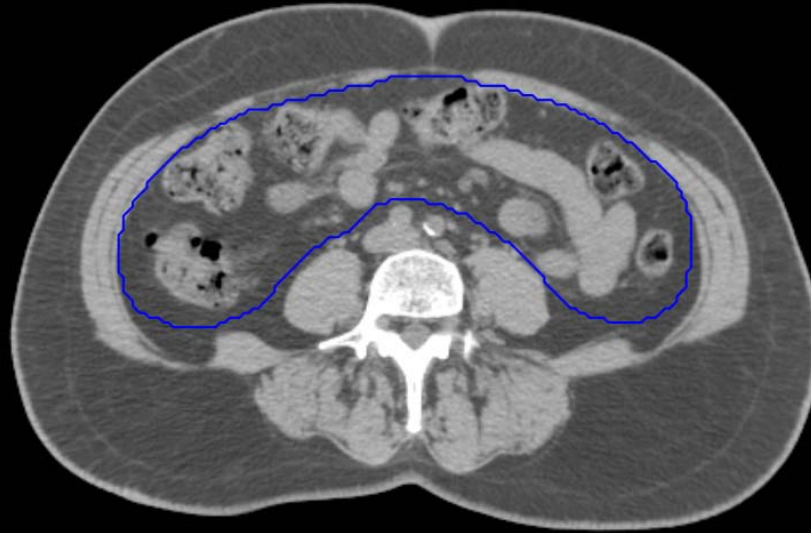

GI:

- Small Bowel
- AnoRectumSig
- Colon

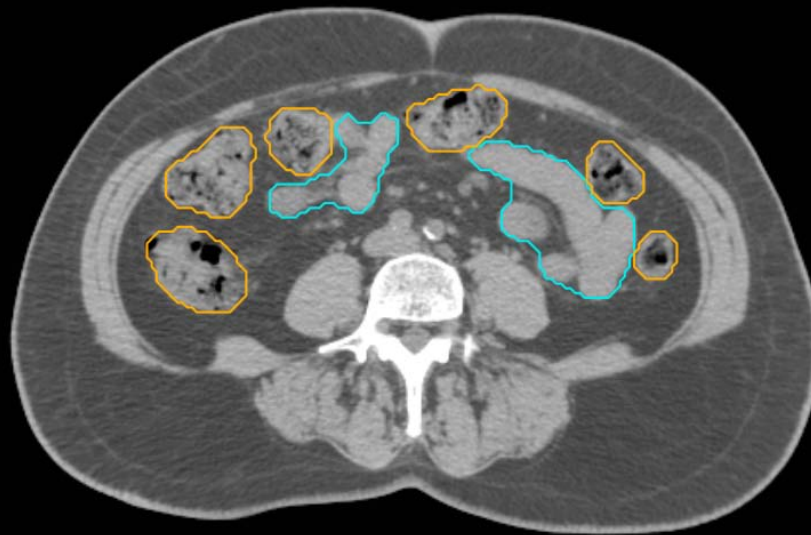GYN:

- Sigmoid
- AnoRectum
- BowelBag



GYN/GI:

- UteroCervix
- Femur\_L
- Femur\_R
- Adnexa\_R
- Adnexa\_L
- Bladder

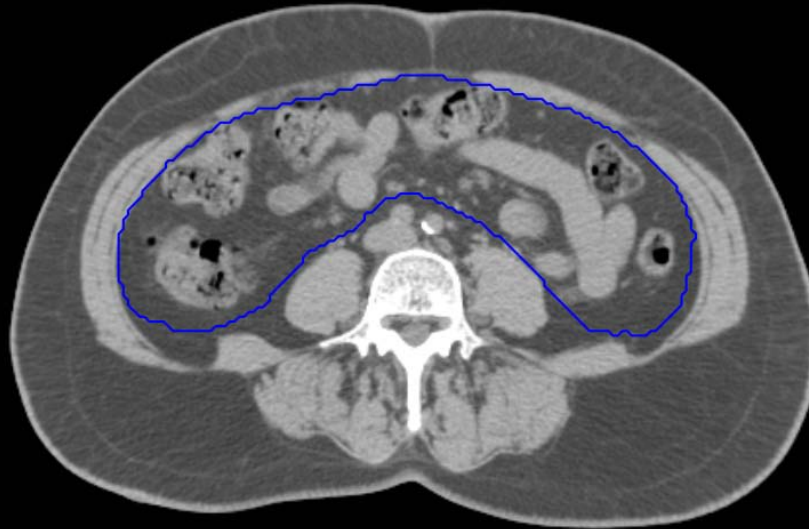

GI:

- Small Bowel
- AnoRectumSig
- Colon

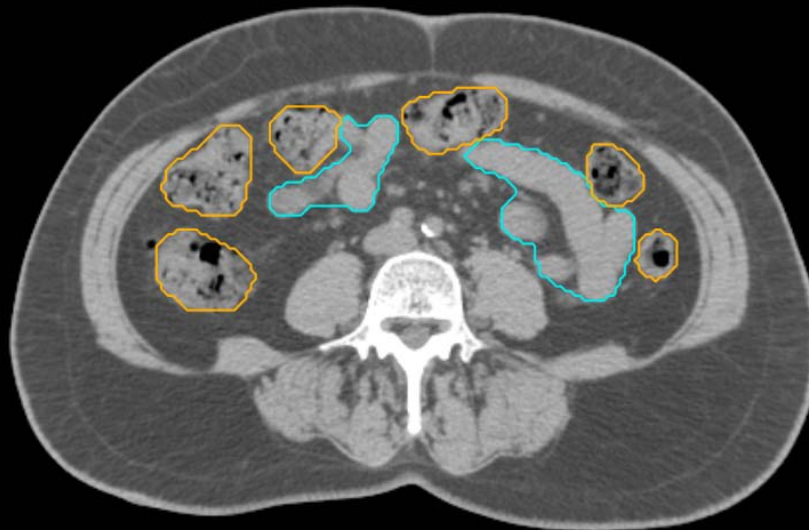GYN:

- Sigmoid
- AnoRectum
- BowelBag



GYN/GI:

- UteroCervix
- Femur\_L
- Femur\_R
- Adnexa\_R
- Adnexa\_L
- Bladder



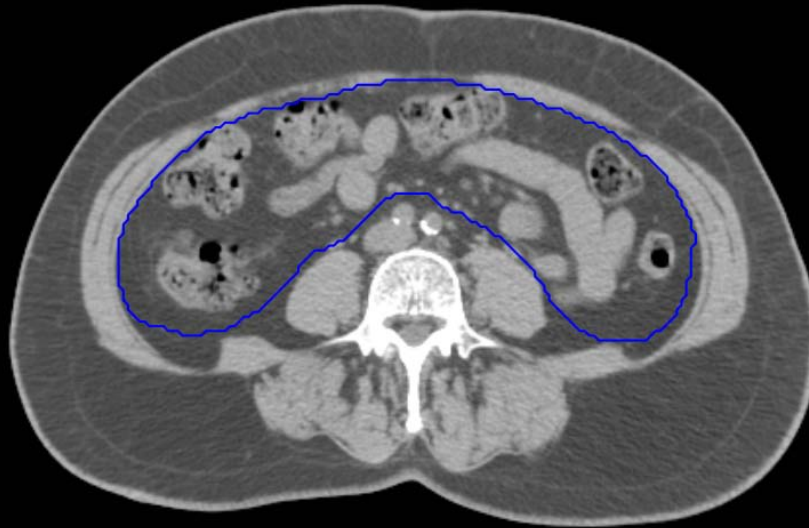GI:

- Small Bowel
- AnoRectumSig
- Colon



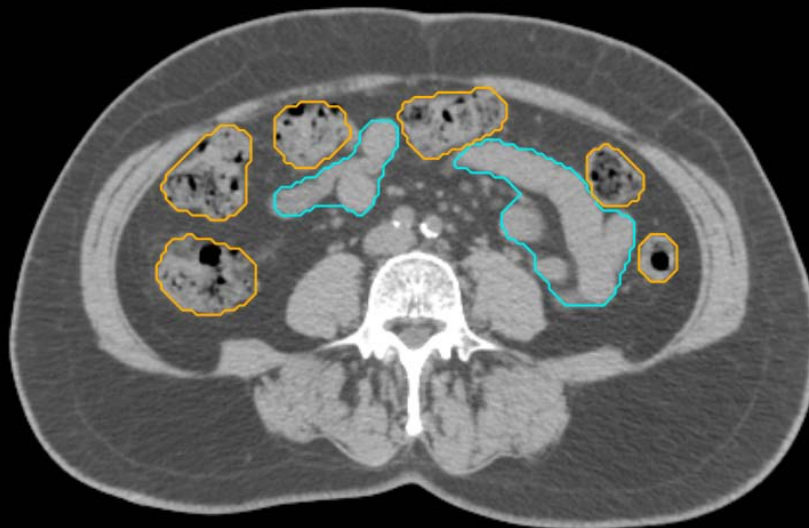GYN:

- Sigmoid
- AnoRectum
- BowelBag



GYN/GI:

- UteroCervix
- Femur\_L
- Femur\_R
- Adnexa\_R
- Adnexa\_L
- Bladder

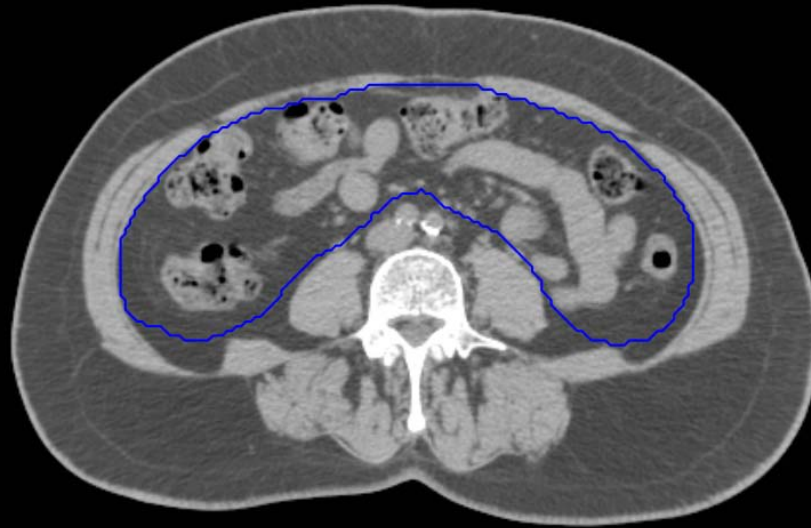


GI:

- Small Bowel
- AnoRectumSig
- Colon

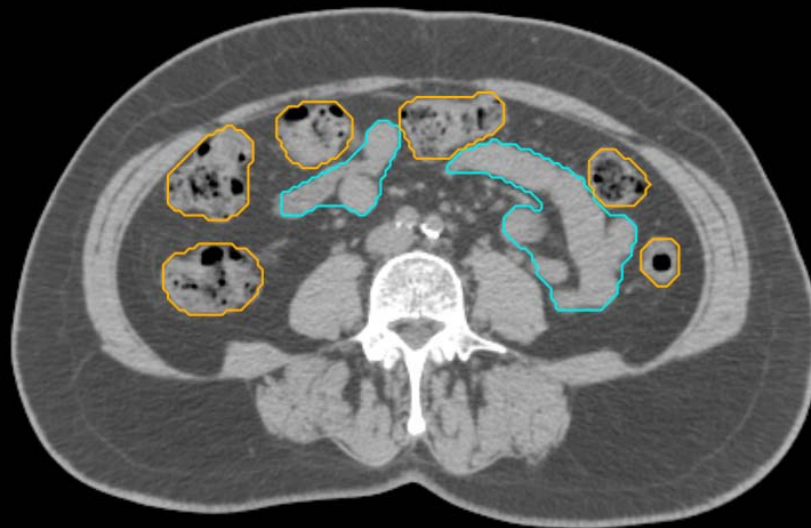GYN:

- Sigmoid
- AnoRectum
- BowelBag



GYN/GI:

- UteroCervix
- Femur\_L
- Femur\_R
- Adnexa\_R
- Adnexa\_L
- Bladder

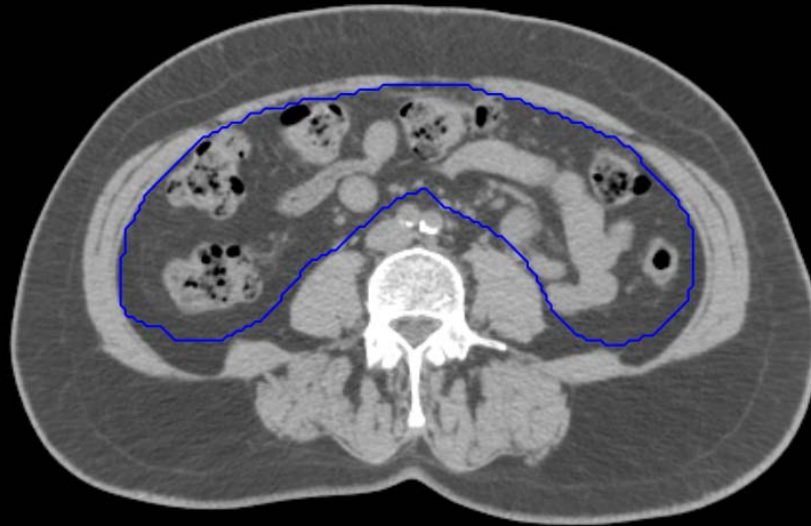


GI:

- Small Bowel
- AnoRectumSig
- Colon

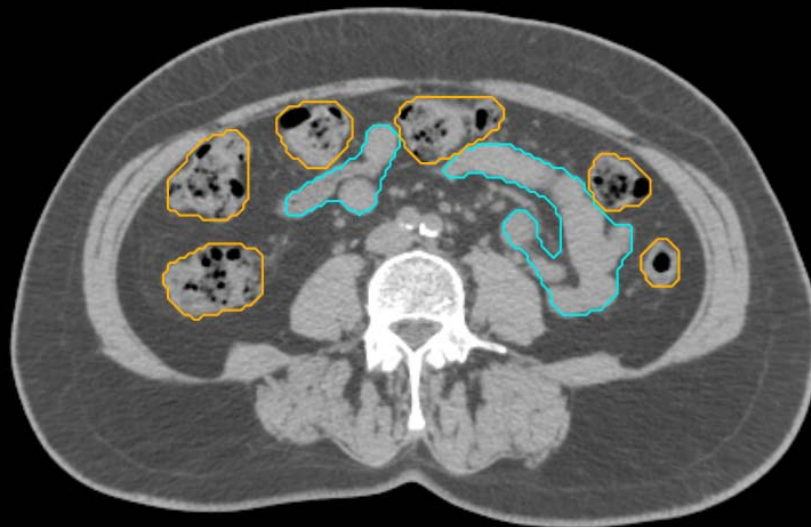
GYN:

- Sigmoid
- AnoRectum
- BowelBag



GYN/GI:

- UteroCervix
- Femur\_L
- Femur\_R
- Adnexa\_R
- Adnexa\_L
- Bladder

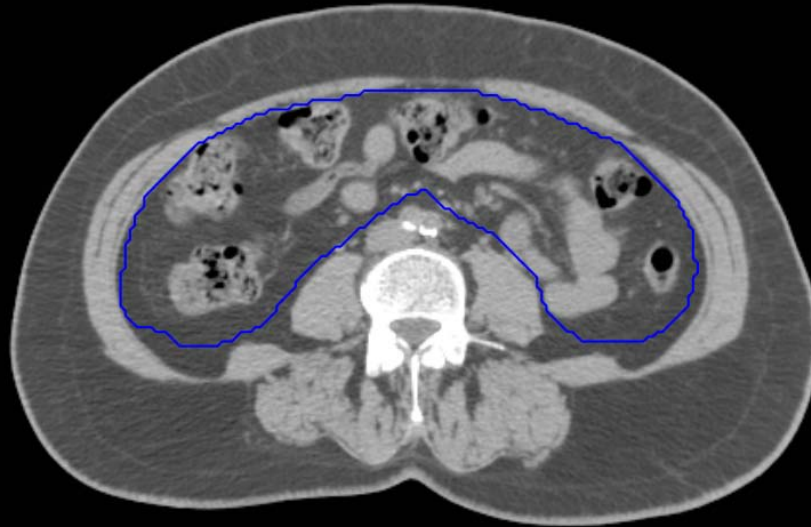


GI:

- Small Bowel
- AnoRectumSig
- Colon

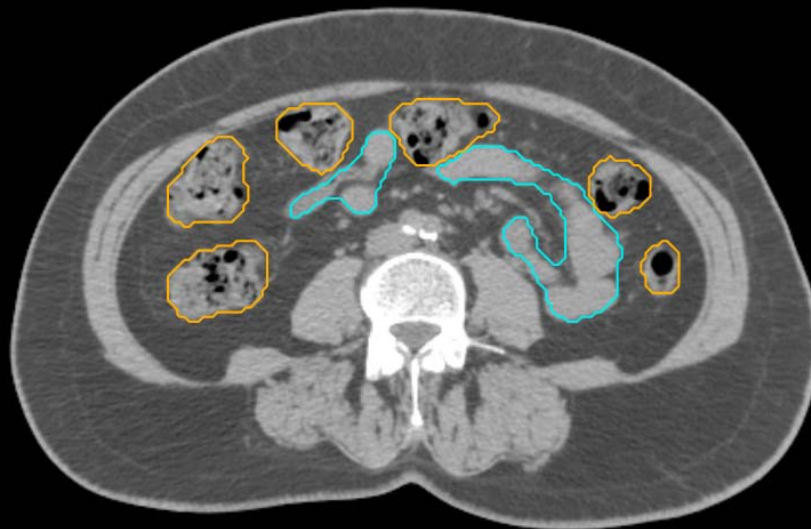
GYN:

- Sigmoid
- AnoRectum
- BowelBag



GYN/GI:

- UteroCervix
- Femur\_L
- Femur\_R
- Adnexa\_R
- Adnexa\_L
- Bladder

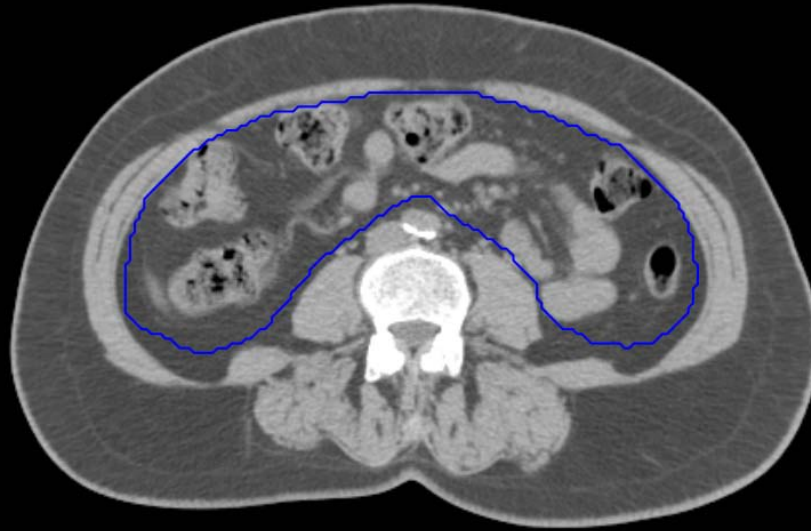

GI:

- Small Bowel
- AnoRectumSig
- Colon

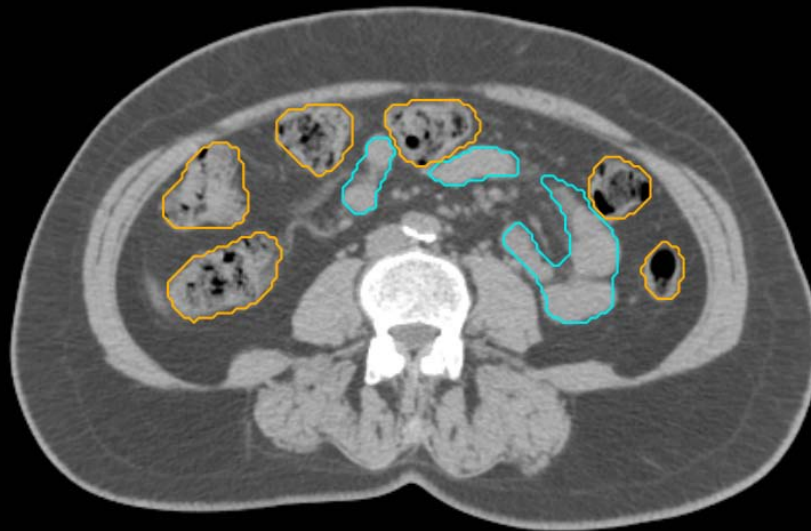GYN:

- Sigmoid
- AnoRectum
- BowelBag



GYN/GI:

- UteroCervix
- Femur\_L
- Femur\_R
- Adnexa\_R
- Adnexa\_L
- Bladder

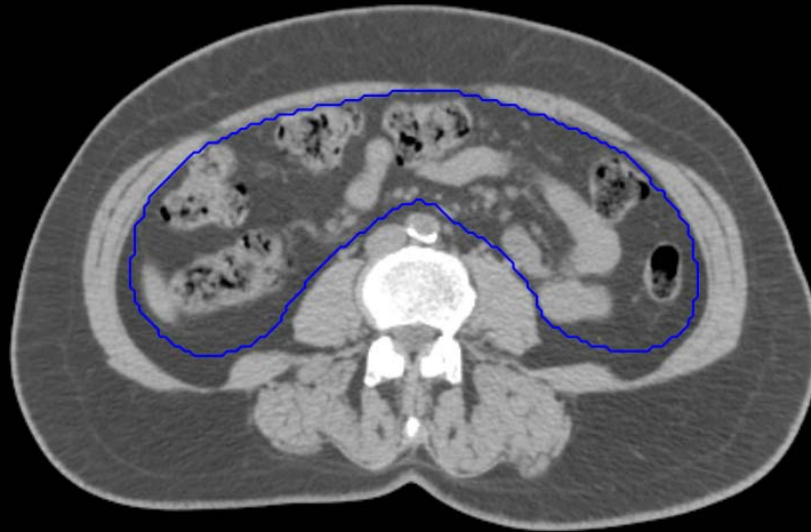

GI:

- Small Bowel
- AnoRectumSig
- Colon

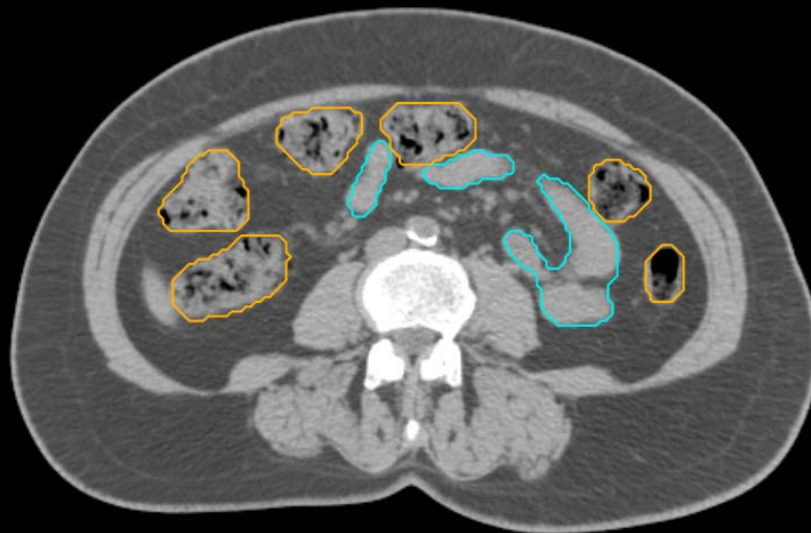GYN:

- Sigmoid
- AnoRectum
- BowelBag



GYN/GI:

- UteroCervix
- Femur\_L
- Femur\_R
- Adnexa\_R
- Adnexa\_L
- Bladder

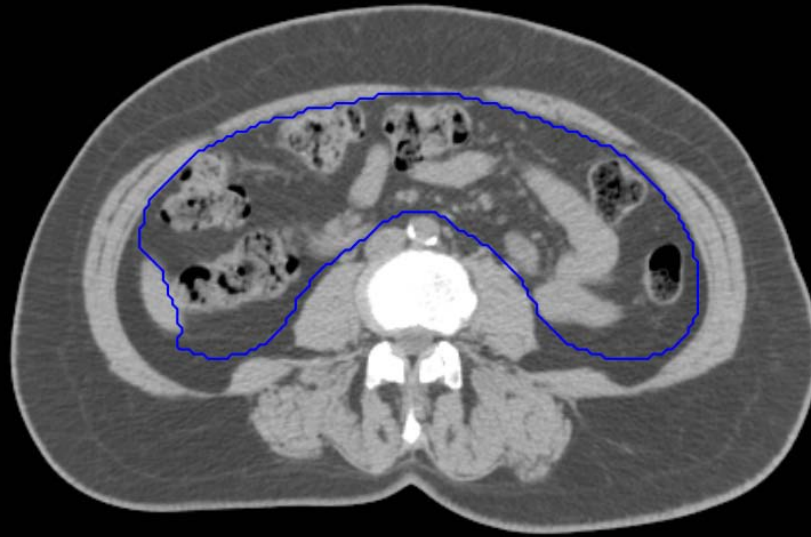


GI:

- Small Bowel
- AnoRectumSig
- Colon

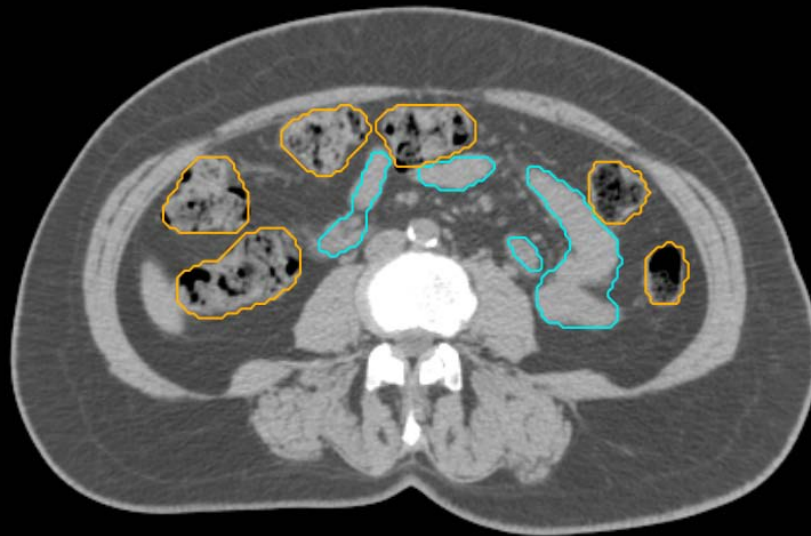
GYN:

- Sigmoid
- AnoRectum
- BowelBag



GYN/GI:

- UteroCervix
- Femur\_L
- Femur\_R
- Adnexa\_R
- Adnexa\_L
- Bladder

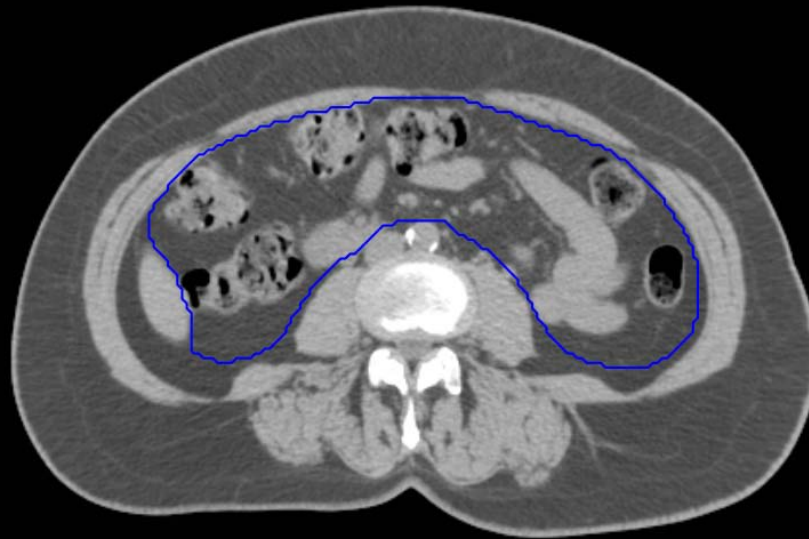


GI:

- Small Bowel
- AnoRectumSig
- Colon

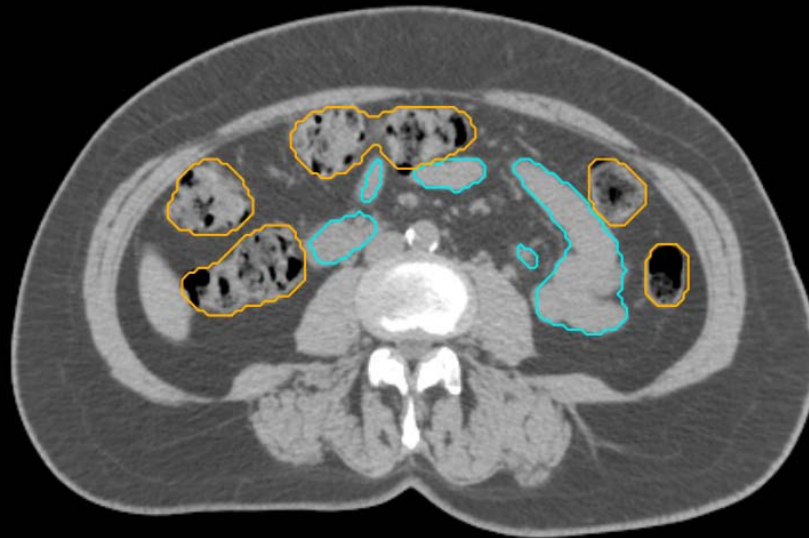GYN:

- Sigmoid
- AnoRectum
- BowelBag



GYN/GI:

- UteroCervix
- Femur\_L
- Femur\_R
- Adnexa\_R
- Adnexa\_L
- Bladder



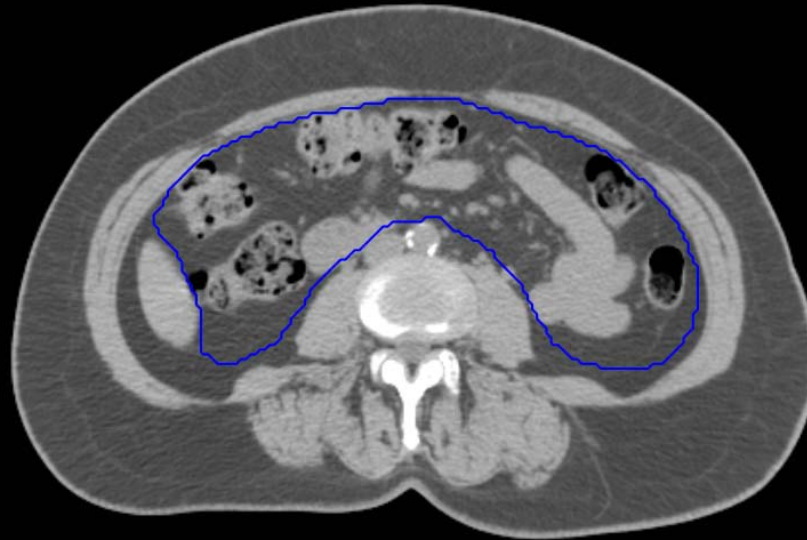GI:

- Small Bowel
- AnoRectumSig
- Colon



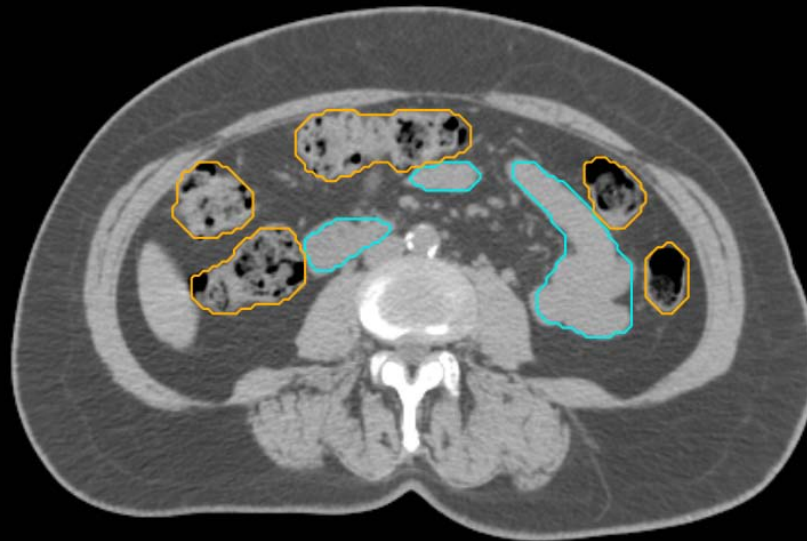GYN:

- Sigmoid
- AnoRectum
- BowelBag



GYN/GI:

- UteroCervix
- Femur\_L
- Femur\_R
- Adnexa\_R
- Adnexa\_L
- Bladder



GI:

- Small Bowel
- AnoRectumSig
- Colon