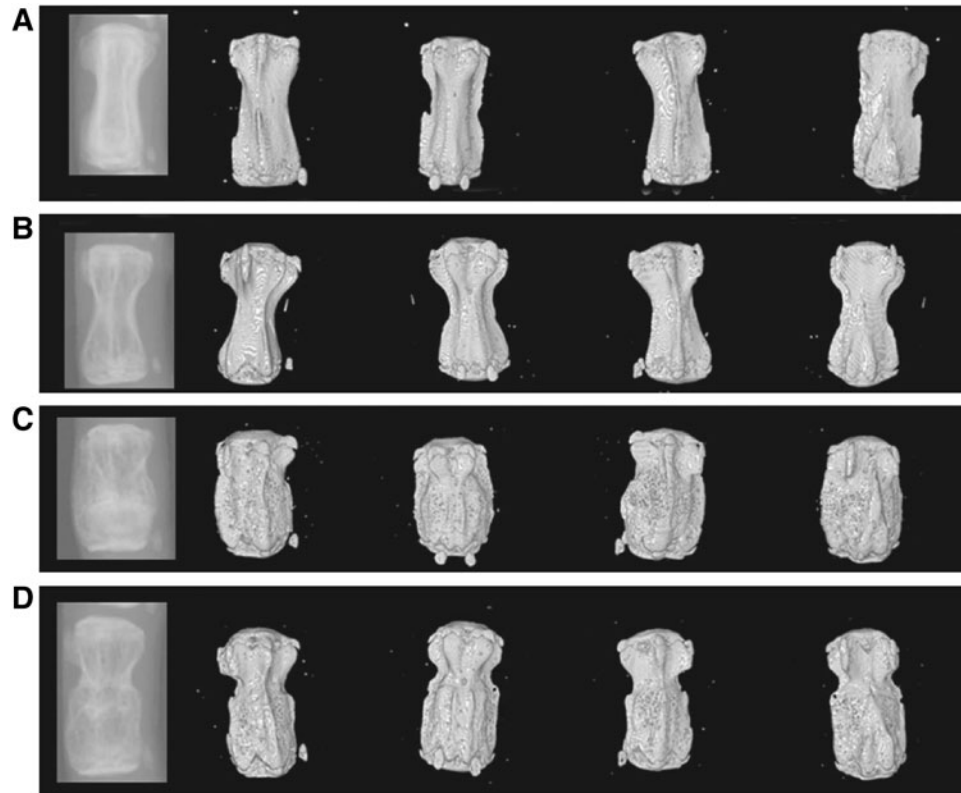


Supplementary Data



SUPPLEMENTARY FIG. S1. X-ray image of tail vertebra and the corresponding micro computerized tomography (μ CT) images shown at four different points of rotation for (A) a normal wild-type vertebra, (B) a normal *oim* vertebra, (C) an *oim* vertebra with an obvious callus, (D) an *oim* vertebra with evidence of bone remodeling suggesting previous callus.