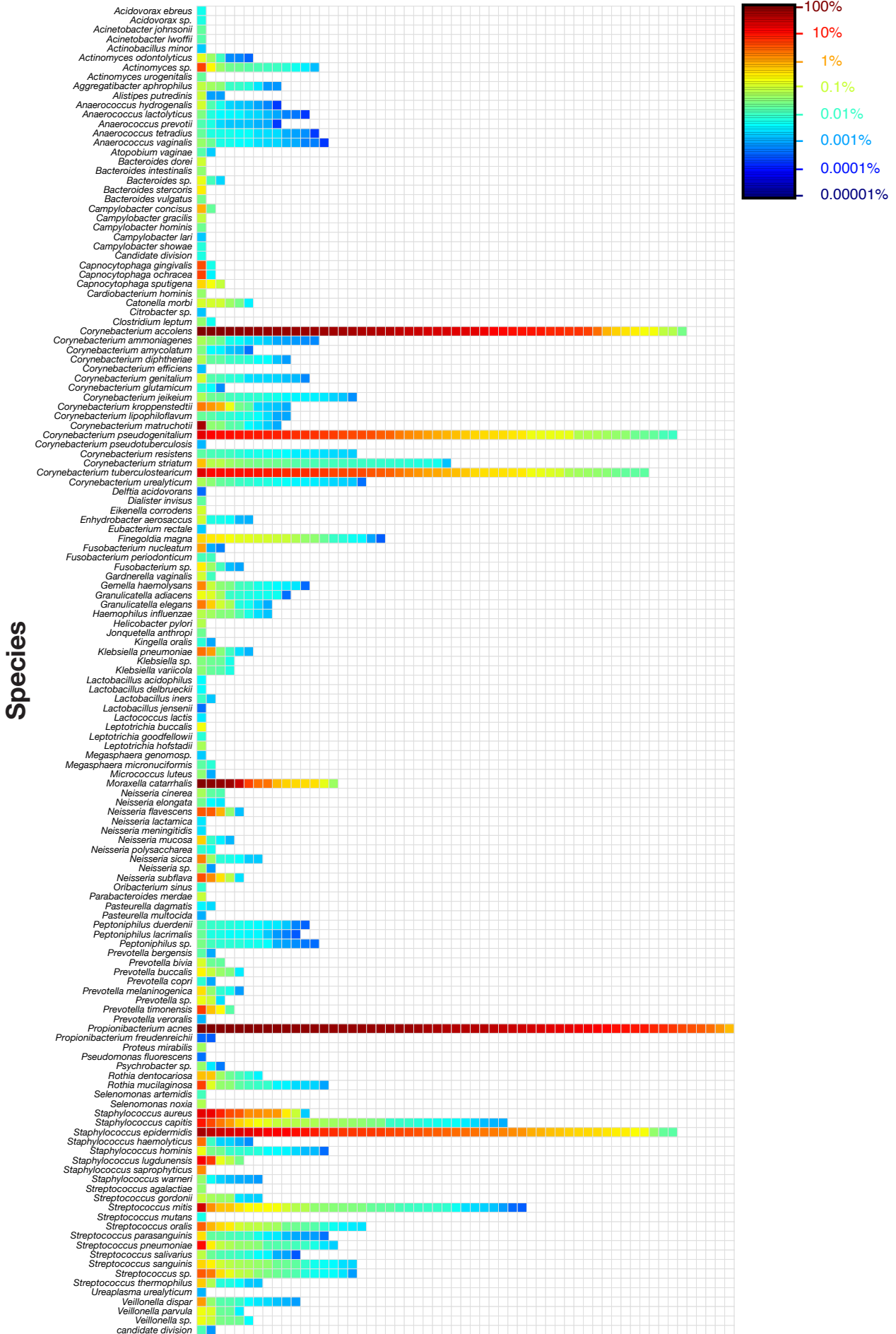
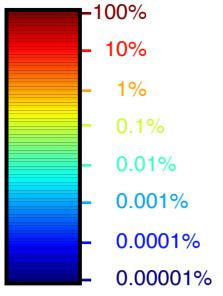


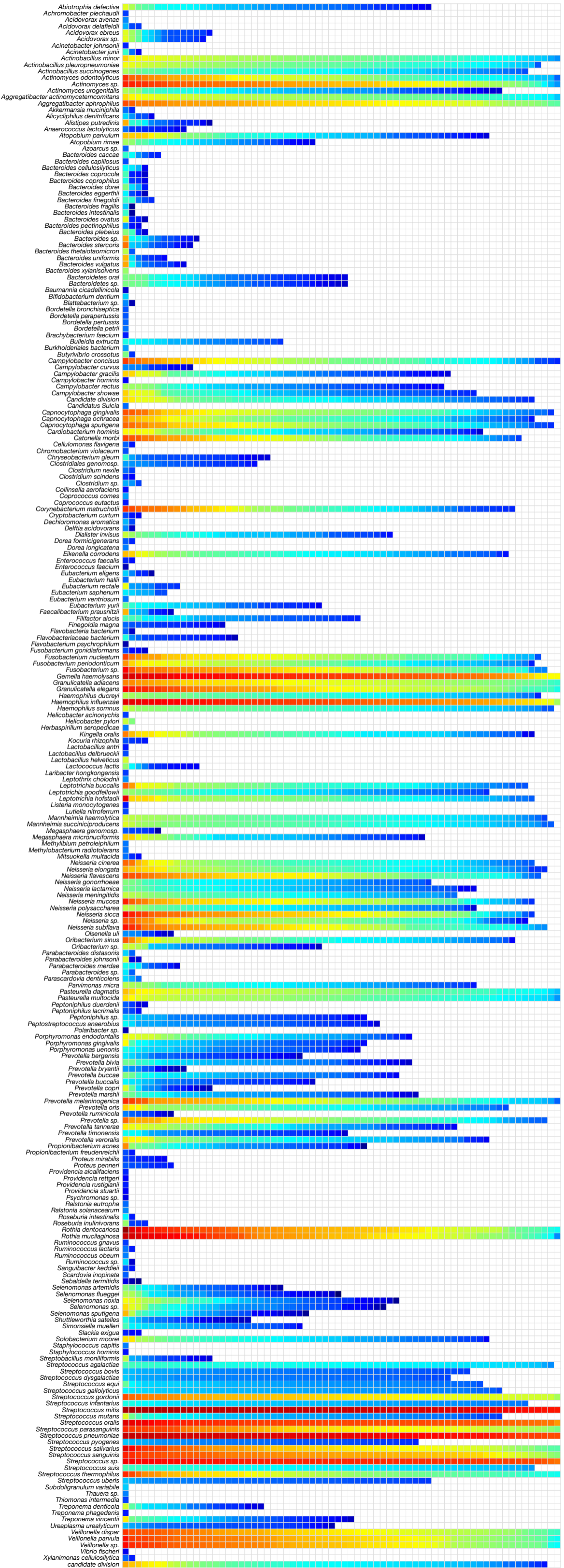
Anterior Nares



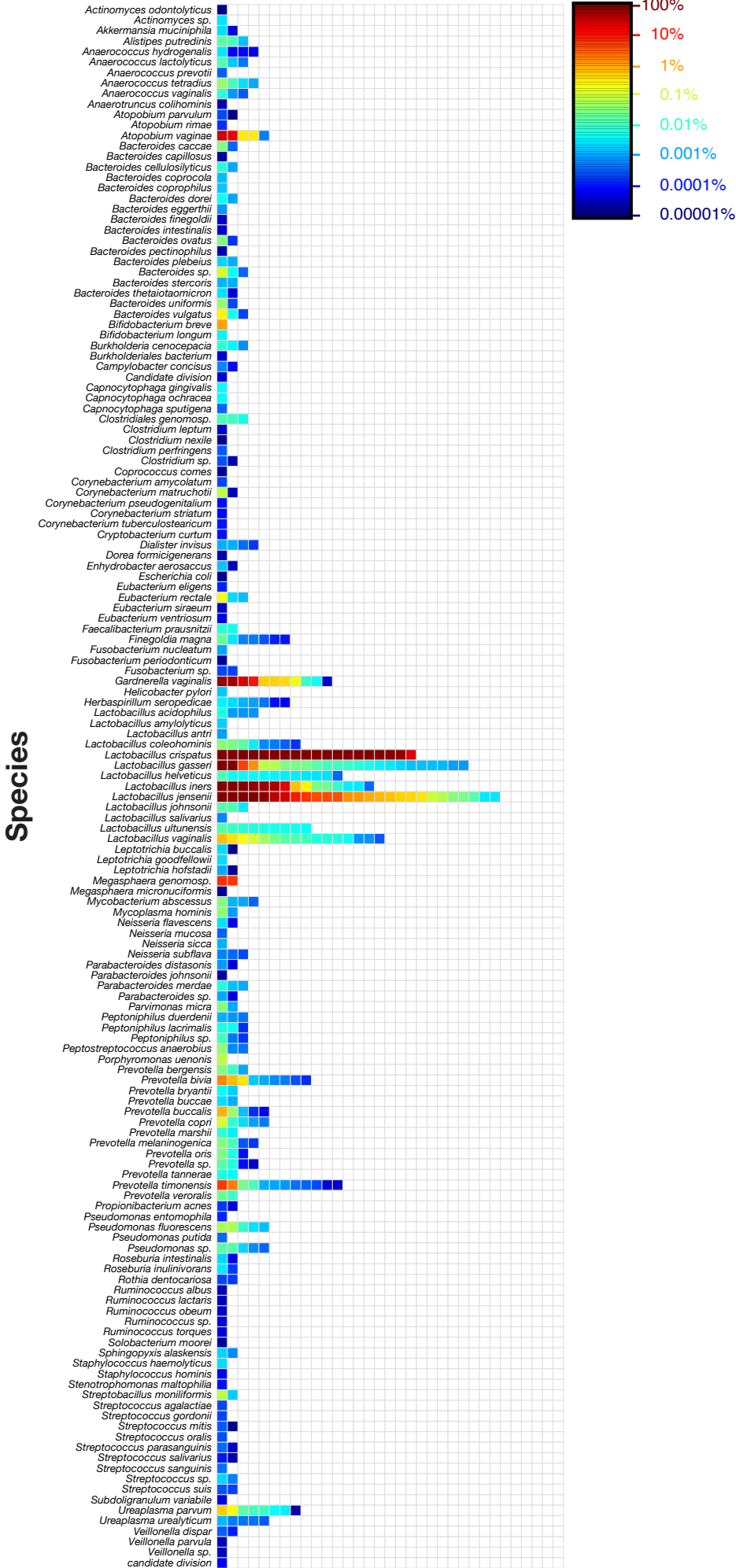
Buccal Mucosa



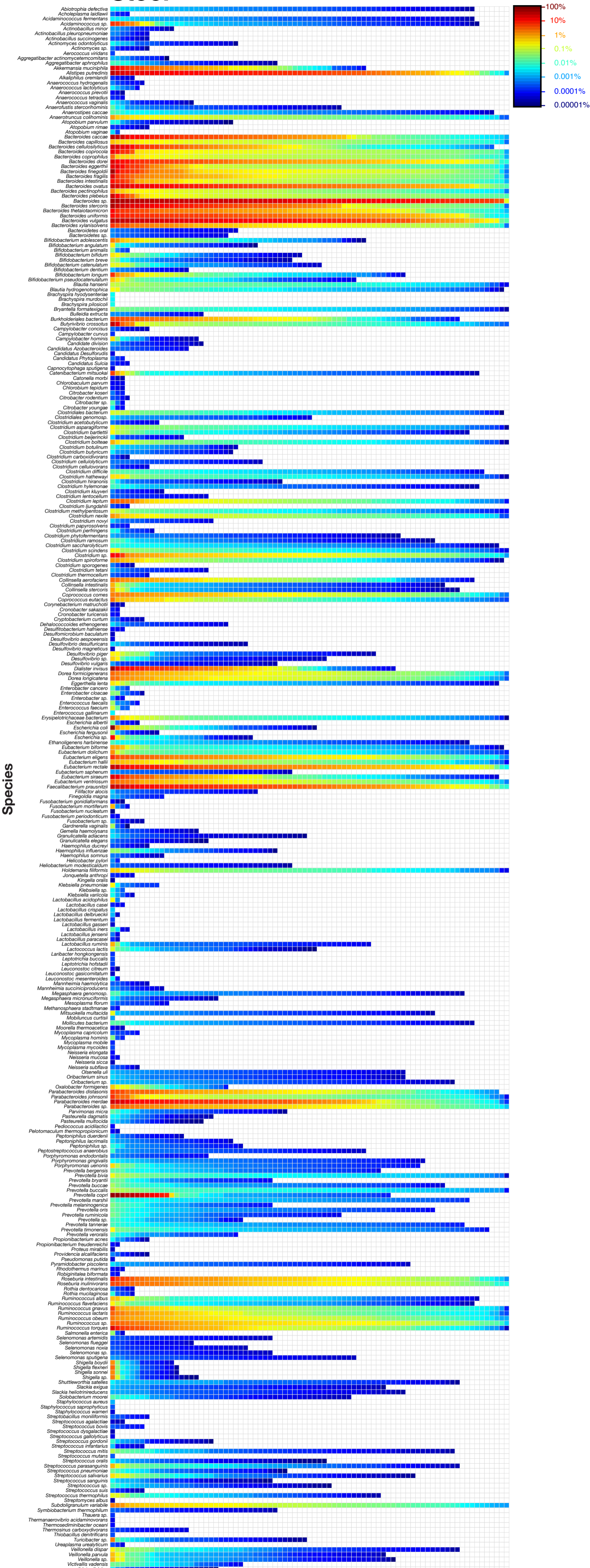
Species



Posterior Fornix



Stool



Supragingival Plaque

