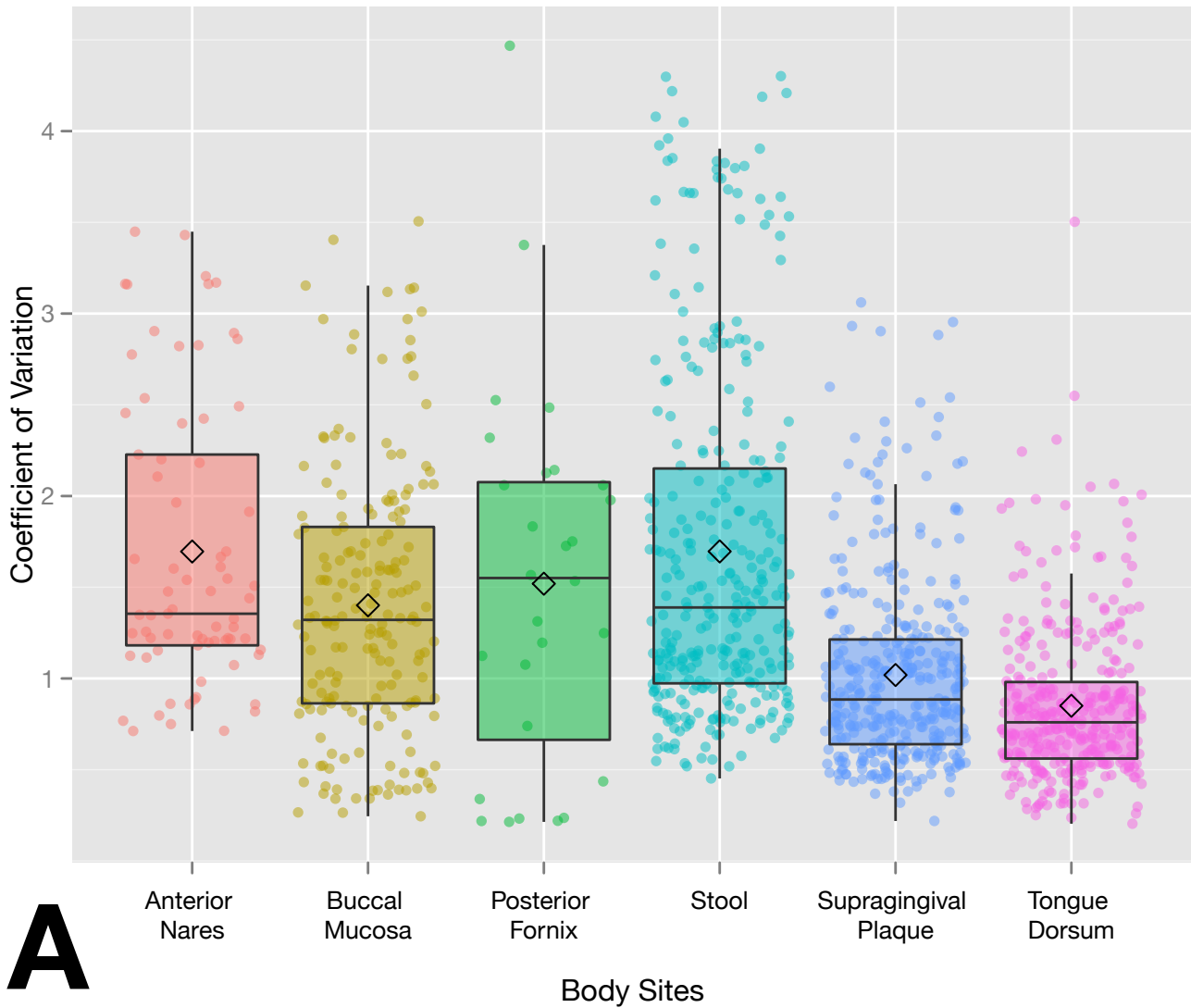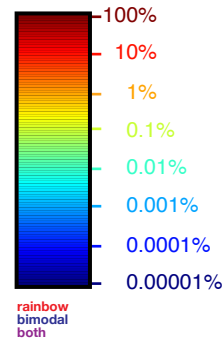




Buccal Mucosa



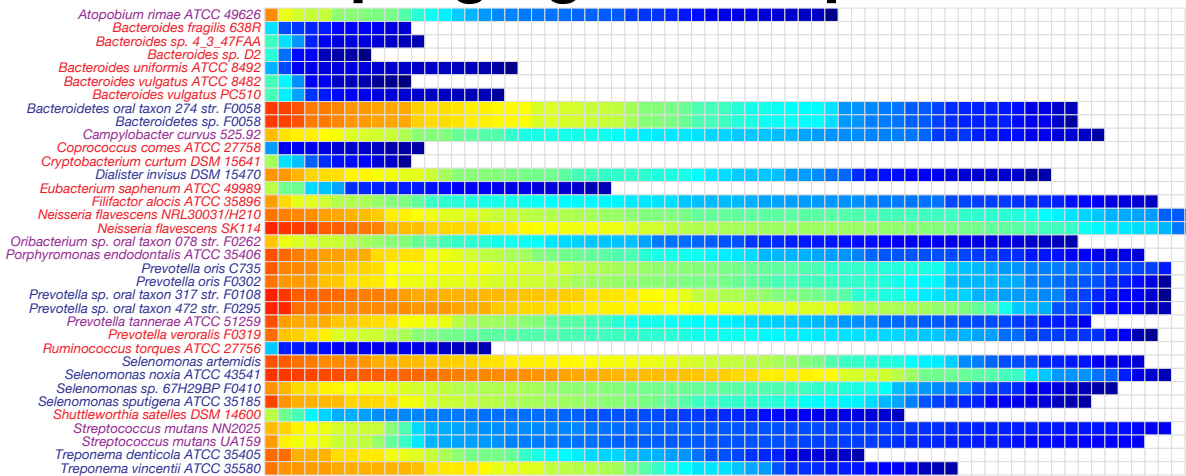
Posterior Fornix



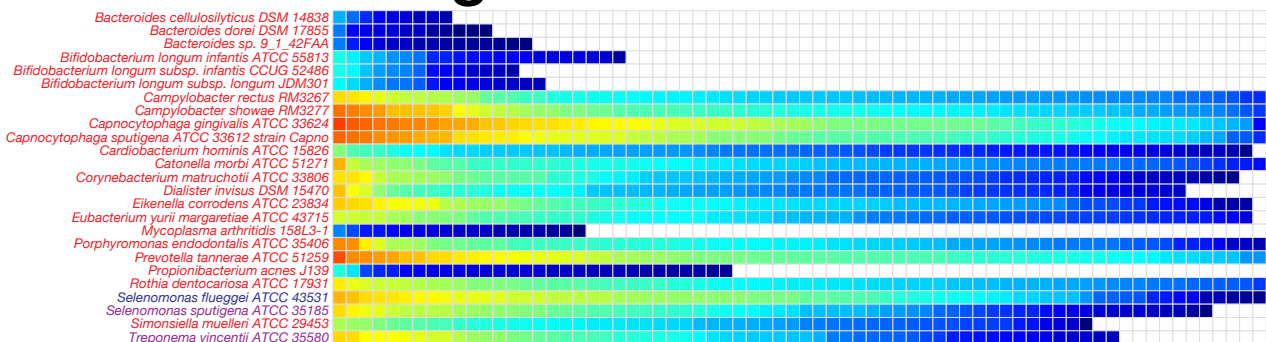
Stool



Supragingival Plaque



Tongue Dorsum



B